ONLINE FIRST

This is a provisional PDF only. Copyedited and fully formatted versión will be made available at final publication

HISTOLOGY AND HISTOPATHOLOGY

ISSN: 0213-3911
e-ISSN: 1699-5848

Submit your article to this Journal (http://www.hh.um.es/Instructions.htm)

Traumatic brain injury: estimate of the age of the injury based on neuroinflammation, endothelial activation markers and adhesion molecules

Authors: Massimiliano dell'Aquila, Aniello Maiese, Alessandra De Matteis, Rocco Valerio Viola, Mauro Arcangeli, Raffaele La Russa and Vittorio Fineschi

DOI: 10.14670/HH-18-319
Article type: REVIEW
Accepted: 2021-02-24
Epub ahead of print: 2021-02-24

This article has been peer reviewed and published immdediately upon acceptance.
Articles in "Histology and Histopathology" are listed in Pubmed.
Pre-print author´s version

Traumatic brain injury: estimate of the age of the injury based on neuroinflammation, endothelial activation markers and adhesion molecules.

Massimiliano dell'Aquila[1], Aniello Maiese[1,2], Alessandra De Matteis[1], Rocco Valerio Viola[1], Mauro Arcangeli[3], Raffaele La Russa[1,2], Vittorio Fineschi[1,2*]

[1] Department of Anatomical, Histological, Forensic and Orthopaedic Sciences, Sapienza University of Rome, Viale Regina Elena 336, 00161 Rome (RM), Italy

[2] IRCSS Neuromed Mediterranean Neurological Institute, Via Atinense 18, 86077 Pozzilli (IS) Italy

[3] Department of Life, Health and Environmental Sciences, University of L'Aquila, L'Aquila, Italy.

Contact details for corresponding author

* Vittorio Fineschi, Department of Anatomical, Histological, Forensic and Orthopaedic Sciences, Sapienza University of Rome, Viale Regina Elena 336, 00161 Rome, Italy. Phone: 3277396980 Email: vittorio.fineschi@uniroma1.it

Keywords

Traumatic Brain Injury, Age Estimation, Immunohistochemistry, Brain, Pathology, Forensic Science.

Short title

Dating traumatic brain injury

Summary

Studies on traumatic brain injury (TBI) are applicable not only in the clinical context, but also in the forensic field. Over time, the literature has accumulated scientific evidence supporting the use of specific histopathological tests in dating traumatic brain injuries. In primary damage, cell death occurs by necrosis/apoptosis. In secondary injury, the underlying mechanisms are inflammation and ischemia. The inflammatory response of the central nervous system (CNS) follows the common steps of the innate response. In head injury, the blood brain barrier (BBB) undergoes both functional damage and, subsequently, finer structural changes. Scientific evidence has shown modifications of the junctional-endothelial system that favors the extravasation of immunocompetent cells. The histological evaluation of the subdural hematoma, of the cerebral contusions, of the diffuse axonal damage can certainly bring useful elements, with limitations, to the chronological evaluation of the lesions. Many markers have been used to better define the dating of the head injury. Several authors also analyzed the usefulness of secondary damage markers in brain tissue. The progress achieved with immunohistochemistry is significant compared to the use of routine staining. With immunohistochemistry it is possible to identify much narrower and more precise time intervals and, above all, with greater probative reliability. Recently attention has been paid to the modification of structural proteins and miRNAs. Future research is already started and entrusted to multidisciplinary teams that know how to combine their specific skills in search of a reproducible standard of known and sufficient accuracy.

List of abbreviations

ACT = alpha1-antichymotrypsin

APC = antigen-presenting cell

ApoE = apolipoprotein E

APP = amyloid precursor protein

BBB = brain-blood barrier

CD15 = cluster differentiation 15

CNS = central nervous system

CP = choroid plexuses

CSEN = calseniline

DAI = diffuse axonal injury

GFAP = glial fibrillary acidic protein

HAM = human alveolar macrophage

HLA-D = human leukocyte antigen D

IL-1β = interleukin-1 beta

LCA = leukocyte common antigen

MHC = major histocompatibility complex

MRF1 = microglial response factor 1

NF = Neurofilaments

PRPH = peripherin

TBI = Traumatic brain injury

TJ = tight junctions

TMEM119 = trans-membrane protein 119

TLR = toll-like receptor

TNF-α = tumor necrosis factor alfa

TUNEL = TdT-mediated dUTP nick end labeling

UCHL 1 = ubiquitin carboxyl-terminal hydrolase isozyme L1

Traumatic brain injury

Traumatic brain injury (TBI) causes various types of lesions that result in aberrant changes to the anatomy and physiology of the brain. TBI can be defined as damaged caused by the application of mechanical forces to the skull and to its contents (Stein et al., 2017; La Russa et al., 2020).

Cranio-encephalic traumatism includes specific nosographic entities with a "chronic" character, meaning that they are caused by repetitive blunt force impacts rather than a single traumatic event. An example of such a condition is chronic traumatic encephalopathy, a syndrome that was first described between 2002 and 2009 and was found to be involved in the deaths of former US athletes (football players and wrestlers) and to be analogous to boxing dementia (or "punch drunk syndrome"), which was identified by the first decades of the twentieth century (Omalu et al., 2011).

The present study focuses, instead, on patients with acute TBI, which constitute the largest group of TBI patients. It is estimated that there are almost one and a half million patients with acute TBI in the United States, of which 50,000 die (Thomas et al., 2008). More generally, TBI is the main cause of severe neurological disability in the Western population under 40 years of age (Böhmer et al., 2011).

It is no coincidence that TBI is common in both forensic pathology and criminal conduct and is becoming an important consideration in civil liability for accidental falls and social and private accident insurance (Oliver et al., 2008).

In recent decades, the physiopathological mechanisms underlying brain damage resulting from TBI have been extensively investigated through to the use of experimental murine models. The knowledge acquired for the clinical purpose of identifying potential pharmacological agents to counteract brain damage and consequent neurological disability (Lo, 2010) can also be used for medical-legal purposes. However, data reported by literature appear fragmentary and contradictory, often concerning experimental studies which have used markers that are scarcely reliable in human cases of traumatic brain damage. These neurobiological insights into the mechanisms of the cellular responses implicated in brain damages, and the characterization of the various mechanisms involved might open new horizons for understanding the time of onset of a brain lesion, the pathophisiological evolution and for effective therapeutic strategies (Riezzo, 2010; Fineschi, 2017). In this review, we discuss scientific evidence supporting the use of specific histopathological tests for the dating of traumatic brain injury.

Physiopathology of traumatic brain injury and the role of neuroinflammation

Following mechanical trauma to the head, the brain undergoes a complex series of damaging events, which implies the occurrence of various correlated mechanisms. First, it is necessary to conceptually distinguish between the two major categories of damage to the central nervous system (CNS). Primary damage occurs immediately after trauma and includes two different types of damage: diffuse damage (concussion and diffuse axonal injury (DAI)) and focal damage (contusions and haemorrhages due to direct rupture of the vascular walls) (Ropper et al., 2019). Primary damage results from the breakdown of cellular membranes in nervous tissue and the dispersion of the cytoplasmic content and organelles caused directly by mechanical force; cell death is thus achieved by a combination of necrosis and apoptosis (Williams et al., 2007)

The so-called "secondary" damage develops within minutes following the initial trauma and develops in the subsequent days or even weeks. It is caused by two pathophysiologically prevalent and somewhat overlapping processes, namely, inflammation and ischaemia. More precisely, the activation of the local inflammatory response is a direct and exclusive consequence of trauma, while localized or generalized cerebral ischaemia is an epiphenomenon of cerebral vasospasm that occurs mainly in the presence of intracranial haemorrhage.

The activation of the inflammatory response in the CNS generally follows common non-antigen-specific immune system pathways (the innate response). The first stimulus, therefore, is the interaction between molecules in the damaged tissue and ubiquitous receptors expressed on glial cells. Within a few seconds, resident cells are activated, which first triggers the pro-inflammatory cytochemical cascade. The next phase involves the recruitment of circulating cells both locally to the site of injury and globally throughout brain tissue.

The first cellular components to participate in the response to injury are pericytes and perivascular macrophages, which migrate to the affected area within the first two hours after the damaging event (Zehendner et al., 2015). At the same time, the constitutive cells of nervous tissue, especially astrocytes and microglial cells, acquire an "activated" phenotype and release pro-inflammatory cytokines. Microglial cells react to injury through the stimulation of Toll-like receptors (TLRs) (Shi et al., 2019) and switch from a branched morphology to an amoeboid morphology and assume the role of phagocytic cells in the CNS; this transition is marked by enhanced expression of microglial response factor-1 (MRF-1). On the other hand, reactive astrocytes produce more glial fibrillary acidic protein (GFAP) than normal astrocytes and

form what is called a "glial barrier". In phases involving lymphocyte populations, microglial cells play the role of antigen-presenting cells (APCs), interacting simultaneously with T4 and T8 lymphocytes by virtue of the dual expression of MHC (major histocompatibility complex) classes I and II (Jassam et al., 2017). These cells, together with macrophages, represent the main source of cytokines in the CNS, such as interleukin-1 beta (IL-1beta), interleukin-6 (IL-6) and tumour necrosis factor alpha (TNF-alpha) (Semple et al., 2010; Ziebell and Morganti-Kossmann, 2010; Chodobski et al., 2011; Sieber et al., 2011; Abdul-Muneer et al., 2015).

It has been shown that the expression of IL-1 beta mRNA increases in the cortex beginning 1 hour after injury and then in the hippocampus 6 hours after injury in experimental models (Suzuki et al., 2009; Helmy et al., 2011). On the ipsilateral side, the levels of IL-1 beta in the choroid plexus (CP) increase until they peak at 6 hours; however, in the contralateral CP, IL-1 beta expression is upregulated between 4 and 6 hours but is much lower than that on the ipsilateral side (Frugier et al., 2010). The kinetics of TNF-alpha expression are different; in the ipsilateral CP, there are two peaks: an immediate peak at 1 hour after trauma and a delayed peak at 6 hours after trauma. This biphasic pattern is not seen in the cortex.

After a slightly longer latency, glial cells and neurons are able to release chemokines, especially Cxcl10 (Israelsson et al., 2008), which interacts with the specific receptor Cxcr3 expressed by T and NK lymphocytes.

Another mechanism underlying the development of secondary brain damage days and weeks after primary damage is an increase in the expression and activation of enzymes with protease activity in tissues and cells (Liu et al., 2006). These neuronal and glial cell products further degrade cell membranes and vascular support structures, amplifying ongoing necrosis and apoptosis processes (Hausmann et al., 2004; Wu et al., 2017).

Alteration of the brain-blood barrier after TBI

As previously mentioned, the crucial process in the development of neuroinflammation secondary to trauma is the recruitment of specialized leukocyte populations from the systemic circulation to brain tissue. The process involves a series of modifications to the brain-blood barrier (BBB), which thus plays a central and decisive role in secondary injury.

The BBB refers to the cellular and molecular complex that constitutes the interface between encephalic capillaries and the relative interstitial space in the organ parenchyma. This unique structure of the CNS regulates the exchange of solutes in a highly selective manner to limit or prevent the passage of toxic agents (Takeshita and Ransohoff, 2012). It is composed of the capillary endothelium, which is has a tight structure and is formed by endothelial cells connected by numerous tight junctions (TJs). The basement membrane is continuous and contains pericytes, and the outermost layer is formed by the pseudopods of astrocytes (Chodobski et al., 2011). In the brain, the exchange of solutes with the blood is more permissive in some specialized areas in which the BBB is incomplete or absent, as in the case of the circumventricular organs and the choroid plexus (CP).

The involvement of the BBB in the establishment of brain damage is twofold. First, primary damage resulting from trauma affect the vasculature, causing partial destruction of the vessel walls and, therefore, structural failure of the BBB (Korn et al., 2005; Strbian et al., 2008; Tomkins et al., 2008). This primary damage was evidenced in an experimental study in which early and unexpected infiltration of T lymphocytes was observed only 30 minutes after the injury event. Early alterations in the BBB are necessarily destructive but may increase permeability due to impairment of endothelial cell function.

The post-acute phase, which can last for weeks and months, involves finer structural alterations in the normal molecular composition of the BBB, especially the junctional endothelial system (Chodobski et al., 2011). Some in vitro molecular expression studies in cell lines have shown that junctional adhesion molecules are redistributed and that the expression of occludin is downregulated in response to TNF-alpha stimulation (Nishioku et al., 2010).

However, the most characteristic changes in the selective permeability of the barrier are not related to the diffusion of water and solutes but rather to the extravasation of immunocompetent cells. In this way, the pro-inflammatory response of the cerebro-vascular unit results in the recruitment of circulating leukocyte populations to the site of damage to amplify and propagate neuroinflammation. Among the most obvious phenotypic modifications is an increase in the expression of adhesion molecules on the luminal surface of the endothelium, specifically ICAM-1, VCAM-1 and PECAM-1 (Zeng and Deng, 2005).

Transendothelial migration of leukocytes through the BBB is a multi-phase process involving a highly controlled chain of events, namely successive rolling, activation, arrest, crawling and migration. A preliminary process called "tethering" occurs, during which between leukocytes first contact the capillary endothelium, allowing the "margination" of cells with respect to the bloodstream. Rolling subsequently

takes place on the same molecular substrate through the interaction between endothelial selectins (P- and E-selectins) and leukocyte ligands (Kerfoot and Kubes, 2002). However, in the activation phase, signalling of chemokines such as Cxcl12 through the Cxcr4 receptor (Johnston and Butcher, 2002) induces the transition of other transmembrane receptors, integrins, into the active form. High-affinity leukocyte integrins bind stably with cell adhesion molecules (CAMs) expressed on the endothelium. The most common molecular interactions are between VLA-4, LFA-1, and MAC-1 (integrins) and ICAM-1 and VCAM-1 (Correale and Villa, 2007; Man et al., 2009).

The CNS vascular bed shows constitutive expression of E- and P-selections, but only in the endothelium of the venules in the CP and in the subarachnoid space (Kivisäkk et al., 2003). ICAM-1, on the other hand, is constitutively expressed globally. However, following trauma, the expression of ICAM-1 increases significantly with a precise time-dependent manner. In an experimental mouse model, an increase in ICAM-1 expression was observed in the cerebral hemisphere 4 hours after trauma and in the contralateral hemisphere 48 hours after trauma (Turowski et al., 2005; Williams et al., 2007). The infiltration of neutrophils into the cerebral parenchyma follows the same topographical and temporal pattern; only in the case of primary microhemorrhages can neutrophils be detected 30 minutes after the trauma (Whalen et al., 1999).

In a different experimental study, enhanced expression of E-selectin and ICAM-1 in endothelial cells was observed 2 hours after mild TBI, but there were no changes in VCAM-1 and MHC I or II class expression (Balabanov et al., 2001).

Timing of the onset of traumatic brain injury

As it is unclear how to measure it, the elapsed time after TBI is one of the most important factors for pathological-forensic evaluation. A typical question posed during autopsies is exactly when death occurred, i.e., how much time has elapsed between death and post-mortem examination. Similarly, dating can be used to determine the elapsed time since an injury.

In the case of TBI and subsequent death, chronological references may therefore have dual usefulness. On the one hand, they provide a temporal reference for the traumatic event itself; on the other hand, by correlating the TBI dating criteria with the remaining pathological and circumstantial evidence, it is possible to provide clarifications on the exact modalities of death. Biochemical markers and post-mortem

fluid analysis have been used for timing purposes, but this is not the focus of the present review (Li et al., Zaki et al., 2011; Olczak et al., 2017; Sieber et al., 2018).

The formation of a sufficiently large subdural haematoma can provide information for TBI dating. Subdural haematomas are observed concomitantly with head trauma less frequently than subarachnoid haemorrhages, but by virtue of their primary dislocation and diffusion properties, they allows the identification of developmental phases within a relatively limited time frame (Walter et al., 2009).

Traditionally, it is believed that the origin of subdural bleeding corresponds to the rupture, even if only partial, of the so-called "bridging veins", the post-capillary venules that drain the cerebral flow from the hemispherical convexities directly into the sagittal venous sinus. Their particular anatomical location together with their parasaggital topography accounts for their susceptibility to shear forces that occur in violent acceleration/deceleration injuries (Miller and Nader, 2014).

Due to the specific topography and kinetics of (venous) bleeding at the origin of subdural haematomas, these lesions tend to assume the pathological appearance of organized haematomas; therefore, it is possible to describe their evolutionary trends over time as in other areas of the body. These characteristics can only be clearly observed through a thorough histological examination and representative sampling of all the components of the lesion in question. Since a detailed discussion of these findings is not part of the purposes of this review, please refer to other more authoritative publications on the subject for more information (Di Maio and Dana, 2007). Here, it is sufficient to note that the initial appearance of fibroblasts at the interface between the haematoma and dural membrane, the subsequent thickening and stratification of the same fibroblasts (Chmieliauskas et al., 2018), and the appearance of capillary neoangiogenesis and granular tissue (Rodríguez-Baeza et al., 2003) occur at 2-3, 4-5 and 5-10 days, respectively (Strassmann, 1949). Conversely, there are no useful markers for dating this kind of lesion within the first 48 hours after trauma; moreover, the diagnostic accuracy of the morphological parameters that describe the evolution of the lesion are lost after the first two weeks (Oehmichen et al., 2003).

Based on these findings, studying meta-traumatic intracranial haemorrhagic lesions has rather utility in determining the time of onset of TBI. Instead, the research in this specific field has focused much more on the characterization of cortical contusions, which are lesions that are systematically associated with a TBI of sufficient energy and are described as bruises on the cortical surface of brain with or without extension to the white matter (Freytag and Lindeberg, 1957). Early microscopic changes followed by specific

degenerative and reactive processes involving neuronal and glial cellular populations almost always occur in cortical tissue subjected to direct mechanical trauma (Kaur and Sharma, 2018).

As will be discussed later in this paper, most of the studies in the field of forensic pathology have involved autoptic material from the cerebral cortices of subjects who were affected by and subsequently died from TBI collected at very different time points. In only some of these studies from as early as the middle of the twentieth century were the data collected at particular time intervals after trauma.

Much more recently, a completely different parameter of primary post-traumatic brain injury, DAI, has been increasingly characterized. DAI is a direct manifestation of mechanical forces applied to the human body due to a completely inertial phenomenon, that is, a sudden acceleration/deceleration transmitted to the cerebral mass floating in the cerebrospinal intracranial fluid that is capable of producing fatal lesions even in the absence of evident contusive or haemorrhagic foci (O'leary and Nichol, 2018).

DAI was initially identified in subjects who experienced violent inertial forces and ended up in a coma in the absence of apparent direct trauma to the head or an entity sufficient to justify the degree of neurological and systemic compromise (Smith et al., 2003). Subsequently, the understanding of the morphological and ultrastructural consequences of the lesion, which themselves are recognizable, has increased to the point that studies have identified parameters that are useful for post-mortem dating of TBI (Johnson et al., 2013).

To the best of our knowledge, the first study (in English) designed specifically to establish the morphologic timeline after cerebral contusion was a study by Oehmichen et al. (1986), a group of researchers from different institutes of forensic medicine in Germany. The researchers collected 275 autopsy cases and performed a combined quantitative and qualitative analysis of macrophage number in brain lesions, all of which involved intraparenchymal haemorrhage. The researchers obtained a large amount of data regarding the cellular size of macrophage infiltrates, the topographical distribution of the macrophages with respect to the lesion, and the histochemical reactivity of the cytoplasmic inclusions. The most interesting changes observed were the time point at which macrophages first appeared, i.e., 11.5 hours, and the time point of peak macrophage infiltration, i.e., 5 days after the trauma.

The localization data, on the other hand, did not provide chronologically precise conclusions and instead confirmed was already widely reported related to macrophage distribution and the peripheral demarcation of the parenchymal contusion-haemorrhage area. Furthermore, the data on the type of inclusions was varied and inconsistent with the few findings previously published in the literature.

Implementation of immunohistochemical assays for TBI dating

As is now the case in many other areas of pathological diagnostics, the most valuable and accurate tools are immunohistochemical techniques. Researchers who evaluated the use of specific markers for estimating the timing of cerebral cortical contusions initially focused on haematogenous cell populations infiltrating the lesions. In the first study on this topic, cluster differentiation 15 (CD15) was identified as a marker of granulocytes and leukocyte common antigen (LCA), cluster differentiation 3 (CD3) and ubiquitin carboxyl-terminal hydrolase isozyme L1 (UCHL-1) were identified as markers of lymphocytes; CD15 staining occurred extremely quick, i.e., 10 minutes after trauma, and is therefore a marker of immediate cell death following TBI. Staining for LCA, CD3 and UCHL1, however, was observed 1, 2 and 3-4 days after trauma, respectively (Hausmann et al., 1999).

The same authors applied an identical method for retrospective examination of autopsy tissues but extended the sampling to the perilesional parenchyma and assessed the specific reactive pattern of glial cells rather than the expression of markers of immunocompetent cells. They performed quantitative morphometric analysis of cells expressing glial fibrillary acidic protein (GFAP) and found a significant increase in the number of astrocytes astrocytic cells between 1 day and 4 weeks after TBI (Hausmann et al., 2000b). The correlation between GFAP expression and the cause of death in subjects suffering from TBI was subsequently studied, and the findings were in line with previously reported results, although the data were not used to determine the timing of these changes (Li et al., 2012).

In another publication, Hausmann and Betz (2001) observed that antibodies against alpha1-antichymotrypsin (ACT), vimentin and tenascin stained glial cells 3 hours, 22 hours and 7 days after trauma, respectively. In addition, they further analysed the expression of laminin, type IV collagen, tenascin, thrombomodulin and factor VIII in the cerebral blood vessel wall. The only significant differences between the experiment and control group was an increase in the expression of factor VIII beginning 3 hours after trauma, and increase in the expression of tenascin beginning 1-2 days after trauma and an increases in the expression of thrombomodulin after the first week (Hausmann and Betz, 2000a). Another index of cellular activation and proliferation, the expression of the Ki67-associated antigen MIB-1, was investigated, and it was found that MIB-1 expression was enhanced in cortical cerebral bruises not earlier than 3 days after trauma and was always detectable from 7 to 14 days (during the second week) after trauma; the positive cells were both proliferating macrophages and activated microglia (Hausmann, 2006).

Furthermore, Orihara and Nakasono (2002) investigated changes in immunoreactivity for apolipoprotein E (apoE) in brain tissue following trauma by comparing cortical autopsy samples taken from injured hemispheres with those taken from contralateral hemisphere. The results revealed that apoE was markedly expressed in both hemispheres but was expressed at a later time point (more than 2 hours after injury) than astrocyte markers. The finding considered most relevant by the authors, however, was that apolipoprotein expression was still increased more than one month after trauma.

Several immunohistochemical assays have been used in combination to quantitatively and qualitatively study macrophage infiltration associated with meta-traumatic intraparenchymal contusion-haemorrhages. Previously, Oemichen and colleagues (1986) obtained complex results related to the immunohistochemical characterization of cytoplasmic inclusions; however, the fundamental finding was that cytoplasmic inclusions formed quickly, which was inconsistent with subsequent results (Biagas et al., 1992; Clark et al., 1994; Soares et al., 1995).

For this reason, the authors performed a pilot study in which they labelled monocytes and macrophages by immunostaining for cluster differentiation 68 (CD68), human leukocyte antigen D (HLA-D), human alveolar macrophage-56 (HAM-56), human macrophage antigen LN-5 (LN-5), and 25F9 antigen. Positive staining was correlated not only with the posttraumatic interval but also with topographical distribution; CD68+ activated macrophages were observed in the intraparenchymal haemorrhage beginning only 3 hours after trauma, whereas this same subset of cells did not infiltrate the injured cortex before 12 hours after trauma. In this cortex, the most obvious cell population was HLA-D+ cells (6 hours after trauma). The infiltration of LN-5- and HAM-56-positive leukocytes was significantly slower, occurring only after 48 hours in perilesional brain tissue (Oehmichen et al., 2009).

Another pathophysiological process related to TBI that researchers have attempted to study to estimate the timing of injury is apoptosis, which occurs in brain tissue following trauma. Dressler et al. (2007) sought to identify time-dependent and cell-specific alterations in apoptosis following trauma by combining index assays (staining for caspase 3 and TdT-mediated dUTP nick end labelling– (TUNEL) staining) with immunohistochemical staining of activated macrophages (CD68), glial cells (GFAP) and lymphocytes (CD3). The researchers reported that neurons evidently expressed caspase 3 beginning 1 hour after trauma and that glial cells and neurons were positive for TUNEL beginning 2 hours after trauma; caspase 3 was expression in glial cells at a slightly later time point (5 hours after trauma). Apoptosis in brain tissue subjected to trauma was drastically reduced, if not absent, starting 4 days after the event. In another study,

Michiue et al. (2008) performed immunohistochemical analysis of brain samples to assess neuronal apoptosis but used an antibody against single-stranded DNA (ssDNA) and assessed the correlation between cause of death and different kinds of brain damage.

Other immunohistochemical markers for apoptosis are molecules associated with the ubiquitin-proteasome complex (ubiquitin and lysine 48-linked polyubiquitin chain (K48)); in a retrospective analysis of an autopsy series, the authors found an appreciable increase in glial and neuronal expression of these markers within 1 hour after TBI, which was sustained until 7 months later (Sakai et al., 2014). In the same paper, they also measured the expression of common markers of autophagy, another pathophysiological mechanism of secondary damage, and they observed that the latency to expression was similar but that the expression persisted for a shorter amount of time, i.e., a maximum of 37 days.

As mentioned previously, the presence of a specific microscopically detectable lesion in the white matter has shown possible utility for estimating the elapsed time since TBI. The first evidence for this was obtained by Blumbergs et al. (1995) in a small retrospective series. The researchers employed a rigorous mapping scheme of the white matter in the brain and identified axonal damage by immunostaining for amyloid precursor protein (APP). This method revealed single immunoreactive axons randomly scattered within unstained tissue; morphologically different patterns were observed, but they were all attributed to axonal damage, and such damage was observed in all types of TBI investigated in the study. Since the latency to the emergency of this damage in the autopsy series was 105 minutes, it was possible to infer the timing of the injury. Subsequent studies that focused on the same molecular target (beta-APP) but in much larger and heterogeneous experimental cohorts showed that the latency to detectable DAI was only 35 minutes through immunohistochemistry (Hortobágyi et al., 2007).

According to literature on the subject, the characterization of neurofilaments and their alterations resulting from TBI has emerged as a topic of interest (Kobek et al., 2014). Neurofilaments (NFs) are intracellular structural proteins (cytoskeleton) of intermediate filaments and are specifically expressed by neurons. Observations of the molecular depletion of neuronal cytoskeleton components resulting from trauma (Hamberger et al., 2003), Kobek et al., 2016) have revealed a correlation between the morphometric expressivity of NF and the interval between head injury and death. The researchers detected a single marker (anti-human neurofilament protein clone 2F11) and performed computerized morphometric analysis to determine two fundamental parameters: the number of recognizable individual structures and the ratio

between the total immunopositive area and the area of the whole image (area fraction). The results showed a statistically significant correlation between neurofilament expression in the tissue and the area fraction.

Neri et al. retrospectively examined brain samples from patients who died after surviving for different periods of time following TBI and assessed AQP4 expression and its correlation with neuroinflammation and hypoxia. AQP4 expression significantly and progressively increased from the acute stages of traumatic insult, and AQP4 expression was upregulated at 7 to 30 days. GFAP expression in astrocytes was the highest after 14-30 days of survival. HIF-1α expression showed a progressive and significant increase. IBA-1 staining revealed that microglia were activated starting three days after trauma, and IBA-1 expression progressively increased for the next 15 to 20 days after the initial trauma. CD68 staining showed that basal macrophages/phagocytes were activated mostly around blood vessels. After 15 and 30 days of survival, CD68 showed the most abundant immunoreactivity in or around the area of necrosis. CD15 immunoreactivity was observed after one day of survival after injury and became increasingly evident around the margin of the necrotic area after seven days of survival (Neri et al., 2018).

It must be emphasized that these studies are very different from those in which immunohistochemistry for NF was performed to detect beaded axons and retraction bulbs, which are lesional patterns associated with head trauma. These changes, in fact, were found to occur at defined time intervals in the cerebral cortex, perivascular tissue and hemispherical white matter by a qualitative study (Romero Tirado et al., 2018).

Yue Lianga et al. (2019) studied DAI, one of the most common and serious pathological consequences of TBI, in rats. Immunohistochemical analysis revealed an increase in the expression of peripherin (PRPH), a cytoskeletal organization protein, and calseniline (CSEN), a calcium ion–regulatory protein, indicating that they have good potential as biomarkers of early DAI.

In a recent review on DAI, Frati et al. (2017) confirmed that ROS-mediated axonal degeneration is mainly caused by extracellular Ca2+. Removal of extracellular Ca2+, but not blockade of mitochondrial Ca2+ release, is an efficient strategy for lowering intracellular Ca2+ levels and inhibiting spheroid formation. In vivo, calpain and calcineurin inhibition can mitigate axonal degeneration.

Bohnert et al. (2020), in an immunohistochemical study of neuroinflammation, documented the usefulness of trans-membrane protein 119 (TMEM119) as a rapidly expressed microglia-specific marker in forensic evaluations of TBI. TMEM119 can be used to distinguish microglia from resident and infiltrating macrophages. In their study, Bohnert et al. stained samples of human brain tissue from subjects who died of TBI with antibodies against TMEM119. The highest number of TMEM119-positive cells was observed

patients with acute TBI, and there were important differences between these patients and control patients who experiences sudden cardiovascular death. These results suggest that TMEM119 could be used as a marker to estimate the minimum survival time after TBI.

In addition to miRNAs (Pinchi et al., 2018), changes in the expression of cytoskeleton components and other structural proteins in neurons are the main focus of histopathological research on brain damage associated with head trauma, as demonstrated by the latest publications that used dynein, dynactin and kinesin as markers for post-mortem diagnosis with promising results (Olczak et al., 2019).

The results of these studies are summarized in Table 1.

Discussion

According to the literature and common handbooks of pathology, various synoptic tables have been formulated for the identification of the timeline of one or more morphological changes. According to Dettmeyer's manual of forensic histopathology (Dettmeyer, 2018), at least 20 different parameters associated with specific time intervals from the original trauma can by identified by histological examination. Some of these parameters lack any specificity regarding the kind of injury and have no time-dependent relationship with trauma, as they appear simultaneously. These changes include oedematous swelling and unspecific signs of cytological primary damage, such as neuronal degeneration, shrinkage and vacuolization. Axonal and nuclear swelling are common signs of analogous cellular modification and are detectable by routine haematoxylin and eosin staining but after a slightly longer time period of approximately 12-24 hours.

The most useful parameters, therefore, are determined by immunostaining for relatively common markers: within a few minutes after trauma, it is possible to observed CD15 immunoreactivity, which is correlated with very early infiltration of the first granulocytes, likely due to intraparenchymal haemorrhage. It is interesting to note that immunohistochemical staining for granulocytes allows us to observe these cells before routine histology (2 hours). Moreover, enhancement of specific assays for apoE in the whole hemisphere ipsilateral to trauma within 3-4 hours of latency, similar to the early loss of astrocytes indicated by immunostaining for GFAP (3 hours), has been reported. The marker that is expressed after the longest elapsed time from trauma, i.e., at least 7 days, is tenascin, which is a marker of a delayed vascular response to trauma (Figure 1).

At intermediate intervals, i.e., between 1 and 7 days, there is a time course of cellular recruitment and tissue infiltration because of the inflammatory response to trauma. According to the suggested scheme, on the second day after trauma, only LCA+ cells are detectable between 2 and 4 days after trauma, CD3+ lymphocytes appear; macrophages are observed as siderophages within 2-5 days; and haematoidin deposits appear in the lesional area after at least 6 days.

Certainly, quantitative and qualitative analysis of inflammatory cellular infiltrates provides valuable information regarding the timing of TBI, as well as injury to other anatomical sites and other types of damage. This has already been reported previously for a pool of specific markers of different macrophage subpopulations (Oehmichen et al., 2009). It is known that mononuclear phagocytes constitute a heterogeneous population of cells rather than a single and homogeneous population because they play roles in both tissue regeneration/repair and self-regulation of the immune response. These specific roles are also reflected by time-specific recruitment to the injury site. Research have therefore proposed the use of as 5 different macrophage markers (HLA-D, CD68, LN-5, HAM-56, and 25F9) in combination to estimate the post-traumatic interval by comparing the expression of these markers at different time point (Figure 2). This method, which was elaborated in a pilot study and is applicable only in cases of cortical contusions with a large haemorrhagic component, however, was not subsequently validated in larger studies, and its diagnostic accuracy was not confirmed.

The findings of the different techniques, however, are not always in agreement, and expert opinion suggests that the use of the parameters studied thus far in daily practice can easily lead to gross diagnostic errors. Furthermore, these techniques often do not account for bi-modal trends in immunostaining for certain markers, such as GFAP; some authors have reported a delayed increase in astrocyte immunoreactivity a few days after trauma, as we mentioned previously (Figure 3).

According to the literature, the dating of traumatic brain injury constitutes is still a challenge in forensic practice. The studies and published data are limited to isolated autopsy series, almost exclusively retrospective series, and meta-analyses and systematic reviews are completely lacking.

The most substantial limitation to the evidence collected so far is the marked heterogeneity of the different autopsy series both in terms of number and sample characteristics and differences in histopathological methods. According to the literature, more than 20 immunohistochemical markers have been shown to have some correlation with a given time point after trauma. These markers recognize very different targets, including neurons, astrocytes, microglia, circulating cells of the immune system, and blood vessel walls.

Conclusions

To date, it is believed that the findings obtained by immunohistochemistry are more significant than those obtained by routine staining with haematoxylin and eosin. Immunohistochemical techniques are able to identify much narrower and more precise time intervals, on the order of minutes within the first 24-48 hours; additionally, instruments with greater objectivity, less inter-operator variability and less interpretation bias can be used.

In cases of traumatic brain death it is essential the contribution of post-mortem examination complemented by toxicological, microbiological and genetic investigations. The histological study of the brain with traditional histochemical techniques can provide relevant data since it is well known that depending on mechanism, severity and timing of the insult, the distribution and the histological pattern of lesions in the brain changes dramatically. By means of immunohistochemical techniques applied in studies both on animals and humans, it has been possible to identify in the brain tissue some markers of traumatic damage with reliable and reproducible results (Riezzo, 2010).

Nevertheless, an easy-to-use, reproducible, high-resolution method with known and sufficient accuracy for identifying time intervals on a large scale is not yet available. Based on the advancement of knowledge related to the pathophysiology of posttraumatic brain injury and, in particular, the mechanisms of associated neuroinflammation derived from cell lines and animal models, it is likely that the histochemical evaluation the expression of endothelial activation markers and adhesion molecules can be used for TBI dating. Thus, by evaluating the combination of these markers and direct markers of vessels used in previous studies, it may be possible to construct a timeline of the unique histological characteristics of the intraparenchymal vascular and capillary walls.

Figure legend

Figure 1 – (A) Light microscopy and IHC analyses of injured cerebral cortical layers: K48 stained cytoplasmic inclusions around the contusion site (black arrows, x80). (B) Reactive astrocytes with significant increase in GFAP immunopositivity (black arrow, x200).

Figure 2 – (A) TNF-α positivity (black arrows) 6 hours after trauma. **(B)** Within the intraparenchymal hemorrhage CD68+ activated macrophages are largely visible along with granulocytes and monocytes (13 hours after trauma in this case).

Figure 3 – (A) Reactive astrocytes produce more glial fibrillary acidic protein (GFAP) than normal (green reactions) and raise what is called a "glial barrier" (14 days after trauma). **(B)** IBA-1 reactions showing dendritic morphology (10 days after trauma in this case).

Declarations

Ethics approval and consent to participate

Not applicable.

Consent for publication

Not applicable.

Availability of data and materials

Data sharing is not applicable to the article as no datasets where generated or analysed during the current study.

Competing interests

The authors declare that they have no competing interests.

Funding

This research received no external funding.

Authors' contributions

Not applicable.

Acknowledgements

Not applicable.

References

Abdul-Muneer P.M., Chandra N. and Haorah J. (2015). Interactions of oxidative stress and neurovascular inflammation in the pathogenesis of traumatic brain injury. Mol. Neurobiol. 51, 966-979.

Balabanov R., Goldman H., Murphy S., Pellizon G., Owen C., Rafols J. and Dore-Duffy P. (2001). Endothelial cell activation following moderate traumatic brain injury. Neurol. Res. 23, 175-182.

Biagas K.V., Uhl M.W., Schiding J.K., Nemoto E.M. and Kochanek P.M. (1992). Assessment of posttraumatic polymorphonuclear leukocyte accumulation in rat brain using tissue myeloperoxidase assay and vinblastine treatment. J. Neurotrauma 9, 363-371.

Blumbergs P.C., Scott G., Manavis J., Wainwright H., Simpson D.A. and McLean A.J. (1995). Topography of axonal injury as defined by amyloid precursor protein and the sector scoring method in mild and severe closed head injury. J. Neurotrauma 12, 565-572.

Böhmer A.E., Oses J.P., Schmidt A.P., Perón C.S., Krebs C.L., Oppitz P.P., D'Avila T.T., Souza D.O., Portela L.V. and Stefani M.A. (2011). Neuron-specific enolase, S100B, and glial fibrillary acidic protein levels as outcome predictors in patients with severe traumatic brain injury. Neurosurgery 68, 1624-1630.

Bohnert S., Seiffert A., Trella S., Bohnert M., Distel L., Ondruschka B. and Monoranu C.M. (2020). TMEM119 as a specific marker of microglia reaction in traumatic brain injury in postmortem examination. Int. J. Legal Med. 134 2167-2176.

Chmieliauskas S., Anuzyte J.S., Liucvaikyte J., Laima S., Jurolaic E., Rocka S., Fomin D., Stasiuniene J. and Jasulaitis A. (2018). Importance of effusion of blood under the dura mater in forensic medicine: A STROBE - compliant retrospective study. Medicine 97, e12567.

Chodobski A., Zink B.J. and Szmydynger-Chodobska J. (2011). Blood-brain barrier pathophysiology in traumatic brain injury. Transl. Stroke Res. 2, 492-516.

Clark R.S., Schiding J.K., Kaczorowski S.L., Marion D.W. and Kochanek P.M. (1994). Neutrophil accumulation after traumatic brain injury in rats: comparison of weight drop and controlled cortical impact models. J. Neurotrauma 11, 499-506.

Correale J. and Villa A. (2007). The blood-brain-barrier in multiple sclerosis: functional roles and therapeutic targeting. Autoimmunity 40, 148-160.

Dettmeyer R.B. (2018). Forensic Histopathology – Fundamentals and Perspectives. 2nd ed. Springer Nature. Berlin.

DiMaio V.J.M. and Dana S.E. (2007). Handbook of forensic pathology. 3rd ed. Taylor & Francis. London.

Dressler J., Hanisch U., Kuhlisch E. and Geiger K.D. (2007). Neuronal and glial apoptosis in human traumatic brain injury. Int. J. Legal Med. 121, 365-375.

Fineschi V., Viola R.V., La Russa R., Santurro A. and Frati P. (2017). A controversial medicolegal issue: timing the onset of perinatal hypoxic-ischemic brain injury. Mediators Inflamm. 2017, 6024959.

Frati A., Cerretani D., Fiaschi A.I., Frati P., Gatto V., La Russa R., Pesce A., Pinchi E., Santurro A., Fraschetti F. and Fineschi V. (2017). Diffuse Axonal Injury and Oxidative Stress: A Comprehensive Review. Int. J. Mol. Sci. 18, 2600.

Freytag E. and Lindeberg R. (1957). Morphology of cortical contusions. A.M.A. Arch. Pathol. 63, 23-42.

Frugier T., Morganti-Kossmann M.C., O'Reilly D. and McLean C.A. (2010). In situ detection of inflammatory mediators in post mortem human brain tissue after traumatic injury. J. Neurotrauma 27, 497-507.

Hamberger A., Huang Y.L., Zhu H., Bao F., Ding M., Blennow K., Olsson A., Hansson H.A., Viano D. and Haglid K.G. (2003). Redistribution of neurofilaments and accumulation of beta-amyloid protein after brain injury by rotational acceleration of the head. J. Neurotrauma 20, 169-178.

Hausmann R., Kaiser A., Lang C., Bohnert M. and Betz P. (1999). A quantitative immunohistochemical study on the time-dependent course of acute inflammatory cellular response to human brain injury. Int. J. Legal Med. 112, 227-232.

Hausmann R. and Betz P. (2000a). The time course of the vascular response to human brain injury--an immunohistochemical study. Int. J. Legal Med. 113, 288-292.

Hausmann R., Riess R., Fieguth A. and Betz P. (2000b). Immunohistochemical investigations on the course of astroglial GFAP expression following human brain injury. Int. J. Legal Med. 113, 70-75.

Hausmann R. and Betz P. (2001). Course of glial immunoreactivity for vimentin, tenascin and alpha1-antichymotrypsin after traumatic injury to human brain. Int. J. Legal Med. 114, 338-342.

Hausmann R., Biermann T., Wiest I., Tübel J. and Betz P. (2004). Neuronal apoptosis following human brain injury. Int. J. Legal Med. 118, 32-36.

Hausmann R. (2006) Age determination of brain contusions. Forensic Sci. Med. Pathol. 2, 85-93.

Helmy A., Carpenter K.L., Menon D.K., Pickard J.D. and Hutchinson P.J. (2011). The cytokine response to human traumatic brain injury: temporal profiles and evidence for cerebral parenchymal production. J. Cereb. Blood Flow Metab. 31, 658-670.

Hortobágyi T., Wise S., Hunt N., Cary N., Djurovic V., Fegan-Earl A., Shorrock K., Rouse D. and Al-Sarraj S. (2007). Traumatic axonal damage in the brain can be detected using beta-APP immunohistochemistry within 35 min after head injury to human adults. Neuropathol. Appl. Neurobiol. 33, 226-237.

Israelsson C., Bengtsson H., Kylberg A., Kullander K., Lewén A., Hillered L. and Ebendal T. (2008). Distinct cellular patterns of upregulated chemokine expression supporting a prominent inflammatory role in traumatic brain injury. J. Neurotrauma 25, 959-974.

Jassam Y.N., Izzy S., Whalen M., McGavern D.B. and El Khoury J. (2017). Neuroimmunology of Traumatic Brain Injury: Time for a Paradigm Shift. Neuron. 95, 1246-1265.

Johnson V.E., Stewart W. and Smith D.H. (2013). Axonal pathology in traumatic brain injury. Exp. Neurol. 246, 35-43.

Johnston B. and Butcher E.C. (2002). Chemokines in rapid leukocyte adhesion triggering and migration. Semin. Immunol. 14, 83-92.

Kaur P. and Sharma S. (2018). Recent Advances in Pathophysiology of Traumatic Brain Injury. Curr. Neuropharmacol. 16, 1224-1238.

Kerfoot S.M. and Kubes P. (2002). Overlapping roles of P-selectin and alpha 4 integrin to recruit leukocytes to the central nervous system in experimental autoimmune encephalomyelitis. J. Immunol. 169, 1000-1006.

Kivisäkk P., Mahad D.J., Callahan M.K., Trebst C., Tucky B., Wei T., Wu L., Baekkevold E.S., Lassmann H., Staugaitis S.M., Campbell J.J. and Ransohoff R.M. (2003). Human cerebrospinal fluid central memory CD4+ T cells: evidence for trafficking through choroid plexus and meninges via P-selectin. Proc. Natl. Acad. Sci. U S A. 100, 8389-8394.

Kobek M., Skowronek R., Jankowski Z. and Pałasz A. (2014). Neurofilaments and traumatic brain injury. Arch. Med. Sadowej Kryminol. 64, 268-279.

Kobek M., Jankowski Z., Szala J., Gąszczyk-Ożarowski Z., Pałasz A. and Skowronek R. (2016). Time-related morphometric studies of neurofilaments in brain contusions. Folia Neuropathol. 54, 50-58.

Korn A., Golan H., Melamed I., Pascual-Marqui R. and Friedman A. (2005). Focal cortical dysfunction and blood-brain barrier disruption in patients with Postconcussion syndrome. J. Clin. Neurophysiol. 22, 1-9.

La Russa, R., Maiese, A., Di Fazio, N., Morano, A., Di Bonaventura, C., De Matteis, A., Fazio, V., Frati, P., and Fineschi, V. (2020). Post-Traumatic Meningitis Is a Diagnostic Challenging Time: A Systematic Review Focusing on Clinical and Pathological Features. Int. J. Mol. Sci. 21, 4148.

Li D.R., Zhang F., Wang Y., Tan X.H., Qiao D.F., Wang H.J., Michiue T. and Maeda H. (2012). Quantitative analysis of GFAP- and S100 protein-immunopositive astrocytes to investigate the severity of traumatic brain injury. Leg. Med. (Tokyo) 14, 84-92.

Li D.R., Zhu B.L., Ishikawa T., Zhao D., Michiue T. and Maeda H. (2006). Postmortem serum protein S100B levels with regard to the cause of death involving brain damage in medicolegal autopsy cases. Leg. Med. (Tokyo) 8, 71-77.

Liu M.C., Akle V., Zheng W., Dave J.R., Tortella F.C., Hayes R.L. and Wang K.K. (2006). Comparing calpain- and caspase-3-mediated degradation patterns in traumatic brain injury by differential proteome analysis. Biochem. J. 394, 715-725.

Lo E.H. (2010). Degeneration and repair in central nervous system disease. Nat. Med. 16, 1205-1209.

Man S., Tucky B., Bagheri N., Li X., Kochar R. and Ransohoff R.M. (2009). Alpha4 Integrin/FN-CS1 mediated leukocyte adhesion to brain microvascular endothelial cells under flow conditions. J. Neuroimmunol. 210, 92-99.

Michiue T., Ishikawa T., Quan L., Li D.R., Zhao D., Komatsu A., Zhu B.L. and Maeda H. (2008). Single-stranded DNA as an immunohistochemical marker of neuronal damage in human brain: an analysis of autopsy material with regard to the cause of death. Forensic Sci. Int. 178, 185-191.

Miller J.D. and Nader R. (2014). Acute subdural hematoma from bridging vein rupture: a potential mechanism for growth. J. Neurosurg. 120, 1378-1384.

Neri M., Frati A., Turillazzi E., Cantatore S., Cipolloni L., Di Paolo M., Frati P., La Russa R., Maiese A., Scopetti M., Santurro A., Sessa F., Zamparese R. and Fineschi V. (2018). Immunohistochemical evaluation of Aquaporin-4 and its correlation with CD68, IBA-1, HIF-1α, GFAP, and CD15 expressions in fatal traumatic brain injury. International Journal of Molecular Sciences 19, 3544.

Nishioku Matsumoto J., Dohgu S., Sumi N., Miyao K., Takata F., Shuto H., Yamauchi A. and Kataoka Y. (2010). Tumor necrosis factor-alpha mediates the blood-brain barrier dysfunct.ion induced by activated microglia in mouse brain microvascular endothelial cells. J. Pharmacol. Sci. 112, 251-254.

Oehmichen M., Eisenmenger W., Raff G. and Berghaus G. (1986). Brain macrophages in human cortical contusions as indicator of survival period. Forensic Sci. Int. 30, 281-301.

Oehmichen M., Walter T., Meissner C. and Friedrich H.J. (2003). Time course of cortical hemorrhages after closed traumatic brain injury: statistical analysis of posttraumatic histomorphological alterations. J. Neurotrauma 20, 87-103.

Oehmichen M, Jakob S, Mann S, Saternus KS, Pedal I and Meissner C (2009) Macrophage subsets in mechanical brain injury (MBI)--a contribution to timing of MBI based on immunohistochemical methods: a pilot study. Leg. Med. (Tokyo) 11, 118-124.

Olczak M., Niderla-Bielińska J., Kwiatkowska M., Samojłowicz D., Tarka S. and Wierzba-Bobrowicz T. (2017). Tau protein (MAPT) as a possible biochemical marker of traumatic brain injury in postmortem examination. Forensic Sci. Int. 280, 1-7.

Olczak M., Poniatowski Ł., Kwiatkowska M., Samojłowicz D., Tarka S. and Wierzba-Bobrowicz T. (2019). Immunolocalization of dynein, dynactin, and kinesin in the cerebral tissue as a possible supplemental diagnostic tool for traumatic brain injury in postmortem examination. Folia Neuropathol. 57, 51-62.

O'leary R.A. and Nichol A.D. (2018). Pathophysiology of severe traumatic brain injury. J. Neurosurg. Sci. 62, 542-548.

Oliver D., Killick S., Even T. and Willmott M. (2008). Do falls and falls-injuries in hospital indicate negligent care -- and how big is the risk? A retrospective analysis of the NHS Litigation Authority Database of clinical negligence claims, resulting from falls in hospitals in England 1995 to 2006. Qual. Saf. Health Care 17, 431-436.

Omalu B., Bailes J., Hamilton R.L., Kamboh M.I., Hammers J., Case M. and Fitzsimmons R. (2011). Emerging histomorphologic phenotypes of chronic traumatic encephalopathy in American athletes. Neurosurgery 69, 173-183.

Orihara Y. and Nakasono I. (2002). Induction of apolipoprotein E after traumatic brain injury in forensic autopsy cases. Int. J. Legal. Med. 116, 92-98.

Pinchi E., Frati A., Cipolloni L., Aromatario M., Gatto V., La Russa R., Pesce A., Santurro A., Fraschetti F., Frati P. and Fineschi V. (2018). Clinical-pathological study on β-APP, IL-1β, GFAP, NFL, Spectrin II, 8OHdG, TUNEL, miR-21, miR-16, miR-92 expressions to verify DAI-diagnosis, grade and prognosis. Sci. Rep. 8, 2387.

Riezzo I., Neri M., De Stefano F., Fulcheri E., Ventura F., Pomara C., Rabozzi R., Turillazzi E. and Fineschi V. (2010). The timing of perinatal hypoxia/ischemia events in term neonates: a retrospective autopsy study. HSPs, ORP-150 and COX2 are reliable markers to classify acute, perinatal events. Diagn. Pathol. 5, 49.

Rodríguez-Baeza A., Reina-de la Torre F., Poca A., Martí M. and Garnacho A. (2003). Morphological features in human cortical brain microvessels after head injury: a three-dimensional and immunocytochemical study. Anat. Rec. A Discov. Mol. Cell. Evol. Biol. 273, 583-593.

Romero Tirado M., Blanco Pampin J.M. and Gallego Gómez R. (2018). Dating of Traumatic Brain Injury in Forensic Cases Using Immunohistochemical Markers (I): Neurofilaments and β-Amyloid Precursor Protein. Am. J. Forensic Med. Pathol. 39, 201-207.

Ropper A.H., Samuels M.A., Klein J.P. and Prasad S. (2019). Adams and Victor's Principles of Neurology, 11th ed. Ropper A. H., Samuels M.A., Klein J.P. and Prasad S. McGraw-Hill Medical. New York.

Sakai K., Fukuda T. and Iwadate K. (2014). Immunohistochemical analysis of the ubiquitin proteasome system and autophagy lysosome system induced after traumatic intracranial injury: association with time between the injury and death. Am. J. Forensic Med. Pathol. 35, 38-44.

Semple B.D., Bye N., Rancan M., Ziebell J.M. and Morganti-Kossmann M.C. (2010). Role of CCL2 (MCP-1) in traumatic brain injury (TBI): evidence from severe TBI patients and CCL2-/- mice. J. Cereb. Blood Flow Metab. 30, 769-782.

Shi H., Hua X., Kong D., Stein D. and Hua F. (2019). Role of Toll-like receptor mediated signaling in traumatic brain injury. Neuropharmacol. 145, 259-267.

Sieber M.W., Claus R.A., Witte O.W. and Frahm C. (2011). Attenuated inflammatory response in aged mice brains following stroke. PLOS One 6, e26288.

Sieber M, Dreßler J, Franke H, Pohlers D and Ondruschka B (2018) Post-mortem biochemistry of NSE and S100B: A supplemental tool for detecting a lethal traumatic brain injury?. J. Forensic Leg. Med. 55, 65-73.

Smith D.H., Meaney D.F. and Shull W.H. (2003). Diffuse axonal injury in head trauma. J. Head Trauma Rehabil. 18, 307-316.

Soares H.D., Hicks R.R., Smith D. and McIntosh T.K. (1995). Inflammatory leukocytic recruitment and diffuse neuronal degeneration are separate pathological processes resulting from traumatic brain injury. The J. Neurosci. 15, 8223-8233.

Stein D.M., Feather C.B. and Napolitano L.M. (2017). Traumatic Brain Injury Advances. Crit. Care Clin. 33, 1-13.

Strassmann G. (1949). Formation of hemosiderin and hematoidin after traumatic and spontaneous cerebral hemorrhages. Arch. Pathol. (Chic) 47, 205-210.

Strbian D., Durukan A., Pitkonen M., Marinkovic I., Tatlisumak E., Pedrono E., Abo-Ramadan U. and Tatlisumak T. (2008). The blood-brain barrier is continuously open for several weeks following transient focal cerebral ischemia. Neuroscience 153, 175-181.

Suzuki S., Tanaka K. and Suzuki N. (2009). Ambivalent aspects of interleukin-6 in cerebral ischemia: inflammatory versus neurotrophic aspects. J. Cereb. Blood Flow Metab. 29, 464-479.

Takeshita Y. and Ransohoff R.M. (2012). Inflammatory cell trafficking across the blood-brain barrier: chemokine regulation and in vitro models. Immunol. Rev. 248, 228-239.

Thomas K.E., Stevens J.A., Sarmiento K. and Wald M.M. (2008). Fall-related traumatic brain injury deaths and hospitalizations among older adults--United States, 2005. J. Safety Res. 39, 269-272.

Tomkins O., Shelef I., Kaizerman I., Eliushin A., Afawi Z., Misk A., Gidon M., Cohen A., Zumsteg D. and Friedman A. (2008). Blood-brain barrier disruption in post-traumatic epilepsy. J. Neurol. Neurosurg. Psychiatry 79, 774-777.

Turowski P., Adamson P. and Greenwood J. (2005). Pharmacological targeting of ICAM-1 signaling in brain endothelial cells: potential for treating neuroinflammation. Cell. Mol. Neurobiol. 25, 153-170.

Walter T., Meissner C. and Oehmichen M. (2009). Pathomorphological staging of subdural hemorrhages: statistical analysis of posttraumatic histomorphological alterations. Leg. Med. (Tokyo) 11 Suppl 1, S56-S62.

Whalen M.J., Carlos T.M., Kochanek P.M., Clark R.S., Heineman S., Schiding J.K., Franicola D., Memarzadeh F., Lo W., Marion D.W. and Dekosky S.T. (1999). Neutrophils do not mediate blood-brain barrier permeability early after controlled cortical impact in rats. J. Neurotrauma 16, 583-594.

Williams A.J., Wei H.H., Dave J.R. and Tortella F.C. (2007). Acute and delayed neuroinflammatory response following experimental penetrating ballistic brain injury in the rat. J. Neuroinflammation 4, 17.

Wu Q., Luo C.L. and Tao L.Y. (2017). Dynamin-related protein 1 (Drp1) mediating mitophagy contributes to the pathophysiology of nervous system diseases and brain injury. Histol. Histopathol. 32, 551-559.

Yue L., Fang T., Lin Z., Longlong Z., Wenhe L., Weisheng H., Shuquan Z., Guanglong H. and Yiwu Z. (2019). iTRAQ-based proteomic analysis discovers potential biomarkers of diffuse axonal injury in rats. Brain Res. Bull. 153, 289-304.

Zaki M.K., Abdel Gawad S.M., Tolba N.H. and Abdel Rahman A.E.S. (2011). Correlation between timing of trauma in living individuals and plasma level of soluble intercellular adhesion molecule type-1 (sICAM-1). Egypt. J. Forensic Sci. 1, 87-92.

Zehendner C.M., Sebastiani A., Hugonnet A., Bischoff F., Luhmann H.J. and Thal S.C. (2015). Traumatic brain injury results in rapid pericyte loss followed by reactive pericytosis in the cerebral cortex. Sci. Rep. 5, 13497.

Zeng Y. and Deng S. (2005). Intercellular adhesion molecular-1 and its response to the injury of organs and tissues. Chin. J. Forensic Med. 20, 350-352.

Ziebell J.M. and Morganti-Kossmann M.C. (2010). Involvement of pro- and anti-inflammatory cytokines and chemokines in the pathophysiology of traumatic brain injury. Neurotherapeutics 7, 22-30.

Table 1 - Summary of the studies evaluated on immunoistochemical assays for age estimation of traumatic brain injury.

First Author	Publication year	Antibody target	Time by TBI
Hausmann et al.,	1999	CD-15 LCA CD-3 UCHL-1	10 minutes 1 day 2 days 3-4 days
Hausmann et al.,	2000	GFAP	1 day
Li DR et al.,	2012	GFAP	--
Hausmann et al.,	2001	ACT Vimentin Tenascin	3 hours 22 hours 7 days
Hausmann et al.,	2000	Factor VIII	3 hours
Hausmann	2006	Ki-67	3 days and 7-14 days
Orihara et al.,	2002	Apo-E	2 hours
Oehmichen et al.,	2009	CD-68 HLA-D LN-5 HAM-56	3 hours 6 hours 48 hours 48 hours
Dressler et al.,	2007	Caspase-3 TUNEL	1 hour (neuronal); 5 hour (glial) 2 hours
Michiue et al.,	2008	Ubiquitin-Proteasome complex	1 hour
Blumbergs et al.,	1995	APP	105 minutes
Hortobágyi et al.,	2007	Beta-APP	35 minutes
Kobek et al.,	2016	Neurofilaments	--
Yue Lianga et al.,	2019	Peripherin, calsenilin	--
Bohnert S. et al.,	2020	$TMEM_{119}$	--

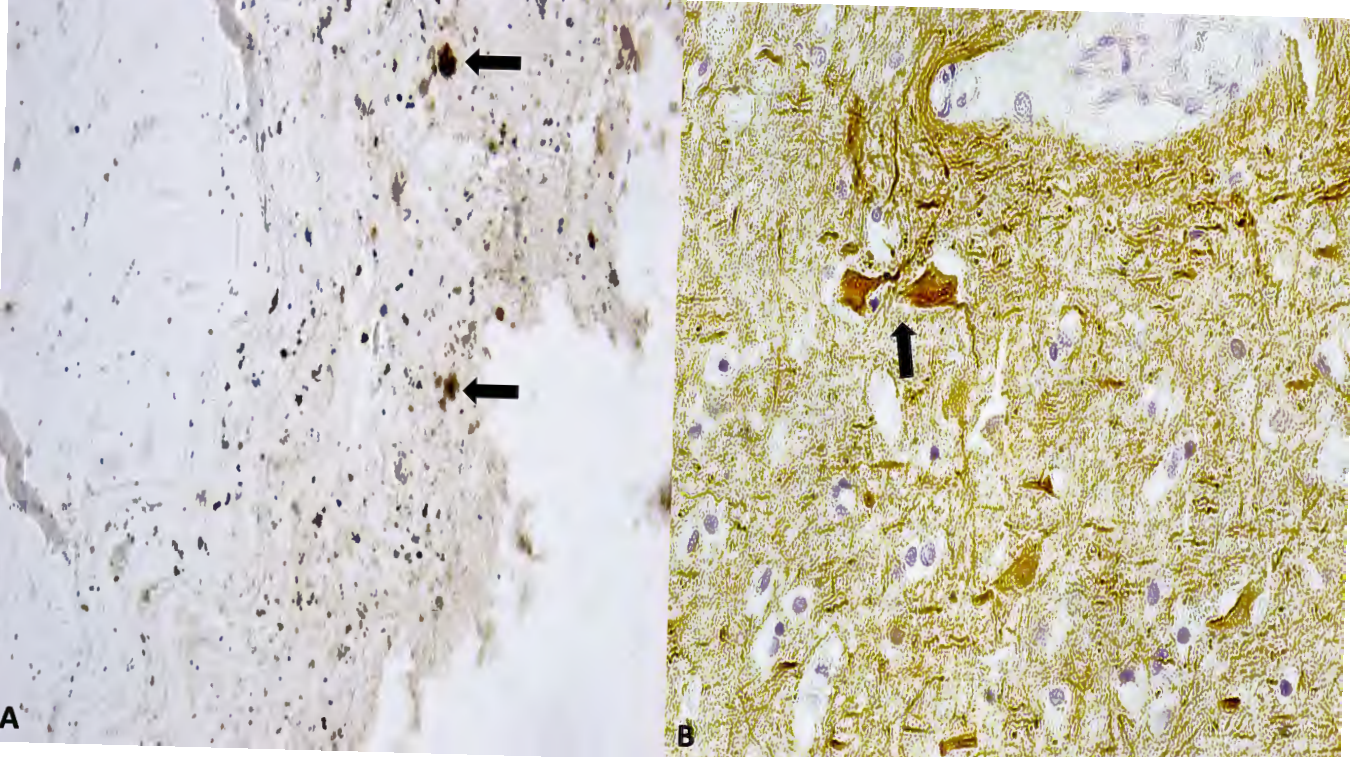
A
B

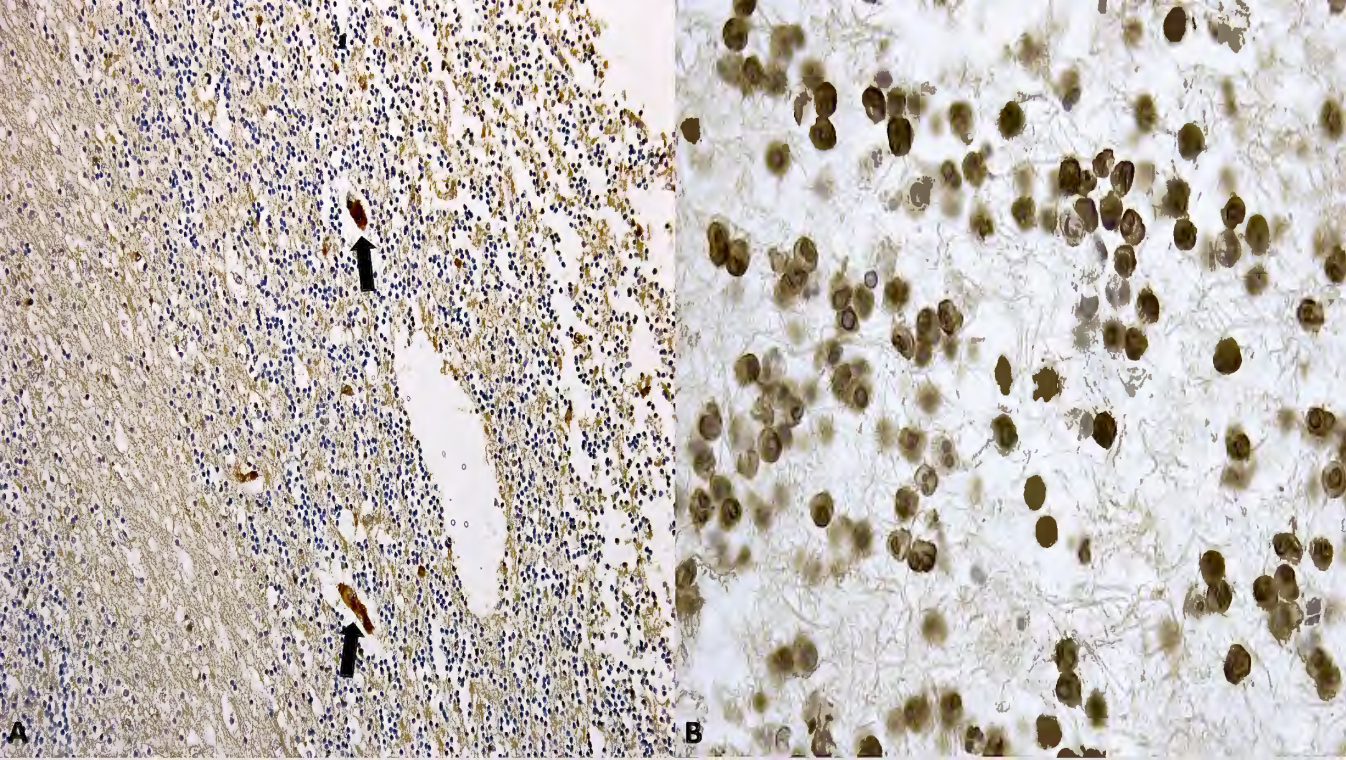
A
B

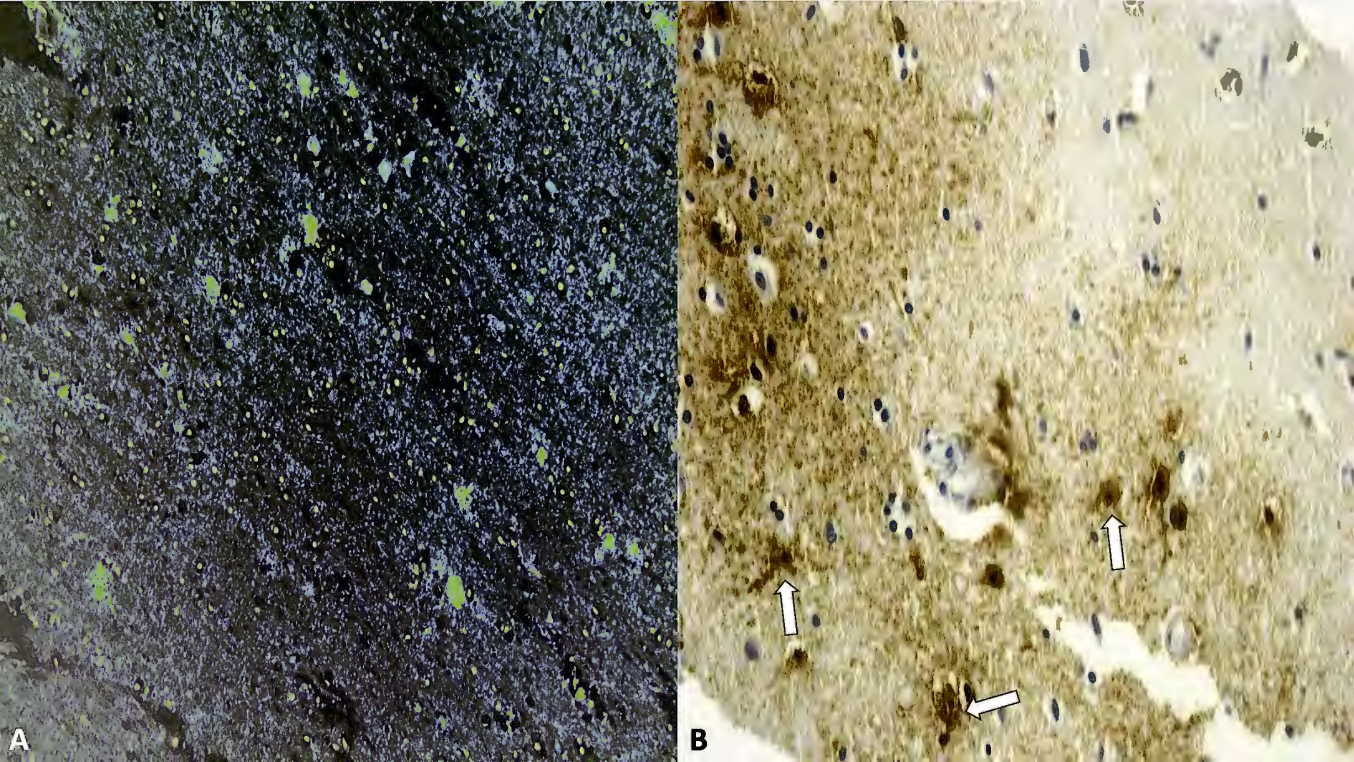
A
B