

# ISL-1: a new potential marker of stem/progenitor cells in the developing human uterus

Flaviana Cau<sup>1</sup>, Maria Carolina Botta<sup>1</sup>, Laura Vinci<sup>2</sup>, Clara Gerosa<sup>2</sup>, Ester Sorrentino<sup>3</sup>, Giancarlo Senes<sup>2</sup>, Flaminia Bardanzellu<sup>4</sup>, Sara Aversa<sup>3</sup>, Francesco Ronchi<sup>1</sup>, Cristiana Bellan<sup>3</sup>, Gavino Faa<sup>2</sup>

<sup>1</sup>Pathological Anatomy and Clinical Pathology, Ospedale N. Signora di Bonaria, ATS, ASSL San Gavino, Italy

<sup>2</sup>Division of Pathology, University Hospital San Giovanni di Dio, University of Cagliari, Cagliari, Italy

<sup>3</sup>Pathological Anatomy, Santa Maria alle Scotte, University of Siena, Siena, Italy

<sup>4</sup>Neonatal Intensive Care Unit, Neonatal Pathology and Neonatal Section, AOU and University of Cagliari, Cagliari, Italy

## Abstract

The human uterus is a highly dynamic organ with peculiar plasticity and marked reproductive ability, due to the presence of a vast number of multiple stem/progenitor cell types, including endometrial, stromal and vascular progenitor cells. Conflicting results have been published regarding which uterine population might represent the real stem/progenitor cell fraction in terms of *in vivo* stem cell activity. Human endometrial side population (ESP) cells were shown to differentiate into multiple endometrial lineages in the stem cell niche provided by whole endometrial cells, suggesting that ESP cells might represent the most important stem/progenitor cells responsible of the cyclical regeneration of the endometrium throughout a woman's reproductive life. This study was aimed at analyzing the localization, composition, and occurrence of stem cell niches in the human fetal uterus at different stages of development. To this end, the whole uterus was obtained at autopsy by 12 human fetuses and newborns, ranging in gestational age from 12 up to 39 weeks of gestation. Tissue paraffin sections were immunostained with antibodies against insulin gene enhancer protein (ISL-1), a transcription factor previously utilized as a marker of stem/progenitor cells in the pancreas, heart and nervous system. Reactivity for ISL-1 was detected in both epithelial and stromal uterine precursors, at all gestational ages, allowing the detection of uterine progenitor cells. The loss of reactivity for ISL-1 in some stromal cell precursors was interpreted as a sign of differentiation. These preliminary data indicate ISL-1 as a useful marker for the detection of stem/progenitor cells in the human fetal endometrium. Further studies are needed to verify the utility of ISL-1 as a marker of stem/progenitor cells in the adult endometrium.

## Keywords

Endometrial stem cells, ISL-1, fetal endometrium, endometrial stem cell niche, stromal endometrial progenitors.

## Corresponding author

Flaviana Cau, Pathological Anatomy and Clinical Pathology, Ospedale N. Signora di Bonaria, ATS, ASSL San Gavino, Italy; tel.: 0390706092370; fax: 0390702115; email: flacau@tiscali.it.

## How to cite

Cau F, Botta MC, Vinci L, Gerosa C, Sorrentino E, Senes G, Bardanzellu F, Aversa S, Ronchi F, Bellan C, Faa G. ISL-1: a new potential marker of stem/progenitor cells in the developing human uterus. *J Pediatr Neonat Individual Med.* 2019;8(2):e080203. doi: 10.7363/080203.

## Introduction

The hypothesis that stem/progenitor cells might be detected in the human endometrium was first advanced in the late Seventies [1]. Endometrial stem cells were first localized in the basalis of the endometrium [2] and, subsequently, they were isolated at the bottom of each endometrial gland [3]. Further studies confirmed the existence of rare clonogenic epithelial and stromal stem cells with high proliferative potential in the human endometrium of adult women [4], both in cycling and inactive phases [5]. In recent years, endometrial stem cells have been subdivided into three pools: i) mesenchymal stem-like cells, characterized by reactivity for CD146; ii) epithelial endometrial progenitor cells, localized in the basalis of endometrial glands; iii) endometrial endothelial progenitors, characterized by the ability to differentiate into the endometrial epithelium, the endometrial stroma and into endothelial cells [6, 7]. Uterine stem/progenitor cells residing both in the endometrium and myometrium have been hypothesized to play a relevant role both during uterine development and in the insurgence of leiomyomas [8], endometrial cancer and endometriosis [9, 10]. In the few studies carried out on stem/progenitors in the human fetal endometrium, multipotential progenitor cells were reported to show a distribution similar to that type of basal/reserve cells [11].

At immunohistochemistry, the endometrial progenitor cells are characterized by the expression of CD9, CD29, CD41a, CD44, CD59, CD73,

CD90, and CD105 [12]. Co-expression of CD146 and platelet-derived growth factor receptor beta (PDGF-R-beta) has been reported to characterize a small population of endometrial stem cells with mesenchymal properties [13]. Mesenchymal uterine stromal cells are immunoreactive for CD29, CD44, CD73, CD105, CD140b, and CD146 [14]. Recently, alkaline phosphatase has been suggested as a possible useful marker for the identification of pluripotent stem cells, as well as related precursor cells, in multiple human tissues, including endometrium [15].

All these data taken together, the human uterus appears as a highly dynamic organ with peculiar plasticity and marked reproductive ability, due to the presence of a huge number of multiple stem/progenitor cell types, including endometrial, stromal and vascular progenitor cells [7]. This study was aimed at analyzing the localization, composition, and occurrence of stem cell niches in the human fetal uterus at different stages of development, utilizing the immunoreactivity of uterine stem cells for insulin gene enhancer protein (ISL-1), also called ISLET1, the protein encoded by the ISL LIM homeobox 1 gene. ISL-1 is a transcription factor that binds to the enhancer region of the insulin gene, by regulating insulin gene expression. It has been shown that ISL-1 plays an important role in the development of several organs, including the heart, the nervous system and the pancreas [16]. Recently, the expression of ISL-1 has been reported in the peri-cloacal mesenchyme and the urethral septum, suggesting a role for ISL-1 as a gene susceptible to bladder exstrophy. Based on these data, given the absence of any ISL-1 expression in the genital system, this study aimed to verify the ISL-1 expression in the developing human uterus at different gestational age.

## Patients and methods

For this work, all the procedures performed were approved by the Ethics Human Studies Committee of the University Medical Center of Cagliari (according to the instructions of the Helsinki Declaration).

Twelve female fetuses and newborns, of gestational age ranging from 12 up to 39 weeks were analyzed in this study. The primary clinical data are reported in **Tab. 1**. In each fetus and newborn, at autopsy, the whole uterus was subdivided into two parts, fixed in 10% formalin, routinely processed and included in paraffin. Five-micron-thick tissue

**Table 1.** Clinical data of the 12 female fetuses and newborns, of gestational age ranging from 12 up to 39 weeks, analyzed in this study.

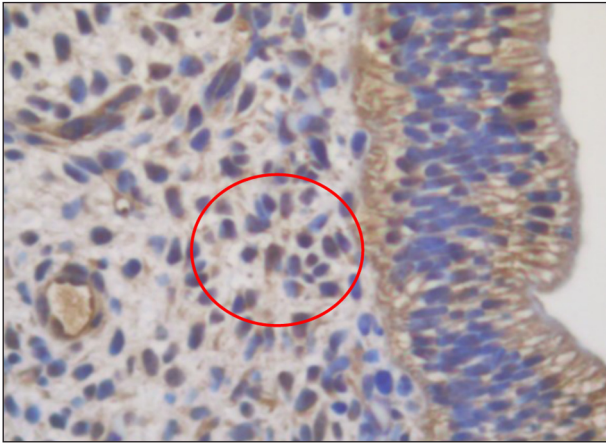
Case no.	Gestational age (weeks)	Postnatal age (days)	Body weight (g)	Macroscopy	Cause of death
1	12	-	13	Normoconformed	Voluntary interruption of gestation
2	18 <sup>+5</sup>	-	300	Normoconformed	Therapeutic abortion
3	19	-	320	Normoconformed	Endouterine death
4	20	-	474	Normoconformed Macerated fetus	Endouterine death
5	21	-	270	Normoconformed the upper limbs, the abdomen and the skull Lower limb alterations Bilateral wrong foot	Voluntary interruption of gestation
6	22	-	400	Normoconformed	Endouterine death
7	26 <sup>+5</sup>	-	1,410	Normoconformed	Endouterine death
8	30	-	1,121	Normoconformed	Endouterine death, acute asphyxia
9	34	42 hours	2,100	Normoconformed	Listeriosis
10	38 <sup>+2</sup>	-	2,220	Normoconformed	Endouterine death
11	39	5	3,400	Normoconformed	Sepsis
12	29	8	892	Normoconformed	Congenital cardiopathy

sections were stained with H&E for histology and immunostained with antibodies against ISL-1 (Thermo scientific, ISLET1 antibody, Catalog Number PA5-27789, Polyclonal Antibody rabbit/IgG). For ISL-1 immunostaining, the U UltraView DAB (Ventana Medical System) protocol was used. In brief, paraffin sections were incubated for 30 minutes at 36°C with the anti-ISL-1 antibody diluted 1:300. Procedures for the use of antibodies ISLET1 have been performed following the retailer's instructions,

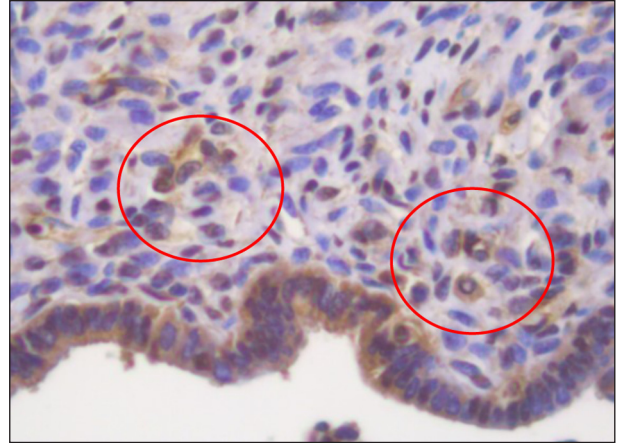
## Results

Immunoreactivity for ISL-1 was observed in the endometrium in all the cases analyzed in the superficial epithelium, as well as in stromal cell precursors. Reactivity for ISL-1 was detected both in the cytoplasm and in the nucleus, in the epithelial and stromal components of the developing uterus. The intensity of the immunoreactivity changed significantly from one case to the next. In some cases, the expression of ISL-1 appeared strong and widespread, whereas in others it was mild and focal. The highest levels of positivity for ISL-1 were observed in the superficial developing epithelial cells, from the early weeks of gestation to the postnatal age, in the absence of a strict correlation with gestational age (**Fig. 1** and **Fig. 2**). Reactivity for ISL-1 in the epithelial uterine precursors was observed at cell membrane level

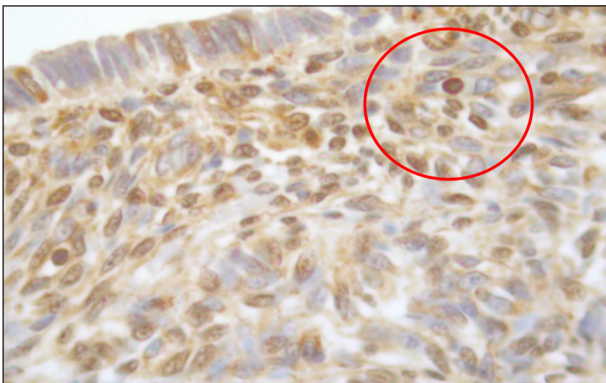
as well as in the cytoplasm. On the contrary, in the stromal cells, ISL-1 was mainly expressed in the nuclei. A marked interindividual variability was found regarding nuclear ISL-1 immunostaining in stromal developing cells: in some cases, particularly in young fetuses (see **Fig. 1**), ISL-1 was expressed in the nuclei of the vast majority of stromal cells, whereas in others, particularly in newborns (see **Fig. 2**), nuclear reactivity for ISL-1 was restricted to a minority of stromal precursor cells. Immunoreactivity for ISL-1, when considering the stromal component, appeared to decrease during gestation. Moreover, in the developing endometrial stroma, we frequently found small nests of ISL-1-reactive stromal cells (**Fig. 1** and **Fig. 2**), suggesting the existence of stem cell niches in multiple zones of the developing endometrium, mainly localized in the sub-epithelial zones. In particular, nests of ISL-1-positive cells, highly suggestive for stem cell niches, were detected in the following zones: a) in the superficial endometrial epithelium; b) in the epithelial invaginations originating the glandular epithelium; c) in the superficial stroma; d) in the deep endometrial stroma, in proximity to the progenitors of the myometrium. In other fields, isolated ISL-1-positive small undifferentiated cells, putatively representing stromal endometrial precursors, appeared surrounded by ISL-1-negative large cells, probably representing accessory cells of the stem cell niche (see **Fig. 3**). Scattered among the ISL-1-reactive stromal cells, we occasionally observed



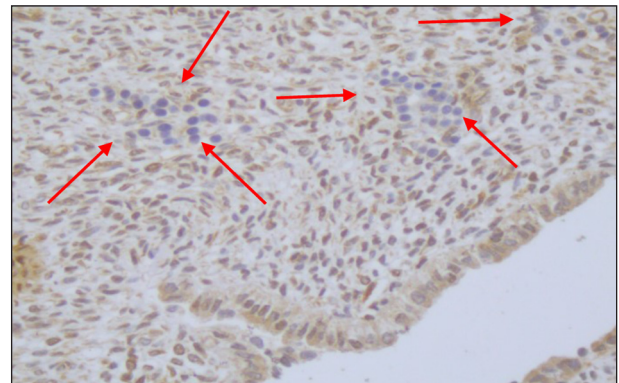
**Figure 1.** Fetal uterus, 12 weeks of gestation. Immunostaining for ISL-1 is observed in the superficial epithelial cells and in stromal progenitors. In the former, ISL-1 is mainly localized in the cell membrane; in the latter, expression of ISL-1 is mainly found in the nucleus. Original magnification X63.



**Figure 2.** Neonatal uterus, 42 hours of postnatal life. ISL-1 is expressed in the majority of superficial epithelial cells, both in the cytoplasm and in the nucleus, and the nucleus of a minority of endometrial stromal cells. Original magnification X63.



**Figure 3.** Neonatal uterus, 5 days of postnatal life. Cytoplasmic immunoreactivity for ISL-1 is detected in a few scattered superficial epithelial cells. Nuclear reactivity is observed in a minority of stromal cells. Isolated ISL-1-positive stromal cells are surrounded by ISL-1-negative cells, putatively representing a stem cell niche. Original magnification X63.



**Figure 4.** Neonatal uterus, 8 days of postnatal life. In the uterine stroma, some clusters of ISL-1-negative cells, probably representing differentiating stromal cells, are observed. Original magnification X20.

islands of cells characterized by the absence of any cytoplasmic or nuclear reactivity for ISL-1, mainly localized in the deeper endometrial stroma (Fig. 4). The loss of ISL-1 might represent an advanced degree of stromal differentiation, characterized by the loss of stability, underlining the usefulness of the ISL-1 immunostaining in highlighting the different stages of maturation of fetal endometrial progenitors.

## Discussion

In recent years, the identification of human endometrial stem cells has been a challenge for

researchers involved in regenerative medicine projects [17]. The endometrium represents an example of physiological regeneration going on during adulthood, having to be renewed at the end of each menstrual cycle [18]. Given that, on a morphological basis, the identification of endometrial stem cells has proved to be very complicated, if not impossible, the search for cellular markers highlighted with immunohistochemical methods has been the basis of numerous research projects, all focused towards a single objective: to define molecular markers of endometrial stem/progenitor cells. Unlike other research projects focused on the detection of



stem cells in the endometrium of adult women, we preferred to study human endometrium during the initial phases of its development in the intrauterine life, with the hope that, in the early phases of endometrial development, we could find a higher number of endometrial progenitor cells to characterize.

The first preliminary results of our study confirm, first of all, the diversity of the progenitor cells of the various human organs and tissues, confirming the non-existence of general markers of “staminality”. This means that, in the approach to the search for stem/progenitor cells present in any organ, if it is necessary to rely on previous studies on stem cell markers in other organs or the same organ of other species, we will have to prepare for a few confirmations and a higher number of unexpected novelties. The markers used in this study were chosen based on literature data, which highlighted ISL-1 as a stem/progenitor/multipotent cell marker in other organs, including pancreas [19] and heart [20]. ISL-1 was selected from a panel of staminal markers, also based on preliminary analyses on fetal or neonatal human endometrium. Other antibodies proposed in the literature as endometrial stem cell markers, including CD90, CD146, CD117 and CD34 [21], were also tested in the preliminary phases of this study, without obtaining encouraging results.

By the data here reported, ISL-1 appears as a new potential handy marker in highlighting the stem/progenitor elements in the endometrium in the intrauterine life. The expression of this marker was mainly found at the nuclear level, allowing to identify the large part of the progenitor cells present in the fetal and neonatal human endometrium. In the superficial epithelium, ISL-1 was expressed not only at the nuclear level, but also at the cell membrane and, in a small percentage of epithelial cells, also inside the cytoplasm.

This is an essential first result of our study: to have identified a new marker, ISL-1, useful for the identification of stem cells/progenitors of human endometrium, both in the early stages of uterine development, starting from the 12<sup>th</sup> week of gestation, as well as in the most advanced stages of gestation, and after birth. Further immunohistochemical investigations, using the anti-ISL-1 antibody, are needed to verify if the expression of this marker is maintained by endometrial stem/progenitor cells even in adulthood. In this case, ISL-1 could be included in the panel of antibodies useful for histopathological

observation of the human endometrium and would allow an assessment of the extent of the stem cell compartment in the biopsies of the endometrium of adult women, both in physiology and disease.

Another possible line of research emerging from our data is the possible expression of ISL-1 in the neoplasms originating from the different cellular components of the endometrium, including adenocarcinoma and stromal tumors [22]. In recent years, research into stem cells has become increasingly important in the characterization of many neoplasms, given the ability of cancer stem cells to be resistant to antineoplastic therapies. Given that many cancer stem cells are characterized by the recovery of cellular programs used during fetal development [23], we may hypothesize that ISL-1 expression might be reactivated during endometrial carcinogenesis [24]. Given that menstruation in the newborn has been recently identified as a relatively frequent event, particularly in preterms, it would be interesting to analyze LIM1 expression and stem niche localization in association with neonatal menstruation [25].

An intriguing finding emerging from our study is the expression of ISL-1 in multiple compartments of the fetal endometrium. In fact, ISL-1-positive cells were found at different levels of the fetal endometrium: a) in the thickness of the superficial endometrial epithelium; b) in the epithelial invaginations from which the glandular epithelium of the uterus originates; c) in the superficial stroma, in close proximity to the basal lamina of the superficial epithelium; d) in the deepest areas of the endometrial stroma, in proximity to the mesenchymal cells with muscle differentiation. The finding of ISL-1 expression in multiple compartments of the developing endometrium may lead to hypothesize that even in the endometrium multiple stem cell niches might exist, as previously reported in the human kidney [26]. The picture emerging from our study, regarding the localization of stem cell niches in the developing human endometrium, is entirely different from that described in the adult endometrium. In adult women, stem cell niches are localized in the basal stratum of the endometrium, particularly in the perivascular zone, from which they migrate towards the functional stratum. Here they differentiate into epithelial-stromal and endothelial cells, rebuilding the endometrium after menstruation [6]. Another difference between fetal and adult endometrial stem cell niches is their connection with vessels. Whereas adult stem cell niches are often localized

around vascular structures, in our study vessels were not associated with fetal endometrial stem cell niches. The multiple endometrial stem cell niches detected in this study in multiple epithelial and stromal compartments might have different differentiating purposes. While the niches present inside the superficial and glandular epithelium could have the task of regulating the development and regeneration of the endometrial epithelium, the stem niches of the straight have the task of regulating the development, differentiation, and regeneration of stromal cells. The hypothesis of the existence of multiple niches of endometrial stem cells needs further confirmation through the use of other immunohistochemical markers that, in future studies, will allow characterization and differentiation of the different endometrial niches between them, both in the human fetal endometrium and in the adult one.

Inside the endometrial stem cell niches, we observed a marked heterogeneity regarding ISL-1 expression. ISL-1-positive cells appeared intercalated with ISL-1-negative cells, confirming the previously described complexity of any stem cell niche, in which accessory cells, with “nurse” function, play a relevant role in the protection of stem/progenitor cells from endogenous or external harmful agents. Moreover, a strong interindividual variability was detected regarding immunoreactivity for ISL-1, even among fetuses with the same gestational age.

The reactivity of the progenitor cells of the uterus for ISL-1, described in this study, represents a connecting element with the progenitor cells of the endocrine pancreas, characterized by the marked expression of ISL-1 [19]. The meaning of this common expression of ISL-1 has not been, at the best of our knowledge, clarified yet. Our study clearly states that ISL-1, previously considered as a marker of pancreatic progenitor cells, should no longer be defined as an organ marker, but merely a marker of stem/progenitor cells. This hypothesis was recently confirmed by numerous authors, who demonstrated that the expression of ISL-1 would play an essential role in the differentiation of multipotent cardiac mesenchymal cells in cardiomyocytes, during cardiac organogenesis [20].

In conclusion, our data indicate ISL-1 as a useful marker for the identification of endometrial stem/progenitor cells during fetal life. Further studies will clarify the usefulness of this marker in the identification of stem cells in the adult

endometrium, particularly in pathological diseases including endometriosis, in epithelial and stromal endometrial tumors.

## Acknowledgements

The Authors want to thank Dr. A. Murru, from the Department of Pathology of the University of Cagliari, and Dr. S. Bartolomei, Dr. C. Cardone, Dr. I. Monciatti and Dr. R. Alfano from the Department of Pathology of the University of Siena, Hospital Santa Maria alle Scotte, for their valuable critical suggestions.

## Declaration of interest

The Authors declare that there is no conflict of interest.

## References

1. Prianishnikov VA. On the concept of stem cell and a model of the functional-morphological structure of the endometrium. *Contraception*. 1978;18:213-23.
2. Padykula HA, Coles LG, Okulicz WC, Rapaport SI, McCracken JA, King NW Jr, Longcope C, Kaiserman-Abramoff IR. The basis of the primate endometrium: a bifunctional germinal compartment. *Biol Reprod*. 1989;40(3):681-90.
3. Tanaka M, Kyo S, Kanaya T, Yatabe N, Nakamura M, Maida Y, Okabe M, Inoue M. Evidence of the monoclonal composition of human endometrial epithelial glands and mosaic pattern of clonal distribution in luminal epithelium. *Am J Pathol*. 2003;163(1):295-301.
4. Chan RW, Schwab KE, Gargett CE. Clonogenicity of human endometrial epithelial and stromal cells. *Biol Reprod*. 2004;70(6):1738-50.
5. Schwab KE, Chan RW, Gargett CE. Putative stem cells activity of human endometrial epithelial and stromal cells during the menstrual cycle. *Fertil Steril*. 2005;84(Suppl 2):1124-30.
6. Gargett CE, Masuda H. Adult stem cells in the endometrium. *Mol Hum Reprod*. 2010;16(11):818-34.
7. Gargett CE, Schwab KE, Deane JA. Endometrial stem/progenitor cells: the first 10 years. *Hum Reprod Update*. 2016;22(2):137-63.
8. Ono M, Bulum SE, Maruyama T. Tissue-specific stem cells in the myometrium and tumor-initiating cells in leiomyoma. *Biol Reprod*. 2014;91(6):149.
9. Sasson IE, Taylor HS. Stem cells and the pathogenesis of endometriosis. *Ann N Y Acad Sci*. 2008;1127:106-15.
10. Teixeira J, Rueda BR, Pru JK. Uterine stem cells. In: *StemBook*. Cambridge (MA): Harvard Stem Cell Institute, 2008.
11. O'Connell JT, Mutter GL, Cviko A, Nucci M, Quade BJ, Kozakewich HP, Neffen E, Sun D, Yang A, McKeon FD, Crum CP. Identification of a basal/reserve cell immunophenotype in benign and neoplastic endometrium: a study with p53 homolog p63. *Gynecol Oncol*. 2001;80(1):30-6.

12. Meng X, Ichim TE, Zhong J, Rogers A, Yin Z, Jackson J, Wang H, Ge W, Bogin V, Chan KW, Thébaud B, Riordan NH. Endometrial regenerative cells: a novel stem cell population. *J Transl Med.* 2007;15(5):57.
13. Schwab KE, Gargett CE. Co-expression of two perivascular cell markers isolates mesenchymal stem-like cells from human endometrium. *Hum Reprod.* 2007;22(11):2903-11.
14. Ulrich D, Tan KS, Deane J, Schwab K, Cheong A, Rosamilia A, Gargett CE. Mesenchymal stem/stromal cells in post-menopausal endometrium. *Hum Reprod.* 2014;29(9):1895-905.
15. Štefková K, Procházková J, Pacherník J. Alkaline phosphatase in stem cells. *Stem Cells Int.* 2015;2015:628368.
16. Yamamizu K, Sharov AA, Piao Y, Amano M, Yu H, Nishiyama A, Dudekula DB, Schlessinger D, Ko MS. Generation and gene expression profiling of 48 transcription-factor-inducible mouse embryonic stem cell lines. *Sci Rep.* 2016;6:25667.
17. Gargett CE. Review article: stem cells in human reproduction. *Reprod Sci.* 2007;14(5):405-24.
18. Jiang YS, Zhu HY, Jin XY, Li C, Li J, Zhang YL, Zhang SY. Co-culture with endometrial stromal cells promotes the differentiation of menstrual blood-derived mesenchymal stem cells into endometrial epithelial cells. *Zhonghua Yi Xue Za Zhi.* 2017;97(33):2614-19.
19. Eberhardt M, Salmon P, von Mach MA, Hengstler JG, Brulport M, Linscheid P, Seboek D, Oberholzer J, Barbero A, Martin I, Müller B, Trono D, Zulewski H. Multipotential nestin and ISL-1 positive mesenchymal stem cells isolated from human pancreatic islets. *Biochim Biophys Res Commun.* 2006;345(3):1167-76.
20. Yang Wang, Yuejiao Li, Chen Guo, Qin Lu, Weiping Wang, Zhuqing Jia, Ping Chen, Kangtao Ma, Danny Reinberg, Chunyan Zhou. ISL1 and JMJD3 synergistically control cardiac differentiation of embryonic stem cells. *Nucleic Acids Res.* 2016;44(14):6741-55.
21. Cervelló I, Simón C. Somatic stem cells in the endometrium. *Reprod Sci.* 2009;16(2):200-5.
22. Sun Y, Yoshida T, Okabe M, Zhou K, Wang F, Soko C, Saito S, Nikaido T. Isolation of Stem-Like Cancer Cells in Primary Endometrial Cancer Using Cell Surface Markers CD133 and CXCR4. *Transl Oncol.* 2017;10(6):976-87.
23. Faa G, Nemolato S, Cabras T, Fanni D, Gerosa C, Fanari M, Locci A, Fanos V, Messana I, Castagnola M. Thymosin  $\beta$ 4 expression reveals intriguing similarities between fetal and cancer cells. *Ann N Y Acad Sci.* 2012;1269:53-60.
24. Kong FF, Li D, Yang H, Ma J, Pan X, Liu HX, Huo JN, Ma XX. Preliminary identification of endometrial cancer stem cells in vitro and in vivo. *Biochem Biophys Res Commun.* 2017;490(2):506-13.
25. Bianchi P, Benagiano G, Brosens. Promoting awareness of neonatal menstruation. *Gynecol Endocrinol.* 2017;33(3):173-8.
26. Gerosa C, Fanos V, Puddu M, Ottonello G, Faa G, Pinna B, Van Eyken P, Fanni D. Not all renal stem cell niches are the same: anatomy of an evolution. *J Pediatr Neonat Individual Med.* 2016;5(2):e050225.