

Cone-beam computed tomographic analysis on root and canal morphology of mandibular first permanent molar among multiracial population in Western European population

Gianluca Gambarini¹, Lucila Piasecki², Priscilla Ropini¹, Gabriele Miccoli¹,
Dario Di Nardo¹, Luca Testarelli¹

Correspondence: Dr. Dario Di Nardo
Email: dario.dinardo@uniroma1.it

¹Department of Oral and Maxillofacial Sciences,
Sapienza University of Rome, Rome, Italy,

²Department of Periodontics and Endodontics,
University at Buffalo, Buffalo, NY, USA

ABSTRACT

Objectives: In the present study, confluent canals in the mandibular first molar's mesial root were investigated in an Italian population by means of cone-beam computed tomography (CBCT). **Materials and Methods:** A total of 200 molars, selected from the CBCT examinations of 130 patients who required this type of X-ray study as part of their dental treatment, were examined. The evaluated parameters were number of canals, root canal system configuration, presence of apical confluences, distance between confluences and apical foramina, which canal had a higher degree of curvature, and symmetry between left and right elements in the same individual. **Statistical Analysis Used:** Percentages of the cases were reported. **Results:** All the examined roots presented two canals. In 59% of cases, a Vertucci Type IV canal configuration was observed, while in 41% of cases, a Type II configuration was observed. Apical confluences were present in 41% of cases. The average distance between confluences and apical foramina was 2.85 mm. When confluences were present, the mesiobuccal canal showed a higher degree of curvature in 78% of cases. Symmetry in Vertucci configuration was seen in 88% of cases. **Conclusions:** Apical confluences in the mesial roots of mandibular molar can be present in a significantly high number of cases, and their recognition is essential to prevent the iatrogenic errors during canal instrumentation.

Key words: Anatomy, cone-beam computed tomography, endodontics, root canal treatment

INTRODUCTION

Lack of recognition of the anatomical complexities is one of the main causes of clinical failure in the root canal treatments.^[1] Recent and more detailed three-dimensional radiographic examinations are gaining crescent popularity due to possibility of understanding the anatomy of root canal system in advance. The methods

used for studying endodontic anatomy can be divided into *ex vivo*, performed on extracted teeth, and *in vivo*, performed directly on patients.

This is an open access journal, and articles are distributed under the terms of the Creative Commons Attribution-NonCommercial-ShareAlike 4.0 License, which allows others to remix, tweak, and build upon the work non-commercially, as long as appropriate credit is given and the new creations are licensed under the identical terms.

For reprints contact: reprints@medknow.com

Access this article online	
Quick Response Code: 	Website: www.eurjdent.com

How to cite this article: Gambarini G, Piasecki L, Ropini P, Miccoli G, Di Nardo D, Testarelli L. Cone-beam computed tomographic analysis on root and canal morphology of mandibular first permanent molar among multiracial population in Western European population. *Eur J Dent* 2018;12:434-8.

DOI: 10.4103/ejd.ejd_116_18

For many years, the “gold standard” for *ex vivo* methods was the clearing technique.^[2] In recent years, the use of micro-computed tomography (CT) gained popularity. Micro-CT is a three-dimensional X-ray technique that can identify the slightest anatomical details with greater accuracy than the clearing technique.^[3] However, this technique is time-consuming and expensive and can be also used only on extracted teeth.^[4]

The *in vivo* techniques for investigating the endodontic space are based on X-ray examinations. Radiology is an essential tool in endodontic practice since it provides a clinician with information otherwise not accessible. For a long time, the only available radiographic method was difficult to interpret because of its two-dimensional nature: The overlap of teeth and surrounding dentoalveolar structures allows to detect only few aspects of their true three-dimensional configuration.^[5,6]

The limits of traditional radiography have been largely overcome by the introduction of cone-beam CT (CBCT), which is capable of providing three-dimensional images of the teeth and their surrounding structures, i.e., images that are related to each other according to the three orthogonal planes in space.^[7-9]

CBCT is proving itself a reliable and nondestructive method for the *in vivo* study of teeth and can be used in the preoperative phase for diagnosis and treatment planning, as well as for investigating endodontic anatomy.^[10-12]

The mandibular first molar is the tooth that most frequently undergoes endodontic treatment and its mesial root is characterized by a complex and variable root canal anatomy.^[13,14] This can affect the quality of instrumentation procedures and the incidence of iatrogenic errors. Although many anatomical studies were conducted to analyze the root canal morphology of mandibular first molar mesial root, no study evaluated the confluences and the different trajectories of the two confluent canals. Therefore, these characteristics were evaluated in the present study by means of CBCT.

MATERIALS AND METHODS

A total of 200 first mandibular molars, selected from the CBCT examinations of 130 patients, were examined. Seventy patients out of 130 had both left and right molars, for a total of 140 teeth out of 200. The sample

of patients consisted of 76 males and 124 females, with an age ranging between 18 and 79 years. The examined CBCTs were previously performed for surgical and implant placement reasons.

The following parameters were evaluated:

- Number of canals
- Root canal system configuration (using as a reference Vertucci classification)
- Presence of apical confluences
- Distance between confluences and apical foramina
- Canal with a higher degree of curvature
- Symmetry between left and right elements in the same individual.

Through the use of iCatVision™ software (Imaging Sciences International, Hatfield, PA, USA), three-dimensional reconstructions were analyzed to evaluate the parameters of interest.

The parameters evaluated first were number of root canals, presence of apical confluences, and root canal system configuration according to the Vertucci classification. The axial projections were examined by scrolling the images in coronal-apical direction; the parasagittal ones were analyzed by reducing the thickness of the section to the minimum (0.2 mm, voxel size) and checked from mesial to distal.

In regard to three-dimensional reconstructions, the cursor was aligned in such a way as to intersect both canals so as to provide even in this case a vision from the mesial side of the dental element.

The distance between apical confluences and apical foramina was measured on parasagittal and three-dimensional reconstructions using the tool for distance measurement present in the same software. When a root had an accentuated curvature on the mesial-distal plane, it was not observable in its entirety in individual parasagittal frames. In this case, it was impossible to directly measure the distance between confluences and apical foramina; therefore, another method was used: The frame corresponding to the root apex and the first frame in which appeared evident the union of the two canals were identified, and taking into account that the distance between each frame and the next was 0.2 mm, the distances between the frames were summed to obtain the value of the distance between the confluence and the apex.

The identification of the canal with a higher degree of curvature in mesial vision was based on the visual

assessment by the operator, not being possible to apply any of the geometrical methods that can be used to measure the mesial-distal curvature on two-dimensional radiographs. In cases of doubt, the canal with the higher degree of curvature was chosen as the longest one, in consideration of the geometric principle that a circumference arc has a greater length than its subtended chord. The two canals were signed by different colors, using the red one for the most difficult one, the green for the easiest, and the blue for the confluences [Figures 1 and 2].

RESULTS

Number of canals and canal system configuration according to Vertucci

- All of the examined mesial roots had two canals. Of the 200 teeth under examination, 108 (59%) showed a Vertucci Type IV configuration, while 82 (41%) showed a Type II configuration.

Apical confluences

- Apical confluences were present in all the teeth with a Type II Vertucci configuration, i.e. in 41% of cases.

Distance between confluences and apical foramina

- The average distance between confluences and apical foramina was 2.847 mm.

Canal with a higher degree of curvature from a mesial point of view

- Considering the whole sample, in 170 roots, the canal with a higher degree of curvature was the mesiobuccal (MB - 85%), while in the remaining 30, it was the mesiolingual (ML - 15%)
- Taking into consideration only the 82 teeth that showed apical confluences, in 64 of them, the canal with a higher degree of curvature was the MB one (MB - 78%), and in the remaining 18, the more curved canal was the ML (22%).

Symmetry of root canal morphology between left and right elements of the same individual

- Fifty-four percent of patients had both first mandibular molars. Symmetry was found in 88% of cases, but the following observations were made:
 - In 74% of cases, mesial roots of both left and right elements showed the same Vertucci configuration and the same canal with a higher degree of curvature
 - In 14% of cases, the same Vertucci configuration was observed, but the canal with a higher degree of curvature was different
 - In 9% of cases, contralateral roots showed different Vertucci configuration and different canal with a higher degree of curvature
 - In 3% of cases, there was a different Vertucci configuration, but the canal with a higher degree of curvature was the same.

DISCUSSION

In the present study, we investigated the root canal anatomy of mandibular first molar mesial roots by means of CBCT. CBCT is a three-dimensional radiological method that is able to overcome the limitations of traditional radiology and is gradually changing the way endodontic treatment is prepared and executed.^[4]

A systematic review of literature shows the presence, in the mesial root, of two canals in 94.2% of cases; such canals would present a Vertucci Type IV configuration in 52.3% of cases and a Type II configuration in 35% of cases.^[14]

The root canal configurations of mandibular first molars reported in literature, however, show great variability related to the different populations examined and the different methods used.

A 2013 study carried out by means of CBCT on an Asian population reported a 76.86% of Type IV configuration,

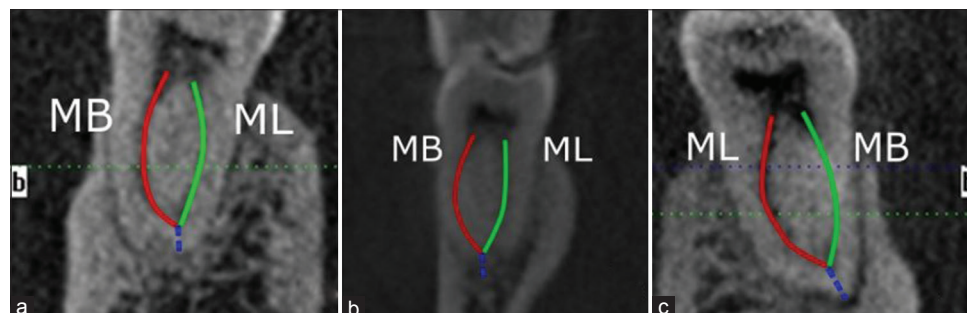


Figure 1: Visualization of canal trajectories and (blue) confluences in three different first molars (a, b, c). The most difficult canal is drawn in red.

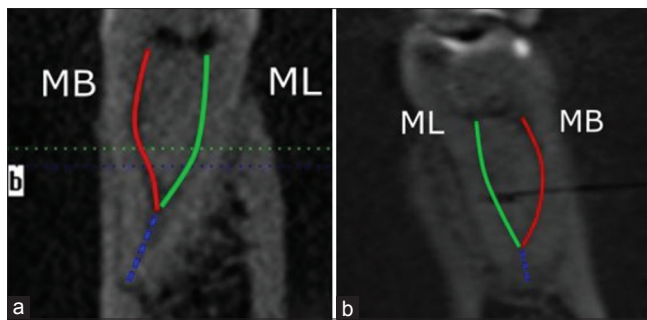


Figure 2: Visualization of canal trajectories and (blue) confluences in two molars (a, b) presenting a more coronal confluence than teeth in Figure 1. The most difficult canal is drawn in red.

followed by a 20.21% incidence of Type II configuration and 1.81% of Type I configuration.^[15]

Another study, on an Italian population, reported a 71.6% incidence of Type IV configuration and a 28.4% incidence of Type II configuration.^[16]

A study carried out on an American population reported a highly variable canal morphology in the mesial root, in which the most frequent configuration found was Type V (22.7%).^[17]

In the present work, 100% of the examined teeth showed the presence of two canals. In 59% of cases, there was a Type IV Vertucci configuration, and in the remaining 41% of cases, there was a Type II configuration, numbers that appear congruent with the statistics reported by de Pablo *et al.*^[14]

The presence of apical confluences (i.e., the presence of multiple canals that become a single canal in the apical-middle thirds of the root) and its relation to canal curvature were evaluated in the present study. No studies so far have evaluated apical confluences in these roots even if their recognition is clinically very relevant. Confluent canals often result in abrupt curvatures that may overstress instruments and cause their intracanal breakage.

This iatrogenic error, however, can be easily avoided by treating and filling the straighter canal up to its apical end and the other canal only up to the junction point.^[1] Unfortunately, in the majority of cases, a preoperative radiograph cannot show confluence and also which canal is the more straight one.

In the present study, all canal confluences were detected in the apical third or between the middle third and the apical third of the root. Therefore, the number of elements having apical confluences

matched the number of elements having a Type II Vertucci configuration.

The average distance between confluences and root apex was 2847 mm. These data are clinically relevant because the apical portion of the canal is always more challenging. An abrupt confluence in the last 3 mm can easily overstress an endodontic instrument, which already accumulated metal stress in coronal and middle curvatures. Moreover, confluent canals are very rarely identified through preoperative two-dimensional radiology, making CBCT a key instrument for better planning of the therapy.

In the present work, we also investigated which canal (the MB or the ML) had a higher degree of curvature when observed from a mesial point of view. Literature is quite unanimous in this regard: Vertucci,^[1] for example, has stated that the vestibular canal is usually the more curved one; another 2015 study observed that the degree of curvature is significantly higher in the MB canal compared to the ML one.^[18] These observations were confirmed by the results of this study: in 85% of cases (considering the entire sample analyzed), the canal with a higher degree of curvature was the MB one.

However, no studies related the canal curvature and apical confluences. In the present study, MB canals were the most curved canal in 78% of cases. Therefore, in the presence of a confluence, the percentage of cases in which the ML canal is more curved than the MB is higher than expected.

Symmetry between left and right mandibular first molars of the same patient was analyzed. Few studies in the literature examined symmetry between contralateral molars, and most of them focused on the number of roots and canals without analyzing in detail the canal trajectories. A 2013 study on an Italian population showed symmetry (in relation to the number of roots and canals) between contralateral molars in 70.6% of cases;^[19] another work,^[20] published in 2015 and referring to an Indian population, observed symmetry between the left and right first molars in 78.6% of cases, always in reference to the above parameters.

In the present study, we aimed at gaining a much more detailed picture of the actual root canal symmetry of contralateral teeth. Two roots may present the same number of canals, but these canals may have different configurations, and also, the canal with a higher degree of curvature may not be the same.

The results showed that symmetry was present in 88% of cases, but a more in-depth analysis highlighted that in 74% of cases, the mesial roots of left and right molars of the same patients presented the same Vertucci configuration and the same canal with a higher degree of curvature; in 14% of cases, the canals had the same configuration, but the canal with a higher degree of curvature was different; in 9% of cases, both the Vertucci configuration and the curved canal were different; finally, in 3% of cases, the root canal configuration was different, but the canal with a higher degree of curvature was the same.

These data clearly show that there may be different degrees of symmetry between endodontic anatomies of two similar dental elements belonging to the same individual.

CONCLUSIONS

Hence, we may conclude that apical confluences in mesial roots of mandibular molar can be present in a significantly high number of cases: their recognition and the evaluation of complexities in the trajectories of the different canals are essential to prevent iatrogenic errors during canal instrumentation.

Financial support and sponsorship

Nil.

Conflicts of interest

There are no conflicts of interest.

REFERENCES

1. Vertucci FJ. Root canal morphology and its relationship to endodontic procedures. *Endod Top* 2005;10:3-29.
2. Kim Y, Perinpanayagam H, Lee JK, Yoo YJ, Oh S, Gu Y, *et al.* Comparison of mandibular first molar mesial root canal morphology using micro-computed tomography and clearing technique. *Acta Odontol Scand* 2015;73:427-32.
3. Lee KW, Kim Y, Perinpanayagam H, Lee JK, Yoo YJ, Lim SM, *et al.* Comparison of alternative image reformatting techniques in micro-computed tomography and tooth clearing for detailed canal morphology. *J Endod* 2014;40:417-22.
4. Basrani B. *Endodontic Radiology*. 2nd ed. Hoboken, New Jersey, US: Wiley-Blackwell; 2012.
5. Gurtu A, Aggarwal A, Mohan S, Singhal A, Bansal R, Agnihotri K. CBCT: A revolutionary diagnostic aid for endodontic dilemmas. *Minerva Stomatol* 2014;63:325-31.
6. Patel S, Dawood A, Whaites E, Pitt Ford T. New dimensions in endodontic imaging: Part 1. Conventional and alternative radiographic systems. *Int Endod J* 2009;42:447-62.
7. Patel S. New dimensions in endodontic imaging: Part 2. Cone beam computed tomography. *Int Endod J* 2009;42:463-75.
8. Ambu E, Ghiretti R, Laziosi R. *3D Radiology in Dentistry. Diagnosis Pre-Operative Planning Follow up*. Milan, Italy: Elsevier; 2013.
9. Scarfe WC, Farman AG. What is cone-beam CT and how does it work? *Dent Clin North Am* 2008;52:707-30, v.
10. Eder A, Kantor M, Nell A, Moser T, Gahleitner A, Schedle A, *et al.* Root canal system in the mesiobuccal root of the maxillary first molar: An *in vitro* comparison study of computed tomography and histology. *Dentomaxillofac Radiol* 2006;35:175-7.
11. Scarfe WC, Levin MD, Gane D, Farman AG. Use of cone beam computed tomography in endodontics. *Int J Dent* 2009;2009:634567.
12. Haridas H, Mohan A, Papisetti S, Ealla KK. Computed tomography: Will the slices reveal the truth. *J Int Soc Prev Community Dent* 2016;6:S85-92.
13. de Pablo OV, Estevez R, Péix Sánchez M, Heilborn C, Cohenca N. Root anatomy and canal configuration of the permanent mandibular first molar: A systematic review. *J Endod* 2010;36:1919-31.
14. de Pablo OV, Estevez R, Heilborn C, Cohenca N. Root anatomy and canal configuration of the permanent mandibular first molar: Clinical implications and recommendations. *Quintessence Int* 2012;43:15-27.
15. Kim SY, Kim BS, Woo J, Kim Y. Morphology of mandibular first molars analyzed by cone-beam computed tomography in a Korean population: Variations in the number of roots and canals. *J Endod* 2013;39:1516-21.
16. Tocci L, Plotino G, Grande NM, Testarelli L, Messineo D, Ciotti M, *et al.* Analysis of root and root canal morphology of maxillary and mandibular molars in a Caucasian population: CBCT study *in vivo*. *G Ital Endodonzia* 2013;27:13-20.
17. Harris SP, Bowles WR, Fok A, McClanahan SB. An anatomic investigation of the mandibular first molar using micro-computed tomography. *J Endod* 2013;39:1374-8.
18. Lee JK, Yoo YJ, Perinpanayagam H, Ha BH, Lim SM, Oh SR, *et al.* Three-dimensional modelling and concurrent measurements of root anatomy in mandibular first molar mesial roots using micro-computed tomography. *Int Endod J* 2015;48:380-9.
19. Plotino G, Tocci L, Grande NM, Testarelli L, Messineo D, Ciotti M, *et al.* Symmetry of root and root canal morphology of maxillary and mandibular molars in a white population: A cone-beam computed tomography study *in vivo*. *J Endod* 2013;39:1545-8.
20. Felsypremila G, Vinothkumar TS, Kandaswamy D. Anatomic symmetry of root and root canal morphology of posterior teeth in Indian subpopulation using cone beam computed tomography: A retrospective study. *Eur J Dent* 2015;9:500-7.