Surgical treatment of two post-traumatic pseudoaneurysms of genicular artery

Paola Orlando, MD,[a,b] Pasqualino Sirignano, MD,[c,d] Francesco Taurino, MD,[e,f] Francesco Aloisi, MD,[a,b] Luigi Rizzo, MD,[a,b] *and* Maurizio Taurino, MD,[a,b] *Rome, Italy*

ABSTRACT

Pseudoaneurysms of the genicular arteries represent an extremely rare clinical occurrence. Nevertheless, young and athletic subjects, who are frequently exposed to direct joint trauma and subsequent reconstructive orthopedic surgery, are especially prone to developing these lesions. The aim of the present report was to describe two cases of a genicular artery pseudoaneurysm observed in young and healthy athletic male patients and successfully managed by surgical excision. (J Vasc Surg Cases Innov Tech 2022;8:555-7.)

Keywords: Genicular arteries; Pseudoaneurysm; Surgical treatment

Pseudoaneurysms of the genicular arteries represent an extremely rare clinical occurrence in the general population, with an incidence ranging from 0.03% to 0.12%. Nevertheless, young, healthy, and athletic subjects who are frequently exposed to direct joint trauma and subsequent orthopedic surgery can present with a relatively higher incidence owing to blunt or iatrogenic trauma.[1,2] The cumulative low incidence of these complications could explain why these lesions are often underestimated and treated suboptimally.[1,2]

The purpose of the present study was to describe two clinical scenarios related to genicular artery pseudoaneurysms and discuss their clinical presentation, diagnostic pathway, and therapeutic approaches. Both patients provided written informed consent for the report of their case details and imaging studies.

CASE REPORT

Patient 1. A 27-year-old male professional karateka was admitted to our hospital because of a pulsating mass in his popliteal fossa, which had suddenly appeared after an over-intense exercise session, probably as consequence of knee joint hyperextension. The patient underwent duplex ultrasound (DUS), which revealed the presence of a 2.5-cm aneurysm in the popliteal fossa that had apparently not arisen from the popliteal artery. Subsequent computed tomography angiography (CTA) showed the presence of a pseudoaneurysm of the posterior genicular artery, without associated popliteal artery injuries (Fig 1). The patient underwent surgical resection. Under spinal anesthesia and through a posterior incision, the posterior genicular artery was identified and ligated with complete pseudoaneurysm resection (Fig 1). The patient was discharged on postoperative day 2 in good general condition. At 5 years of follow-up, he was still completely asymptomatic with no recurrent symptoms.

Patient 2. A 32-year-old male amateur football player had been admitted to our hospital emergency room because of a pulsatile swelling medial to the right patella. His medical history was positive for multiple surgical procedures to reconstruct the cruciate ligaments, the last of which had been performed 10 days previously.

The DUS findings were highly suspicious for an iatrogenic pseudoaneurysm of the medial genicular artery. CTA confirmed the presence of a 3-cm pseudoaneurysm without other concurrent lesions present (Fig 2). Under spinal anesthesia, the patient underwent proximal and distal ligation of the medial genicular artery and complete pseudoaneurysm resection via a surgical incision medial to the right patella (Fig 2). His postoperative curse was uneventful, and he was discharged on the second postoperative day. At 90 days of follow-up, the patient was completely asymptomatic and without any complications.

DISCUSSION

Genicular artery pseudoaneurysms are often related to blunt trauma and/or develop as iatrogenic lesions after orthopedic surgery. Both blunt and iatrogenic trauma can lead to arterial wall disruption, false lumen creation, and pseudoaneurysm sac growth. Thus, regardless of the underlying mechanism, pseudoaneurysm-related complications (eg, compression of surrounding structures, arterial rupture, bleeding, hemarthrosis, fascial

From the Department of Clinical and Molecular Medicine, Sapienza University of Rome[a]; the Vascular and Endovascular Surgery Division, Sant'Andrea Hospital of Rome[b]; the Department of Surgery "Paride Stefanini," Sapienza University of Rome[c]; the Vascular and Endovascular Surgery Division, Sant'Andrea Hospital of Rome[d]; the Department of Medical Surgical Sciences and Translational Medicine, Sapienza University of Rome[e]; and the Orthopaedic and Traumatology Division, Sant'Andrea Hospital of Rome.[f]

Author conflict of interest: none.

Correspondence: Pasqualino Sirignano, MD, Department of Surgery "Paride Stefanini", Sapienza University of Rome, Via di Grottarossa, 1035/1039, Rome 00189, Italy (e-mail: pasqualino.sirignano@uniroma1.it).

The editors and reviewers of this article have no relevant financial relationships to disclose per the Journal policy that requires reviewers to decline review of any manuscript for which they may have a conflict of interest.

2468-4287

https://doi.org/10.1016/j.jvscit.2022.07.022

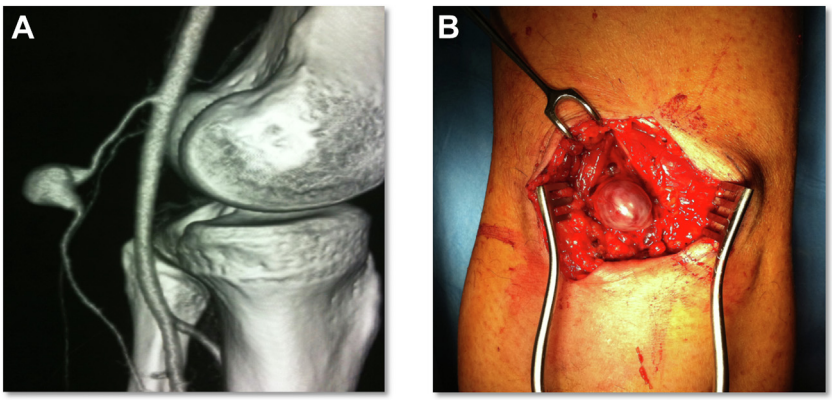

Fig 1. A, Reconstruction of computed tomography angiography (CTA) image of pseudoaneurysm originating from posterior geniculate artery. **B,** Intraoperative image showing pseudoaneurysm through posterior surgical access.

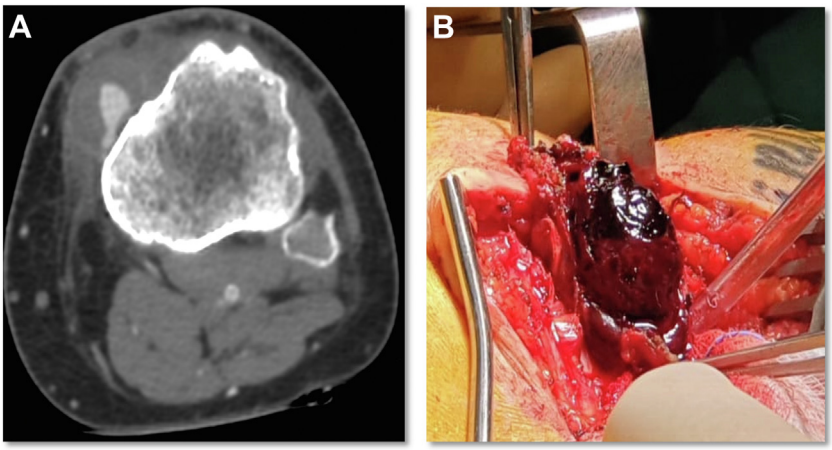

Fig 2. A, Computed tomography angiography (CTA) of pseudoaneurysm originating from medial geniculate artery. **B,** Intraoperative image showing pseudoaneurysm through medial surgical access.

hematoma, compartment syndrome) can potentially be equally severe.[3] Likewise, the presenting symptoms can be very diverse. Patients can be asymptomatic or can present with pulsating swelling, pain, calf edema, visible bruising, or hematoma.[3] The symptoms can also include neurologic and/or thrombotic compression deficits in the case of full-blown rupture.[3] The latency between the traumatic event and the intervention will depend on the timing of the diagnosis, which has generally ranged from 1 week to 3 months after the trauma.[4]

DUS has classically represented the first level investigation for the diagnosis, although CTA is mandatory before planning surgery because it can provide information about the pseudoaneurysm dimensions, morphology, location, and relationship with surrounding structures.[5] Although treatment is mandatory for all types of pseudoaneurysms, the previously reported studies have suggested different approaches according to the size of the lesion. Genicular artery pseudoaneurysms with a diameter of <2 cm can be effectively managed by ultrasound-guided compression with or without thrombin injection,[6] a minimally invasive, effective, and quick procedure. However, complications such as distal embolization and infection have been reported.[7,8] In contrast, larger pseudoaneurysm, such as those in our patients, will require a more aggressive surgical or endovascular approach.[6] The use of direct coils or microsphere embolization has been previously reported with satisfactory results.[9,10]

Nevertheless, thrombin injection will not always be a definitive solution, and endovascular procedures can be difficult because of vessel tortuosity. Moreover, the endovascular approach has a low, but not absent, risk of further iatrogenic lesions. Classically, surgical intervention via complete pseudoaneurysm exclusion represents the standard of treatment because it will always be feasible.[11] Moreover, just as for our cases, open surgery can be effectively performed without the risk of damage to the collateral vessels. Finally, such a procedure can be safely performed under spinal, or even

local, anesthesia without the requirement for a prolonged hospitalization.

CONCLUSIONS

Pseudoaneurysms of the genicular arteries are extremely infrequent occurrences but must always be considered when examining young athletic patients, especially those with a medical history positive for previous orthopedic surgery. Although several endovascular treatments, such as thrombin injection and microsphere or coil embolization, represent attractive treatment options, traditional surgery is still a feasible and effective choice.

REFERENCES

1. Mansour MA, Gorsuch JM. Diagnosis and management of pseudoaneurysms. Perspect Vasc Surg Endovasc Ther 2007;19:58-64.
2. Karkos CD, Thomson GJ, D'Souza SP, Prasad V. False aneurysm of the popliteal artery: a rare complication of total knee replacement. Knee Surg Sports Traumatol Arthrosc 2000;8:53-5.
3. Aldrich D, Anschuetz R, Lopresti C. Pseudoaneurysm complicating knee arthroscopy. Arthroscopy 1995;11:229-30.
4. Carroll BA, Graif M, Orron DE. Peripheral Vascular Imaging and Intervention. Mosby Yearbook; 1992. p. 211-25.
5. Skibo L, Polak JF. Compression repair of a postcatheterization pseudoaneurysm of the brachial artery under sonographic guidance. AJR Am J Roentgenol 1993;160:383-4.
6. Ibrahim M, Booth RE Jr, Clark TW. Embolization of traumatic pseudoaneurysms after total knee arthroplasty. J Arthroplasty 2004;19:123-8.
7. Grewe PH, Mugge A, Germing A, Harrer E. Occlusion of pseudoaneurysms using human or bovine thrombin using contrast-enhanced ultrasound guidance. Am J Cardiol 2004;93:1540-2.
8. Pritsch T, Parnes N, Menachem A. A bleeding pseudoaneurysm of the lateral genicular artery after total knee arthroplasty: a case report. Acta Orthop 2005;76:138-40.
9. Sugimoto T, Kitade T, Morimoto N, Terashima K. Pseudoaneurysms of peroneal artery: treatment with transcatheter platinum coil embolization. Ann Thorac Cardiovasc Surg 2004;10:263-5.
10. Kiss H, Drekonja T, Grethen C, Dorn U. Postoperative aneurysm of the popliteal artery after arthroscopic meniscectomy. Arthroscopy 2001;17:203-5.
11. Evans JD, De Boer MT, Mayor P. Pseudoaneurysm of the medial inferior genicular artery following anterior cruciate ligament reconstruction. Ann R Coll Surg Engl 2000;82:182-4.

Submitted May 11, 2022; accepted Jul 27, 2022.