


Endoscopic management of giant colonic polyps: a retrospective Italian study

Paolo Quitadamo¹, Sara Isoldi¹, Germana De Nucci², Giulia Muzi³, Flora Caruso⁴

¹Pediatric Gastroenterology and Hepatology Unit, Santobono-Pausilipon Children's Hospital, Naples; ²Gastroenterology and Endoscopy Unit, Garbagnate Milanese Hospital, Milan; ³NESMOS Department, Pediatric Unit, Sapienza University of Rome, Rome; ⁴Hepatogastroenterology Division, Department of Precision Medicine, University of Campania Luigi Vanvitelli, Naples, Italy



Endoscopic management of giant colonic polyps: a retrospective Italian study

BACKGROUND


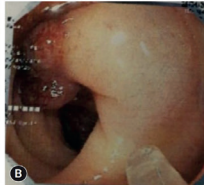

- **Giant polyps**, defined as polyps larger than 30 mm, pose a significant technical challenge as special skills are required for their removal.
- Endoscopic resection technique selection for giant colonic polyps is important for obtaining complete tissue for accurate histopathological diagnosis, which is crucial for **diagnosis, prognosis, and treatment planning**, despite the lack of a single best method identified by controlled trials.

METHODS

- 38 patients who underwent the regional screening program for colorectal cancer prevention and were diagnosed with **giant colonic polyps** were recruited.
- The management of this large series of giant polyps was retrospectively evaluated to compare the efficacy and side effects of different resection techniques.

RESULTS

- With the **epinephrine volume reduction** method, we achieved *en bloc* resection in all cases.
- **Furthermore:**
 - **Histology confirmed the correct indication to endoscopic resection in all cases**
 - **No earlier or delayed complications were observed**
 - **No patient required hospitalization**

Epinephrine volume reduction is as an alternative technique for giant polyp resection, since it is safe, effective, low cost and it allows not to postpone the polypectomy to a later time.

Clin Endosc 2024;57:501-507

Received: September 12, 2023 **Revised:** January 13, 2024
Accepted: January 14, 2024

Correspondence: Paolo Quitadamo
 Pediatric Gastroenterology and Hepatology Unit, Santobono-Pausilipon
 Children's Hospital, Via Mario Fiore 6, 80129 Naples, Italy
E-mail: paoloquitadamo@yahoo.it

© This is an Open Access article distributed under the terms of the Creative Commons Attribution Non-Commercial License (<https://creativecommons.org/licenses/by-nc/4.0/>) which permits unrestricted non-commercial use, distribution, and reproduction in any medium, provided the original work is properly cited.

Background/Aims: Polyps greater than 30 mm are classified as “giants”. Their endoscopic removal represents a technical challenge. The choice of the endoscopic removal technique is important because it provides a resection sample for precise histopathological staging. This is pivotal for diagnostic, prognostic, and management purposes.

Methods: From a retrospective analysis, we obtained a sample of 38 giant polyps. Eighteen polypectomies were performed using the epinephrine volume reduction (EVR) method, nine polypectomies utilized endo-looping or clipping methods, and 11 patients underwent surgery.

Results: We obtained *en bloc* resection with the EVR method in all cases; histology confirmed the correct indication for endoscopic resection in all cases. Moreover, no early or delayed complications were observed, and no patient required hospitalization. Using endo-looping or clipping methods, we observed advanced histology in 1/9 (11.1%) cases, while another patient (1/9, 11.1%) had delayed bleeding. Among patients who underwent surgery, 5/11 (45.5%) were deemed overtreated and three had post-surgical complications.

Conclusions: We propose EVR as an alternative technique for giant polyp resection due to its safety, effectiveness, cost-efficiency, and the advantage of avoiding the need to postpone polypectomy to a later time. Further prospective studies might help improve this experience and enhance the technique.

Keywords: Endoscopic removal; Polypectomy; Polyps

INTRODUCTION

Large polyps—including those larger than 30 mm, which are defined as “giants”—pose a significant technical challenge as special skills are required for their removal.¹ Polyp size is directly correlated with an increased risk of carcinoma.^{2,3} A thorough examination of the polyp is crucial, particularly in the case of a giant polyp, to determine the best approach for its removal and the possibility of endoscopic resection.⁴ Three parameters should be evaluated before endoscopic resection: morphology, pit pattern, and vascular pattern, all of which correlate with histology. The morphologic type of superficial lesions is established using the Parigi-Kyoto classification.⁵ Various types of pit patterns are determined by the microstructure of colonic mucosa on the polyp’s surface. The invasive growth of a *de novo* carcinoma is usually away from the surface rather than towards it; however, a disorganized or “nonstructural” pattern seems to correspond to carcinomas with a submucosal invasion, including *de novo* lesions.⁶ Finally, the examination of colonic mucosa on the polyps’ surface is optimally conducted through magnifying chromoendoscopy for the vascular pattern, where indigo carmine was originally used to delineate the mucosal pattern,^{7,8} and magnifying virtual chromoendoscopy, utilizing narrow-band imaging to enhance the mucosal pattern.⁹ Both modalities frequently use Kudo’s classification as the criteria to diagnose neoplasia. This provides the basis for real-time decisions during ongoing colonoscopy.¹⁰⁻¹²

In addition to morphology, pit, and vascular patterns, two other factors must also be considered before polyp removal: the polyp size (as previously mentioned) and prevention of compli-

cations. High-grade dysplasia is reported in up to 35% of villous adenomas that are greater than 1 cm in size.^{13,14} The likelihood of encountering invasive cancer increases with growing polyp size and approaches 85% in sessile polyps larger than 4 cm.^{15,16} However, large polyps can remain benign, despite their dimensions.¹⁷⁻¹⁹ In some cases, no obvious areas of invasion may be present even if the polyp contains focally invasive carcinoma. The incidence of high-grade dysplasia and invasive carcinoma increases with increasing polyp size and percentage of villous components.^{17,20}

Preventing complications is a landmark in the management of giant polyps. The most frequent complications include post-polypectomy bleeding, perforation, and technical difficulties in removing giant polyps.^{21,22} Previous studies recognized some features related to postpolypectomy bleeding, including polyp size, position in the right colon, sessile morphology, number of polyps, comorbidities, endoscopist’s experience, and the use of antiplatelet/anticoagulant drugs.^{23,24} To decrease such risk, saline solution injection, epinephrine injection, and the use of endoloops (Olympus America) were recommended.²⁵⁻²⁷ Nevertheless, placing an endoscopic endoloop around the stalk owing to the large dimensions is often difficult and involves a risk of entrapment.²⁸ For these reasons, a sculpt-down resection may be necessary to fully evaluate the pedicle or base of the polyp, and surgery is needed in some cases.^{29,30}

Although multiple techniques for giant polyp excision were proposed, controlled trials do not support one optimal method.³¹ Some techniques for endoscopic resection of colorectal tumors³²⁻³⁷ include the ‘sculpting down’ polypectomy, the endoscopic resection through a retroflexed scope, clipping before

polypectomy, and the epinephrine volume reduction (EVR). Finally, certain giant polyps may require surgery for their removal.

The primary aim of this study was to retrospectively evaluate the management of a large series of giant polyps in a sample of adult patients who underwent colonoscopy for screening purposes. Secondary aims were to compare the efficacy and side effects of different resection techniques.

METHODS

This retrospective study was conducted between January 2020 and December 2021 at San Giovanni di Dio Hospital, a first-level endoscopic center in Campania, Italy. All patients undergoing the regional screening program for colorectal cancer prevention who were diagnosed with giant colonic polyps were recruited. No exclusion criteria were considered.

The central department database was used to identify the cases. A medical record was completed for all enrolled patients. Demographic and clinical data included the patient's age, sex, and possible comorbidities. Moreover, we collected the features of the resected giant polyps, including shape, size, colonic site, pit, and vascular patterns. Estimating the size can be difficult as endoscopists frequently overestimate the *in vivo* size. Empirically, estimation was performed with an open 35 mm snare and ruler measurement immediately after excision and fixation in formalin. Finally, we recorded the resection technique along with possible complications, the polyp histological analysis report, and the eventual 1-year recurrence.

The EVR technique was performed by injecting 4 to 8 mL of 1:10,000 epinephrine solution into the head of the polyp at two to four sites. Variceal needles (23 gauge) were used for the injections. An immediate blanching of the head was noted following the injection. Subsequently, 2 to 4 mL of epinephrine were injected into the stalk at two or more sites. A dramatic volume reduction was achieved after 3 to 5 minutes.

Study data were entered into Excel spreadsheets (Microsoft Inc.) and analyzed with GraphPad PRISM software ver. 5.1 (GraphPad Software Inc.) and R ver. 3.6.0 software (R Foundation for Statistical Computing) environment for statistical computing. Quantitative variables were expressed as the mean±standard deviation while frequencies and percentages were used for categorical variables. Statistical analyses were performed using the chi-squared test or the Fisher exact test, as deemed appropriate, to analyze differences in clinical pre-

sentation (symptomatic vs. asymptomatic). The odds ratio was computed to assess the association between the different study variables and the rate of complications. A *p*-value of ≤0.05 was considered significant and the odds ratio was calculated with a 95% confidence interval.

Ethical statement

The study was approved by the “Cardarelli-Santobono” independent Ethics Committee (No. 23/2018) and was conducted in accordance with the Declaration of Helsinki and Guidelines for Good Clinical Practice. Informed patient consent was not obtained owing to the study's nature and the absence of specific or demographic data recording.

RESULTS

During the regional screening program, we detected a total of 38 giant polyps out of 700 endoscopies (5.4%). Polyps were identified in 25 male and 13 female patients (mean age±standard deviation: 64.5±8.4 years, age range: 50–70 years). The mean size of the polyps (maximum diameter) was 3.6 cm. Furthermore, 32/38 polyps (84.2%) were pedunculated while 6/38 (15.8%) were sessile. The shape, size, pit and vascular patterns, colonic site, and histological features of each polyp are listed in Table 1.

Eighteen polypectomies were performed with the EVR method, nine polypectomies used endo-looping/clipping methods, and 11 patients underwent surgery. We used colonoscope EX-ERA II 190 to perform pancolonoscopies. In 30 cases, the instrument was replaced by a gastroscope to obtain an improved control of resection for evaluating the exact morphology of the polyps. This substitution was particularly necessary for lesions often located in diverticular sigma.

The EVR method allowed an *en bloc* resection in 18/18 polyps (100%) (Fig. 1). An injection in the head of the polyp was performed after an assessment of polyp morphology and size. The exam was completed with the eventual change of the endoscope. Histological analysis confirmed the accurate indication for endoscopic resection in all cases: only 5/18 (27.8%) polyps were identified with advanced histology (Haggitt 1). Moreover, no early or delayed complications were observed, and no patient required hospitalization (Table 1).

The endo-looping and clipping method allowed an *en bloc* resection in only 5/9 cases (55.6%). In the remaining cases, the sculpt-down technique was performed. Histological analysis

Table 1. Specific features of giant polyps along with their management and outcome

Sex	Age (yr)	Size (cm)	Shape	Colonic site	Pit pattern (Kudo)	Vascular pattern (NICE)	Removal technique	Histology	Complication	1-year recurrence
M	70	4	Ip	Sigmoid	III-L	2	EVR	HGD	None	None
F	53	3	Is	Sigmoid	III-L	2	EVR	HGD	None	None
F	80	3	Ip	Sigmoid	III-L	2	EVR	Haggit 1	None	None
M	52	4	Is	Sigmoid	III	2	EVR	HGD	None	None
M	63	4	Ip	Sigmoid	III-IV	2	EVR	HGD	None	None
M	67	3.5	Ip	Sigmoid	III-L	2	EVR	HGD	None	None
M	64	4	Ip	Sigmoid	III-IV	2	EVR	HGD	None	None
F	62	4	Is	Sigmoid	III	2	EVR	HGD	None	None
F	70	3	Is	Sigmoid	III-IV	2	EVR	Haggit 1	None	Yes
M	63	4	Ip	Sigmoid	III-IV	2	EVR	HGD	None	None
F	76	4	Ip	Sigmoid	III	2	EVR	Haggit 1	None	None
F	53	4	Ip	Sigmoid	III-L	2	EVR	HGD	None	None
M	73	3	Ip	Sigmoid	III	2	EVR	HGD	None	None
M	72	3	Ip	Sigmoid	III-IV	2	EVR	HGD	None	None
M	69	3	Ip	Sigmoid	III-L	2	EVR	Haggit 1	None	None
M	63	3	Ip	Sigmoid	III	2	EVR	HGD	None	None
F	57	3	Ip	Sigmoid	III	2	EVR	HGD	None	None
F	75	3	Ip	Sigmoid	III-IV	2	EVR	Haggit1	None	None
M	64	5	Ip	Sigmoid	III	2	E	HGD	None	None
M	65	5	Ip	Sigmoid	III	2	E	LGD	Delayed bleeding	None
F	66	5	Is	Sigmoid	III-L	2	E+SD	HGD	None	None
M	55	3	Ip	Sigmoid	III	2	E	HGD	None	None
F	62	4	Ip	Sigmoid	III-IV	2	SD	Haggit 2	None	None
M	64	4	Ip	Sigmoid	III-IV	2	Cpost	HGD	None	None
M	60	4	Ip	Sigmoid	III	2	Cpre+SD	HGD	None	None
M	64	3	Ip	Sigmoid	III	2	Cpre, post+SD	HGD	None	None
M	74	3	Ip	Sigmoid	III	2	Cpost+SD	Kikushi 1	None	None
F	68	4	Ip	Sigmoid	III-IV	2	Cpre, post+SD	HGD	None	None
F	36	3	Ip	Sigmoid	III-L	2	S	Haggit 2	None	None
M	68	3	Ip	Sigmoid	IV	2	S	Cancer	None	None
M	80	4	Isp	Sigmoid	IV-V	2-3	S	Cancer	None	None
F	66	3	Ip	Sigmoid	IV	2	S	Kikushi 2	None	None
F	58	3.5	Ip	Sigmoid	III	2	S	HGD	None	None
M	66	3	Ip	Sigmoid	III	2	S	HGD	Yes	None
F	58	4	Ip	Sigmoid	III	2	S	HGD	None	None
M	64	4	Is	Sigmoid	III-IV	2	S	Haggit 1	None	None
M	65	4	Ip	Sigmoid	III-IV	2	S	Haggit 2	Yes	None
M	63	3	Ip	Sigmoid	III	2	S	Haggit 1	None	None
M	66	3	Ip	Sigmoid	IV	2	S	Cancer	Yes	None

NICE, narrow-band imaging international colorectal endoscopic; M, male; F, female; EVR, epinephrine volume reduction; E, endloop; SD, sculpt down; S, surgery; C, clipping; LGD, low grade dysplasia; HGD, high-grade dysplasia.

confirmed the accurate indication for endoscopic resection in all cases: only 1/9 (11.1%) polyps were discovered with advanced histology (Haggitt 2). Finally, 1/9 (11.1%) patients had delayed bleeding after 4 days, yet this was spontaneously resolved (Table 1).

Among the 11 patients that underwent surgical polyp resection, 3/10 were diagnosed with colorectal cancer, 7/10 were deemed overtreated, and three had post-surgical complications.

None of the 38 study patients experienced a polyp recurrence at a 1-year follow-up (Table 1).

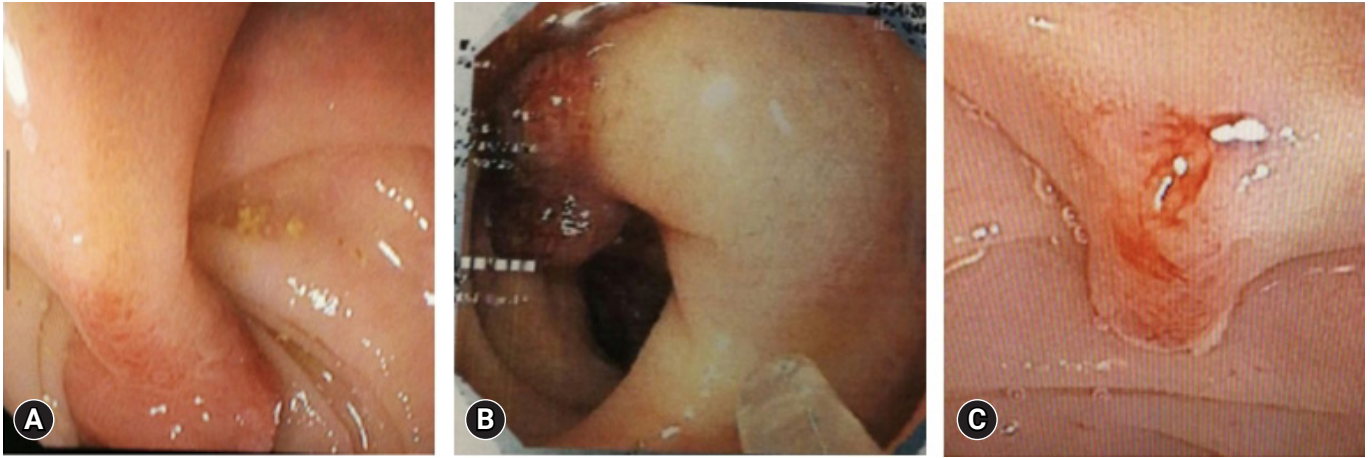


Fig. 1. Endoscopic images of the epinephrine volume reduction techniques. (A) A giant pedunculated polyp in sigmoid colon. (B) Epinephrine volume reduction. (C) One time polypectomy.

DISCUSSION

In our study, the EVR technique was demonstrated to be a safe and effective therapeutic option for giant polyp endoscopic resection, displaying better outcomes in comparison to other endoscopic techniques such as endo-loop placement. Moreover, fewer complications were recorded in our patients treated with this approach compared to those treated with endo-looping and surgery.

The management of giant colonic polyps during endoscopy may be challenging as these polyps are uncommon and exposure during training is limited. Concerns regarding incomplete resection, coexistent malignancy, and safety make the removal of giant polyps controversial. In cases of poor visualization of the stalk, significant reduction of polyp volume by piecemeal resection may be necessary before complete removal can be safely performed.

Endoscopic treatment is an effective therapy for large colorectal neoplasia and may be performed as *en bloc* or through piecemeal resection, depending on lesion morphology or local expertise, although *en bloc* resection should generally be preferred.^{38,39} The choice of the endoscopic removal technique is very important because it provides a resection specimen for precise histopathologic staging to further direct diagnosis, prognosis, and management decisions.

The EVR technique results in optimal control of polyp resection and of the overall operatory field by achieving a volume reduction of 25% in the diameter of a sphere which equates to an almost 60% reduction in volume. Quantifying polyp sizes is

difficult, especially if they are more than 3 cm. Indeed, precise measurement is not as essential as having a good vision of the totality of the lesion and the possibility of an *en-bloc* resection. Polyp size reduction leads to a consequential reduction in the associated risk of bleeding. Epinephrine injection, the use of endoloops, and endoclipping are generally necessary for giant polyps resection to reduce the risk of bleeding because the feeding artery is often large and difficult to cauterize.^{34,40-42} However, up to 24% of post-procedural bleeding is reported in the scientific literature after EVR.³⁴

No relapse was observed during our 1-year endoscopic follow-up. This might be another step towards endoscopic EVR becoming the standard treatment for giant polyps, instead of surgical procedures (conventional or laparoscopic resection or transanal excision), especially in patients with severe illnesses and elevated risk for surgery and anesthesia. The risk of residual tumor or nodal metastases for giant polyps meeting favorable criteria must be balanced against a mortality risk of 0.2% to 2% of elective colon surgery, which additionally increases with age.

The EVR technique is also suitable for the diverticular disease of the colon; indeed, the presence of diverticula renders the placement of an endoloop relatively contraindicated, as it exacerbates the necessity for subsequent resections, requiring a significant number of sculpt-down procedures. Furthermore, the application of the EVR technique for laterally spreading tumors is debatable since they do not have a single vascular axis and an excess of epinephrine may be needed for an adequate result.

The EVR technique is a cheap intervention that is particularly suitable for peripheral centers. In addition, EVR allows a

single-stage removal of the lesion without the need to repeat the colonoscopy, thus increasing patient compliance and decreasing costs.

In conclusion, we propose EVR as an alternative technique for giant polyp resection, due to the safety, effectiveness, and cost-efficiency of the procedure. Additionally, EVR provides the advantage of not delaying the polypectomy to a later time. The results of our study are encouraging although the sample size is relatively small. Further prospective studies could enhance this experience, refine the technique, and yield meaningful data.

Conflicts of Interest

The authors have no potential conflicts of interest.

Funding

None.

Author Contributions

Conceptualization: FC, PQ; Data curation: FC, PQ, GDN; Formal analysis: SI, PQ; Investigation: FC, SI; Methodology: GDN, PQ; Supervision: PQ, FC; Validation: all authors; Visualization: SI; Writing—original draft: PQ, SI, FC; Writing—review & editing: all authors.

ORCID

Paolo Quitadamo <https://orcid.org/0000-0003-0734-7472>
 Sara Isoldi <https://orcid.org/0000-0001-8390-5371>
 Germana De Nucci <https://orcid.org/0000-0001-8758-654X>
 Giulia Muzi <https://orcid.org/0000-0003-2720-6570>
 Flora Caruso <https://orcid.org/0009-0008-5339-7853>

REFERENCES

- Coverlizza S, Risio M, Ferrari A, et al. Colorectal adenomas containing invasive carcinoma. Pathologic assessment of lymph node metastatic potential. *Cancer* 1989;64:1937–1947.
- Cannon-Albright LA, Bishop DT, Samowitz W, et al. Colonic polyps in an unselected population: prevalence, characteristics, and associations. *Am J Gastroenterol* 1994;89:827–831.
- Fong TV, Chuah SK, Chiou SS, et al. Correlation of the morphology and size of colonic polyps with their histology. *Chang Gung Med J* 2003;26:339–343.
- Choi YS, Lee JB, Lee EJ, et al. Can endoscopic submucosal dissection technique be an alternative treatment option for a difficult giant (≥ 30 mm) pedunculated colorectal polyp? *Dis Colon Rectum* 2013;56:660–666.
- The Paris endoscopic classification of superficial neoplastic lesions: esophagus, stomach, and colon: November 30 to December 1, 2002. *Gastrointest Endosc* 2003;58(6 Suppl):S3–S43.
- Kudo S, Rubio CA, Teixeira CR, et al. Pit pattern in colorectal neoplasia: endoscopic magnifying view. *Endoscopy* 2001;33:367–373.
- dos Santos CE, Lima JC, Lopes CV, et al. Computerized virtual chromoendoscopy versus indigo carmine chromoendoscopy combined with magnification for diagnosis of small colorectal lesions: a randomized and prospective study. *Eur J Gastroenterol Hepatol* 2010;22:1364–1371.
- Kudo S, Tamura S, Nakajima T, et al. Diagnosis of colorectal tumorous lesions by magnifying endoscopy. *Gastrointest Endosc* 1996;44:8–14.
- Fujii T, Hasegawa RT, Saitoh Y, et al. Chromoscopy during colonoscopy. *Endoscopy* 2001;33:1036–1041.
- Sano Y, Emura F, Ikemats H. Narrow band imaging. In: Waye JD, Rex DK, Williams CB, editors. *Colonoscopy: principles and practice*. 2nd ed. Wiley-Blackwell; 2009. p. 514–526.
- Kanao H, Tanaka S, Oka S, et al. Narrow-band imaging magnification predicts the histology and invasion depth of colorectal tumors. *Gastrointest Endosc* 2009;69(3 Pt 2):631–636.
- Wada Y, Kudo SE, Kashida H, et al. Diagnosis of colorectal lesions with the magnifying narrow-band imaging system. *Gastrointest Endosc* 2009;70:522–531.
- Naini BV, Odze RD. Advanced precancerous lesions (APL) in the colonic mucosa. *Best Pract Res Clin Gastroenterol* 2013;27:235–256.
- Kudo Se, Lambert R, Allen JJ, et al. Nonpolypoid neoplastic lesions of the colorectal mucosa. *Gastrointest Endosc* 2008;68(4 Suppl):S3–S47.
- Bianco MA, Cipolletta L, Rotondano G, et al. Prevalence of non-polypoid colorectal neoplasia: an Italian multicenter observational study. *Endoscopy* 2010;42:279–285.
- O'Brien MJ, Winawer SJ, Zauber AG, et al. The National Polyp Study. Patient and polyp characteristics associated with high-grade dysplasia in colorectal adenomas. *Gastroenterology* 1990;98:371–379.
- Stulc JP, Petrelli NJ, Herrera L, et al. Colorectal villous and tubulovillous adenomas equal to or greater than four centimeters. *Ann Surg* 1988;207:65–71.
- Fung CH, Goldman H. The incidence and significance of villous change in adenomatous polyps. *Am J Clin Pathol* 1970;53:21–25.
- Boyce HW Jr. “Malignant” colon polyps: pathologist’s obligation and clinician’s dilemma. *Gastrointest Endosc* 1980;26:56–57.
- Fenoglio CM, Haggitt RC, Hamilton SR, et al. Colonic dysplasia. *Pathol Annu* 1981;16 Pt 1:181–213.

21. Pigò F, Bertani H, Grande G, et al. Post-polypectomy bleeding after colonoscopy on uninterrupted aspirin/non steroidal anti-inflammatory drugs: systematic review and meta-analysis. *Dig Liver Dis* 2018;50:20–26.
22. Nivatvongs S. Complications in colonoscopic polypectomy: an experience with 1,555 polypectomies. *Dis Colon Rectum* 1986;29:825–830.
23. Smith LE. Fiberoptic colonoscopy: complications of colonoscopy and polypectomy. *Dis Colon Rectum* 1976;19:407–412.
24. Webb WA, McDaniel L, Jones L. Experience with 1000 colonoscopic polypectomies. *Ann Surg* 1985;201:626–632.
25. Gibbs DH, Opelka FG, Beck DE, et al. Postpolypectomy colonic hemorrhage. *Dis Colon Rectum* 1996;39:806–810.
26. von Delius S, Thies P, Umgelter A, et al. Hemodynamics after endoscopic submucosal injection of epinephrine in patients with nonvariceal upper gastrointestinal bleeding: a matter of concern. *Endoscopy* 2006;38:1284–1288.
27. Paspatis GA, Paraskeva K, Theodoropoulou A, et al. A prospective, randomized comparison of adrenaline injection in combination with detachable snare versus adrenaline injection alone in the prevention of postpolypectomy bleeding in large colonic polyps. *Am J Gastroenterol* 2006;101:2805.
28. Di Giorgio P, De Luca L, Calcagno G, et al. Detachable snare versus epinephrine injection in the prevention of postpolypectomy bleeding: a randomized and controlled study. *Endoscopy* 2004;36:860–863.
29. Hachisu T. A new detachable snare for hemostasis in the removal of large polyps or other elevated lesions. *Surg Endosc* 1991;5:70–74.
30. Iishi H, Tatsuta M, Narahara H, et al. Endoscopic resection of large pedunculated colorectal polyps using a detachable snare. *Gastrointest Endosc* 1996;44:594–597.
31. Matsushita M, Hajiro K, Takakuwa H, et al. Ineffective use of a detachable snare for colonoscopic polypectomy of large polyps. *Gastrointest Endosc* 1998;47:496–499.
32. Dobrowolski S, Dobosz M, Babicki A, et al. Prophylactic submucosal saline-adrenaline injection in colonoscopic polypectomy: prospective randomized study. *Surg Endosc* 2004;18:990–993.
33. Kouklakis G, Mpoumpoumaris A, Gatopoulou A, et al. Endoscopic resection of large pedunculated colonic polyps and risk of post-polypectomy bleeding with adrenaline injection versus endoloop and hemoclip: a prospective, randomized study. *Surg Endosc* 2009;23:2732–2737.
34. Hogan RB, Hogan RB 3rd. Epinephrine volume reduction of giant colon polyps facilitates endoscopic assessment and removal. *Gastrointest Endosc* 2007;66:1018–1022.
35. Inoue Y, Tezuka T, Shinohara T, et al. Endoscopic mucosal resection of colorectal tumors. *Dig Endosc* 2004;16:91–94.
36. Park Y, Jeon TJ, Park JY, et al. Comparison of clipping with and without epinephrine injection for the prevention of post-polypectomy bleeding in pedunculated colon polyps. *J Gastroenterol Hepatol* 2015;30:1499–1506.
37. Lee SH, Lee KS, Park YS, et al. Submucosal saline-epinephrine injection in colon polypectomy: appropriate indication. *Hepatogastroenterology* 2008;55:1589–1593.
38. Shioji K, Suzuki Y, Kobayashi M, et al. Prophylactic clip application does not decrease delayed bleeding after colonoscopic polypectomy. *Gastrointest Endosc* 2003;57:691–694.
39. Ferlitsch M, Moss A, Hassan C, et al. Colorectal polypectomy and endoscopic mucosal resection (EMR): European Society of Gastrointestinal Endoscopy (ESGE) Clinical Guideline. *Endoscopy* 2017;49:270–297.
40. Wayne JD, Lewis BS, Yessayan S. Colonoscopy: a prospective report of complications. *J Clin Gastroenterol* 1992;15:347–351.
41. Hsieh YH, Lin HJ, Tseng GY, et al. Is submucosal epinephrine injection necessary before polypectomy?: a prospective, comparative study. *Hepatogastroenterology* 2001;48:1379–1382.
42. Katsinelos P, Kountouras J, Paroutoglou G, et al. Endoloop-assisted polypectomy for large pedunculated colorectal polyps. *Surg Endosc* 2006;20:1257–1261.