



### Technical procedure

## Digital assisted soft tissue sculpturing (DASS) technique for immediate loading pink free complete arch implant prosthesis

Alessandro Pozzi<sup>a,\*</sup>, Lorenzo Arcuri<sup>b</sup>, Michael S. Block<sup>c</sup>, Peter K. Moy<sup>d</sup>

<sup>a</sup> Adjunct Professor, Dental College of Georgia, Augusta University, USA. Private Practice, Rome, Italy

<sup>b</sup> University of Rome Tor Vergata, Rome, Italy

<sup>c</sup> Private Practice, Metairie, LA, USA

<sup>d</sup> Department of Oral & Maxillofacial Surgery, UCLA School of Dentistry, Los Angeles, CA, USA

### Abstract

**Purpose:** To introduce a digitally assisted technique to achieve the ideal soft and bone tissue interface for anatomic-driven pink free implant supported fixed prosthesis, and prefabricate an interim prosthesis to be used the day of the surgery as a prosthetic scaffold to condition the healing

**Methods:** The digital assisted soft tissue sculpturing (DASS) technique allows the previsualization of the ideal soft and bone tissue interface and fabricate a computer aided design computer aided manufacturing (CAD-CAM) anatomic-driven pink free complete arch interim prosthesis for the immediate loading. Bone and soft tissue interface as well as the interim prosthesis design are performed in a segmented multiple standard tessellation language (STL) file embedding the bone anatomy, the intraoral surface anatomy (dental and soft tissue), the digital wax-up and the implant positioning. The interim prosthesis is used as a prosthetic scaffold to guide the soft and bone tissue surgical sculpturing and regeneration.

**Conclusions:** The DASS technique is a predictable integrated digital workflow that simplifies the achievement of a scalloped tissue interface for pink free fixed implant prosthesis, reestablishing the mucosal dimension required for the protection of underlying bone while maintaining tissue health. The surgical sculpturing and maturation of the soft and bone tissue is driven and enhanced by the xenogeneic collagen matrix grafting and prosthetic scaffold effect of the digitally prefabricated interim prosthesis delivered the day of the surgery.

**Keywords:** Digital workflow, Navigation, guided surgery, Xenogeneic collagen matrix, Complete arch immediate loading.

Received 16 July 2019, Accepted 20 February 2020, Available online●●

### 1. Introduction

Technological advancements have significantly improved data acquisition, leading to a realistic and accurate overview of the bony structures, as well as bone density, to predict the stability of implants starting with the virtual planning stage [1]. The establishment and maintenance of an efficient soft tissue seal around a dental implant as well as around a prosthetic framework are hallmarks for implant success [2,3]. Implant planning software have overlooked the importance of the soft tissue previsualization. Most planning software focuses their tools onto the bone and the prosthetic contour. Analysis of the distance between the margin of the planned crowns and existing bone is necessary to determine if the restoration needs to incorporate a pink prosthetic area, if a grafting procedure will be required, if implants can be placed at the level of the bone or below such level, or if bone reduction is needed [4]. Digital developments have made it

possible to fuse different sets of three dimensional (3D) imaging files including digital imaging and communications in medicine (DICOM) and stereolithography (STL) files resulting in the creation of a virtual dental patient (VDP) in which the bone and soft tissues as well as the prosthetic set-up are clearly visualized. However the current role of digital assisted implant dentistry cannot be limited only to the virtual rendering of the patient anatomy but indeed to pre-visualize the ideal interplay between the soft tissue architecture, the bone at the implant and pontic sites and being able to transfer the related interface into the clinical reality at the time of the surgical intervention. Surgical augmentation techniques and prosthetic protocols can develop the soft-tissue architecture with varying levels of predictability [5-8] in order to achieve a minimum width of the peri-implant mucosa [9,10]. Significantly less bone loss can occur around bone-level implants placed with a mucosal interface thicker than 2 mm. Thin soft tissues may be augmented during implant placement resulting in less crestal bone loss [11]. This article introduces a digitally assisted proof of concept technique to previsualize the ideal soft and bone tissue interface and deliver an anatomic-driven pink free interim fixed prosthesis (FP-1 and FP-2) [12], to be used the day of the intervention as a prosthetic scaffold in combination with a surgical technique to sculpture the soft and bone tissue and thereafter conditioning the healing process.

\* Corresponding author at: Studio POZZI - International Center Oral Rehabilitation  
Viale Liegi 44, Rome, Italy  
E-mail address: apoizzi@augusta.edu (A.Pozzi).

## 2. Materials and methods

The smiling scan technique, as previously published by the Authors, is a more comprehensive, facially driven digital treatment to compose a VDP showing a broad smile under static conditions, through the superimposition of 2 different digital data sets, the DICOM files generated by the cone beam computed tomography (CBCT) (Scanora 3Dx, Kavo Dental GmbH, Biberach, Germany) scan recorded while the patient displays a broad smile on for the duration of the scan and the STL files obtained by the intraoral optical surface scanning (IOS) or extraoral optical surface scanning (EOS) of the patient's intraoral anatomy (Carestream 3600 Intraoral Scanner, Carestream Dental LLC, Atlanta, GA, USA) [13].

The smiling scan technique will allow the clinician to visualize the relationship between the upper, mid, and lower thirds of the face, the lines of symmetry, the lips, the cheeks, the occlusal plane and the related zone of transition between lip frame, gingival tissue and residual dentition or the edentulous jaw to properly evaluate the aesthetic outcome of the digitally designed patient smile (Figs. 1 and 2). The superimposition of the CBCT scan and optical surface scan, through matching of the resulting DICOM and STL data files, requires the identification of corresponding landmarks in both scanning datasets. The proprietary algorithm software (DTX ImplantStudio, Nobel Biocare AG, Kloten, Switzerland) automatically overlays the DICOM data with the STL data, regardless if the source of the optical scanning is an intraoral scanner or a laboratory scanner. The patient was asked to keep the dental arches in contact during the Smiling Scan technique in order to record the current maxillo-mandibular skeletal relationship and vertical occlusal dimension. In case of patient with terminal dentition a wax rim was taken and kept into the mouth during the CBCT examination in order to record the proper maxillo-mandibular skeletal relationship and vertical occlusal dimension.

In case of complete edentulism of one or both dental arches or terminal dentition with less than 3 teeth, the Smiling Scan and the integration of the planned prosthesis within the craniofacial model can be achieved through the double scan technique with fiducial markers based matching [14]. A radiographic acrylic resin guide was fabricated, duplicating the patient denture properly addressing the vertical occlusal dimension, phonetics and aesthetics, and trimming the buccal flange in order to better visualize into the software the interplay between the ideal prosthetic contour at the cervical level and the edentulous ridge (Fig. 3).

The implant planning software allowed for an automated design of the complete arch wax-up in order to enhance a prosthetically driven implant positioning. The prosthetic design can be verified and validated with the use of the fully-adjustable virtual articulator tool of the restorative software, properly set up according with the patient values assessed with an electronic face-bow (Arcus Digma, KavoDental GmbH, Biberach, Germany).

Segmented multiple interrelated STL files embedding the bone anatomy, the intraoral surface anatomy (dental and soft tissue), the digital wax-up, and implant positioning were then automatically forwarded to the prosthetic software (DTX StudioDesign, Nobel Biocare AG, Kloten, Switzerland) [15]. The 3D visualization of the implant recipient sites characteristics provides the clinician with insight into the surgical, prosthetic and biologic needs that have to be accomplished in order to digitally sculpt a ridge form that can house the overall prosthetic framework, considering at the same time the minimum soft tissue thickness required to protect the underlying bone [10,16] (Figs. 4, 5 and 6). The prosthetic software allowed a clear visualization of the relationship between the soft and bone interface and the prosthetic contour at the cervical area, facilitating the digitally assisted soft tissue sculpturing (DASS) technique, in order to house the biologic height of soft tissue at the implant and pontic sites [10]. A well-fitting soft tissue-restorative interface is designed, adapting the prosthetic contour to the digitally sculptured soft and bone tissue

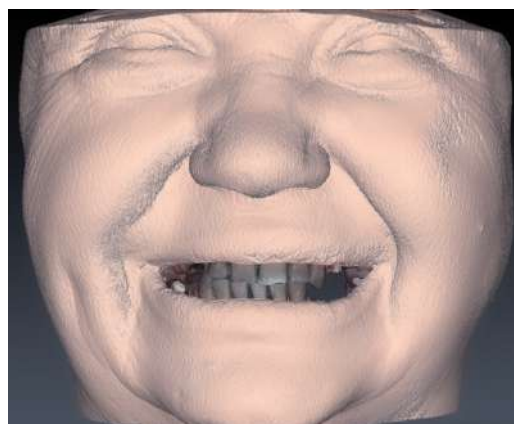


Fig. 1. Smiling scan technique with terminal dentition.

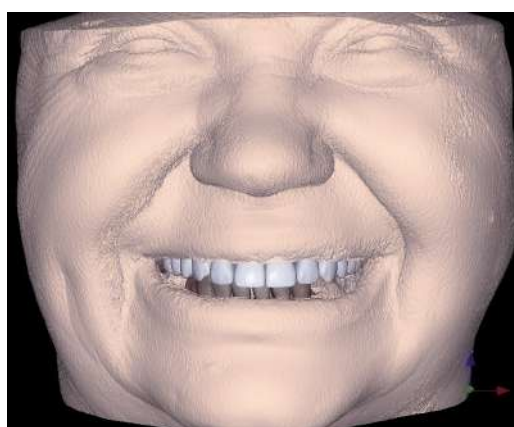
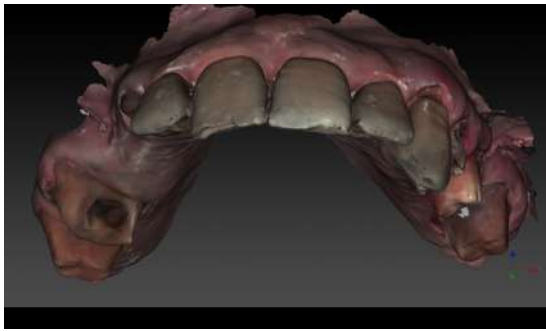


Fig. 2. Smiling scan technique with automated design of the complete arch digital wax-up.

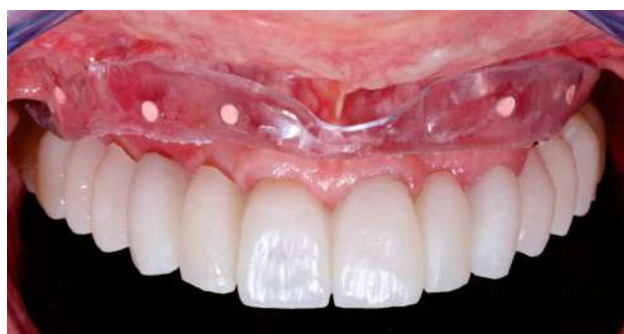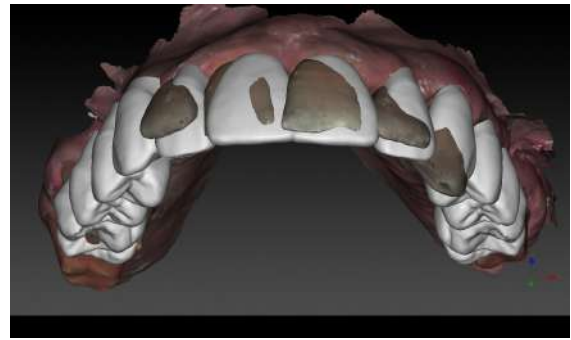


Fig. 3. Aesthetic radiographic guide for double scan technique.

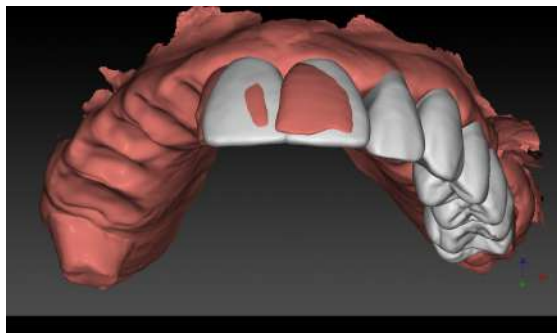
architecture (Figs. 7 and 8). The digital design of the prosthetic contour at the pontic sites followed the concepts of the biological pontic design (BPD) previously published by the authors [10] with a tight but non-compressive contact with the soft tissue of 300  $\mu$ m to allow easy hygienic access to the supporting implants to improve oral hygiene maintenance and reduce the risk of biological complications. The pontic surface was modeled with two convexities tightly in contact with the underlying soft tissue. The main convexity approaches the buccal and interproximal area, supporting the ideal shape of the gingival parabola and interproximal papilla, roughly mirroring the contours of the osseous ridge crest. This convexity echoes the facial appearance of a



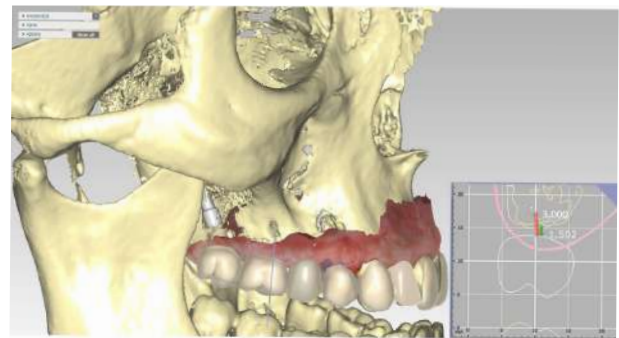
**Fig. 4.** STL file representing the current terminal dentition of the patient with the related soft tissue deformities.



**Fig. 5.** Complete arch digital wax-up overlaying the IOS STL current anatomy.

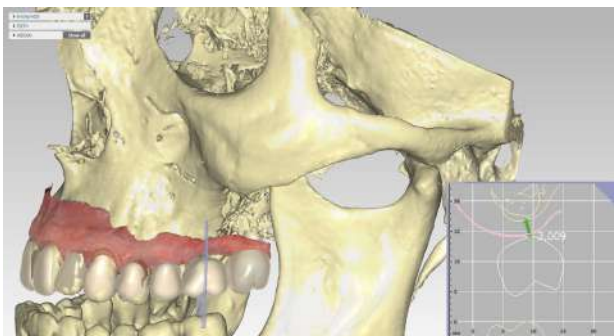


**Fig. 6.** Digital sculpturing of the soft tissue interface.



**Fig. 7.** Interplay between prosthetic contour, soft and bone tissue.

Green Arrow: pre-operative distance between the ideal prosthetic contour and the bone. Red Arrow: Ideal soft tissue height to achieve by means of soft and bone tissue sculpturing.



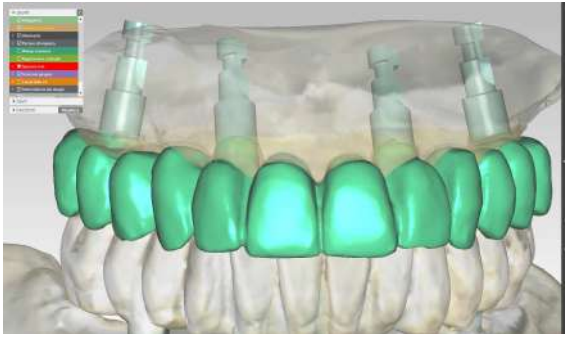
**Fig. 8.** In this scenario the BPD properly shaped is already distant 3 mm from the bone surface, in this case a split thickness flap and a xenogeneic collagen matrix grafting were performed to augment the soft tissue volume and embrace the prosthetic contour.

natural tooth as it emerges from the soft tissue (longer in the mid-cervical area and shorter at the interproximal junctions). The inner bucco-lingual convexity is oriented perpendicular to the main one and slopes toward the lingual side of the pontic, tightly in contact with the mesial-to-distal contours of the BPD [10]. The DASS technique aims to achieve a consistent 3 mm distance from the prosthetic contour and the bone interface through the soft and bone tissue sculpturing and the proper design of the BPD (Figs. 7 and 8). The interim prosthesis was then designed accordingly (Fig. 9).

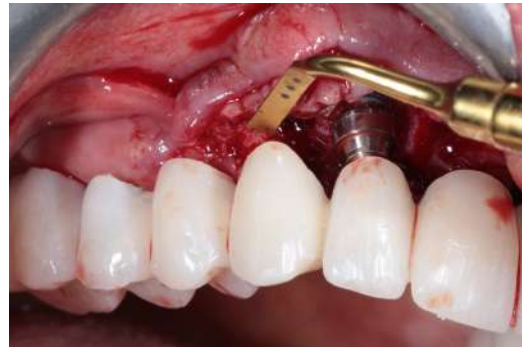Computer assisted implant surgery was performed by means of a surgical template fabricated using a 3D printer (MAX UV, Asiga, Sydney, Australia) with a dedicated resin (GR-10 guide clear-transparent, pro3Dure medical GmbH, Iserlohn, Germany) or through a dynamic navigation system (XGUIDE, X-NAV Technologies, LLC, Lansdale, PA, USA). In order to minimize surgical trauma,

a flapless or a mini flap approach were performed according to the bone and soft tissue characteristics of the implant recipient sites. If the attached gingiva needed to be implemented, a small flap was used rather than a flapless approach. The interim prosthesis was fabricated with methylmetacrylate based resin for 3D printing systems (GR-17.1 Temporary It, pro3Dure medical GmbH, Iserlohn, Germany) [15]. The interim prosthesis was used as a prosthetic scaffold to guide the soft and bone tissue surgical sculpturing. The soft tissue reduction was performed by means of a microblade (CK-2 Small Full Radius Scalpel, KavoKerr, Orange, CA, USA) or a mucotome guided by the surgical template or by the navigation system, in order to carve selectively the soft tissue at the implant and pontic sites while the bone reduction was performed with the piezotome insert OT4 under copious irrigation (Piezosurgery touch, Mectron spa, Carasco, Italy) (Fig. 10). In the post extraction sites at both implant and pontic level, a socket preservation procedure was performed in order to compensate for the horizontal and vertical ridge alterations that can be expected after tooth extraction. The fresh alveolar sockets were filled with 0.25 to 1 mm granules of slowly resorbing bone substitute material (Bio-Oss or Bio-Oss Collagen, Geistlich Pharma, Wolhusen, Switzerland), which was hydrated using the patient's blood mixed with antibiotic solution (Rifocin 250 mg/10 ml, Sanofi-aventis, Milan, Italy). The expected post extraction bone resorption was considered by the Authors differently according to the surgical access and thereafter the BPD was designed and delivered at 3 mm and 1.5 mm from the bone interface in case of flapless and with flap surgical procedures respectively [17].

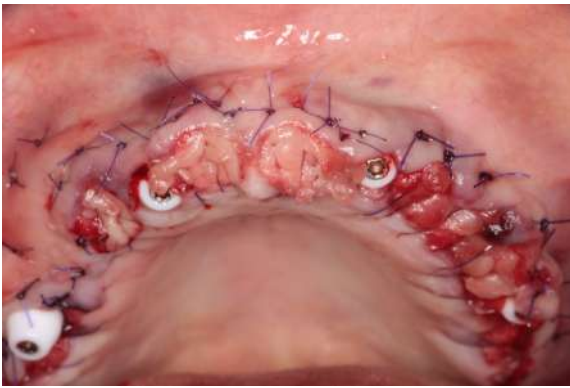
A porcine, porous, resorbable and volume-stable collagen matrix (Fibrogide, Geistlich Pharma AG, Wolhusen, Switzerland) was positioned between the soft and bone tissue interface and the prosthetic contour in order to enhance the soft tissue regeneration, avoiding



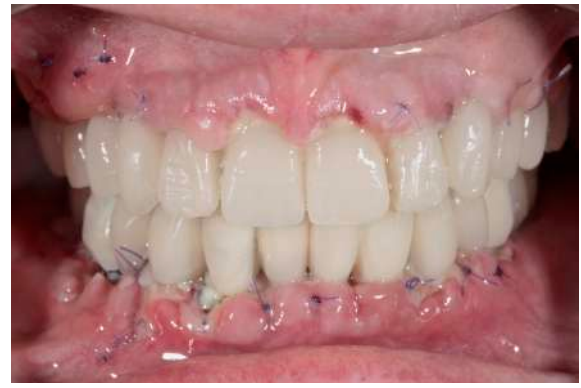**Fig. 9.** Complete arch digital wax-up matching the novel scalloped soft tissue anatomy.



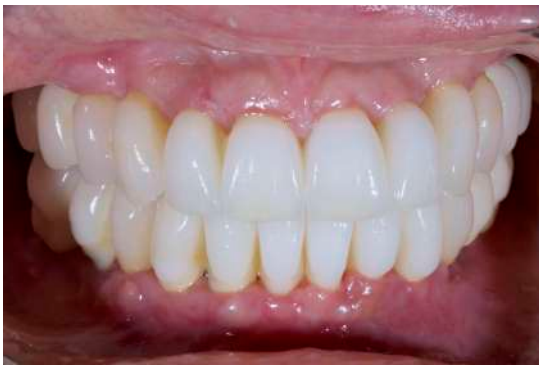**Fig. 10.** Bone reduction performed with the piezotome insert.



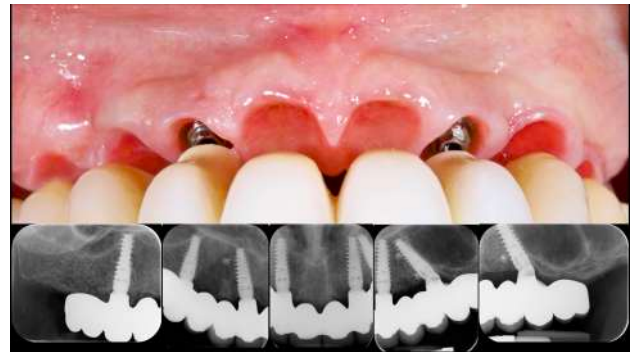**Fig. 11.** Xenogeneic soft tissue matrix grafting positioned in between the tissue interface and the prosthetic contour.



**Fig. 12.** Interim prosthesis immediately delivered and soft tissue healing enhancement after 2 weeks.



**Fig. 13.** Definitive prosthesis at 1 year follow up.



**Fig. 14.** Healthy scalloped bone and soft tissue interface with the related anatomic-driven prosthetic contour and periapical X-ray at 3 year follow up.

bone exposure. In the areas where the adequate amount of soft tissue to embrace the BPD was missing in the vertical and or horizontal directions, the xenogeneic collagen matrix was grafted through a supra-periosteal tunnel access created by means of two vertical vestibular incisions at the mesial and distal sides of the deficient site. An auto-polymerizing polyurethane resin (Structur 3, Voco GmbH, Cuxhaven, Germany) was used to reline the prefabricated computer aided design computer aided manufacturing (CAD-CAM) interim prosthesis onto the abutments and improve the fit, ensuring accurate positioning onto the abutment surface. The emergence profile of the interim prosthesis was adapted by trimming the resin remnants and polishing the surface [15]. The interim prosthesis was immediately delivered on the day of the surgery with the prosthetic contour at the cervical and interproximal areas completely embedded into the soft tissue interface,

in order to condition the maturation of the surgical wound driving the healing to match the prosthetic interface (Figs. 11 and 12). Following an uneventful healing period of 3-4 months, definitive impressions can be obtained. A cross-mounting technique was used to articulate the opposite arch cast with the interim restoration screwed onto the master cast by means of an interocclusal jig [18]. The screw retained provisional prosthesis was used to transfer all the information related to the aesthetics, phonetics, vertical dimension of occlusion (VDO), and centric relation (CR) into the definitive restoration by means of an EOS procedure (Kavo, LS 3 Scanner, Biberach, Germany). Complete-arch zirconia framework with monolithic lithium disilicate full-contour crowns fused on the top with the zirconia surface in tight but not compressive contact with the soft tissue was delivered as a definitive prosthesis (Figs. 13 and 14) [19].

### 3. Difference from conventional methods

Superimposition and 3D rendering of the facial skeleton, soft tissue, and dentition provide a comprehensive method for evaluating all the aspects of the implant treatment in a more logical and interdisciplinary manner than the conventional approach [15]. In the conventional analogic protocol for full arch immediate loading, the dental technicians are used to prefabricate the type 1 and 2 fixed dental interim prosthesis adjusting and grinding the master cast at the implant emergence and pontic sites, without any biologic guidelines related to the soft tissue height or the underlining bone anatomy but indeed with the only aim to embrace the prosthetic contour into the restorative interface. Thereafter the clinicians, in order to fit and relin such prefabricated interim prosthesis may remove a non-adequate quantity of soft and bone tissue in excess or defect. The overall conventional approach results in a very empiric method, mostly relying on the surgical and prosthetic skills of the clinician, to achieve a prosthetic interface featured with a tight but non compressive contact with the soft tissue to allow an easy hygienic access to the implants, improving oral hygiene maintenance and reducing the risk of biological complications [10]. However such procedure might also result in an excessive pressure, exerted by the prosthetic contour and leading to a thinning of the epithelium and to a changing in the composition of the connective tissue compartment subjacent to the epithelium itself with subsequent bleeding and ulceration [20,21]. Recently developed digital technologies allow the design of an anatomic-driven prosthesis followed by a prosthesis-driven surgery, resulting in minimal and precise tissue removal [15]. Rojas-Vizcaya published a hybrid digital analogic approach to perform the bone and soft tissue interface sculpturing using the interim prosthesis as a guide [22]. Indeed, the authors did not utilize, into the software, the relationship between the soft tissue, the underling bone and the prosthetic contour. The clinician was obliged to raise a supracrestal full-thickness flap to visualize the bone and perform its reduction, in order to leave a distance from the prosthetic contour to the bone ranging from 1 to 2 mm for the soft tissue healing. On the contrary, the described DASS technique supports the concept that bone and soft tissue reduction is not arbitrary, but indeed based upon a pre-determined, prosthetically ideal tooth position, achieved by means of a digital wax up performed on the VDP, considering the interplay between soft tissue height and the bone crest anatomy. The soft and bone tissue interface has to be prepared as well as the BPD prosthetic contour, in order to ensure an adequate mucosal thickness of about 3 mm in order to guarantee the proper seal in between the prosthetic contour and the underlining bone [10]. Salama et al [23] described a digitally integrated workflow, using three CAD-CAM surgical templates to obtain the desired bone reduction, a prosthetically guided implant positioning, and load an interim prosthesis that replicates the ideal tissue contours according to the BPD [10]. Anyway, the bone scalloping was designed on an STL file of the patient bone anatomy without considering the anatomic features of the overlining soft tissue architecture. Moreover, the anatomically shaped and prosthetically guided bone reduction was achieved with a bone supported CAD-CAM template and thus performed after raising a full-thickness flap. The DASS technique allows the previsualization of all the components of the perio-implant restorative interface in a digital scenario in which are represented the patient hard and soft tissue anatomy as well as the biologically shaped prosthetic contour [10]. Moreover, the tissue sculpturing is conducted with a minimally invasive surgical protocol throughout a flapless or a mini-flap access performed by means of a microblade and a guided mucotome just to allow the insertion of the piezosurgery tip to reshape the bone crest, instead of conventional bur mounted on the contra-angle or handpiece as usually advised in the conventional protocol. The minimal invasive surgical approach is needed in order to maintain the original soft tissue architecture and blood supply on site. A porcine, porous, resorbable and volume-stable collagen matrix was properly positioned in between the

soft-bone tissue interface and the prosthetic contour in order to enhance the soft tissue regeneration and avoid leaving the bone exposed in the oral cavity. In a previously published manuscript, an equine lyophilized resorbable collagen was positioned between the exposed crestal connective tissue and the apical portion of the pontic without taking into account the minimum bone to prosthetic contour distance needed to guarantee an adequate soft tissue height [6]. A recent meta-analysis based on seven randomized clinical trials suggested that the use of collagen matrix is equally effective to the connective tissue graft in increasing peri-implant soft tissue thickness and keratinized mucosa within 1-year follow-up. Nevertheless, further studies will be required to evaluate the long-term effectiveness of collagen matrix-based soft tissue augmentation on peri-implant marginal bone stability [24]. The use of a volume stable xenogeneic collagen matrix for soft tissue augmentation advised by the Authors, reduced the overall surgical trauma and post-operative morbidity compared to an autogenous soft tissue grafting in the management of complete arch implant supported restorations, resulting in a post-surgical soft tissue maturation and healing enhancement.

### 4. Effect or performance

The Authors in a previously published study stated the existence of a “prosthetic biological width” underneath the pontic-designed implant prosthetic contour, whose dimension ( $2.26 \pm 0.60$  mm) may affect the health and the dimensional stability of the soft tissue and bone interface at the implant and pontic sites [25]. The prosthetic violation of such physiological barrier may result in inflammation, ulceration, and thinning of the epithelium, jeopardizing the bone crest stability [26]. The suggested integrated digital workflow may enhance a more comprehensive treatment plan, based on a non-invasive simulation of the surgical and prosthetic outcomes, as well as a more effective communication among clinician and dental technician in order to digitally design and prefabricate a biologically driven prosthesis that can be used to guide the sculpturing of the restorative surface and at the same time as a prosthetic scaffold to enhance the maturation and the scalloping of the soft tissue interface for type 1 and 2 fixed dental implant supported prosthesis. The major limitation of the DASS technique is intrinsic in its nature that makes mandatory an adequate learning curve with the technologies used, the digital implant planning and dental design software, the static and dynamic guided surgery systems and most of all a comprehensive knowledge on the interrelated areas of the implant treatment.

### 5. Conclusion

The DASS technique is a predictable digitally assisted technique that allows the previsualization of the ideal soft and bone tissue interface and prefabricate a CAD-CAM anatomy-driven type 1 or 2 implant supported complete arch interim prosthesis for the immediate loading. The surgical sculpturing of the soft and bone tissue, the soft tissue healing enhancement by means of xenogeneic collagen matrix grafting and the prosthetic scaffold effect of the interim prosthesis allow to achieve a scalloped interface and reestablish the mucosal dimension required for the protection of underlying tissues while maintaining tissue health. The suggested integrated digital workflow may contribute to a more comprehensive implant treatment plan, as well as a more effective communication among clinician and dental technician on the major surgical, prosthetic and biologic variables that can affect the treatment outcomes.

### Conflict of interest

The authors declare to have no conflict of interest.

## References

- [1] Sennerby L, Andersson P, Pagliani L, Giani C, Moretti G, Molinari M, et al. Evaluation of a novel cone beam computed tomography scanner for bone density examinations in preoperative 3D reconstructions and correlation with primary implant stability. *Clin Implant Dent Relat Res* 2015;17:844–53.
- [2] Sanz M, Lang NP, Kinane DF, Berglundh T, Chapple I, Tonetti MS. Seventh european workshop on periodontology of the european academy of periodontology at the paradur at la granja, segovia, spain. *J of Clin Periodontol* 2011 Mar;38:1–2.
- [3] Pozzi A, Holst S, Fabbri G, Tallarico M. Clinical reliability of CAD/CAM cross-arch zirconia bridges on immediately loaded implants placed with computer-assisted/template-guided surgery: a retrospective study with a follow-up between 3 and 5 years. *Clin Implant Dent Relat Res* 2015;17:e86–96.
- [4] Cooper L, De Kok IJ, Reside GJ, Pungpapong P, Rojas-Vizcaya F. Immediate fixed restoration of the edentulous maxilla after implant placement. *J Oral Maxillofac Surg* 2005;63:97–110.
- [5] Salama M, Ishikawa T, Salama H, Funato A, Garber D. Advantages of the root submergence technique for pontic site development in esthetic implant therapy. *Int J Periodontics Restorative Dent* 2007;27:521–7.
- [6] Calesini G, Micarelli C, Coppè S, Scipioni A. Edentulous site enhancement: a regenerative approach for the management of edentulous areas. Part 1. Pontic areas. *Int J Periodontics Restorative Dent* 2008;28:517–23.
- [7] Landsberg CJ. Implementing socket seal surgery as a socket preservation technique for pontic site development: surgical steps revisited—a report of two cases. *J Periodontol* 2008;79:945–54.
- [8] Akcalı A, Schneider D, Ünlü F, Bıçakcı N, Köse T, Hämmerle CH. Soft tissue augmentation of ridge defects in the maxillary anterior area using two different methods: a randomized controlled clinical trial. *Clin Oral Implants Res* 2015;26:688–95.
- [9] Berglundh T, Lindhe J. Dimension of the periimplant mucosa. Biological width revisited. *J Clin Periodontol* 1996;23:971–3.
- [10] Pozzi A, Tallarico M, Moy PK. The Implant biologic pontic designed interface: description of the technique and cone-beam computed tomography evaluation. *Clin Implant Dent Relat Res* 2015;17:e711–20.
- [11] Puisys A, Linkevicius T. The influence of mucosal tissue thickening on crestal bone stability around bone-level implants. A prospective controlled clinical trial. *Clin Oral Implants Res* 2015;26:123–9.
- [12] Misch CE. Bone classification, training keys to implant success. *Dent Today* 1989;8:39–44.
- [13] Pozzi A, Arcuri L, Moy PK. The smiling scan technique: facially driven guided surgery and prosthetics. *J Prosthodont Res* 2018;62:514–7.
- [14] van Steenberghe D, Naert I, Andersson M, Brajnovic I, Van Cleynenbreugel J, Suetens P. A custom template and definitive prosthesis allowing immediate implant loading in the maxilla: a clinical report. *Int J Oral Maxillofac Implants* 2002;17:663–70.
- [15] Pozzi A, Arcuri L, Moy PK. Temporary shell Proof-of-Concept technique: digital-assisted workflow to enable customized immediate function in two visits in partially edentulous patients. *Compend Contin Educ Dent* 2018;39:e9–e12.
- [16] Pozzi A, Tallarico M, Marchetti M, Scarfò B, Esposito M. Computer-guided versus free-hand placement of immediately loaded dental implants: 1-year post-loading results of a multicentre randomised controlled trial. *Eur J Oral Implantol* 2014;7:229–42.
- [17] Bassir SH, Alhareky M, Wangsrimongkol B, Jia Y, Karimbux N. Systematic review and meta-analysis of hard tissue outcomes of alveolar ridge preservation. *Int J Oral Maxillofac Implants* 2018;33: 979–994.
- [18] Chaimattayompol N, Stancescu J, Steinberg J, Vergo TJ Jr. Use of a cross-mounting buccal index to help transfer the spatial relationships of an interim prosthesis to the definitive implant-supported prosthesis. *J Prosthet Dent* 2001;85:509–15.
- [19] Pozzi A, Tallarico M, Barlattani A. Monolithic lithium disilicate full-contour crowns bonded on CAD/CAM zirconia complete-arch implant bridges with 3 to 5 years of follow-up. *J Oral Implantol* 2015;41:450–8.
- [20] Tripodakis AP, Constandtinides A. Tissue response under hyperpressure from convex pontics. *Int J Periodontics Restorative Dent* 1990;10:408–14.
- [21] Zitzmann NU, Marinello CP, Berglundh T. The ovate pontic design: a histologic observation in humans. *J Prosthet Dent* 2002;88:375–80.
- [22] Rojas-Vizcaya F. Prosthodontically guided bone sculpturing for a maxillary complete-arch implant-supported monolithic zirconia fixed prosthesis based on a digital smile design: a clinical report. *J Prosthet Dent* 2017;118:575–80.
- [23] Salama MA, Pozzi A, Clark WA, Tadros M, Hansson L, Adar P. The “scaloped guide”: a proof-of-concept technique for a digitally streamlined, pink-free full-arch implant protocol. *Int J Periodontics Restorative Dent* 2018;38:791–8.
- [24] Gargallo-Albiol J, Barootchi S, Tavelli L, Wang HL. Efficacy of Xenogeneic Collagen Matrix to Augment Peri-Implant Soft Tissue Thickness Compared to Autogenous Connective Tissue Graft: A Systematic Review and Meta-Analysis. *Int J Oral Maxillofac Implants* 2019;34:1059–1069.
- [25] Pozzi A, Tallarico M, Moy PK. The implant biologic pontic designed interface: description of the technique and cone-beam computed tomography evaluation. *Clin Implant Dent Relat Res* 2015;17:e711–20.
- [26] Raigrodski AJ, Hillstead MB, Meng GK, Chung KH. Survival and complications of zirconia-based fixed dental prostheses: a systematic review. *J Prosthet Dent* 2012;107:170–7.



Copyright: This is an open-access article distributed under the terms of Creative Commons Attribution License 4.0 (CCBY 4.0), which allows users to distribute and copy the material in any format so long as attribution is given to the author(s).