



Topography-Guided Transepithelial Photorefractive Keratectomy for the Treatment of Persistent and Visually-Significant Adenoviral Corneal Infiltrates

Leopoldo Spadea , Lucia Di Genova, Edoardo Trovato Battagliola , Maria Pia Paroli 

Eye Clinic, Policlinico Umberto I, "Sapienza" University of Rome, Rome, Italy

Correspondence: Leopoldo Spadea, Head Eye Clinic, Policlinico Umberto I, "Sapienza" University of Rome, Via Benozzo Gozzoli 34, Rome, 00142, Italy, Tel +39 06 519 32 20, Fax +390688657818, Email leopoldo.spadea@uniroma1.it

Purpose: To evaluate visual and refractive outcomes of customized photorefractive keratectomy (PRK) in subjects with persistent subepithelial corneal opacities secondary to adenoviral epidemic keratoconjunctivitis (EKC).

Patients and Methods: Prospective study, which recruited patients with persistent and visually-significant post-EKC corneal opacities unresponsive to prolonged topical therapy (6 months or more). Outcome measures: uncorrected and best-corrected distance visual acuity, subjective refractive astigmatism, keratometric astigmatism, spherical equivalent, minimum corneal thickness, and corneal morphological irregularity index. Subjects were followed for 12 months post-treatment.

Results: Eighteen eyes of 18 patients aged between 32 and 75 years treated with topography-guided transepithelial PRK with iRes excimer laser (iVIS Technologies, Taranto, Italy) from June 2020 to July 2021. After 12 months, the mean UDVA improved from 1.0 ±0.00LogMAR pre-op to 0.15±0.154LogMAR, and the mean CDVA improved from 0.4±0.41LogMAR pre-op to 0.0±0.00LogMAR. With respect to UDVA, all treated eyes (100%) showed an improvement of 6 ETDRS lines or more and with respect to CDVA, 9 out of 18 eyes (50%) showed an improvement of 6 ETDRS lines or more. The mean ablation depth was 54.7±5.9µm. A statistically significant improvement was observed in all topographic indices. No infiltrate recurrence, post-treatment corneal haze, ocular hypertension or other side effects were observed throughout the follow-up period.

Conclusion: Topography-guided PRK could be considered an effective and safe treatment option to improve visual acuity in patients affected by persistent and visually-significant subepithelial corneal infiltrates caused by EKC.

Keywords: adenoviral epidemic keratoconjunctivitis, subepithelial corneal opacities, topography-guided transepithelial PRK

Introduction

Epidemic keratoconjunctivitis (EKC) is a contagious eye disease caused by multiple adenoviruses. These are medium-sized (90–100 nm), nonenveloped viruses with an icosahedral nucleocapsid containing a double-stranded DNA genome. The most virulent serotypes are 8, 19, 37, 53, and 54. They can cause a wide range of illnesses in humans. When eyes are infected, EKC can result. EKC is associated with inflammation of the cornea and conjunctiva, in the form of follicular conjunctivitis, papillary hypertrophy, conjunctival hemorrhage, lid edema, and chemosis. Preauricular and submandibular lymphadenopathy may be present and help in the diagnosis.¹ A diffuse epithelial keratitis is a distinguishing feature in the early stages of the disease. This condition can be more easily appreciated after the application of sodium fluorescein. The punctiform epithelial defects may coalesce into larger lesions approximately one week after infection. Subepithelial corneal infiltrates and epithelial keratitis typically develop two or three weeks after symptoms onset. These infiltrates generally develop in the center of the cornea, but they may spread over the entire surface.¹ These infiltrates cause significant visual disturbances such as permanent glare and/or photophobia, as well as decreased visual acuity as a result of irregular astigmatism. In severe cases, membranes or pseudomembranes develop on the tarsal conjunctiva.¹ Corneal

signs may persist for months to years. Topical treatment with corticosteroids, cyclosporine, and antiviral drugs may fail to induce disease remission. The disease can in fact recur once therapy is discontinued.²

Excimer laser phototherapeutic keratectomy (PTK) and transepithelial photorefractive keratectomy (PRK) are safe and effective procedures to treat corneal opacities localized within the anterior third of the stroma. They can be used to ablate aberrant tissue, improve transparency, and create a smoother surface.^{3,4} Successful removal of adenoviral EKC corneal opacities using PTK has been reported.^{5,6} Ablating the central cornea results in corneal flattening, which leads to a hyperopic shift. This change is directly proportional to the ablation depth. However, the hyperopic shift is unpredictable and may diminish over time.⁷

Customized PTK has been successfully used to treat superficial corneal opacities. Transepithelial excimer laser ablation is a potentially effective technique due to its ability to detect and analyze corneal irregularities that have to be corrected.^{8,9} In recent years, there have been reports of using myopic PRK, with or without the associated use of mitomycin-C (MMC), to remove EKC infiltrates.^{10,11}

To the best of our knowledge, this is the first prospective study investigating the clinical and refractive results of customized topography-guided transepithelial PRK with no antimetabolite for the treatment of persistent visually significant EKC infiltrates.

Patients and Methods

The present study was performed in accordance with the principles stated in the Declaration of Helsinki and obtained ethical approval from the local Institutional Review Board (IRB) of the “Sapienza” University of Rome, Umberto I Hospital (Prot. #0189/2020). Informed consent was obtained from all patients prior to enrollment. This is a prospective study conducted in a referral center for corneal pathologies. The population included adult subjects (at least 18 years old) with EKC corneal opacities. Inclusion criteria were eyes with persistent anterior EKC corneal opacities that decreased best-corrected visual acuity by at least 3 lines. Persistent lesions were defined as lesions not responsive to topical steroids or immunosuppressants after at least 6 months of therapy. A minimum pre-operative central corneal thickness less than 400 microns was an exclusion criterion. The other exclusion criteria were presence of an active keratitis (as determined by the pattern of fluorescein staining and clinically detectable stromal edema), eyes with active uveitis and any corneal degenerations or opacities other than those resulting from the viral keratitis, glaucoma, dry eye, herpetic corneal ulcer, diabetes, autoimmune diseases, or pregnancy. Prior to recruitment, all eyes had been treated with topical steroids or immunosuppressants for at least 6 months (Figure 1A).

All patients underwent a complete preoperative ophthalmologic examination. They were inquired about the presence of disturbing visual symptoms, such as photophobia and glare. The examination included a complete ocular and systemic history, slit-lamp biomicroscopy of the anterior and posterior segment, uncorrected distance visual acuity (UDVA), best corrected distance visual acuity (CDVA) (both expressed as the logarithm of the minimum angle of resolution, LogMAR), subjective refractive astigmatism (SRAST), and keratometric astigmatism at 3mm area (SimK), spherical

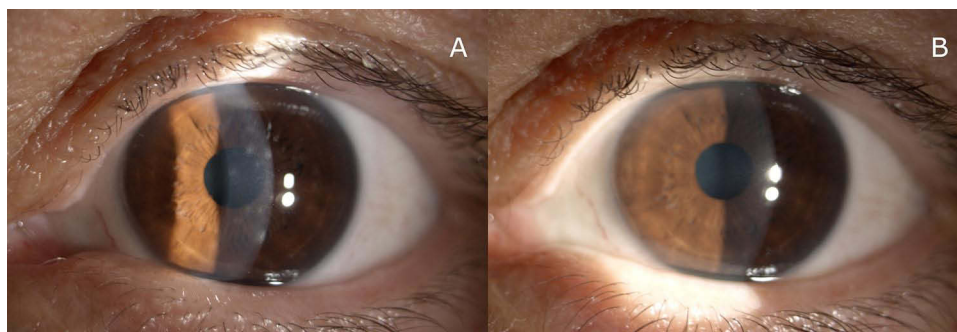


Figure 1 (A) Pre-operative clinical slit lamp image showing the left eye of a 38 year-old female patient (I.C.) with persistent corneal infiltrates following adenovirus infection and irregular astigmatism. The UDVA was 20/200, the CDVA was 20/63 with a refraction of +1.25 sph = -5 cyl ax180°. The patient complained permanent glare, photophobia and decreased visual acuity. (B) 12-months following PRK the slit-lamp image evidenced a resolution of corneal infiltrates and a clear cornea. The final postoperative UDVA was 20/20.

equivalent (SEQ), minimum corneal thickness (MCT), corneal morphological irregularity index (CMI) and applanation tonometry (AT). The device used to measure the SimK and the corneal thickness was a Scheimpflug corneal tomographer (Precisio2[®], iVIS Technologies, Taranto, Italy). Intraocular pressure was measured using the Goldmann applanation tonometer. Pre-operative evaluation also included refraction under cycloplegia and posterior segment examination. The corneal morphological irregularity index (CMI) is a parameter that indicates the deviation of the corneal shape from that of the best-matching toric surface and it is measured in microns. It is a surrogate parameter for high-order aberrations and it is intrinsically related to the quality of vision of the patient: the higher the value, the worse the quality of vision. Laser treatment planning was performed with the aid of a high-resolution corneal tomographer (Precisio2[®], iVIS Technologies, Taranto, Italy) and a dynamic pupillometer (pMetrics, iVIS Technologies, Taranto, Italy). All measurements were performed by the same examiner in the morning (ET).

Surgical Technique

All of the eyes underwent a one-step topography-guided transepithelial PRK surgery. The laser treatment was customized based on morphological and refractive data calculated by the tomographer, the spherical error quantified during the visual acuity examination. Target refractive and ablation zones were defined by the projection of an ideal pupil, as determined by dynamic pupillometry, onto the ideal corneal surface. A transepithelial approach was chosen to factor in the refractive contribution of the epithelium, which was in fact distributed unevenly over the corneal surface. The customized treatment was executed by means of the “Corneal Interactive Programmed Topographic Ablation” software (CIPTA2[®], iVIS Technologies, Taranto, Italy). This software determines the ablation volume as the intersection between the anterior shape detected by Precisio2[®] and the ideal shape determined taking care of the total corneal astigmatism and of the high order of aberrations, by means of a ray tracing process. The refractive correction factors in the total corneal astigmatism, high-order aberrations, and the subjective spherical error.

Two drops of oxybuprocaine were applied 5 minutes before surgery and after the insertion of the eye speculum. Following cyclotorsional measurement and pupil eye-tracker registration, the treatment was performed with a 0.65mm dual-flying-spot 1KHz excimer laser (iRES[®], iVIS Technologies, Taranto, Italy) using the one-step custom transepithelial “no-touch” (cTEN[®], iVIS Technologies, Taranto, Italy) ablation technique. Mitomycin-C or other pharmacological agents were not applied during the procedure. The mean targeted residual cylinder was 0D.

At the end of the laser procedure, a bandage soft contact lens (PureVision 2, Bausch & Lomb, Rochester, USA) was applied for 7 days. Postoperative treatment included ofloxacin eye drops 3 times a day, and artificial tears 6 times a day throughout the follow-up. After contact lens removal and epithelial resurfacing, patients were prescribed topical ofloxacin eye drops 3 times a day for 1 week, 0.1% fluorometholone eye drops initially 3 times/day and tapered to 1 drop/day each month for the following 3 months, and artificial tears 6 times a day throughout the entire follow-up period. Patients were examined 1, 3, and 7 days after the surgery and 1, 3, 6 and 12 months postoperatively. Tomographic examinations were repeated 3, 6, and 12 months post-treatment.

Statistical Analysis

Data distribution was tested using the Shapiro–Wilk test. Descriptive analysis was used to present pre-treatment and post-treatment data in the form of mean, standard deviation, and range (min and max values). Categorical variables were compared using the Chi-square test. The outcome variables were compared between visits using the repeated measures ANOVA. The level of statistical significance was set at $p < 0.05$. Statistical analysis was performed using STATA, v. 14.0 (StataCorp, TX, USA).

Results

This interventional, non-randomized, prospective clinical study recruited eighteen eyes of 18 patients (7 women [39%] and 11 men [61%]) with persistent EKC subepithelial infiltrates. Enrollment period spanned between June 2020 and July 2021. Subjects were treated with excimer laser topography-guided trans-epithelial PRK. Mean patient age was 53.1 ± 13.1 years (range, 32–75). Visual symptoms and cornea abnormalities had a duration of 16.3 ± 17.4 months (ranged from 6 to 41). All patients (100%) presented with marked photophobia prior to surgery. The mean targeted optical zone

diameter was $3.64 \pm 1.54 \mu\text{m}$ and the maximum planned depth ablation was $54.7 \pm 5.9 \mu\text{m}$ (range 44–70), assuming a target residual pachymetry of $487.4 \pm 29.1 \mu\text{m}$.

Re-epithelialization occurred in all eyes by the second follow-up (1 week after surgery). After treatment, 33% of subjects (6 eyes) continued to complain of a certain degree of photophobia (Chi-square test, $p < 0.01$). No patient developed conjunctivitis after treatment (Figure 1B). All patients (18 eyes; 100%) returned for follow-up at 1, 3, and 12 months. Table 1 summarizes pre-op and post-op clinical data of study subjects.

A mild haze (grade 1) was observed in two eyes (11.1%). No regression or recurrence of infiltrates were observed. As shown in Table 1 and in Figure 2, statistically significant improvements in both UCVA and CDVA were observed after surgery. Mean UDVA improved from $1.0 \pm 0.00 \text{LogMAR}$ pre-op to $0.15 \pm 0.154 \text{LogMAR}$ 12-month post-op ($p < 0.001$). Mean CDVA improved from $0.4 \pm 0.41 \text{LogMAR}$ pre-op to $0.0 \pm 0.00 \text{LogMAR}$ 12-month post-op ($p < 0.001$). With respect to UDVA, all treated eyes (100%) showed an improvement of 6 ETDRS lines or more. With respect to CDVA, 9 out of 18 eyes (50%) showed an improvement of 6 ETDRS lines or more. No eyes presented UDVA worse than 1 LogMAR (20/200) at 6 and 12 months postoperatively, compared with 100% preoperatively (Figure 2). No eyes showed a tendency towards hyperopic refraction more than 0.5D. Both subjective refractive astigmatism (SRAST) and keratometric astigmatism (SimK) decreased from baseline values ($p < 0.01$). SRAST decreased from a mean of -5D to -0.62D at 12 months. SimK decreased from a mean of 2.6D to 1D at 12 months. Figure 3 shows the corneal topography of a patient post-operatively. Mean pachymetry changed from $475 \pm 14.9 \mu\text{m}$ to $431 \pm 20.6 \mu\text{m}$ post-operatively ($p < 0.01$) (Table 1). This corresponds to a mean change of $-44 \mu\text{m}$ (ranged from -50 to -39). The actual ablation was less than planned ($54.7 \pm 5.9 \mu\text{m}$; ranged from 44 to 70). Tonometry values remained unchanged throughout the follow-up ($p > 0.05$).

On the last visit, patients were asked about their level of visual satisfaction. The level of satisfaction was assessed with yes/no questions regarding whether treatment had created any improvement or benefit in visual acuity and/or quality of vision. All patients reported an improvement in both visual acuity and quality of vision (Chi-square test, $p < 0.01$).

Table 1 Outcome Measures Measured Before Surgery and at 3 Months, 6 Months, and 12 Months Post-Operatively

| | Baseline n = 18 | 3 Months n = 18 | 6 Months n = 18 | 12 Months n = 18 | P value |
|--------------|----------------------------------|---------------------------------|-------------------------------|-------------------------------------|------------------|
| UDVA | 1 ± 0 (1–1) | 0.17 ± 0.134 (0–0.4) | 0.16 ± 0.121 (0–0.4) | 0.15 ± 0.154 (0–0.3) | <0.001 |
| CDVA | 0.4 ± 0.412 (0–0.8) | 0.06 ± 0.08 (0–0.2) | 0.07 ± 0.04 (0–0.2) | 0.05 ± 0.05 (0–0.1) | <0.001 |
| SEq | -1.87 ± 0.64 (-2.50–1.25) | 0.08 ± 0.22 (-0.25–0.50) | 0.05 ± 0.24 (0–0.50) | 0.05 ± 0.24 (0–0.50) | <0.001 |
| SRAST | -5 ± 0 (-5 – -5) | -0.5 ± 0.51 (-1 – 0) | -0.62 ± 0.64 (-1.25–0) | -0.62 ± 0.64 (-1.25 – -0.25) | <0.01 |
| SimK | 2.6 ± 0.57 (2.1–3.2) | 0.85 ± 0.46 (0.4–1.3) | 0.95 ± 0.26 (0.7–1.2) | 1.00 ± 0.31 (0.7–1.3) | <0.01 |
| CCT | 475 ± 14.9 (461–490) | 431 ± 20.6 (411–451) | 432 ± 24.2 (409–456) | 433 ± 23.2 (411–456) | <0.01 |
| CMI | 30.3 ± 2.46 (27.9–32.3) | 10.1 ± 2.00 (8.1–12.0) | 11.8 ± 2.15 (9.7–13.9) | 11.8 ± 2.09 (9.7–13.8) | <0.01 |

Notes: Values are reported as mean \pm standard deviation (range: minimum value – maximum value). p values were based on the repeated measures ANOVA test. Bold values indicate $p < 0.05$ significant.

Abbreviations: UDVA, uncorrected distance visual acuity (LogMAR); CDVA, corrected distance visual acuity (LogMAR); SEq, spherical equivalent (D); SRAST, subjective refractive astigmatism (D); SIM-K, keratometric astigmatism (D) calculated across the central 3-mm by ray-tracing; CCT, central corneal thickness (μm); CMI, cornea morphological irregularity index (μm).

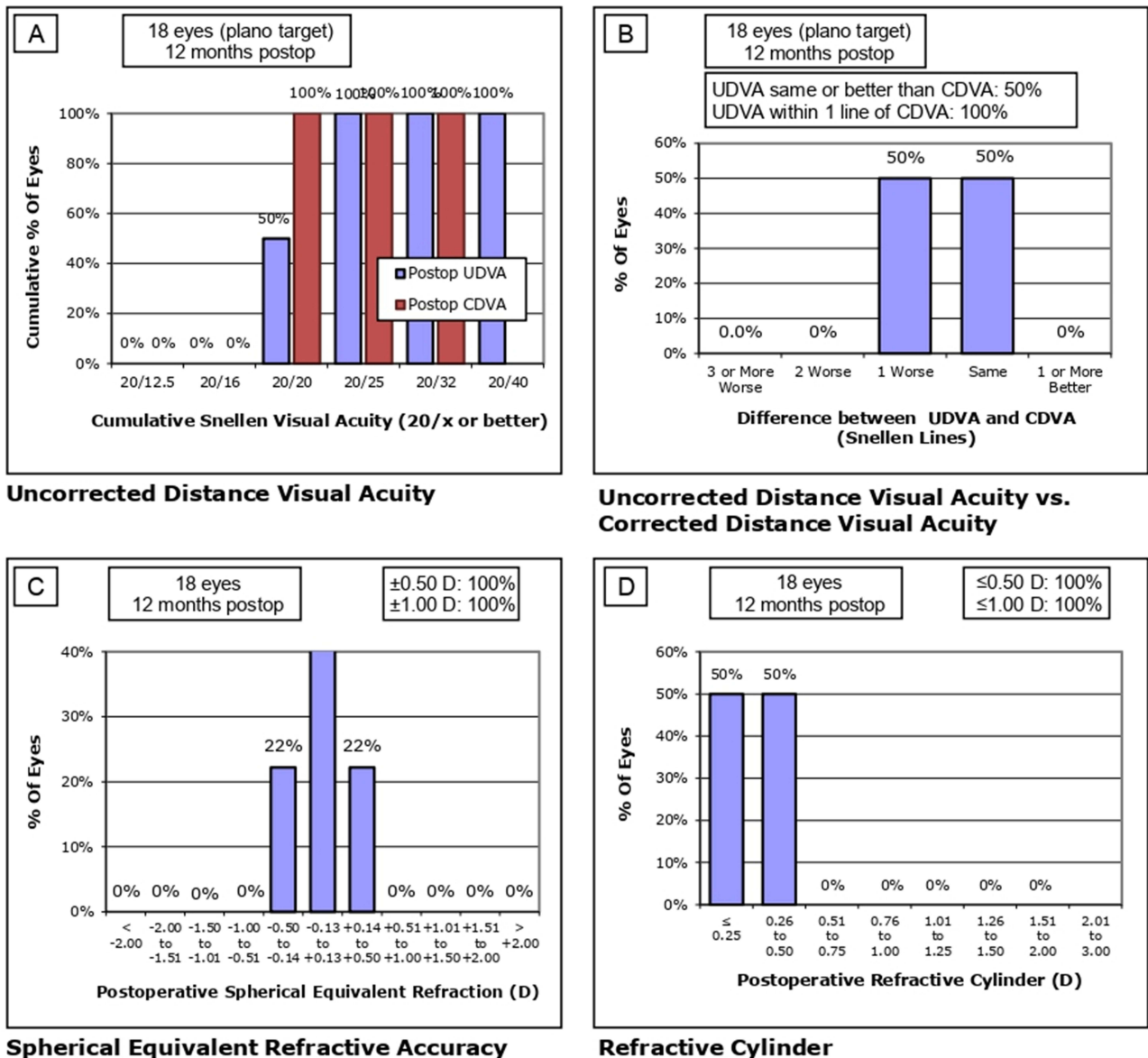


Figure 2 Refractive outcomes after 12 months. (A) Indicates cumulative Snellen visual acuity. (B) Indicates the change in CDVA after surgery. (C) Compares the target and the obtained spherical refraction. (D) Shows the post-operative spherical equivalent refraction.

Discussion

The main purpose of this study was to evaluate the long-term efficacy and safety of customized topography-guided transepithelial PRK to treat persistent and visually-significant corneal opacities secondary to epidemic keratoconjunctivitis (EKC). EKC is one of the most common eye infections worldwide. Adenovirus keratitis classically presents with follicular conjunctivitis and punctate epithelial keratitis. Subepithelial corneal infiltrates develop 1–2 weeks after symptoms begin. These opacities may lead to an irregular cornea, subepithelial opacities that decrease visual acuity and quality of vision, due to high astigmatism, photophobia, glare, halos, and higher-order aberrations (HOAs), that can persist for months and even years.^{2,12} Histopathologic studies of affected cornea samples have shown lymphocytic infiltrates and fibroblasts, without the presence of virus-like particles, restricted to the superficial stroma, Bowman layer, and epithelium.¹³ Adenovirus stromal keratitis is thought to represent a delayed hypersensitivity immune response to viral antigens in the corneal stroma. The corneal stroma may harbor the immunogenic factors that trigger subepithelial infiltrate. For this reason, removing the anterior stroma the risk of recurrence may reduce.¹⁴

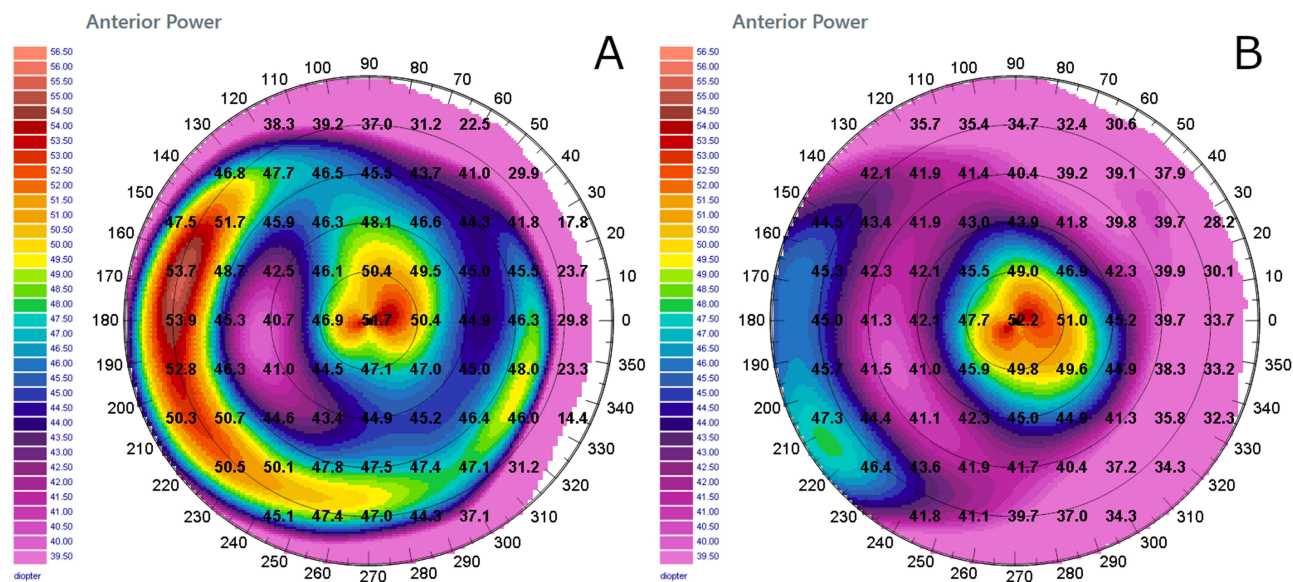


Figure 3 Computerized tomographic images of a 60 year-old female patient (FS.) included in the cohort. **(A)** Preoperative the UDVA was 20/200, and the CDVA 20/100 with a refraction of -5 cyl $\times 180^\circ$. The Corneal Morphological Irregularity Index (CMI) was $32.3\mu\text{m}$ and the keratometric astigmatism (SimK) 3.8D (absolute scale, tangential algorithm). The planned optical zone was 5.65mm with a maximum ablation depth of $65\mu\text{m}$, and an estimated residual pachymetry of $414\mu\text{m}$. **(B)** 12-months following PRK the final postoperative UDVA was 20/25 and the CDVA 20/20 with a refraction of $+0.50$ $\times 40^\circ$. The CMI was $13.8\mu\text{m}$ and the keratometric astigmatism (SimK) was 1.3D. The minimum corneal thickness was $423\mu\text{m}$, $9\mu\text{m}$ thicker than expected. The map's image highlights the improved corneal profile obtained after customized topography-guided transepithelial PRK for treatment of persistent corneal infiltrates following adenovirus infection (absolute scale, tangential algorithm).

Previous studies have evaluated the safety and efficacy of excimer laser PTK for the treatment of anterior corneal opacities and surface irregularities.^{15–17} Excimer laser PTK has been used to treat persistent adenoviral subepithelial corneal opacities with positive results. The 193nm Argon-Fluoride laser photochemically breaks intermolecular bonds, expelling corneal tissue in a controlled manner without causing collateral thermal damage. Ablating and flattening the central cornea leads to a hyperopic shift that is proportional to the ablation depth. Previous studies also reported some degree of induced hyperopia of about 1.52D as measured 12 months post-op.¹⁷ Stark et al have described great variability in the refractive changes following stromal ablations greater than $85\mu\text{m}$.¹⁸ A thinner ablation induces a smaller hyperopic shift.¹⁹

The rationale for choosing a customized topography-guided transepithelial technique is based on the results of previous studies.^{8,20} The corneal epithelium acts as a fluid masking agent. A transepithelial approach allows for elimination of the epithelial thickness variability due to remodeling and refractive outcomes that are more consistent with the predefined refractive target.²¹ The one-step topography-guided transepithelial PRK corrects the epithelial and stromal defects, reduces the risk for post-treatment haze, and leads to a significant improvement in visual acuity.^{22,23} The improvement in visual acuity and quality of vision is related to the correction of both LOAs and HOAs.²³ A customized topography-guided photorefractive keratectomy regularizes the cornea surface, improves the topographic indices, and generally leads to excellent refractive outcomes.^{24,25} Subjects in our study showed no regression throughout the follow-up period. This differs from what has been reported in similar studies (10–15% of treated eyes).²⁶ This might be explained by a customized transition zone with a constant radial slope that minimizes the risk of regression caused by epithelial regrowth. The refractive stability in our cohort may be more solid as compared to other PRK techniques.²⁷ Finally, a reduction of both the refractive defect and total higher-order aberrations was obtained, avoiding secondary astigmatism, as described by other authors.¹²

Yıldırım et al evaluated the long-term visual and refractive outcomes of wavefront-guided transepithelial photorefractive keratectomy with mitomycin-C (MMC) for the treatment of corneal opacities secondary to adenoviral EKC.²⁸ No infiltrate recurrence was observed and the treatment was effective for the purpose of visual rehabilitation. Recently, transepithelial PRK and topical tacrolimus were shown to represent an effective procedure for the treatment of adenoviral EKC, leading to an improvement in visual acuity, corneal densitometry, and corneal HOA.²⁹ Haze is another important long-term complication of

excimer laser ablation and one of the limits of this treatment. Haze development is likely secondary to deposition of irregular collagen fibers by activated keratocytes in the wound.³⁰ Aberrant re-epithelialization can contribute to additional complications, including irregular astigmatism and scarring.^{16,31} In the past, the use of MMC was preferred to reduce scar formation following PTK in EKC patients.^{11,16} MMC modulates collagen synthesis during wound healing. For this reason, treatment with MMC could be beneficial in reducing post-treatment corneal haze and recurrence of EKC infiltrates.^{11,16,32} Recently, Adib-Moghaddam et al evidenced a comparable incidence of post-op haze in eyes with mild to moderate myopia after transepithelial PRK, regardless of MMC use, when total ablation depth was less than 160µm. Moreover, MMC-treated eyes showed worse endothelial cell indices.³³ Studies have shown that haze formation and recurrence of subepithelial infiltrates may occur after PTK.³⁴ However, in our experience, transepithelial PRK without MMC was not complicated by either infiltrate recurrence or haze formation throughout the 12-month follow-up.

Some authors noted adenoviral keratoconjunctivitis reactivation after excimer laser refractive surgery in some patients. Successful resolution of recurrent late-developing EKC-like keratitis was achieved through the use of topical steroids, with good clinical and visual outcomes. Corneal infiltrates were presumed to represent an immune response to adenoviral antigens deposited within the corneal stroma during the primary adenoviral infection.^{5,26} In the current study, enrolled eyes had been treated with topical steroids for at least 6 months. Despite prolonged treatment, these visually-significant corneal infiltrates failed to resolve. In such cases, corneal opacities and disabling visual symptoms can persist for years. All recruited subjects were complaining of photophobia and poor quality of vision prior to enrollment. After excimer laser treatment, all patients showed a significant improvement in visual acuity, quality of vision, as well as a decrease in photophobia. Laser treatment smoothed out the cornea surface and improved its transparency. No side effects were reported and all corneas remained transparent and free of EKC infiltrates throughout the 12-month follow-up.

Conclusion

Epidemic kerato-conjunctivitis is often characterized by the presence of bilateral corneal infiltrates and conjunctivitis. When these infiltrates are located centrally, visual acuity can be severely affected. This condition responds favorably to topical therapy in most patients. The corneal infiltrates resolve and the visual acuity returns to baseline values. However, in rare cases, the corneal infiltrates might persist or recur after therapy is discontinued, and visual acuity might be permanently affected. The etiology for the decrease in visual acuity is two-fold: the presence of anterior stromal opacities as well as the anterior surface irregularity. In this study, authors explored the efficacy of topography-guided transepithelial photo-refractive keratectomy in restoring visual acuity in this subset of patients. The results in terms of improvement in visual acuity, disease recurrence, and safety were excellent. For this reason, topography-guided transepithelial PRK should be considered as an effective treatment modality in patients with persistent and visually-significant corneal infiltrates due to EKC that do not respond to topical therapy.

Funding

This research did not receive any specific grant from funding agencies in the public, commercial, or not-for-profit sectors.

Disclosure

The authors report no conflicts of interest in this work.

References

1. Jhanji V, Chan TCY, Li EYM, Agarwal K, Vajpayee RB. Adenoviral keratoconjunctivitis. *Surv Ophthalmol*. 2015;60:435–443. doi:10.1016/j.survophthal.2015.04.001
2. Chodosh J, Miller D, Stroop WG, Pflugfelder SC. Adenovirus epithelial keratitis. *Cornea*. 1995;14(2):167–174. doi:10.1097/00003226-199503000-00010
3. Fagerholm P. Phototherapeutic keratectomy: 12 years of experience. *Acta Ophthalmol Scand*. 2003;81(1):19–32. doi:10.1034/j.1600-0420.2003.00015.x
4. Kapasi M, Baath J, Mintsioulis G, Jackson WB, Baig K. Phototherapeutic keratectomy versus mechanical epithelial removal followed by corneal collagen crosslinking for keratoconus. *Can J Ophthalmol*. 2012;47(4):344–347. doi:10.1016/j.jcjo.2012.03.046

5. Jabbur NS, O'Brien TP. Recurrence of keratitis after excimer laser keratectomy. *J Cataract Refract Surg.* 2003;29(1):198–201. doi:10.1016/S0886-3350(02)01365-2
6. Starr MB. Recurrent subepithelial corneal opacities after excimer laser phototherapeutic keratectomy. *Cornea.* 1999;18(1):117–120. doi:10.1097/00003226-199901000-00018
7. Amm M, Duncker GI. Refractive changes after phototherapeutic keratectomy. *J Cataract Refract Surg.* 1997;23:839–844. doi:10.1016/S0886-3350(97)80240-4
8. Spadea L, Bianco G, Balestrazzi E. Topographically guided excimer laser photorefractive keratectomy to treat superficial corneal opacities. *Ophthalmology.* 2004;111:458–462. doi:10.1016/j.ophtha.2003.06.002
9. Alessio G, Boscia F, La Tegola MG, Sborgia C. Topography-driven excimer laser for the retreatment of decentralized myopic photorefractive keratectomy. *Ophthalmology.* 2001;108(9):1695–1703. doi:10.1016/S0161-6420(01)00706-0
10. Fite SW, Chodosh J. Photorefractive keratectomy for myopia in the setting of adenoviral subepithelial infiltrates. *Am J Ophthalmol.* 1998;126:829–831. doi:10.1016/S0002-9394(98)00224-4
11. Alevi D, Barsam A, Kruh J, Prince J, Perry HD, Donnenfeld ED. Photorefractive keratectomy with mitomycin-C for the combined treatment of myopia and subepithelial infiltrates after epidemic keratoconjunctivitis. *J Cataract Refract Surg.* 2012;38(6):1028–1033. doi:10.1016/j.jcrs.2011.12.039
12. Kepez Yildiz B, Urvasizoglu S, Yildirim Y, et al. Changes in higher-order aberrations after phototherapeutic keratectomy for subepithelial corneal infiltrates after epidemic keratoconjunctivitis. *Cornea.* 2017;36(10):1233–1236. doi:10.1097/ICO.0000000000001296
13. Lund OE, Stefani FH. Corneal histology after epidemic keratoconjunctivitis. *Arch Ophthalmol.* 1978;96(11):2085–2088. doi:10.1001/archophth.1978.03910060465016
14. Campos M, Nielsen S, Szerenyi K, Garbus JJ, McDonnell PJ. Clinical follow-up of phototherapeutic keratectomy for treatment of corneal opacities. *Am J Ophthalmol.* 1993;115(4):433–440. doi:10.1016/S0002-9394(14)74443-5
15. Moniz N, Fernandez ST. Efficacy of phototherapeutic keratectomy in various superficial corneal pathologies. *J Refract Surg.* 2003;19(2):S243–S246. doi:10.3928/1081-597X-20030302-15
16. Yamazaki ES, Ferraz CA, Hazarbasanov RM, Allemann N, Campos M. Phototherapeutic keratectomy for the treatment of corneal opacities after epidemic keratoconjunctivitis. *Am J Ophthalmol.* 2011;151(1):35–43.e1. doi:10.1016/j.ajo.2010.07.028
17. Fagerholm P, Fitzsimmons TD, Orndahl M, Ohman L, Tengroth B. Phototherapeutic keratectomy: long-term results in 166 eyes. *Refract Corneal Surg.* 1993;9(2 Suppl):S76–S81.
18. Stark WJ, Chamon W, Kamp MT, Enger CL, Rencs EV, Gottsch JD. Clinical follow-up of 193-nm ArF excimer laser photokeratectomy. *Ophthalmology.* 1992;99(5):805–812. doi:10.1016/S0161-6420(92)31896-2
19. Chow AMM, Yiu EPF, Hui MK, Ho CK. Shallow ablations in phototherapeutic keratectomy: long-term follow-up. *J Cataract Refract Surg.* 2005;31:2133–2136. doi:10.1016/j.jcrs.2005.03.079
20. Dausch D, Schröder E, Dausch S. Topography-controlled excimer laser photorefractive keratectomy. *J Refract Surg.* 2000;16(1):13–22. doi:10.3928/1081-597X-20000101-03
21. Spadea L, Visioli G, Mastromarino D, Alexander S, Pistella S. Topography-guided trans-epithelial no-touch photorefractive keratectomy for high irregular astigmatism after penetrating keratoplasty: a prospective 12-months follow-up. *Ther Clin Risk Manag.* 2021;17:1027–1035. doi:10.2147/TCRM.S329932
22. Adib-Moghaddam S, Soleyman-Jahi S, Tefagh G, Tofghi S, Grentzelos MA, Kymionis GD. Comparison of single-step transepithelial photorefractive keratectomy with or without mitomycin C in mild to moderate myopia. *J Refract Surg.* 2018;34(6):400–407. doi:10.3928/1081597X-20180402-02
23. Oliveira RF, Ferreira GA, Ghanem VC, Corrêa-Dantas PE, Ghanem RC. Transepithelial surface ablation with mitomycin C for the treatment of chronic central corneal scars following adenoviral keratoconjunctivitis. *J Refract Surg.* 2020;36(1):55–61. doi:10.3928/1081597X-20191203-01
24. Sorkin N, Einan-Lifshitz A, Abelson S, et al. Stepwise guided photorefractive keratectomy in treatment of irregular astigmatism after penetrating keratoplasty and deep anterior lamellar keratoplasty. *Cornea.* 2017;36(11):1308–1315. doi:10.1097/ICO.0000000000001359
25. Ghoreishi M, Naderi beni A, Naderi Beni Z. Visual outcomes of topography-guided excimer laser surgery for treatment of patients with irregular astigmatism. *Lasers Med Sci.* 2014;29(1):105–111. doi:10.1007/s10103-013-1282-9
26. Kuo IC, Lee SM, Hwang DG. Late-onset corneal haze and myopic regression after photorefractive keratectomy (PRK). *Cornea.* 2004;23(4):350–355. doi:10.1097/00003226-200405000-00007
27. Mulè G, Chen S, Zhang J, et al. Central corneal regularization (CCR): an alternative approach in keratoconus treatment. *Eye Vis.* 2019;6(1):40. doi:10.1186/s40662-019-0165-y
28. Yıldırım Y, Akbaş YB, Tunç U, et al. Visual rehabilitation by using corneal wavefront-guided transepithelial photorefractive keratectomy for corneal opacities after epidemic keratoconjunctivitis. *Int Ophthalmol.* 2021;41(6):2149–2156. doi:10.1007/s10792-021-01772-7
29. Elhamaky TR. Pentacam corneal densitometry-guided treatment of adenoviral corneal subepithelial infiltrates: a comparative study between transepithelial phototherapeutic keratectomy and topical tacrolimus. *Int Ophthalmol.* 2021;41(1):67–77. doi:10.1007/s10792-020-01553-8
30. Spadea L, Giammaria D, Trabucco P. Corneal wound healing after laser vision correction. *Br J Ophthalmol.* 2016;100(1):28–33. doi:10.1136/bjophthalmol-2015-306770
31. Spadea L, Giovannetti F. Main complications of photorefractive keratectomy and their management. *Clin Ophthalmol.* 2019;29:2305–2315. doi:10.2147/OPHTH.S233125
32. Spadea L, Verrecchia V. Effectiveness of scraping and mitomycin C to treat haze after myopic photorefractive keratectomy. *Open Ophthalmol J.* 2011;5:63–65. doi:10.2174/1874364101105010063
33. Adib-Moghaddam S, Soleyman-Jahi S, Salmanian B, et al. Single-step transepithelial photorefractive keratectomy in myopia and astigmatism: 18-month follow-up. *J Cataract Refract Surg.* 2016;42(11):1570–1578. doi:10.1016/j.jcrs.2016.08.029
34. Nagpal R, Maharana PK, Roop P, et al. Phototherapeutic keratectomy. *Surv Ophthalmol.* 2020;65(1):79–108. doi:10.1016/j.survophthal.2019.07.002

Therapeutics and Clinical Risk Management

Dovepress

Publish your work in this journal

Therapeutics and Clinical Risk Management is an international, peer-reviewed journal of clinical therapeutics and risk management, focusing on concise rapid reporting of clinical studies in all therapeutic areas, outcomes, safety, and programs for the effective, safe, and sustained use of medicines. This journal is indexed on PubMed Central, CAS, EMBase, Scopus and the Elsevier Bibliographic databases. The manuscript management system is completely online and includes a very quick and fair peer-review system, which is all easy to use. Visit <http://www.dovepress.com/testimonials.php> to read real quotes from published authors.

Submit your manuscript here: <https://www.dovepress.com/therapeutics-and-clinical-risk-management-journal>