

BIS Brazilian Dental Science

25th Jubilee



Source: macrovector/Freepik



A radiation free alternative to CBCT volumetric rendering for soft tissue evaluation

Um método alternativo à TCFC sem radiação ionizante para a avaliação de tecidos moles da face

Giovanna PERROTTI¹ , Rodolfo REDA^{2,3} , Ornella ROSSI¹ , Isabella D'APOLITO⁴ ,
Tiziano TESTORI^{1,5,6,7} , Luca TESTARELLI^{2,3}

1 - Lake Como Institute, Como, Italia.

2 - Sapienza Università di Roma, Dipartimento di Scienze Odontomatologiche e Maxillo Facciali, Roma, Italia.

3 - Saveetha Institute of Medical and Technical Sciences, Department of Prosthodontics and Implantology, Saveetha Dental College and Hospitals. Chennai, India.

4 - Università Cattolica del Sacro Cuore, School of Dentistry. Rome, Italy.

5 - IRCCS Istituto Ortopedico Galeazzi, Clinica Odontoiatrica, Sezione di Implantologia e Riabilitazione Orale. Milano, Italia.

6 - Università degli Studi di Milano, Dipartimento di Scienze Biomediche, Chirurgiche e Odontoiatriche. Milano, Italia.

7 - University of Michigan, School of Dentistry, Department of Periodontics and Oral Medicine. Ann Arbor, MI, USA.

How to cite: Perrotti G, Reda R, Rossi O, D'Apolito I, Testori T, Testarelli L. A radiation free alternative to CBCT volumetric rendering for soft tissue evaluation. *Braz Dent Sci.* 2023;26(1):e3726. <https://doi.org/10.4322/bds.2023.e3726>

ABSTRACT

Objective: The aim of the present study is to evaluate whether a “radiation free” method using 3D facial scan can replace Cone Beam Computed Tomography (CBCT) volumetric rendering of soft tissue of the patient to assess maxillofacial surgery outcomes and compare the reference points and angular measurements of patient facial soft tissue. **Material and Methods:** Facial soft tissue scan of the patient’s face, before and after orthognathic surgery and a CBCT of the skull for volumetric rendering of soft tissues were carried out. The 3D acquisitions were processed using Planmeca ProMax 3D ProFace® software (Planmeca USA, Inc.; Roselle, Illinois, USA). The participant were positioned in a natural position during the skull scanning. Three sagittal angular measurements were performed (Tr-NA, Tr-N-Pg, Ss-N-Pg) and two verticals (Go-N-Me, Tr-Or-Pg) on facial soft tissue scan and on the patient’s 3D soft tissue CBCT volumetric rendering. **Results:** A certain correspondence has been demonstrated between the measurements obtained on the Proface and those on the CBCT. **Conclusion:** A radiation free method was to be considered an important diagnostic tool that works in conditions of not subjecting the patient to harmful ionizing radiation and it was therefore particularly suitable for growing subjects. The soft tissue analysis based on the realistic facial scan has shown sufficient reliability and reproducibility even if further studies are needed to confirm the research result.

Keywords

CBCT; Ionizing radiation; Soft tissue; Orthodontics; Diagnosis.

RESUMO

Objetivo: Avaliar se um método “livre de radiação” usando escaneamento facial 3D pode substituir a renderização volumétrica da tomografia computadorizada de feixe cônico (TCFC) dos tecidos moles do paciente para analisar os resultados da cirurgia maxilofacial e comparar os pontos de referência e medições angulares afim de avaliar a correspondência entre as duas metodologias. **Material e Métodos:** Foi realizado o escaneamento dos tecidos moles faciais do paciente, antes e depois da cirurgia ortognática e uma tomografia computadorizada de feixe cônico do crânio para renderização volumétrica dos tecidos moles. As aquisições 3D foram processadas usando o software Planmeca ProMax 3D ProFace® (Planmeca USA, Inc.; Roselle, Illinois, USA). O participante foi posicionado em posição natural durante o escaneamento do crânio. Três medições angulares sagitais foram realizadas (Tr-NA,

Tr-N-Pg, Ss-N-Pg) e duas verticais (Go-N-Me, Tr-Or-Pg) nas imagens de scaneamento e nas imagens do tecido mole facial da reconstrução tridimensional da TCFC. **Resultados:** Uma certa correspondência foi demonstrada entre as medidas obtidas no Proface® e aquelas na TCFC. **Conclusão:** Um método livre de radiação deve ser considerado uma importante ferramenta de diagnóstico que funciona em condições de não submeter o paciente a radiação ionizante nociva e, portanto, é particularmente adequado para indivíduos em crescimento. A análise de tecidos moles com base na varredura facial realista mostrou confiabilidade e reprodutibilidade, porém mais estudos são necessários para confirmar o resultado da pesquisa.

PALAVRAS-CHAVE

Ortodontia; Radiação não ionizante; Tecidos moles; Tomografia computadorizada de feixe cônico; Diagnóstico.

INTRODUCTION

Originally, the orthodontic diagnosis was conducted through the evaluation of the hard tissues, skeleton and teeth, on the basis of the lateral telerradiograph and the dental cast [1].

Starting with Tweed, all the major 2D cephalometries presented mainly one aesthetic parameter of soft tissue which considers the relationship between nose, lips and chin but always on a bidimensional sagittal prospective [2,3].

In the late 1990s Arnett and co. strongly criticized cephalometric analyzes that focused the treatment plan mainly on hard tissue parameters. Arnett advocated what interests the patient is not the ideal skeletal and dental ratio, but a series of aesthetic-morphometric parameters based on the quality of the soft tissues, which however could mask serious conditions of malocclusion or skeletal discrepancy [4-6].

The increasing desire in the last few years to improve patients' facial appearance had placed aesthetics as the first treatment objective for orthodontists and maxillo-facial surgeons who had as obligation the maintenance or improvement of facial aesthetic parameters [7].

Therefore, the assessment of facial morphology has found a greater interest among clinicians and the precise and detailed evaluation of soft tissues has become more and more relevant [8].

Furthermore, it has been demonstrated that patients as well as their friends and relatives evaluate the result of the orthodontic and orthognathic treatment on the perceived changes in the face [9].

This great interest in non-invasive methods has led to the development of new imaging

tools that can improve the role of soft tissue in diagnosis [4,5].

A full assessment of the three-dimensional shape, size and proportions of the facial soft tissues must therefore be considered as a decisive step in the orthodontic diagnosis.

The possibility of studying facial features using non-invasive 3D radiographic systems, such as laser surface scanning, multi-image photogrammetry, stereo-photogrammetry or by the recent 3D facial photography technique had become concrete. Furthermore, facial surface could be appreciated and obtained through the 3D rendering of soft tissues from the face starting from the Digital Imaging and COmmunications in Medicine (DICOM) files of a skull scan.

These recent methods offered several benefits, including speed of data collection, data retention and management, accuracy and reliability [6-10].

It is necessary to underline how important a reproducible head position is during images acquisition. However, the difficulty encountered in reliably performing facial acquisition was likely responsible for the secondary role of soft tissue analysis in supportive diagnosis compared to skeletal analysis [10,11].

However, there were also complications related to the appropriate use of equipment and software as well as the absence of reliable norm values for 3D measurements of facial soft tissues, which requires further study.

Several analyzes have been proposed in the past for the facial soft tissue evaluation. Most include photographic images from a lateral point of view [7,12]. Some authors also proposed the evaluation of soft tissues using frontal images [10,11]. However, 3d facial scan allowed to better appreciate soft tissues from every

perspective, identify reference points and carrying out measurements in three dimensions [13,14], make a precise analysis of facial soft tissues and collect patient data and information over time.

To the authors' knowledge, to date, no studies comparing soft tissue changes between 3D facial scan images and that obtain from a CBCT 3D rendering have been reported. The aim of the present study is to compare the values obtained from the facial scan with that obtained from a 3D rendering obtained from a CBCT of the same patient in order understand if they are overlapping.

MATERIALS AND METHODS

A clinical case of a patient with severe facial asymmetry and undergoing combine orthodontic-surgical treatment is shown.

As protocol for surgical cases, a CBCT with Planmeca Viso® G7 (Planmeca USA, Inc.; Roselle, Illinois, USA) with hard and soft tissue of the patient is taken and, furthermore, a 3D soft tissue facial scan of the patient with Planmeca ProMax 3D ProFace® (Planmeca USA, Inc.; Roselle, Illinois, USA), before and after orthognatic surgery (Figure 1A-B).

Ethical approval has not been required for this type of study. The CBCT and the facial scan of the patient have been required by the maxillofacial surgeon in order to plan the surgery. The patient, adequately informed of the risks and benefits of radiographic investigations, has deliberately signed the consent to perform the CBCT and the facial scan and to use the data for the purposes of scientific research.

The facial soft tissue scan was made with Planmeca ProMax 3D ProFace®, which produces a realistic 3D image of the face (Figure 2A-B).

The photographs were acquired using the ProFace option, which does not require radiation.

This system relies on lasers able to scan facial geometry and some digital cameras, which capture texture and color. The sensor is composed of two laser lights, two digital cameras and two light-emitting diodes.

The spatial accuracy of this device is 0.03mm (as reported by the manufacturer). During the acquisition of the image, the patient's head lay in the natural position, the face presented a neutral

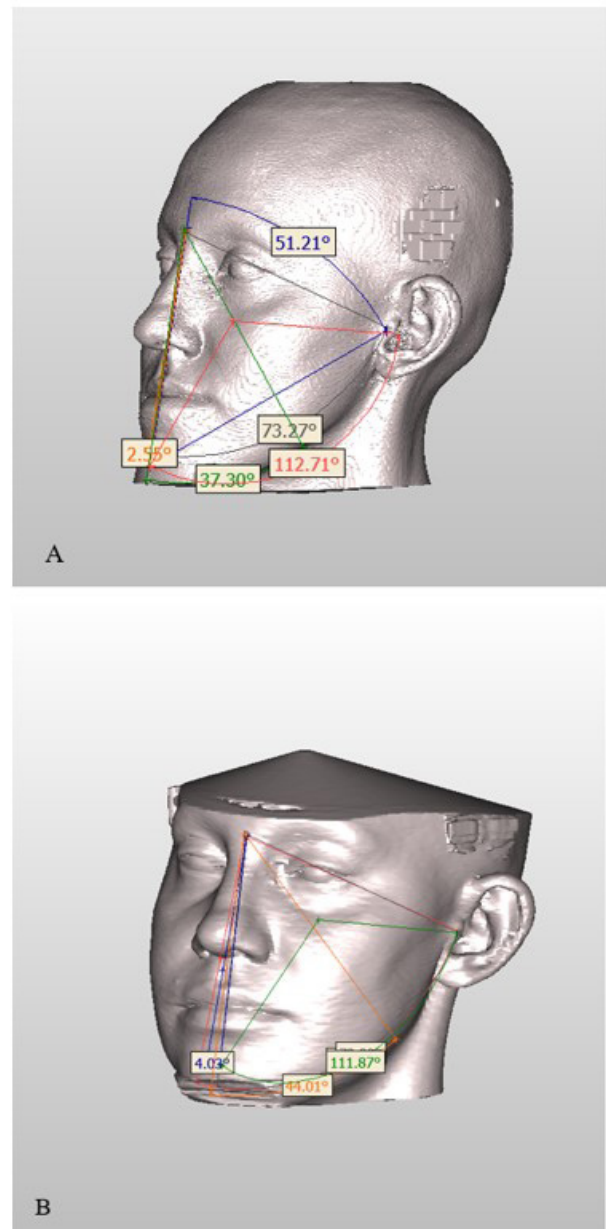


Figure 1 - A: Rendering 3D Soft Tissue Pre-surgery; B: Rendering 3D Post Surgery

expression, the jaw was in a resting position as well as the lips in the absence of excessive muscular effort.

Taking up the scientific work carried out by Zecca et al. [15], the same reference points were used for the cephalometric analysis of soft tissues but only some angular measurements used by them. Specifically, three sagittal angular measurements (Tr-N-A, Tr-N-Pg, Ss-N-Pg) and two vertical ones (Go-N-Me, Tr-Or-Pg) were selected to obtain a good anatomical correspondence between hard and soft tissue.

These measurements were taken both on the facial soft tissue scan of the face thanks to

Romexis software which allow to take linear and angular measurements and on the CBCT soft tissues volume rendering with SimPlant O&O by Materialise Dental. Version: 3.0.

RESULTS

The aim of the present study is to analyze whether the measurements made on the 3D face foto obtained with Proface are correlated with patient's CBCT soft tissues 3D rendering, before and after surgical treatment. The sequence of the same measurements has been taken.

Figure 2A show the measurements made on the Planmeca ProMax 3D ProFace® software

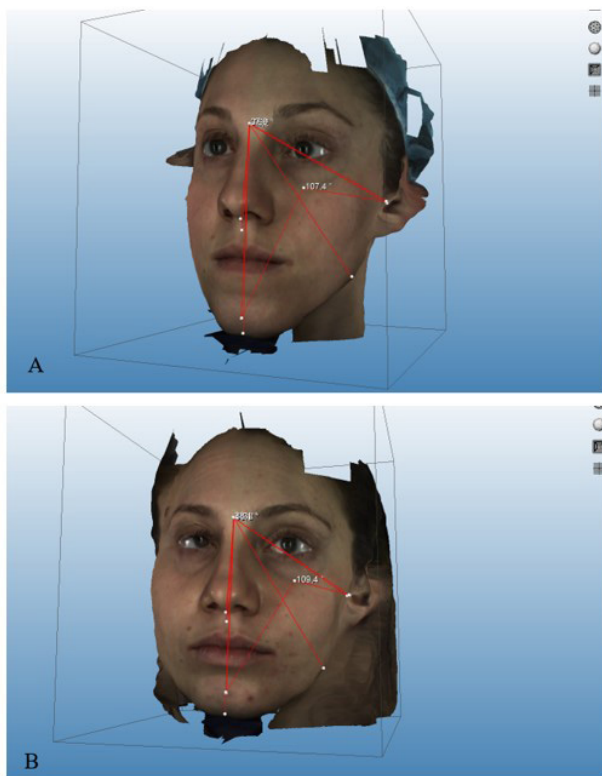


Figure 2 - A: Proface Pre Surgery; B: Proface Post Surgery

and on the patient's pre-treatment 3D soft tissues rendering respectively.

Figure 2B show the measurements made on the Planmeca ProMax 3D ProFace® software and on the patient's post -surgery 3D soft tissues rendering.

The measurements have been reported in Table I.

Figure 1A-B show the measurement of soft tissue on CBCT volumetric rendering before and after patient's surgery.

As can be seen from the results obtained, a correspondence between the measurements performed on the Planmeca ProMax 3D ProFace® software and those on the patient's CBCT soft tissues rendering, in accordance with the orthodontic-surgical treatment performed was obtained.

DISCUSSION

Thanks to the advent of 3D facial scan, it is possible to better appreciate soft tissues from every perspective and in three dimensions, identifying reference points and carrying out angular and linear measurements [13,14]. It is so possible to do a precise analysis of facial soft tissues and collect data and information of the patient over time.

The role of facial soft tissue assessment is becoming increasingly important in orthodontic diagnosis and treatment planning, especially in patients undergoing maxillo-facial surgery [16].

The treatment effects on soft tissue profile when managing the underling dental and skeletal changes to estimate facial and occlusal improvements must be kept under control [15,16].

Table I - Proface and Soft-Tissue CBCT angular measurements, pre- and post-surgery, of the followers parameters: Tr-N-Subnasal, Tr-N-Pg, Sspinal-N-Pg, Go-N-Me, Tr-Or-PG (Tr=trichion), N= Nasion, Sn=subnasal, Pg= Pogonion, Sp=Subspinale, Go= Gonio,n Me=Menton, Or= Orbitale)

Measurements	Proface and Soft-Tissue CBCT Rendering 3D			
	Proface		CBCT Soft Tissue	
	Pre-Surgery (°)	Post-Surgery (°)	Pre-Surgery (°)	Post-Surgery (°)
Tr-N-Sn	76.20	75.20	79.92	73.27
Tr-N-Pg	70.00	66.80	73.89	51.21
Sp-N-Pg	2.50	4.30	4.30	2.55
Go-N-Me	37.90	38.10	44.01	37.30
Tr-Or-Pg	107.40	109.40	111.87	112.71

A truthful evaluation of the treatment outcome is made possible through out a radiation free method based on 3D Facial Scan.

The analysis of 3D Facial Scan can be objectified through linear and angular measurements performed on the scan. From our results, no significant differences between 3D facial scan of the patient and CBCT soft tissues volumetric rendering has been seen.

This could suggest an alternative non-radiogenic method, especially useful in those situations where radiation should be further reduced (children and patients with radiation correlated risk) [17].

When possible, the clinician have to reduce the radiogenic load in patients and efficiently use other tools available to elaborate a correct diagnosis. 3D facial scan is one of these tools that should be correlated and implemented with further measurement and comparison system. The outcomes of a surgical and orthognatic treatment should be seen more on the aesthetic result of soft tissues that reflect the new positioning of the bones.

The 3D Facial Scan method offers several advantages over conventional (non-3D) photography, considering the possibility of obtaining 3D images and reliability to perform facial analysis [8].

Several techniques for obtaining digital images have been proposed over the years. The possibility of adequately reproducing tissue landmarks and therefore making these measurements reproducible is extremely important. The use of laser scans and stereophotogrammetry (both non-invasive and non-ionizing) have gained most favor in the orthodontic literature [12].

Laser scanning is a non-invasive 3D facial images acquisition method and has been successfully applied in studies of treatment outcome and relapse [12].

Facial soft tissue analysis, taking into account skeletal morphology or occlusal orthodontic treatments, is assuming an increasingly important role in orthodontic diagnosis and treatment planning. Therefore, having the ability to diagnose and monitor soft tissue analysis over time allows us to have a source of diagnostic information and treatment outcome evaluation [15].

The growing interest in non-invasive diagnostic examinations by the clinicians and the growing request of aesthetic improvement by the laypersons are the reason why attention to soft tissue has increased in recent years. Nevertheless, one of the difficulties of planning soft tissue analysis is perhaps dictated by the fact that great importance has been given to hard tissue analysis for orthodontic purposes in the recent past [10,11]. The limits of facial examination include costs for the machines, difficulty in handing, technique-sensitive difficulties when capturing the deeper tissues, and rendering [18]. A limitation of facial scanning and 3D rendering of soft tissues from CBCT is the difficulty to effectively detect the surface of a patient's face without there being image distortion. Even the slightest movement by the patient or the compression of some facial areas (chin, forehead, ears, cheeks) greatly alters the final result. To date, there is no an effective system to block the patient's head without compressing the soft structures of the face. Despite limitations in scan quality and software operation, 3D facial scanners are rapid and non-invasive tools that can be utilized in multiple facets of facial and dental care [19].

Non-invasive diagnostic examination could be of great importance in orthodontic diagnosis and for orthodontic treatment follow-up, making further radiological exams prescribed only when needed [15]. Furthermore, this can also allow for a more adequate evaluation of the soft tissues, allowing the noble structures adjacent to the sites to be treated to be isolated and protected in the treatment plans [20,21].

Even today, the most described follow-up exam is a lateral cephalometric radiograph, although this only allows for the verification of a linear, vertical, and anteroposterior progression of facial change, always and exclusively in two-dimensions. For the type of acquisition of the lateral projection image, no depth or specific orientation of landmarks can be revealed. The aforementioned limits have been overcome in recent years, considering radiation-free 3D imaging or with reduced exposure to ionizing radiation for the analysis of hard and soft tissues [22,23].

With these acquisitions it is possible to monitor the 3D changes of the facial profiles. The possibility of working on data in 3D rather

than 2D allows to obtain even more information, as also underlined in other recently published studies [24,25].

Therefore, the previous considerations lead us to state that the best way to describe the facial changes that occur after orthognathic treatment requires the use of an imaging system that captures the facial anatomy in its complexity [26-28].

CONCLUSIONS

The present soft tissue analysis proposal based on 3D facial scans has shown good reliability and reproducibility although further studies are needed to confirm the search result. Radiation free methods to perform cephalometric tracings on soft tissues should be able to become an increasingly predictable method in order to reduce the radiogenic load to which the orthodontic patient is subjected. The use of 3D images without the support of a numerical evaluation scheme and standard values for comparison and diagnosis make these devices less widespread while for objective necessity, conventional radiological systems or CBCT continue to be used even in non-elective situations.

The combination of intraoral scans and a radiation free cephalometry may represent the future of the diagnostic approach in orthodontics. The future of digital scanning is expected to involve wide availability of scanners at lower costs with high quality and accuracy for various dental and medical applications.

Author's Contributions

GP: Conceptualization, resources, writing—original draft preparation. RR: Validation, writing—review and editing. OR: Conceptualization, software, investigation, data curation. IA: Methodology, formal analysis, writing—original draft preparation. TT: Validation, writing—review and editing, supervision. LT: Validation, visualization.

Conflict of Interest

The authors have no proprietary, financial, or other personal interest of any nature or kind in any product, service, and/or company that is presented in this article.

Funding

This research received no external funding.

Regulatory Statement

Ethical approval has not been required for this type of study. The CBCT and the facial scan of the patient has been required by the maxillofacial surgeon in order to plan the surgery. The patient, adequately informed of the risks and benefits of radiographic investigations, has deliberately signed the consent to perform the CBCT and the facial scan and to use the data for the purposes of scientific research.

REFERENCES

1. Kau CH, Zhurov AI, Scheer R, Bouwman S, Richmond S. The feasibility of measuring three-dimensional facial morphology in children. *Orthod Craniofac Res.* 2004;7(4):198-204. <http://dx.doi.org/10.1111/j.1601-6343.2004.00289.x>. PMID:15562582.
2. Ricketts RM. Perspectives in the clinical application of cephalometrics. The first fifty years. *Angle Orthod.* 1981;51(2):115-50. PMID:6942666.
3. Gruppo Editoriale Cadmos. Cephalometry by the tweed technic. *Dent Press.* 1970;6(6):11-3 PMID: 5287854.
4. Arnett GW, Bergman RT. Facial keys to orthodontic diagnosis and treatment planning. Part I. *Am J Orthod Dentofacial Orthop.* 1993;103(4):299-312. [http://dx.doi.org/10.1016/S0889-5406\(93\)70010-L](http://dx.doi.org/10.1016/S0889-5406(93)70010-L). PMID:8480695.
5. Arnett GW, Bergman RT. Facial keys to orthodontic diagnosis and treatment planning. Part II. *Am J Orthod Dentofacial Orthop.* 1993;103(5):395-411. [http://dx.doi.org/10.1016/S0889-5406\(05\)81791-3](http://dx.doi.org/10.1016/S0889-5406(05)81791-3). PMID:8480709.
6. Fastuca R, Beccarini T, Rossi O, Zecca PA, Caprioglio A. Influence of facial components in class III malocclusion esthetic perception of orthodontists, patients, and laypersons. *J Orofac Orthop.* 2022;83(1):48-58. <http://dx.doi.org/10.1007/s00056-021-00287-1>. PMID: 33929556.
7. Deli R, Gioia ED, Galantucci LM, Percoco G. Accurate facial morphologic measurements using a 3-camera photogrammetric method. *J Craniofac Surg.* 2011;22(1):54-9. <http://dx.doi.org/10.1097/SCS.0b013e3181f6c4a1>. PMID:21187775.
8. Menéndez López-Mateos ML, Carreño-Carreño J, Palma JC, Alarcón JA, Menéndez López-Mateos C, Menéndez-Núñez M. Three-dimensional photographic analysis of the face in European adults from southern Spain with normal occlusion: reference anthropometric measurements. *BMC Oral Health.* 2019;19(1):196. <http://dx.doi.org/10.1186/s12903-019-0898-y>. PMID:31462244.
9. Bishara SE, Cummins DM, Jorgensen GJ, Jakobsen JR. A computer assisted photogrammetric analysis of soft tissue changes after orthodontic treatment. Part I: methodology and reliability. *Am J Orthod Dentofacial Orthop.* 1995;107(6):633-9. [http://dx.doi.org/10.1016/S0889-5406\(95\)70107-9](http://dx.doi.org/10.1016/S0889-5406(95)70107-9). PMID:7771369.
10. Dong Y, Zhao Y, Bai S, Wu G, Zhou L, Wang B. Three-dimensional anthropometric analysis of chinese faces and its application in evaluating facial deformity. *J Oral Maxillofac Surg.* 2011;69(4):1195-206. <http://dx.doi.org/10.1016/j.joms.2010.05.023>. PMID:21050632.

11. Karatas OH, Toy E. Three-dimensional imaging techniques: a literature review. *Eur J Dent.* 2014;8(1):132-40. <http://dx.doi.org/10.4103/1305-7456.126269>. PMID:24966761.
12. Gwilliam JR, Cunningham SJ, Hutton T. Reproducibility of soft tissue landmarks on three-dimensional facial scans. *Eur J Orthod.* 2006;28(5):408-15. <http://dx.doi.org/10.1093/ejo/cjl024>. PMID:16901962.
13. Othman SA, Ahmad R, Mericant AF, Jamaludin M. Reproducibility of facial soft tissue landmarks on facial images captured on a 3D camera. *Aust Orthod J.* 2013;29(1):58-65. PMID:23785939.
14. Brons S, van Beusichem ME, Bronkhorst EM, Draaisma J, Berge SJ, Maal TJ, et al. Methods to quantify soft-tissue based facial growth and treatment outcomes in children: a systematic review. *PLoS One.* 2012;7(8):e41898. <http://dx.doi.org/10.1371/journal.pone.0041898>. PMID:22879898.
15. Zecca PA, Fastuca R, Beretta M, Caprioglio A, Macchi A. Correlation assessment between three-dimensional facial soft tissue scan and lateral cephalometric radiography in orthodontic diagnosis. *Int J Dent.* 2016;2016:1473918. <http://dx.doi.org/10.1155/2016/1473918>. PMID:27313615.
16. Kilib N, Catal G, Kiki A, Oktay H. Soft tissue profile changes following maxillary protraction in Class III subjects. *Eur J Orthod.* 2010;32(4):419-24. <http://dx.doi.org/10.1093/ejo/cjp119>. PMID:20053719.
17. Beretta M, Federici Canova F, Zaffarano L, Gianolio A. Face Scan for Ceph 3D: a green way for diagnosis in children. *Eur J Paediatr Dent.* 2022;23(3):201-3. <http://dx.doi.org/10.23804/ejpd.2022.23.03.06>. PMID:36172909.
18. Amornvit P, Sanohkan S. The accuracy of digital face scans obtained from 3D scanners: an in vitro study. *Int J Environ Res Public Health.* 2019;16(24):5061. <http://dx.doi.org/10.3390/ijerph16245061>. PMID:31842255.
19. Lee JD, Nguyen O, Lin YC, Luu D, Kim S, Amini A, et al. Facial scanners in dentistry: an overview. *MDPI Prosthesis.* 2022;4(4):664-78. <http://dx.doi.org/10.3390/prosthesis4040053>.
20. Diniz V, Corrêa EC, Gonçalves BC, Fardim KA, Manhães LRC Jr, Tango EK, et al. Prevalence of soft tissue calcifications in cone beam computed tomography images in the region of head and neck. *Braz Dent Sci.* 2020;23(2):1-6. <http://dx.doi.org/10.14295/bds.2020.v23i2.186>.
21. de Souza Jr C, Machado R, Batts RA, Garcia LD. Inferior alveolar nerve paraesthesia after overfilling into the mandibular canal, confirmed by cone-beam computed tomography: a case report. *Braz Dent Sci.* 2021;24(2):1-8. <http://dx.doi.org/10.14295/bds.2021.v24i2.2421>.
22. Incrapera AK, Kau CH, English JD, McGrory K, Sarver DM. Soft tissue images from cephalograms compared with those from a 3D surface acquisition system. *Angle Orthod.* 2010;80(1):58-64. <http://dx.doi.org/10.2319/111408-583.1>. PMID:19852641.
23. Shetty SR, Reddy S, Abdelmagyd HA, Marei H, Shetty R, Elsayed WS. Assessment of alveolar bone level and furcation involvement in periodontal diseases using dental cone-beam computed tomography (CBCT): a systematic review. *Braz Dent Sci.* 2020;23(3):1-8. <http://dx.doi.org/10.14295/bds.2020.v23i3.1927>.
24. Kau CH, Zhurov AI, Scheer R, Bouwman S, Richmond S. The feasibility of measuring three-dimensional facial morphology in children. *Orthod Craniofac Res.* 2004;7(4):198-204. <http://dx.doi.org/10.1111/j.1601-6343.2004.00289.x>. PMID:15562582.
25. Salemi F, Shokri A, Foroozandeh M, Farhadian M, Yeganeh A. Knowledge level of Iranian dental practitioners towards digital radiography and cone-beam computed tomography. *Braz Dent Sci.* 2021;24(2). <http://dx.doi.org/10.14295/bds.2021.v24i2.2442>.
26. Kau CH, Cronin A, Durning P, Zhurov A, Sandham A, Richmond S. A new method for the 3D measurement of postoperative swelling following orthognathic surgery. *Orthod Craniofac Res.* 2006;9(1):31-7. <http://dx.doi.org/10.1111/j.1601-6343.2006.00341.x>. PMID:16420272.
27. Perrotti G, Baccaglione G, Clauser T, Scaini R, Grassi R, Testarelli L, et al. Total Face Approach (TFA) 3D cephalometry and superimposition in orthognathic surgery: evaluation of the vertical dimensions in a consecutive series. *Methods Protoc.* 2021;4(2):36. <http://dx.doi.org/10.3390/mps4020036>. PMID:34069808.
28. Kau CH, Richmond S, Savio C, Mallorie C. Measuring adult facial morphology in three dimensions. *Angle Orthod.* 2006;76(5):773-8. PMID:17029509.

(Corresponding address)

Rodolfo Reda

Sapienza Università di Roma, Dipartimento di Scienze Odontostomatologiche e

Maxillo Facciali, Roma, Italia.

Email: rodolfo.reda@uniroma1.it

Date submitted: 2022 Dec 05

Accepted submission: 2022 Dec 05