*Letter to the Editor*

Ear, Nose & Throat Journal
2022, Vol. 0(0) 1–3

DOI: 10.1177/01455613221074739
journals.sagepub.com/home/ear
SAGE

# The Evaluation of Vertigo in Children: Which Role for Parental-Camera Recording and Telemedicine?

**Virginia Fancello, MD[1], Chiara Bianchini, PhD, MD[1], Giannicola Iannella, PhD, MD[2], Giovanni Cammaroto, PhD, MD[2], Giuseppe Meccariello, MD[2], Stefano Pelucchi, MD[1] and Andrea Ciorba, PhD, MD[1]**

**Keywords**
Vertigo, telemedicine, pediatric, smartphone, camera, COVID-19

Sir,

At this time, the management of pediatric patients affected by vertigo remains a challenge that requires a multidisciplinary approach and the collaboration of many specialists, such as otorhinolaryngologists, audiologists, pediatricians, and neurologists. Vertigo in children is a condition often difficult to assess since the little patients are frequently incapable to provide a complete description of their complaints, and parents can be inaccurate or incomplete, in describing or recognizing crucial clinical signs.

Many disorders, including neurological and audio-vestibular diseases, can manifest with vertigo, which in children can occur alone or in association to other symptoms such as visual disturbances, migraine, or learning disabilities. It can severely affect the quality of life of both, children and their families, especially if persisting, enhancing parental concerns and anxieties.[1-3]

A careful collection of medical history, with a detailed description of symptoms, is crucial in the diagnostic process. However, parents/caregivers may omit important data since they are not trained to recognize red flags or specific signs. Thus, during the first consultation, otolaryngologists should alert parents/caregivers for assessing specific vertigo features, in the case of future episodes. Timing, frequency, triggers, and associated manifestations can be helpful details to report.

Among specific diagnostic tools, the video Head Impulse Test (vHIT) is a valuable instrument for assessing the vestibular-ocular reflex (VOR), even if it can present a higher percentage of artefacts in children, mainly due to technical issues (i.e., higher gain and blinking eyes).[4] Furthermore, while teenagers can undergo different investigations, including specific vestibular testing, the cooperation of younger children, for a full clinical and instrumental testing, can be tricky.[5,6]

Currently, the use of patients' self-recorded videos is not common among the audio-vestibular practice. However, according to Gedik-Soyuyuce et al, their application can be valuable for observing children's behaviors during acute vertigo attacks.[7] Nowadays, smartphone high-definition cameras could be useful for recording the dizzy children during a crisis. Therefore, detailed features (i.e., eyes and body movements) could be documented, as already proposed for the adults affected by Meniere's disease.[8]

Figure 1 shows a possible diagnostic flow chart for helping clinicians in the evaluation of pediatric patients affected by vertigo. Self-recordings can be particularly useful in teenagers with suspected vestibular migraine. In fact, the diagnostic criteria of childhood vestibular migraine, as per the latest updates of the Barany Society, include at least 5 migraine episodes associated with vestibular symptoms, lasting between 5 minutes and

[1]ENT and Audiology Unit, Department of Rehabilitation and Neurosciences, University of Ferrara, Italy
[2]Department of Head-Neck Surgery, Otolaryngology, Head-Neck and Oral Surgery Unit, Morgagni Pierantoni Hospital, Via Carlo Forlanini, Forlì, Italy

Received: December 15, 2021; revised: December 27, 2021; accepted: January 4, 2022

**Corresponding Author:**
Virginia Fancello, ENT and Audiology Unit, Department of Rehabilitation and Neurosciences, University of Ferrara, viale Aldo Moro 8, Ferrara, Emilia Romagna 44121, Italy.
Email: virginia.fancello@gmail.com

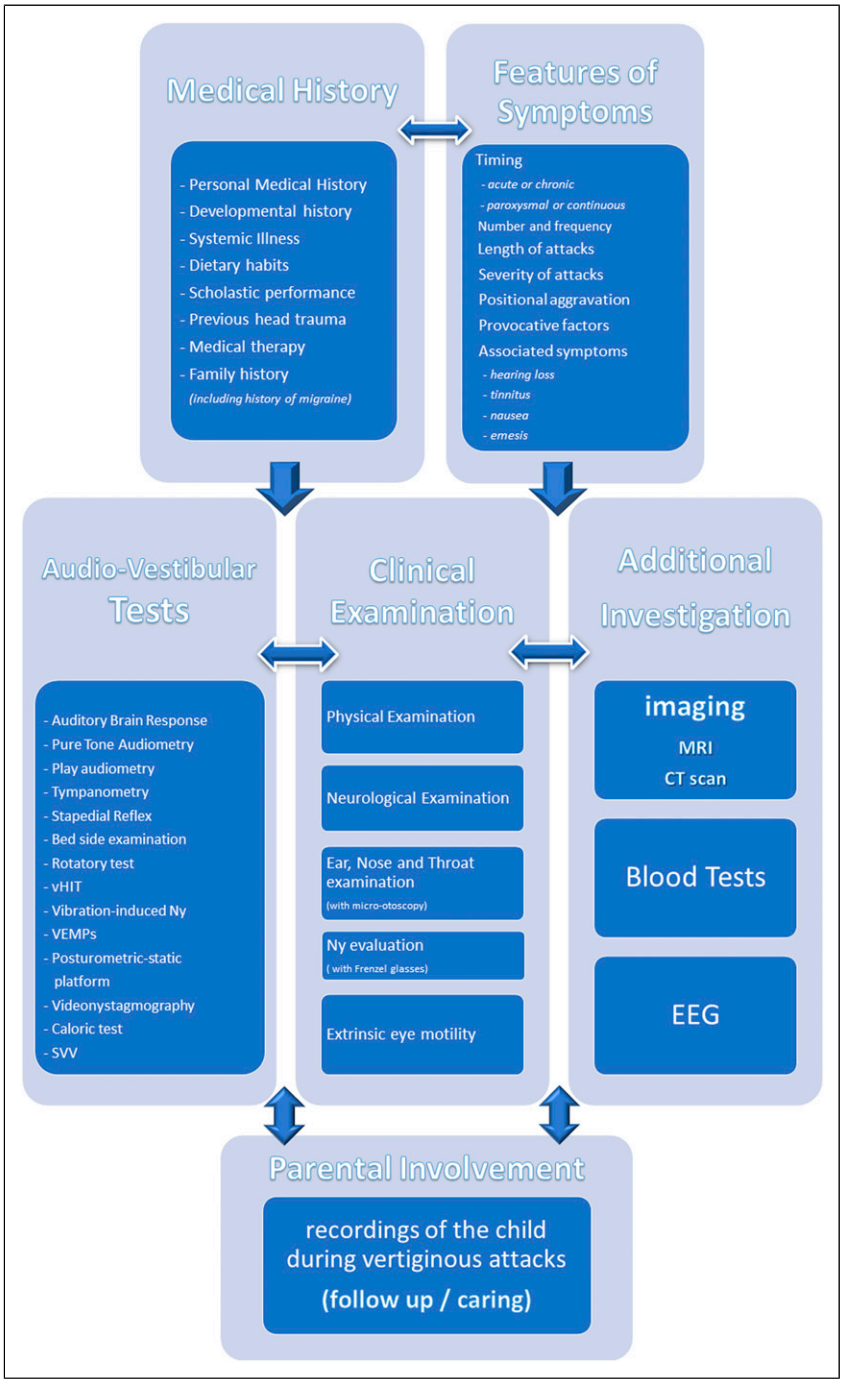


**Figure 1.** A possible diagnostic approach to vertigo in pediatric patients, including self or parental recordings. Legend: Ny: nystagmus; VEMPs: vestibular-evoked myogenic potentials; vHIT: video head impulse test; SVV: subjective visual vertical; MRI: magnetic resonance imaging; CT: computerized tomography; EEG: electroencephalogram.

72 hours.[9] Accordingly, self-recorded videos can help to make the diagnosis more reliable.

Furthermore, it is likely that telemedicine could be useful for evaluating the dizzy children. During the COVID-19 pandemic, telemedicine has been applied to many fields, as it can be an effective and affordable option for evaluating and offering advice on specific problems to those quarantined or infected and isolated. Possibly, via teleconsultation, healthcare professionals could provide parents detailed recommendations, while observing a vertigo crisis and its features.

In conclusion, the evaluation of the child affected by vertigo should be always careful and accurate; it could also

include home video recordings, in order to achieve detailed features of eyes and body movements during the attack, and eventually a telemedicine approach.

## ORCID iDs

Virginia Fancello https://orcid.org/0000-0002-3290-8983
Chiara Bianchini https://orcid.org/0000-0002-5115-6107
Andrea Ciorba https://orcid.org/0000-0003-3455-2295

## References

1. Weiss AH, Phillips JO. Congenital and compensated vestibular dysfunction in childhood: an overlooked entity. *J Child Neurol*. 2006;21:572-579.
2. Rine RM, Braswell J, Fisher D, Joyce K, Kalar K, Shaffer M. Improvement of motor development and postural control following intervention in children with sensorineural hearing loss and vestibular impairment. *Int J Pediatr Otorhinolaryngol*. 2004; 68:1141-1148.
3. Braswell J, Rine RM. Evidence that vestibular hypofunction affects reading acuity in children. *Int J Pediatr Otorhinolaryngol*. 2006;70:1957-1965.
4. Kim KS, Jung YK, Hyun KJ, Kim MJ, Kim HJ. Usefulness and practical insights of the pediatric video head impulse test. *Int J Pediatr Otorhinolaryngol*. 2020;139:110424. doi:10.1016/j.ijporl.2020.110424.
5. Haripriya GR, Lepcha A, Augustine AM, John M, Philip A, Mammen MD. Prevalence, clinical profile, and diagnosis of pediatric dizziness in a tertiary care hospital. *Int J Pediatr Otorhinolaryngol*. 2021;146:110761. doi:10.1016/j.ijporl.2021.110761.
6. Lee JD, Kim CH, Hong SM, et al. Prevalence of vestibular and balance disorders in children and adolescents according to age: a multi-center study. *Int J Pediatr Otorhinolaryngol*. 2017;94: 36-39. doi:10.1016/j.ijporl.2017.01.012.
7. Gedik-Soyuyuce O, Gence-Gumus Z, Ozdilek A, Ada M, Korkut N. Vestibular disorders in children: a retrospective analysis of vestibular function test findings. *Int J Pediatr Otorhinolaryngol*. 2021;146:110751. doi:10.1016/j.ijporl.2021.110751.
8. Kıroğlu M, Dağkıran M. The role of mobile phone camera recordings in the diagnosis of meniere's disease and pathophysiological implications. *J Int Adv Otol*. 2020;16(1):18-23. doi:10.5152/iao.2019.6605.
9. van de Berg R, Widdershoven J, Bisdorff A, et al. Vestibular migraine of childhood and recurrent vertigo of childhood: diagnostic criteria consensus document of the committee for the classification of vestibular disorders of the Bárány society and the international headache society. *J Vestib Res*. 2021;31(1):1-9. doi:10.3233/VES-200003.