

Selective medical treatment of heterotopic interstitial pregnancy

U. Indraccolo¹, G. Corona², M. Bonito³, S.R. Indraccolo⁴, E. Ferrazzi⁵, R. Di Iorio⁶

¹Complex Operative Unit of Obstetrics and Gynecology, "Alto Tevere" Hospital of Città di Castello, ASL 1, Città di Castello

²Department of Obstetrics and Gynecology, Genzano Hospital, Genzano of Rome

³Department of Obstetrics and Gynecology, San Pietro Fatebenefratelli Hospital, Rome

⁴Department of Gynecological and Urological Sciences, Sapienza, University of Rome, Rome

⁵Department of Obstetrics and Gynecology, "Vittore Buzzi" Hospital, University of Milan, Milan

⁶Department of Medical and Surgical Sciences and Translational Medicine, "Sapienza" University of Rome, Rome (Italy)

Summary

A new case of interstitial pregnancy after embryos transfer is reported. The interstitial pregnancy was one of twin pregnancy who was diagnosed sonographically and selectively interrupted at the 15th week. The residual pregnancy ended in an elective cesarean section early term.

Key words: Interstitial pregnancy; Selective pregnancy termination; Embryo transfer.

Introduction

To date, interstitial pregnancy in twins has been raised by increasing of the intra-uterine transfers of embryos after in vitro fertilization. The topic has been reviewed by some Authors in literature, focussing on diagnosis and treatment (1-4). This report presents a new case of interstitial pregnancy treated conservatively, to improve the knowledge regarding the topic.

Case Report

The patient was 35-years-old. Her past medical history recorded an operative laparoscopy performed for three-year primary infertility. A pelvic inflammatory disease and endometriosis was diagnosed with bilateral salpingectomy. The patient conceived after in-utero transfer of two embryos obtained by in-vitro fertilization. At 13 weeks and three days of pregnancy, she was recovered for bleeding and haemoperitoneum. After careful echographic check,

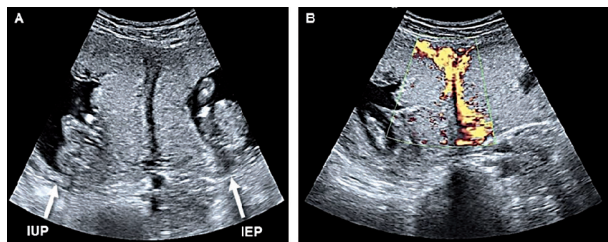


Figure 1. — Two-dimensional gray scale transverse section showing the intrauterine pregnancy (IUP) and the left interstitial pregnancy (IEP) (Panel A). Color Doppler imaging shows two different trophoblast layers between intrauterine and ectopic pregnancies (Panel B).

an interstitial left eterotopic pregnancy in a twin pregnancy was diagnosed (Figure 1). Both pregnancies were viable. A week later, a selective interruption of the interstitial pregnancy was performed by using transvaginal ultrasound-guided aspiration and instillation of hypertonic solution of sodium chloride. The follow-up of pregnancy was uneventful. The pregnancy ended in an elective cesarean section (male, 3,120 grams, Apgar 9-10), without any complications. Figure 2 shows the externalized uterus after the cesarean, performed at 37 weeks and five days, with the interstitial pregnancy as a swelling on the left side of the uterus.

Discussion

The case of an interstitial pregnancy is reported. The diagnosis of the interstitial pregnancy in twins should be taken in account in case of in vitro fertilization and embryos transfer when a thin septum of myometrium is interposed between the chorions (Figure 1) An additional risk factor for interstitial pregnancy was the previous salpingectomy (3-4). According to literature (1), the echographic finding of interstitial pregnancy in twins has allowed the selective interruption of the interstitial pregnancy, thereby obtaining the evolution of the residual fetus until the term of gestation.

Conclusion

The case increases evidence that conservative management of interstitial pregnancy in twins can be obtained successfully and safely.

Revised manuscript accepted for publication May 15, 2018

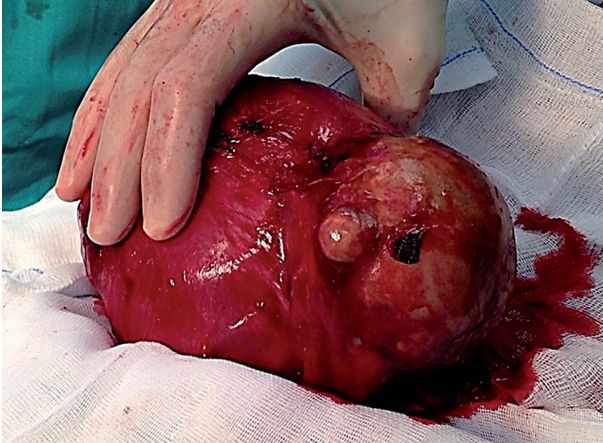

Figure 2. — The residual interstitial pregnancy is the swelling on the left side of the uterus.

References

- [1] Dendas W., Schobbens J.C., Mestdagh G., Meylaerts L., Verswijvel G., Van Holsbeke C.: "Management and outcome of heterotopic interstitial pregnancy: case report and review of literature". *Ultrasound*, 2017, 25, 134.
- [2] Dolinko A.V., Vrees R.A., Frishman G.N.: "Non-tubal ectopic pregnancies: overview and treatment via local injection". *J. Minim. Invasive Gynecol.*, 2018, 25, 287.
- [3] Dibble E.H., Lourenco A.P.: "Imaging unusual pregnancy implantations: rare ectopic pregnancies and more". *A.J.R. Am. J. Roentgenol.*, 2016, 207, 1380.
- [4] Parker V.L., Srinivas M.: "Non-tubal ectopic pregnancy". *Arch. Gynecol. Obstet.*, 2016, 294, 19.

Corresponding Author:
U. INDRACCOLO, M.D., PHD.
Via P. Veronese 2/c
06024 Gubbio (PG) (Italy)
e-mail: ugo.indraccolo@libero.it