



Case report

A life-threatening small bowel obstruction as onset of an unknown sarcoidosis: A case report

Gregorino Paone^{a,c,*}, Alessia Steffanina^b, Giulia De Rose^c, Giacomo Leonardo^b,
Daniele Colombo^d, Paolo Ricci^e, Francesco Sabetta^b, Francesco Vaccaro^c, Edoardo Rosato^f,
Paolo Palange^c

^a Department of Cardiovascular, Respiratory, Nephrologic, Anesthesiologic, Geriatric Sciences La Sapienza University of Rome, Rome, Italy

^b Casilino Hospital, Rome, Italy

^c Department of Public Health and Infectious Diseases, La Sapienza University of Rome, Rome, Italy

^d Department of Biomedicine and Prevention, Anatomic Pathology Section, University of Rome Tor Vergata, Rome, Italy

^e Department of Radiology, Oncology and Pathology, Sapienza University of Rome, Rome, Italy

^f Department of Translational and Precision Medicine, Sapienza University of Rome, Rome, Italy



ARTICLE INFO

Keywords:

Small bowel obstruction
Abdominal sarcoidosis
Granuloma

ABSTRACT

Sarcoidosis is a systemic granulomatous disorder of unknown etiology characterized by non-caseating granulomas at the site of disease. A confident diagnosis should be established by the evidence of typical granulomas on biopsy and after exclusion of other conditions. Clinically recognizable Gastrointestinal involvement (GI) occurs in less than 1.6% of patients with sarcoidosis, with data revealing small intestine participation in 0.03% of the cases and few anecdotal reports describe a peritoneal presentation. Clinical manifestations of peritoneal sarcoidosis are abdominal discomfort, bloating, weight loss, epigastric and peri-umbilical pain with or without ascites, bowel obstruction. Treatment depends on symptoms and disease activity.

Herein we describe the case of a 42-years-old male patient who developed an acute, life-threatening small bowel obstruction as first manifestation of sarcoidosis.

To the best of our knowledge, this is the only report showing such extensive and acute onset of intra-abdominal sarcoidosis in the absence of a previous disease manifestation and without pulmonary involvement.

1. Introduction

Sarcoidosis is a multisystemic disorder of unknown etiology. A genetic predisposition is indicated by familial clustering and there are different lines of evidence supporting the concept that the disease results from exposure of genetically susceptible hosts to specific environmental agents. Since the causes of sarcoidosis have remained unknown, the list of possible causative agents has continuously expanded [1,2].

As a systemic disease sarcoidosis affects multiple organs, but it is usually dominant in the lungs (90%) and lymph nodes (30%). Although, digestive tract involvement is extremely rare [1,3,4], an early diagnosis is crucial because GI sarcoidosis may be the first sign of the disease in many individuals and may represent a life-threatening event in several patients.

Clinical expression, natural history and prognosis of sarcoidosis are unpredictable; thus, the diagnosis is not sufficient to initiate a treatment.

Long term corticosteroids represent the mainstay of therapy, but no clear protocols have been endorsed for dose and treatment duration [5].

We describe the unique case of a 42-years-old male patient who developed an acute, life-threatening small bowel obstruction due to peritoneal involvement as first sarcoidosis manifestation, in the absence of liver and lung involvement.

2. Case presentation

A 42-year-old man from Bangladesh was admitted to the emergency department for nausea, vomiting, abdominal pain, constipation and fever. He was alert, oriented and in acute distress. Before hospital admission his medical history was unremarkable. He denied weight loss, cough, sputum production and chest pain.

Body temperature was 38.4 °C, pulse was 93 bpm, blood pressure 135/85 mmHg, SpO₂ 98% on room air at rest. Physical examination was

* Corresponding author. Department of Cardiovascular, Respiratory, Nephrologic, Anesthesiologic, Geriatric Sciences La Sapienza University of Rome, Rome, Italy.
E-mail addresses: rpaone1023@yahoo.com, gregorino.paone@uniroma1.it (G. Paone).

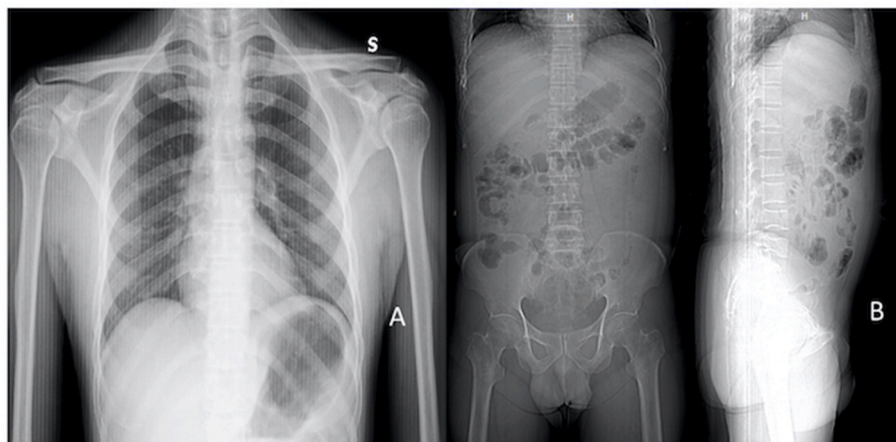


Fig. 1. a)Chest X ray with no lymph nodes or parenchymal involvement. b)Abdominal X-ray revealing dilated small-bowel loops, multiple scattered air fluid levels.

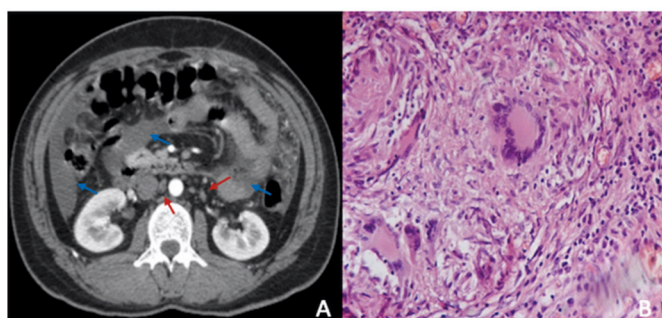


Fig. 2. A) Contrast - enhanced abdominal and pelvis computed tomography scans in the axial plane showing abundant ascitic fluid (blue arrows) and multiple lymph nodes, the largest near the right renal hilum (red arrows). B) Microscopic slide revealing non necrotizing epithelioid cell granuloma. (For interpretation of the references to colour in this figure legend, the reader is referred to the Web version of this article.)

normal except for a distended abdomen moderately tender over the epigastric area; bowel sounds were hyperactive with no evidence of organomegaly.

Laboratory data were normal except for blood hemoglobin level (8.4 g/dL), C-reactive protein level (79.73 mg/L). Blood cultures and HIV serology were negative. Chest X-Ray was normal, neither lymph-nodes nor parenchymal involvement were observed (Fig. 1A).

Abdominal X-ray revealed dilated small-bowel loops, some scattered air fluid suggesting a partial toward a complete small-bowel obstruction (Fig. 1B).

A contrast-enhanced computed tomography (CT) of abdomen and pelvis demonstrated abundant ascitic fluid, multiple increased lymph nodes in different stations, and no other GI organs involvement (Fig. 2A).

Patient underwent laparotomy, which revealed corpuscular hemorrhagic ascites, adhesive peritonitis, rock-hard consistency omentum, multiple dilated and fused small bowel loops. A careful separation of adhesions between omentum, small intestine and bowel loops was executed. Several hard consistency nodules were found on bowel wall, mesentery, omentum, appendix, pelvis and subdiaphragmatic region and multiple biopsies were performed.

Staining for acid-fast bacilli (AFB), Grocott methenamine silver stain, periodic acid-Schiff stain, fungal and viral tissue cultures resulted negative.

Mycobacterium DNA search by Polymerase Chain Reaction (PCR) on ascitic liquid was negative.

The following primer sets were used for PCR: IS6110 (sense

Table 1

Differential diagnoses analyzed during our diagnostic process.

DIFFERENTIAL DIAGNOSIS	RESULTS	TESTS
TUBERCULOSIS	NEGATIVE	BIOPSY, CULTURE, PCR ON SURGICAL SPECIMEN
PERITONEAL CARCINOSIS	NEGATIVE	HYSTOLOGICAL EXAMINATION ON SURGICAL SPECIMEN BIOPSY
IBD/WHIPPLE'S DISEASE	NEGATIVE	HYSTOLOGICAL EXAMINATION ON SURGICAL SPECIMEN BIOPSY
IgG4 DISEASE	NEGATIVE	SALIVARY GLAND BIOPSY; IgG4 MEASUREMENT
FUNGAL/PARASITIC INFECTION	NEGATIVE	CULTURE

–5'CCTGCGAGCGTAGGCGTCGG-3', anti-sense 5'- CCTGCGAGCGTAGGCGTCGG-3').

Appendix histologic examinations, omentum, peritoneum, bowel wall and pelvis biopsies revealed lymph histiocytic non-caseating granulomatous inflammation with multinucleated giant cells consistent with sarcoidosis (Fig. 2B).

Histological examination and laboratory tests excluded causes of abdominal and peritoneal granulomatosis such as tuberculosis, parasitosis (schistosomiasis, actinomycosis), fungal infections (histoplasmosis), IBD, Whipple's disease and peritoneal carcinosis (Table 1).

Culture tests for M. Tuberculosis and atypical mycobacteria on surgical specimens did not show bacterial growth after 2 months.

Patient postoperative course was complicated by a mild transient left pleural effusion with associated atelectasis. He underwent a 10 days antibiotic therapy with Meropenem 1 gm three times a day plus Vancomycin 1 gm bid i.v.

A total body CT showed no mediastinal lymph nodes enlargement or lung lesions. After the histological diagnosis of sarcoidosis, a corticosteroid treatment (Prednisone 25 mg/die) was initiated. He was discharged and a tight outpatient follow-up was initiated.

Prednisone was given at a dosage of 25 mg/die for 3 months, then reduced to 15mg/d for 2 months and slowly tapered to 5–10 mg/die, over 12 months, monitoring patient symptoms and treatment side effects.

From hospital discharge, patient underwent abdominal CT after 3, 9 and 24 months; abdominal ultrasound after 6, 12 and 24 months; Chest X ray after 12 months.

No evidence of sarcoidosis was observed. Laboratory tests were performed every 2 months to monitor treatment side effects and disease activity with no evidence of alterations. At the three months evaluation patient evaluation we observed a complete response to therapy without

complications or side effects. After 6 months, a significant increase of lipase (600 u/L) and amylase (363 u/L) was observed and the hypothesis of IgG4 disease was considered. Thus, the patient underwent a salivary gland biopsy and IgG4 measurement, which ruled out the diagnosis [6]. Lipase and amylase levels returned to normality after two months of a diet and healthy lifestyle regimen.

Follow-up evaluations at 9-12-24 months demonstrated a steady favorable clinical course with subject wellness and no signs of disease on abdominal CT or Chest X ray.

3. Discussion

Sarcoidosis is a systemic granulomatous disease of unknown etiology, characterized by noncaseating granulomas in target organs [1,4]. Although the exact etiology of this disorder remains unknown, sarcoidosis is considered a multifactorial process, due to both genetic susceptibility and environmental insults [7].

Sarcoidosis presentation varies widely, affecting individuals of all racial, ethnic backgrounds and ages [8,9]. Thoracic involvement is the most common presentation, reported in up to 90% of patients [10]. Conversely, a clinically recognizable gastrointestinal (GI) involvement is uncommon, occurring in 0.1–1.6% of patients with sarcoidosis, with data revealing a small bowel involvement in 0.03% of the cases [11]. Peritoneal sarcoidosis is even more unusual with few anecdotal cases reported in literature and hemorrhagic ascites is extremely rare [12–14]. The most common reported manifestation are colicky abdominal pain, chills and feverishness [15–17], non-specific constitutional symptoms and obstruction may be present as well mimicking an intestinal cancer [18–20].

Reaching an abdominal sarcoidosis diagnosis is not a straightforward process. Compatible clinical features should be associated with evidence of non-caseating granulomas in the symptomatic or incident organ and exclusion of other causes of granulomatous disease.

Several diseases should routinely be investigated and ruled out in patients with suspected intestinal sarcoidosis, including inflammatory, infectious, and neoplastic diseases. On presentation, key differential diagnoses are tuberculosis, parasitosis, fungal infections, IBD, Whipple's disease and peritoneal carcinosis [21,22].

Since tuberculosis is endemic in Bangladesh, we considered tuberculous peritonitis as the main differential diagnosis. We believe that the combination of diagnostic tests we performed (PCR amplification using IS6110 primer, stain for acid fast bacilli, Mycobacteria cultures), the complete radiologic resolution and the favorable clinical response to a 12 months corticosteroids treatment ruled out the diagnosis of peritoneal tuberculosis [23].

Treatment depends on symptomatology and disease activity. Asymptomatic patients may be monitored with no need for therapy; patients with a clear organ involvement and positive tissue biopsy should be treated with corticosteroid (20–40 mg/d) from six to eight weeks or until a response to therapy and then gradually tapered. The optimal treatment duration is unknown, but most reports recommend a length of at least one year. Other agents (e.g. hydroxychloroquine, azathioprine, methotrexate) may be necessary in patients who do not respond to treatment or as steroid-sparing therapy, but data are very limited [24]. Rarely complicated abdominal localization requires a surgery treatment [25,26].

4. Conclusions

Serosal surface sarcoidosis is very unusual with few anecdotal cases reported in literature.

Herein, we report a unique case of a patient who underwent abdominal surgery because of a sudden life-threatening peritoneal sarcoidosis presentation with no previous history of disease and no pulmonary or liver involvement.

To our knowledge, no papers report such an acute presentation.

We suggest that sarcoidosis should be considered as a possible cause of sudden abdominal obstruction. Therefore, even in a critical setting, patients should undergo to all diagnostic procedures to rule out this diagnosis.

Declaration of competing interest

None.

References

- [1] Statement on sarcoidosis. Joint Statement of the American Thoracic Society (ATS), the European Respiratory Society (ERS) and the World Association of Sarcoidosis and other Granulomatous Disorders (WASOG) adopted by the ATS board of Directors and by the ERS Executive Committee, February 1999, *Am. J. Respir. Crit. Care Med.* 160 (1999) 736–755, <https://doi.org/10.1164/ajrccm.160.2.ats4-99>.
- [2] E. Bargagli, A. Prasse, Sarcoidosis: a review for the internist, *Intern Emerg Med* 13 (2018) 325–331, <https://doi.org/10.1007/s11739-017-1778-6>.
- [3] E. Ghrenassia, A. Mekinian, C. Chapelon-Albric, P. Levy, et al., Digestive-tract sarcoidosis: French nationwide case-control study of 25 cases, *Medicine (Baltim.)* 95 (2016) e4279, <https://doi.org/10.1097/MD.0000000000004279>.
- [4] M.C. Iannuzzi, B.A. Rybicki, A.S. Teirstein, Sarcoidosis, *N. Engl. J. Med.* 357 (2007) 2153–2165, <https://doi.org/10.1056/NEJMra071714>.
- [5] D. Valeyre, A. Prasse, H. Nunes, Y. Uzunhan, et al., Sarcoidosis, *Lancet* 383 (2014) 1155–1167, [https://doi.org/10.1016/S0140-6736\(13\)60680-7](https://doi.org/10.1016/S0140-6736(13)60680-7).
- [6] S. Rustscheff, Does your patient have sarcoid or IgG4-related disease? Or both? Or are both diseases just parts of the same disease spectrum? *Chest* 156 (2019) A234, <https://doi.org/10.1016/j.chest.2019.08.288>.
- [7] A.A. Starshinova, A.M. Malkova, Basantsova, Sarcoidosis as an autoimmune disease, *Front. Immunol.* 10 (2020) 2933, <https://doi.org/10.3389/fimmu.2019.02933>.
- [8] L.S. Newman, C.S. Rose, E.A. Bresnitz, M.D. Rossman, et al., A case control etiologic study of sarcoidosis: environmental and occupational risk factors, *Am. J. Respir. Crit. Care Med.* 170 (2004) 1324–1330, <https://doi.org/10.1164/rccm.200402-2490C>.
- [9] B.A. Rybicki, M. Major, J. Popovich, et al., Racial differences in sarcoidosis incidence: a 5-year study in a health maintenance organization, *Am. J. Epidemiol.* 145 (1997) 234–241, <https://doi.org/10.1093/oxfordjournals.aje.a009096>.
- [10] G. Paone, B. Lucantoni, A. Leone, et al., Human Neutrophil Peptides stimulate tumor necrosis factor- α release by alveolar macrophages from patients with sarcoidosis, *Chest* 135 (2009) 586–587, <https://doi.org/10.1378/chest.08-2585>.
- [11] A. Zakaria, B. Al Share, I. Turk, et al., An uncommon cause of a small bowel obstruction, *Case Rep Gastrointest Med* 2017 (2017), <https://doi.org/10.1155/2017/1628215>, 1628215: 1–4.
- [12] A.J. Papowitz, J.K.H. Li, Abdominal sarcoidosis with ascites, *Chest* 59 (1971) 692–695, <https://doi.org/10.1378/chest.59.6.692>.
- [13] F. Santolaria Fernandez, D. Hernandez Marrero, E. Gonzalez Reimers, et al., Peritoneal sarcoidosis, *Arch. Intern. Med.* 148 (1988) 233–237, <https://doi.org/10.1001/archinte.1988.00380010235026>.
- [14] A. Nicolini, M. Vita, S. Lanata, Peritoneal Sarcoidosis: an unusual presentation and a brief review of the literature, *Monaldi Arch. Chest Dis.* 75 (2) (2011) 132–134, <https://doi.org/10.4081/monaldi.2011.226>.
- [15] S.W. Lee, M.H. Lee, E.J. Lee, et al., Peritoneal Sarcoidosis: a case report, *Medicine* 98 (2019) 24, <https://doi.org/10.1097/MD.00000000000016001>.
- [16] A. Alatmi, A. Joury, A. Mubarak, Extensive abdominal sarcoidosis without pulmonary manifestation, *Ochsner J.* 19 (2019) 174–177, <https://doi.org/10.31486/toj.17.0111>.
- [17] L. Stemboroski, B. Gaye, R. Makary, et al., Isolated gastrointestinal sarcoidosis involving multiple gastrointestinal sites presenting as chronic diarrhea, *ACG Case Rep J* 3 (2016 21) e198, <https://doi.org/10.14309/crj.2016.171>.
- [18] C. Tu, Q. Lin, J. Zhu, et al., Isolated sarcoidosis of accessory spleen in the greater omentum: a case report, *Exp Ther Med* 11 (2016) 2379–2384, <https://doi.org/10.3892/etm.2016.3221>.
- [19] E.C. Ebert, M. Kierson, K.D. Hagspiel, Gastrointestinal and hepatic manifestations of sarcoidosis, *Am. J. Gastroenterol.* 103 (2008) 3184–3192, <https://doi.org/10.1111/j.1572-0241.2008.02202.x>.
- [20] M. Friedman, M.A. Ali, M.L. Borum, Gastric sarcoidosis: a case report and review of the literature, *South. Med. J.* 100 (2007) 301–303, <https://doi.org/10.1097/SMJ.0b013e318030ed94>.
- [21] P. Brito-Zerón, K. Bari, R.P. Baughman, et al., Sarcoidosis involving the gastrointestinal tract: diagnostic and therapeutic management, *Am. J. Gastroenterol.* 114 (2019) 1238–1247, <https://doi.org/10.14309/ajg.0000000000000171>.
- [22] N. Soto – Gomez, J.I. Peters, A.M. Nambiar, Diagnosis and management of sarcoidosis, *Am. Fam. Physician* 93 (2016) 840–850. PMID: 27175719.
- [23] P. Govender, J.S. Berman, The diagnosis of sarcoidosis, *Clin. Chest Med.* 36 (2015) 585–602, <https://doi.org/10.1016/j.ccm.2015.08.003>.

- [24] P. Ungprasert, J.H. Ryu, E.L. Matteson, Clinical manifestations, diagnosis, and treatment of sarcoidosis, *Mayo Clin Proc Innov Qual Outcomes* 3 (2019) 358–375, <https://doi.org/10.1016/j.mayocpiqo.2019.04.006>.
- [25] B. Vahid, T. Lin, Surgical aspects of abdominal Sarcoidosis, *Surg. J.* 2 (2007) 5–13, doi=sjour.2007.5.13.
- [26] A. Abdulaziz, U.J. Abdulaziz, M. Abeer, Extensive abdominal sarcoidosis without pulmonary manifestation, *Ochsner J.* 2 (2019) 174–177, <https://doi.org/10.31486/toj.17.0111>.