

Aggressive Afterload Lowering to Improve the Right Ventricle A New Target for Medical Therapy in Pulmonary Arterial Hypertension?

Carminé Dario Vizza^{1*}, Irene M. Lang^{2*}, Roberto Badagliacca^{1*}, Raymond L. Benza^{3*}, Stephan Rosenkranz^{4,5*}, R. James White^{6*}, Yochai Adir^{7,8}, Arne K. Andreassen⁹, Vijay Balasubramanian¹⁰, Sonja Bartolome¹¹, Isabel Blanco^{12,13}, Robert C. Bourge¹⁴, Jørn Carlsen^{15,16}, Rafael Enrique Conde Camacho¹⁷, Michele D'Alto¹⁸, Harrison W. Farber¹⁹, Robert P. Frantz²⁰, H. James Ford²¹, Stefano Ghio²², Mardi Gomberg-Maitland²³, Marc Humbert^{24,25,26}, Robert Naeije²⁷, Stylianos E. Orfanos²⁸, Ronald J. Oudiz²⁹, Sergio V. Perrone³⁰, Oksana A. Shlobin³¹, Marc A. Simon³², Olivier Sitbon^{24,25,26}, Fernando Torres¹¹, Jean Luc Vachieri³³, Kuo-Yang Wang³⁴, Magdi H. Yacoub³⁵, Yan Liu³⁶, Gil Golden³⁶, and Hiromi Matsubara^{37*}

Abstract

Despite numerous therapeutic advances in pulmonary arterial hypertension, patients continue to suffer high morbidity and mortality, particularly considering a median age of 50 years. This article explores whether early, robust reduction of right ventricular afterload would facilitate substantial improvement in right ventricular function and thus whether afterload reduction should be a treatment goal for pulmonary arterial hypertension. The earliest clinical studies of prostanoid treatment in pulmonary arterial hypertension demonstrated an important link between lowering mean pulmonary arterial pressure (or pulmonary vascular resistance) and improved survival. Subsequent studies of oral monotherapy or sequential combination therapy demonstrated smaller reductions in mean pulmonary arterial pressure and pulmonary vascular resistance. More recently,

retrospective reports of initial aggressive prostanoid treatment or initial combination oral and parenteral therapy have shown marked afterload reduction along with significant improvements in right ventricular function. Some data suggest that reaching threshold levels for pressure or resistance (components of right ventricular afterload) may be key to interrupting the self-perpetuating injury of pulmonary vascular disease in pulmonary arterial hypertension and could translate into improved long-term clinical outcomes. Based on these clues, the authors postulate that improved clinical outcomes might be achieved by targeting significant afterload reduction with initial oral combination therapy and early parenteral prostanoids.

Keywords: combination therapy; prostacyclin; pulmonary arterial hypertension; pulmonary arterial pressure; right ventricular afterload

(Received in original form September 10, 2021; accepted in final form December 13, 2021)

Ⓓ This article is open access and distributed under the terms of the Creative Commons Attribution Non-Commercial No Derivatives License 4.0. For commercial usage and reprints, please e-mail Diane Gern (dgern@thoracic.org).

*Co-first authors.

Supported by United Therapeutics Corporation to consider the possibility of a clinical study evaluating pulmonary arterial pressure targets as an endpoint. Subsequently, the initiative and authorship of the manuscript was driven by the authors independently from United Therapeutics Corporation. United Therapeutics Corporation contracted Omni Healthcare Communications to provide editorial services limited to assimilating author feedback and formatting for submission. None of the authors was compensated by United Therapeutics Corporation in any way for their involvement with this manuscript development, and the co-first authors take responsibility for the ideas and opinions espoused.

Author Contributions: C.D.V., I.M.L., R.B., R.L.B., S.R., R.J.W., and H.M. conceived the article and wrote initial and final drafts. All authors contributed to article revision and gave final approval for publication.

Author Statement: In patients with pulmonary arterial hypertension, the strategy of initial combination therapy with 2 oral drugs or 3 drugs including a parenteral prostanoid has been shown to significantly reduce right ventricular afterload and markedly improve right ventricular function. Such aggressive treatment strategies may provide robust hemodynamic improvement and even near normalization of hemodynamics in some cases. Preliminary data suggest that there may be thresholds of pressure and/or afterload resistance, whereby a more aggressive pulmonary arterial hypertension treatment strategy might result in favorable long-term clinical outcomes. Rigorous testing of this concept would require multicenter, prospective studies of an early, multitargeted medication approach to target thresholds of hemodynamics and right ventricular function, leading to improved clinical outcomes.

Correspondence and requests for reprints should be addressed to Carmine Dario Vizza, M.D., Dipartimento di Scienze Cliniche Internistiche Anestesiologiche e Cardiovascolari, Università di Roma La Sapienza, Policlinico Umberto I, Viale del Policlinico 155, 00161 Rome, Italy. E-mail: dario.vizza@uniroma1.it.

Am J Respir Crit Care Med Vol 205, Iss 7, pp 751–760, Apr 1, 2022

Copyright © 2022 by the American Thoracic Society

Originally Published in Press as DOI: 10.1164/rccm.202109-2079PP on December 14, 2021

Internet address: www.atsjournals.org

¹Dipartimento di Scienze Cliniche Internistiche Anestesiologiche e Cardiovascolari, Università di Roma La Sapienza, Rome, Italy; ²Division of Cardiology, Department of Internal Medicine II, Medical University of Vienna, Vienna, Austria; ³Division of Cardiovascular Diseases, The Ohio State University, Columbus, Ohio; ⁴Department of Cardiology, Clinic III for Internal Medicine, Cologne, Germany; ⁵Cologne Cardiovascular Research Center, Cologne, Germany; ⁶Department of Pulmonary and Critical Care Medicine, University of Rochester, Rochester, New York; ⁷Pulmonary Division, Carmel Medical Center, Haifa, Israel; ⁸Faculty of Medicine, Technion Institute of Technology, Haifa, Israel; ⁹Department of Cardiology, Oslo University Hospital Rikshospitalet, Oslo, Norway; ¹⁰Division of Pulmonary and Critical Care, Department of Medicine, University of California San Francisco Fresno, Fresno, California; ¹¹Division of Pulmonary and Critical Care Medicine, University of Texas Southwestern Medical Center, Dallas, Texas; ¹²Department of Pulmonary Medicine, The August Pi i Sunyer Biomedical Research Institute, University of Barcelona, Barcelona, Spain; ¹³Biomedical Research Networking Center on Respiratory Diseases (CIBERES), Madrid, Spain; ¹⁴Department of Cardiovascular Disease, University of Alabama at Birmingham, Birmingham, Alabama; ¹⁵Department of Cardiology, Rigshospitalet, Copenhagen University Hospital, Copenhagen, Denmark; ¹⁶Faculty of Health and Medical Sciences, Department of Clinical Medicine, University of Copenhagen, Copenhagen, Denmark; ¹⁷Critical Medicine and Intensive Care, Pulmonology, Vascular Pulmonary Center, Pulmonology Foundation of Colombia, University Clinic Colombia, Bogota, Colombia; ¹⁸Department of Cardiology, University "L. Vanvitelli," Monaldi Hospital, Naples, Italy; ¹⁹Pulmonary Center, Boston University School of Medicine, Boston, Massachusetts; ²⁰Department of Cardiovascular Medicine, Mayo Clinic, Rochester, Minnesota; ²¹Division of Pulmonary and Critical Care Medicine, University of North Carolina at Chapel Hill, Chapel Hill, North Carolina; ²²Division of Cardiology, San Matteo Hospital, Scientific Institute for Research, Hospitalization, and Healthcare, Pavia, Italy; ²³Department of Cardiology, School of Medicine & Health Sciences, George Washington University, Washington, D.C.; ²⁴Faculté de Médecine, Université Paris-Saclay, Le Kremlin-Bicêtre, France; ²⁵Service de Pneumologie et Soins Intensifs, Hôpital Bicêtre, Assistance Publique-Hôpitaux de Paris, Le Kremlin-Bicêtre, France; ²⁶Unité Mixte de Recherche S999, Hôpital Marie Lannelongue-Institut National de la Santé et de la Recherche Médicale, Le Plessis-Robinson, France; ²⁷Department of Cardiology, Erasme University Hospital, Brussels, Belgium; ²⁸1st Department of Critical Care, National and Kapodistrian University of Athens Medical School, Athens, Greece; ²⁹Division of Cardiology, Lundquist Institute for Biomedical Research at Harbor-University of California Los Angeles Medical Center, Torrance, California; ³⁰Departamento Cardiología, Instituto Fundación para la Lucha contra las Enfermedades Neurológicas de la Infancia, Buenos Aires, Argentina; ³¹Advanced Lung Disease and Transplant Program, Inova Fairfax Hospital, Falls Church, Virginia; ³²Division of Cardiology, Department of Medicine, University of California San Francisco, San Francisco, California; ³³Pulmonary Vascular Diseases and Heart Failure Clinic, Department of Cardiology, Cliniques Universitaires de Bruxelles-Hôpital Erasme, Brussels, Belgium; ³⁴Center for Pulmonary Hypertension and Pulmonary Vascular Disease, China University Hospital, Taichung, Taiwan; ³⁵National Heart and Lung Institute, Heart Science Centre, Harefield Hospital, London, United Kingdom; ³⁶Department of Global Medical Affairs, United Therapeutics Corporation, Research Triangle Park, North Carolina; and ³⁷Department of Cardiology and Clinical Science, National Hospital Organization, Okayama Medical Center, Okayama, Japan

Although there have been improvements in the treatment of pulmonary arterial hypertension (PAH), including initial combination therapy (1), clinical progression continues to occur. In addition, survival rates are still unacceptable, with mortality rates of 43% and 51% at 5 and 7 years, respectively, in the United States and 41% at 5 years in France (2). This is particularly alarming, considering the median age in registries is ~50 years.

For this reason, the sixth World Symposium on Pulmonary Hypertension recommended early achievement of a low-risk status as a key clinical priority for patients with PAH (3). This goal clearly requires formal risk assessment at each visit using one of three contemporary stratification approaches (3). Interestingly, expert consensus has not settled on afterload reduction as an explicit treatment goal.

To address these and related management issues, we reviewed 1) the pathophysiology of right ventricular (RV) dysfunction in PAH and the likely importance of significant afterload reduction; 2) the range of RV afterload reduction achieved with the current therapeutic approaches; 3) therapeutic strategies that have achieved a significant reduction in RV afterload, as well as the potential importance of reaching threshold amounts; and 4) the

impact of robust RV afterload reduction on RV function and, ultimately, clinical prognosis.

The Pathophysiology of RV Dysfunction in Pulmonary Hypertension

In PAH, RV dysfunction develops mainly because of uncoupling of the RV function from the pulmonary arterial afterload (i.e., afterload mismatch) (4, 5). The vascular pathology increases afterload to such an extent that the compensatory increase in RV contractility (homeometric adaptation) is not sufficient to support normal systolic function. Progressive vascular disease intensifies the afterload mismatch, causing RV dilatation (heterometric adaptation); increased wall stress impairs RV coronary blood flow, with a downward spiral of systemic congestion cardiorenal syndrome, further RV failure, and eventual death (Figure 1).

The concept of afterload mismatch can be described mathematically by RV–pulmonary arterial coupling, calculated as the ratio between RV contractility (end-systolic elastance) and RV afterload (arterial elastance). Normal end-systolic elastance-to-

arterial elastance ratio is 1.5–2; a simplified approach to estimating this ratio from ordinary hemodynamic measurements is maximum RV pressure/mean pulmonary arterial pressure (mPAP) – 1 (6). This simplified approach highlights that reducing mPAP is usually necessary to move the RV–pulmonary arterial coupling toward normal. Thus, in the absence of intrinsic myocardial damage, one should expect that a reduction in mPAP would result in recovery of RV function.

It is possible that, especially when PAH is associated with systemic disease, RV dysfunction could be aggravated by direct myocardial damage, as has been observed in PAH associated with connective tissue disease or HIV infection (7–9).

Clinical Importance of RV Afterload Reduction in Pulmonary Hypertension

Lessons from Pulmonary Endarterectomy and Balloon Pulmonary Angioplasty in Chronic Thromboembolic Pulmonary Hypertension

Although the pathogenesis of the increased afterload in chronic thromboembolic

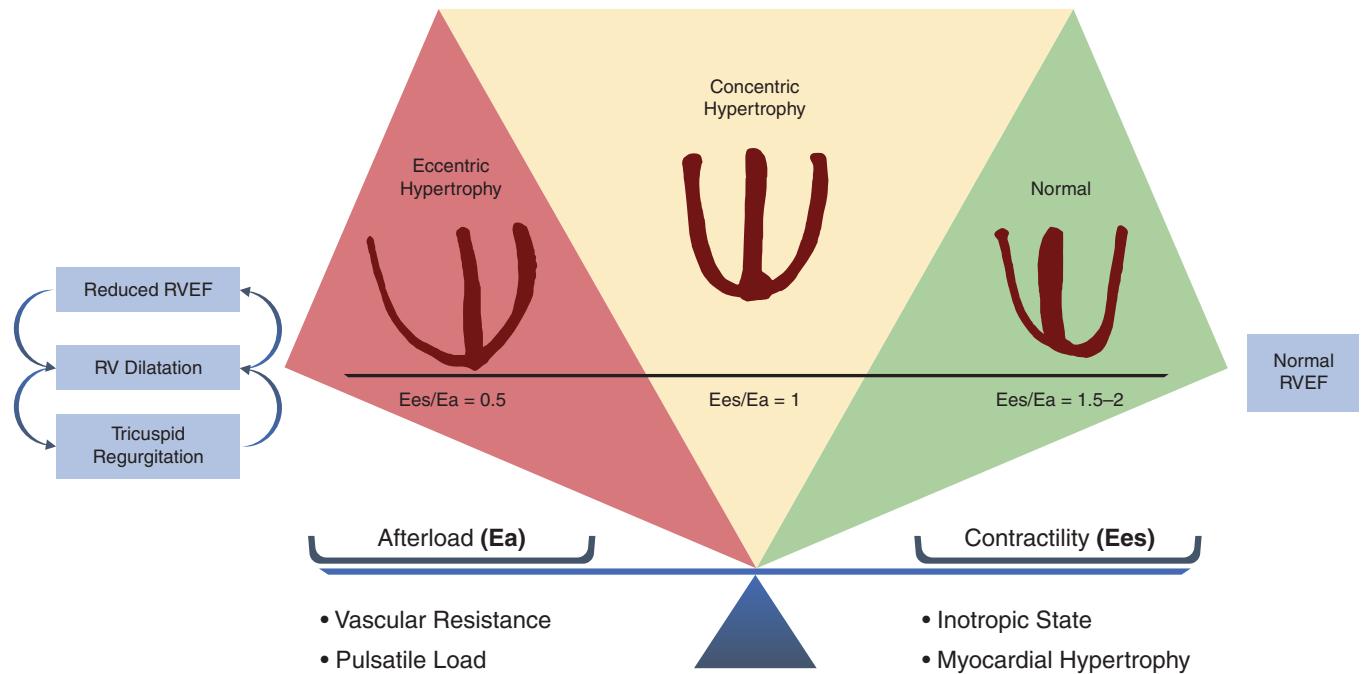


Figure 1. Diagram depicting the interplay among afterload, contractility, and right ventricular (RV) remodeling. On the left, if the increase in afterload (determined by vascular resistance and pulsatile load) is not balanced by an increase in contractility (determined by inotropic status and compensatory hypertrophy), RV–pulmonary arterial coupling decreases, with a reduction in systolic function and RV dilation. Ventricular dilatation causes enlargement of the tricuspid annulus and the appearance of functional tricuspid regurgitation. This starts a vicious cycle, with progressive RV dilatation and reduction in RV ejection fraction (RVEF). In the absence of intrinsic myocardial damage, robust afterload reduction using aggressive therapeutic interventions may restore RV–pulmonary arterial coupling close to normal values. As a result, RV dimensions and systolic function may return to normal (reverse RV remodeling). On the right, the increased afterload is balanced by an enhanced inotropic status and compensatory hypertrophy (like in congenital heart disease), and normal RV–pulmonary arterial coupling is maintained. Despite the high afterload, RV function is largely preserved. Ea = arterial elastance; Ees = end-systolic elastance.

pulmonary hypertension (CTEPH) is not identical to that of PAH, the mechanisms that cause RV dysfunction are similar. In CTEPH, mortality is directly correlated with mPAP (10). After successful pulmonary endarterectomy, near-normalization of mPAP and pulmonary vascular resistance (PVR) is associated with a large reduction in RV size and improvement in RV systolic function (11); these hemodynamic and RV changes are associated with excellent survival compared with patients who did not undergo pulmonary endarterectomy (12).

Similar hemodynamic results were obtained with balloon pulmonary angioplasty in a Japanese registry (13). In a retrospective study, substantial improvements in RV end-diastolic and end-systolic volume index, RV ejection fraction (RVEF), and mass by cardiac magnetic resonance imaging were seen (14).

Lessons from Lung Transplantation in PAH: Reverse Pulmonary Vascular Remodeling under Conditions of Hemodynamic Normalization

Lung transplantation was the only therapeutic option for PAH before the advent of specific medical treatment. Pasque and colleagues first described a uniform, early post-transplant normalization of mPAP, PVR, and RVEF that persisted throughout the 4-year follow-up period in patients with idiopathic PAH after lung transplantation (15); other series described similar and dramatic right heart reverse remodeling (RHRR) (16–18). Of note, the right ventricle recovers within a few weeks after transplantation regardless of the degree of pretransplant dilatation, dysfunction, and preoperative tricuspid regurgitation (19). An intriguing observation in some patients with PAH who have undergone single-lung transplantation is that accompanying the

near normalization of mPAP, there is regression of microvasculopathy in the remaining (native) lung (20).

Lessons from Calcium Channel Responders

In patients with idiopathic PAH who are acute responders to vasodilator challenge, high-dosage calcium channel blockers can achieve an impressive reduction in mPAP (–39%) and PVR (–50%) with very good long-term survival (21). Consequently, near normalization of RV function can be seen in those with an acute vasodilator response (22).

Key Point 1

Collectively, these data highlight that the right ventricle can recover completely upon substantial reduction or near normalization of RV afterload in CTEPH and PAH.

Table 1. Mean Pulmonary Arterial Pressure and Pulmonary Vascular Resistance or Total Pulmonary Resistance Reduction with Upfront Dual Combination Therapy and First-Line Parenteral Prostanoid Therapy in Pulmonary Arterial Hypertension

Study	Treatment Group	mPAP (mm Hg)		PVR (dyne·s·cm ⁻⁵)		RV Function/Survival
		Baseline	EOS (Reduction)	Baseline	EOS (Reduction)	
Oral combination therapy						
Sitbon <i>et al.</i> 2016 (26)	ERA + PDE-5i	54.2 ± 11.1	47.4 ± 13.3 (-12.5%)	1,021 ± 357	565 ± 252 (-44.7%)	—
Van de Veerdonk <i>et al.</i> 2017 (27)	ERA + PDE-5i	56 ± 17	43 ± 12 (-23.2%)	950	393 (-58.6%)	RVEF ↑ 34% ± 12% to 47% ± 13%; RVEDV ↓ by 5 ± 16 mL/m ²
	ERA or PDE-5i	54 ± 11	53 ± 18 (-1.9%)	705	574 (-18.6%)	RVEF ↑ 36% ± 11% to 40% ± 14% (between-group <i>P</i> < 0.001); RVEDV ↑ by 3 ± 16 mL/m ² (between-group <i>P</i> = 0.038)
D'Alto <i>et al.</i> 2018 (28)	Ambrisentan + tadalafil	50 ± 13	45 ± 15 (-10.0%)	880 ± 480	640 ± 320 (-27.3%)	—
Sitbon <i>et al.</i> 2019 (29)	Macitentan + tadalafil	—	—	—	-47%	—
Chin <i>et al.</i> 2021 (30)	Selexipag + macitentan + tadalafil	—	—	—	-54%	—
	Macitentan + tadalafil	—	—	—	-52%	—
First-line parenteral prostanoid therapy						
Rubin <i>et al.</i> 1990 (31)	i.v. epoprostenol	58.6	49.3 (-15.9%)	1,728*	1,112* (-35.6%)	—
Barst <i>et al.</i> 1996 (32)	i.v. epoprostenol	61	56.2 (-7.9%)	—	-21%	—
Simonneau <i>et al.</i> 2002 (33)	s.c. treprostinil	—	↓ 2.3 vs. ↑ 0.7 with PBO (-3.7%)	—	↓ 3.5 [†] vs. ↑ 1.2 [†] with PBO (-13.5%)	—
Sadushi-Koliçi <i>et al.</i> 2012 (34)	s.c. treprostinil	—	↓ by 5.2	—	↓ by 220	1-, 5-, 9-yr survival of 96%, 78%, and 57%, respectively
McLaughlin <i>et al.</i> 2002 (35)	i.v. epoprostenol	61 ± 13	53 ± 13 (-13.1%)	1,336 ± 512	816 ± 432 (-38.9%)	1-, 2-, and 3-yr survival of 87.8%, 76.3%, and 62.8%, respectively
Sitbon <i>et al.</i> 2002 (36)	i.v. epoprostenol	68 ± 14	60 ± 12 (-11.8%)	37.3 ± 10.5 [‡]	25.0 ± 6.9 [‡] (-33.0%)	1-, 2-, 3-, and 5-yr survival of 85%, 70%, 63%, and 55%, respectively
First-line dual combination therapy including parenteral prostanoids						
Humbert <i>et al.</i> 2004 (37)	i.v. epoprostenol + bosentan	—	Median, -9.0%	—	Median, -35.2%	—
	i.v. epoprostenol	—	Median, -2.2%	—	Median, -25.7%	—
Kemp <i>et al.</i> 2012 (38)	i.v. epoprostenol + bosentan	65 ± 12	55 ± 15 (-15.4%)	1,493 ± 398	784 ± 364 (-47.5%)	—
Bergot <i>et al.</i> 2014 (39)	i.v. epoprostenol + oral therapy	—	↓ by -9.2 ± 13.9	—	↓ by -822 ± 482	—
	i.v. epoprostenol	—	↓ by -11.9 ± 17.1 (-25.0%)	—	↓ by -521 ± 392 (-36.3%)	—
Badagliacca <i>et al.</i> 2018 (40) (matched cohorts of 4 different treatment strategies)	Parenteral prostanoid + oral therapy	54.4 ± 11	38.4 ± 8.9 (-28.7%)	1,072 ± 336	496 ± 192 (-50.7%)	Significant improvement in RVEDA and RVFAC
First-line triple combination therapy including parenteral prostanoids						
Sitbon <i>et al.</i> 2014 (41)	i.v. epoprostenol + bosentan + sildenafil	65.8 ± 13.7	44.4 ± 13.4 (-32.5%)	1,718 ± 627	492 ± 209 (-71.2%)	3-yr survival 100%
D'Alto <i>et al.</i> 2020 (42)	s.c. treprostinil + ambrisentan + tadalafil	60 ± 9	42 ± 5 (-30.0%)	1,312 ± 352	440 ± 104 (-69%)	↓ Right-sided atrial area and RVEDA, improved left ventricular eccentricity index, ↑ RVFAC; right heart reverse remodeling achieved in all patients; 2-yr survival 100%

Definition of abbreviations: EOS = end of study; ERA = endothelin receptor antagonist; i.v. = intravenous; mPAP = mean pulmonary arterial pressure; PBO = placebo; PDE-5i = phosphodiesterase type-5 inhibitor; PVR = pulmonary vascular resistance; RV = right ventricular; RVEDA = right ventricular end-diastolic area; RVEDF = right ventricular end-diastolic volume; RVEF = right ventricular ejection fraction; RVFAC = right ventricular fractional area change; s.c. = subcutaneous; WU = Wood units.

*The values provided for this study are for total pulmonary resistance.

[†]The values provided for this study are in PVR index, WU/m², representing PVR/body surface area.

[‡]The values provided for this study are for total pulmonary resistance and reported in U/m².

Effect of PAH Therapies on RV Afterload Reduction

Oral Monotherapy

The effect of PAH monotherapy on afterload reduction is mild. After 3 to 6 months of treatment, an average reduction in PVR of only -2.7 Wood units (-216 dyne·s·cm⁻⁵) and a very mild decrease in mPAP (-3.1 mm Hg) occur (23). Similarly, the effect on RV function after 16 weeks of monotherapy with bosentan achieves only trivial changes in RV areas by echocardiography (24).

Initial Oral Combination Therapy in PAH

The widespread and guideline-recommended use of initial oral combination therapy after the publication of the First-Line Ambrisentan and Tadalafil Combination Therapy in Subjects With Pulmonary Arterial Hypertension (AMBITION) trial (25) is supported by the impressive clinical outcomes. There have been smaller, mostly open-label studies that address the hemodynamic effect of this approach (Table 1) (26–42). The summary of these observations suggests that initial oral combination therapy can significantly improve hemodynamic status, with PVR reduction of 27–59% and mPAP reduction of 10–23% (from baseline). It appears clear that initial oral combination therapy produces a more pronounced hemodynamic improvement than monotherapy, with a larger impact on RV morphology/function. Nonetheless, a recent multicenter retrospective study showed that despite a median PVR decrease of 37%, approximately 50% of patients with PAH who received first-line oral combination therapy did not achieve low-risk status and needed additional treatment (43).

Initial Triple Oral Combination Therapy

Preliminary findings from the Efficacy and Safety of Initial Triple Versus Initial Dual Oral Combination Therapy in Patients With Newly Diagnosed Pulmonary Arterial Hypertension (TRITON) study revealed similar reductions in PVR with upfront triple combination (macitentan, tadalafil, and selexipag) as with dual combination (macitentan and tadalafil) therapy after 26 weeks of treatment (-54% vs. -52% , respectively) (30). The

effects on 6-minute walking distance and N-terminal pro brain natriuretic peptide were similar (30).

Initial or Early Parenteral Prostanoids

Parenteral prostanoids were the first drugs approved for the treatment of PAH. Historically, treatment with parenteral prostanoids improved hemodynamic status, with mPAP reduction of 8–16% and PVR reduction of 14–39%, both from baseline (Table 1) (26–42). Contemporary treatment with parenteral treprostinil (sometimes as sequential combination) uses considerably higher doses, with additional gains in all relevant hemodynamic measures (34, 40, 44).

Initial Dual Combination Therapy with Parenteral Prostanoids

Initial dual combination therapy including a parenteral prostanoid (one oral plus parenteral) can significantly improve hemodynamic status, with mPAP reduction of 9–29% and PVR reduction of 35–56% (37–39). In a recent study, authors analyzed matched cohorts of four different treatment strategies, and the numerically largest improvement in hemodynamics was achieved when patients took an initial combination of parenteral prostanoid plus single oral therapy (Table 1) (26–42).

Initial Triple Combination Therapy Including Parenteral Prostanoids

Although reports of this approach are limited, several recent observations highlight the therapeutic potential of this strategy (Table 1) (26–42). These studies suggest that upfront triple combination therapy that includes a parenteral prostanoid reduces PVR by around 70% and mPAP by around 30%. In one of these studies, upfront triple combination therapy with subcutaneous treprostinil, ambrisentan, and tadalafil was also associated with RHRR in all patients. A recent analysis supports the hypothesis that triple combination therapy including a parenteral prostanoid is the only approach that reduces mortality in PAH compared with other strategies (45). In the absence of rigorous data for lower-risk disease, this approach should be considered with caution, as the potential risk (infection) and side effects may outweigh the benefit. Similar hemodynamic and clinical results were not observed with selexipag, an oral

nonprostanoid agonist of the prostacyclin receptor (30).

Initial Parenteral Prostanoid Therapy Guided by Hemodynamic Follow-Up

In Japan, Matsubara and Ogawa developed a treatment approach for early initiation and rapid uptitration of parenteral prostanoids in all patients with hemodynamically severe PAH (mPAP > 50 mm Hg) (46). Their goal was to rapidly titrate epoprostenol to an approximate dose of 40–60 ng/kg/min in combination with an endothelin receptor antagonist and/or phosphodiesterase type-5 inhibitor to normalize mPAP. Using this titration scheme in 56 patients with idiopathic/heritable PAH, mPAP decreased from 63 ± 15 mm Hg to 35 ± 10 mm Hg (mean reduction, -44% ; $P < 0.01$) and PVR decreased from $1,473 \pm 600$ dyne·s·cm⁻⁵ to 481 ± 421 dyne·s·cm⁻⁵ (mean reduction -67.3% ; $P < 0.01$). The hemodynamic results in this retrospective cohort were associated with excellent long-term survival rates of 98%, 96%, 96%, and 78% at 1, 3, 5, and 10 years, respectively (47). Importantly, the authors also found that the mPAP achieved after treatment was an important predictor of prognosis. Patients who achieved mPAP < 42.5 mm Hg had the best survival during the study period (46). This study suggests that 40 mm Hg may be a biological threshold, as seen in patients with CTEPH undergoing balloon pulmonary angioplasty (13), a pressure at which prognosis is improved with fewer complications.

More recently, using an implantable CardioMEMS sensor to monitor pulmonary pressure at home, Benza and colleagues tailored PAH therapy (mostly parenteral prostacyclin therapies) using trends in PAP-based metrics to improve stroke volume index and RV efficiency while reducing total peripheral resistance and elastance (48). After 1 month, they observed a significant reduction in mPAP (42 ± 13 mm Hg to 34 ± 14 mm Hg; $P < 0.05$) and an improvement in cardiac output (5.8 ± 1.5 L/min to 6.8 ± 1.8 L/min; $P < 0.05$) (48). Patients were aggressively managed, with serial changes in parenteral prostacyclin therapies within the first 4 months based on continuous monitoring. In this pilot study, the authors concluded that close monitoring of cardiopulmonary hemodynamics enabled targeted uptitration of parenteral prostanoids in patients with PAH.

Figure 2 summarizes the reductions in mPAP and PVR by study for the different combinations and prostanoid therapy options (26–42, 47, 48).

Late Add-On of Parenteral Prostanoids

Studies have consistently shown that the late use of parenteral prostanoids in patients with advanced disease may have little clinical benefit. Adding epoprostenol to bosentan was associated with clinical and survival benefits in patients with World Health Organization Functional Class (WHO FC) III symptoms but not for those with WHO FC IV disease (49). Similar results supporting earlier prostacyclin use were noted in an Italian observational study, which included late referrals for the initiation of parenteral prostanoids. The authors noted in this retrospective study that the late initiation of parenteral drug was associated with poor prognosis compared with those referred earlier. They hypothesized that this poor prognosis was related to the advanced clinical and hemodynamic status of the patients who had been maintained on oral drugs despite evidence of clinical deterioration (50). Similarly, in a study in which intravenous treprostinil was added after detection of an insufficient response (6–12 mo) to oral combination therapy, only a mild mPAP reduction from 55 mm Hg to 51 mm Hg and a PVR reduction from 936 $\text{dyne}\cdot\text{s}\cdot\text{cm}^{-5}$ to 696 $\text{dyne}\cdot\text{s}\cdot\text{cm}^{-5}$ was observed. In addition, only 19% of patients achieved low-risk status at follow-up. Although long-term survival of patients who sufficiently responded to treatment escalation with treprostinil was excellent, median survival of patients who did not achieve low-risk status after the initiation of treprostinil therapy was only 2.1 years (51).

Key Point 2

Aggressive treatment approaches, especially those which include an early parenteral prostanoid, seem to improve cardiopulmonary hemodynamics in PAH more efficiently than more moderate early or delayed sequential approaches, especially for higher-risk patients. An aggressive approach correlates with good patient outcomes and more robust reductions in mPAP and PVR, which seems to be key in reversing adverse pulmonary arterial and right heart remodeling.

RV Morphology, Function, and Afterload

RV dysfunction in PAH is mainly caused by afterload mismatch; however, few studies have addressed the effect of afterload reduction on RV function after PAH-specific medication. One series of 110 patients with PAH who were primarily treated with monotherapy found an inverse correlation between changes in PVR and cardiac magnetic resonance imaging–measured RVEF after an average of 1 year of treatment (52). More recently, a multicenter prospective study addressed the frequency of RHRR, defined as a decrease in RV end-diastolic area (RVEDA), right atrial area, and left ventricular systolic eccentricity index, in 102 treatment-naïve patients with idiopathic PAH. After 1 year of therapy, the likelihood of RHRR was related to a reduction in PVR of >50%. RHRR was an independent predictor of prognosis in PAH and a good predictor of patients' risk stratification using the Registry to Evaluate Early And Long-term pulmonary arterial hypertension disease management (REVEAL) risk score (40).

Studies of RHRR have only recently started, and thus we lack a robust definition. It seems clinically sound to have a composite assessment of multiple morphological parameters; we propose that RVEDA, RV fractional area change (RVFAC), right atrial area, and left ventricular eccentricity index would be reasonable components, some of which have been shown to have prognostic relevance in the evaluation of treatment response (57, 58).

Another recent study highlights the importance of improving RVEDA by reducing mPAP to achieve beneficial effects on the patient's risk profile (53). These results are similar to those from a different study evaluating the utility of stroke volume index after initial management of PAH (54); this important study demonstrated that intermediate-risk patients are a diverse group poorly characterized by risk stratification alone. In fact, after initial therapy, about 25% of those patients had progressive RV dilatation, whereas about 40% experienced reductions in mPAP and RVEDA; stroke volume index was a useful differentiator in separating those with good and poor clinical prognosis. An aggressive afterload reduction strategy may be particularly important in men with PAH (55) and patients with

intrinsic RV disease (e.g., an “at-risk” ventricle from systemic sclerosis) (56).

The optimal therapeutic strategy to reverse RV and right atrial remodeling in severe PAH remains to be defined, but a recent retrospective study suggests the importance of early and aggressive combination therapy that includes parenteral prostanoids. In this study, intermediate-risk patients (defined according to the European Society of Cardiology/European Respiratory Society risk table) were treated with various therapeutic approaches: initial parenteral prostanoid with single oral, initial oral combination, upfront oral combination, oral monotherapy, or parenteral prostanoid monotherapy. After an average of 6 months, the largest reduction in mPAP and PVR occurred with initial parenteral prostanoid and single oral. The authors found a clear relationship between PVR and both RVEDA and RV fractional area change. Significant improvement in RVEDA and RV fractional area change was seen only with a large reduction in PVR (>40%) (40). Similarly, a recent analysis of a monocentric cohort shows that the likelihood of normalizing RVEDA is a sigmoid function of PVR changes. In that cohort, RVEDA normalization required a drop in PVR of >50% with treatment (57).

Key Point 3

Robust hemodynamic improvements (afterload reduction) are required to reverse pathologic remodeling of the right ventricle and restore RV function to normal in PAH.

Open Questions and Issues

Which Afterload Parameter Should We Use?

Afterload has two main components: vascular resistance to a continuous flow (evaluated by PVR) and resistance to pulsatile flow (assessed by pulmonary arterial compliance [PAC]) (59). Given the inverse curvilinear relationship between these components (4–6), it is likely that PAC will improve in patients with a larger reduction in PVR. Few studies compare the prognostic impact of these parameters, and the results are not consistent. Some studies found that PAC had a stronger prognostic impact than PVR (60–62), whereas another study determined PAC was not an important prognostic factor (54). We focused on PVR

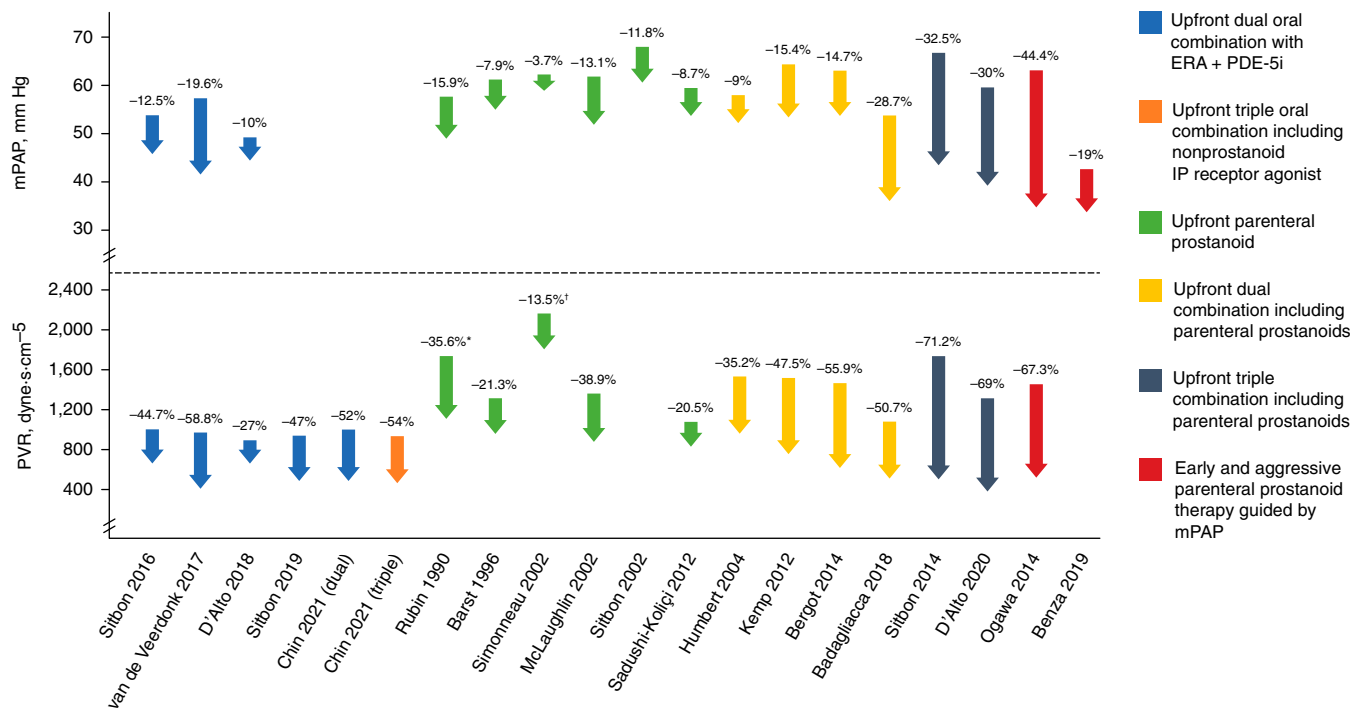


Figure 2. Reductions in mean pulmonary arterial pressure (mPAP) and pulmonary vascular resistance (PVR) in the studies cited in the article (23–39, 44, 45). The beginning of each arrow aligns with the mean baseline value, and the tip of the arrow aligns with the mean value after treatment. Mean percentage reduction from baseline is stated above the arrow. Note that the baseline values are different among the studies; on average, the studies that used parenteral prostanoids in combination with other drugs included patients with higher mPAP and PVR values than those in the other therapeutic strategies. *The values provided for this study are for total pulmonary resistance in Wood units (WU). [†]The values provided for this study are in PVR index, WU/m², representing PVR/body surface area. ERA = endothelin receptor antagonist; IP receptor = prostacyclin receptor; PDE-5i = phosphodiesterase type-5 inhibitor.

because most studies of hemodynamics in PAH documented PVR changes, not PAC. Pulmonary arterial elastance is a parameter that includes both components; it has the potential of clinical application in its simplified version as pulmonary arterial effective elastance, but there is a methodologic debate on the best way to calculate it (63, 64).

mPAP May Not Be a Reliable Measure of PAH Severity

mPAP reflects both PAC and PVR. In extreme cases of PAH, the systolic function of the right ventricle could deteriorate to the point at which it is unable to generate adequate PAP and flow. In such situations, a reduction in mPAP could be misleading, because it would not be a sign of hemodynamic improvement. Therefore, as discussed previously, the reduction in mPAP or PVR should be associated with an improvement in RV function and morphology. Potential disagreements between risk status and hemodynamics need to be reconciled in prospective studies.

Oral Combination Therapy Could Be Enough to Decrease Afterload

In treatment-naïve patients, initial oral combination therapy reduces morbidity and is sometimes very effective at reducing PVR (i.e., between 40% and 50% of baseline in some studies) (26–30). Despite these favorable results, only around 50% of 106 patients in one cohort maintained low-risk status at 2 years (43). In a larger cohort of 181 patients, although improvement in risk status was related to PVR reduction, only about 30% of patients had a moderate PVR reduction (>25% after treatment) (65). Considering the progressive nature of PAH, these data suggest patients treated with initial combination therapy should be monitored closely with early treatment escalation if they do not achieve low-risk status (or as soon as they deteriorate from low-risk status at a later time) (3). The Riociguat replacing PDE-5i Therapy evaluated Against Continued PDE-5i therapy (REPLACE) study results suggest clinical improvement in about 40% of patients when switching from a phosphodiesterase type-5 inhibitor to

riociguat, and uncontrolled, open-label data with riociguat suggest improvements in hemodynamics for a similar population (66, 67). Addition of selexipag, including the subset of patients already on combined phosphodiesterase type-5 inhibitor and endothelin receptor antagonist, was shown to improve outcomes in the Selexipag in Pulmonary Arterial Hypertension (GRIPHON) study (68). However, subsequent analysis of the overall GRIPHON cohort found that for those at highest risk based on N-terminal pro brain natriuretic peptide values > 1,400 pg/ml, morbidity remained high (69). Early parenteral prostanoids are a rational, guideline-based choice in most patients who do not achieve low-risk status at early follow-up and especially for those who deteriorate from low-risk status at a later time point.

Limitations of Treatment with Parenteral Prostanoids

Limitations of treatment with parenteral prostanoids include the burden and management of continuous infusion, side

effects (myalgia, flushing, headache, nausea, diarrhea, and perhaps thrombocytopenia), risk of systemic infections with intravenous administration, and local pain (sometimes intense) from subcutaneous administration (70). Given these limitations, patients are often understandably reluctant to accept this therapy. A patient support program with qualified personnel is required for adherence and to maintain quality of life (71).

Excessive Dose Titration of Parenteral Prostanoids and the Risk of High Cardiac Output Syndrome

Titration of parenteral prostanoids remains controversial. Most expert centers treat patients with periodic, slow, and steady dose escalation (every 1–2 wk) of prostanoid after discharge from the hospital, until they reach a maximally tolerated dose. According to Rich and colleagues, this approach could cause high cardiac output syndrome (72). In a series of 55 patients, 12 patients complained of flushing, bloating, and fatigue and had a normal to hypercontractile left ventricle. Those patients were treated with very high epoprostenol doses (98 + 61 ng/kg/min) and had a significant reduction in mPAP (–25% from baseline) and PVR (–71%), an increase in cardiac output (10.1 + 2.3 L/min), and a significant improvement in WHO FC (75% in FC I and 25% in FC II). The authors were able to reduce the epoprostenol dose by an average of 39% without any significant immediate change in mPAP, and all patients remained in WHO FC I or II after an average of 13.6 months (72). This observation underscores the need for careful follow-up of patients; it also raises the possibility of continuous ambulatory pulmonary pressure monitoring in prostanoid treatment to achieve dose optimization and avoid undesirable effects and overdose (48).

Transition from Parenteral Prostanoid to Inhaled Prostanoid, Oral Prostanoid, or Selexipag

Inhaled prostanoids (iloprost, treprostinil), oral prostanoids (treprostinil, beraprost), and selexipag were developed to overcome problems associated with parenteral

administration of prostanoids, but the clinical efficacy seems lower (73). Currently no controlled trials have addressed this approach or the unmet medical need represented by patients who experience severe side effects from parenteral administration. Results from several small uncontrolled studies suggest that switching from parenteral to inhaled or oral prostanoids is an option in stable patients with good clinical and hemodynamic status (74).

Conclusions

The results of numerous studies suggest, independently and collectively, that greater reduction of RV afterload improves RV function and clinical outcomes. Initial oral combination and especially treatment regimens using parenteral prostacyclin early in the disease process provide greater hemodynamic improvement in patients with PAH. Based on published literature and a strong body of clinical experience, rigorous afterload reduction may enable profound reverse remodeling of the right ventricle. Thus, targeting afterload reduction using a hemodynamics-guided strategy early in treatment is likely to significantly improve RV function. The timing of right catheterization during the follow-up is an open question, but it seems appropriate to have an invasive assessment if the patients do not reach a low-risk status despite maximal oral therapy or when there is a discrepancy between risk status and RV morphology and function. This treatment paradigm needs to be tested prospectively in patients with PAH, particularly those with an intermediate- or high-risk status at early follow-up. We understand that triple therapy including parenteral prostacyclins may not be universally available. However, from a policy perspective, we note that monotherapy is rarely sufficient to achieve meaningful goals, whereas 40–50% of patients in the Italian cohort achieved low-risk status and substantial reduction in PVR on initial combination therapy (43).

Optimizing Knowledge: Call for Action

- Significant afterload reduction with subsequent improvement in right heart structure and function is feasible.
- Upfront combination therapy with two or three drugs including parenteral prostanoids results in greater RV afterload reduction, which leads to measurable improvements in structure and function of right heart cavities.
- Early use of parenteral prostanoids at an adequate dosage reduces RV afterload more effectively and efficiently than late use.
- Guidance of treatment strategies by hemodynamic monitoring might lead to more substantial RV afterload reduction and better clinical outcomes.
- To validate these concepts:
- Information on RV function and RV afterload should be collected in future clinical trials and prospective registries.
- Treatment strategies that substantially improve or even normalize RV afterload should be developed and investigated in randomized controlled clinical trials. Additional investigations on the effect of upfront triple combination, including a parenteral prostacyclin versus dual upfront tablet combination in intermediate-risk patients, are needed.
- mPAP or PVR, as an independent risk factor, should be assessed against other independent risk factors that inform the various risk stratification schemes. ■

Author disclosures are available with the text of this article at www.atsjournals.org.

Acknowledgment: Editorial support was provided by William Fiedelman, M.D., Laura Sitrler, E.L.S. (Omni Healthcare Communications), and Kevin Maher, P.M.P., C.C.R.P. (United Therapeutics Corporation), funded by United Therapeutics Corporation.

References

- Galiè N, Humbert M, Vachiery JL, Gibbs S, Lang I, Torbicki A, *et al*. 2015 ESC/ERS Guidelines for the diagnosis and treatment of pulmonary hypertension: The Joint Task Force for the Diagnosis and Treatment of Pulmonary Hypertension of the European Society of Cardiology (ESC) and the European Respiratory Society (ERS): Endorsed by: Association for European Paediatric and Congenital Cardiology (AEPC), International Society for Heart and Lung Transplantation (ISHLT). *Eur Respir J* 2015;46:903–975.
- Boucly A, Weatherald J, Savale L, Jaïs X, Cottin V, Prevot G, *et al*. Risk assessment, prognosis and guideline implementation in pulmonary arterial hypertension. *Eur Respir J* 2017;50:1700889.
- Galiè N, Channick RN, Frantz RP, Grünig E, Jing ZC, Moiseeva O, *et al*. Risk stratification and medical therapy of pulmonary arterial hypertension. *Eur Respir J* 2019;53:1801889.
- Vonk Noordegraaf A, Westerhof BE, Westerhof N. The relationship between the right ventricle and its load in pulmonary hypertension. *J Am Coll Cardiol* 2017;69:236–243.
- Sanz J, Sánchez-Quintana D, Bossone E, Bogaard HJ, Naeije R. Anatomy, function, and dysfunction of the right ventricle: JACC State-of-the-Art Review. *J Am Coll Cardiol* 2019;73:1463–1482.
- Naeije R, Vanderpool R, Peacock A, Badagliacca R. The right heart-pulmonary circulation unit: physiopathology. *Heart Fail Clin* 2018;14:237–245.
- Hsu S, Houston BA, Tampakakis E, Bacher AC, Rhodes PS, Mathai SC, *et al*. Right ventricular functional reserve in pulmonary arterial hypertension. *Circulation* 2016;133:2413–2422.
- Tedford RJ, Mudd JO, Girgis RE, Mathai SC, Zaiman AL, Houston-Harris T, *et al*. Right ventricular dysfunction in systemic sclerosis-associated pulmonary arterial hypertension. *Circ Heart Fail* 2013;6:953–963.
- Frustaci A, Petrosillo N, Vizza D, Francone M, Badagliacca R, Verardo R, *et al*. Myocardial and microvascular inflammation/infection in patients with HIV-associated pulmonary artery hypertension. *AIDS* 2014;28:2541–2549.
- Riedel M, Stanek V, Widimsky J, Prerovsky I. Longterm follow-up of patients with pulmonary thromboembolism: late prognosis and evolution of hemodynamic and respiratory data. *Chest* 1982;81:151–158.
- D'Armini AM, Zanotti G, Ghio S, Magrini G, Pozzi M, Scelsi L, *et al*. Reverse right ventricular remodeling after pulmonary endarterectomy. *J Thorac Cardiovasc Surg* 2007;133:162–168.
- Delcroix M, Lang I, Pepke-Zaba J, Jansa P, D'Armini AM, Snijder R, *et al*. Long-term outcome of patients with chronic thromboembolic pulmonary hypertension: results from an international prospective registry. *Circulation* 2016;133:859–871.
- Ogawa A, Satoh T, Fukuda T, Sugimura K, Fukumoto Y, Emoto N, *et al*. Balloon pulmonary angioplasty for chronic thromboembolic pulmonary hypertension: results of a multicenter registry. *Circ Cardiovasc Qual Outcomes* 2017;10:e004029.
- Fukui S, Ogo T, Morita Y, Tsuji A, Tateishi E, Ozaki K, *et al*. Right ventricular reverse remodeling after balloon pulmonary angioplasty. *Eur Respir J* 2014;43:1394–1402.
- Pasque MK, Trulock EP, Cooper JD, Triantafillou AN, Huddleston CB, Rosenbloom M, *et al*. Single lung transplantation for pulmonary hypertension: single institution experience in 34 patients. *Circulation* 1995;92:2252–2258.
- Kasimir MT, Seebacher G, Jaksch P, Winkler G, Schmid K, Marta GM, *et al*. Reverse cardiac remodeling in patients with primary pulmonary hypertension after isolated lung transplantation. *Eur J Cardiothorac Surg* 2004;26:776–781.
- Gorter TM, Verschuren EAM, van Veldhuisen DJ, Hoendermis ES, Erasmus ME, Bogaard HJ, *et al*. Right ventricular recovery after bilateral lung transplantation for pulmonary arterial hypertension. *Interact Cardiovasc Thorac Surg* 2017;24:890–897.
- Sarashina T, Nakamura K, Akagi S, Oto T, Oe H, Ejiri K, *et al*. Reverse right ventricular remodeling after lung transplantation in patients with pulmonary arterial hypertension under combination therapy of targeted medical drugs. *Circ J* 2017;81:383–390.
- Hoeper MM, Benza RL, Corris P, de Perrot M, Fadel E, Keogh AM, *et al*. Intensive care, right ventricular support and lung transplantation in patients with pulmonary hypertension. *Eur Respir J* 2019;53:1801906.
- Levy NT, Liapis H, Eisenberg PR, Botney MD, Trulock EP. Pathologic regression of primary pulmonary hypertension in left native lung following right single-lung transplantation. *J Heart Lung Transplant* 2001;20:381–384.
- Sitbon O, Humbert M, Jaïs X, Iosif V, Hamid AM, Provencher S, *et al*. Long-term response to calcium channel blockers in idiopathic pulmonary arterial hypertension. *Circulation* 2005;111:3105–3111.
- Huez S, Vachiery JL, Naeije R. Improvement in right ventricular function during reversibility testing in pulmonary arterial hypertension: a case report. *Cardiovasc Ultrasound* 2009;7:9.
- Coeytaux RR, Schmit KM, Kraft BD, Kosinski AS, Mingo AM, Vann LM, *et al*. Comparative effectiveness and safety of drug therapy for pulmonary arterial hypertension: a systematic review and meta-analysis. *Chest* 2014;145:1055–1063.
- Galiè N, Hinderliter AL, Torbicki A, Fourme T, Simonneau G, Pulido T, *et al*. Effects of the oral endothelin-receptor antagonist bosentan on echocardiographic and doppler measures in patients with pulmonary arterial hypertension. *J Am Coll Cardiol* 2003;41:1380–1386.
- Galiè N, Barberà JA, Frost AE, Ghofrani HA, Hoeper MM, McLaughlin VV, *et al*; AMBITION Investigators. Initial use of ambrisentan plus tadalafil in pulmonary arterial hypertension. *N Engl J Med* 2015;373:834–844.
- Sitbon O, Sattler C, Bertoletti L, Savale L, Cottin V, Jaïs X, *et al*. Initial dual oral combination therapy in pulmonary arterial hypertension. *Eur Respir J* 2016;47:1727–1736.
- van de Veerdonk MC, Huis In T Veld AE, Marcus JT, Westerhof N, Heymans MW, Bogaard HJ, *et al*. Upfront combination therapy reduces right ventricular volumes in pulmonary arterial hypertension. *Eur Respir J* 2017;49:1700007.
- D'Alto M, Romeo E, Argiento P, Paciocco G, Prediletto R, Ghio S, *et al*. Initial tadalafil and ambrisentan combination therapy in pulmonary arterial hypertension: cLinical and haemodyNamic long-term efficacy (ITALY study). *J Cardiovasc Med (Hagerstown)* 2018;19:12–17.
- Sitbon O, Cottin V, Canuet M, Cleron P, Gressin V, Perchenet L, *et al*. Initial combination therapy of macitentan and tadalafil in pulmonary arterial hypertension. *Eur Respir J* 2020;56:2000673.
- Chin KM, Sitbon O, Doelberg M, Feldman J, Gibbs JSR, Grünig E, *et al*. Three- versus two-drug therapy for patients with newly diagnosed pulmonary arterial hypertension. *J Am Coll Cardiol* 2021;78:1393–1403.
- Rubin LJ, Mendoza J, Hood M, McGoon M, Barst R, Williams WB, *et al*. Treatment of primary pulmonary hypertension with continuous intravenous prostacyclin (epoprostenol): results of a randomized trial. *Ann Intern Med* 1990;112:485–491.
- Barst RJ, Rubin LJ, Long WA, McGoon MD, Rich S, Badesch DB, *et al*; Primary Pulmonary Hypertension Study Group. A comparison of continuous intravenous epoprostenol (prostacyclin) with conventional therapy for primary pulmonary hypertension. *N Engl J Med* 1996;334:296–301.
- Simonneau G, Barst RJ, Galiè N, Naeije R, Rich S, Bourge RC, *et al*; Treprostinil Study Group. Continuous subcutaneous infusion of treprostinil, a prostacyclin analogue, in patients with pulmonary arterial hypertension: a double-blind, randomized, placebo-controlled trial. *Am J Respir Crit Care Med* 2002;165:800–804.
- Sadushi-Kolici R, Skoro-Sajer N, Zimmer D, Bonderman D, Schemper M, Klepetko W, *et al*. Long-term treatment, tolerability, and survival with sub-cutaneous treprostinil for severe pulmonary hypertension. *J Heart Lung Transplant* 2012;31:735–743.
- McLaughlin VV, Shillington A, Rich S. Survival in primary pulmonary hypertension: the impact of epoprostenol therapy. *Circulation* 2002;106:1477–1482.
- Sitbon O, Humbert M, Nunes H, Parent F, Garcia G, Hervé P, *et al*. Long-term intravenous epoprostenol infusion in primary pulmonary hypertension: prognostic factors and survival. *J Am Coll Cardiol* 2002;40:780–788.
- Humbert M, Barst RJ, Robbins IM, Channick RN, Galiè N, Boonstra A, *et al*. Combination of bosentan with epoprostenol in pulmonary arterial hypertension: BREATHE-2. *Eur Respir J* 2004;24:353–359.

38. Kemp K, Savale L, O'Callaghan DS, Jaïs X, Montani D, Humbert M, *et al.* Usefulness of first-line combination therapy with epoprostenol and bosentan in pulmonary arterial hypertension: an observational study. *J Heart Lung Transplant* 2012;31:150–158.
39. Bergot E, Sitbon O, Cottin V, Prévot G, Canuet M, Bourdin A, *et al.* Current epoprostenol use in patients with severe idiopathic, heritable or anorexigen-associated pulmonary arterial hypertension: data from the French pulmonary hypertension registry. *Int J Cardiol* 2014;172:561–567.
40. Badagliacca R, Raina A, Ghio S, D'Alto M, Confalonieri M, Correale M, *et al.* Influence of various therapeutic strategies on right ventricular morphology, function and hemodynamics in pulmonary arterial hypertension. *J Heart Lung Transplant* 2018;37:365–375.
41. Sitbon O, Jaïs X, Savale L, Cottin V, Bergot E, Macari EA, *et al.* Upfront triple combination therapy in pulmonary arterial hypertension: a pilot study. *Eur Respir J* 2014;43:1691–1697.
42. D'Alto M, Badagliacca R, Argiento P, Romeo E, Farro A, Papa S, *et al.* Risk reduction and right heart reverse remodeling by upfront triple combination therapy in pulmonary arterial hypertension. *Chest* 2020; 157:376–383.
43. D'Alto M, Badagliacca R, Lo Giudice F, Argiento P, Casu G, Corda M, *et al.* Hemodynamics and risk assessment 2 years after the initiation of upfront ambrisentan–tadalafil in pulmonary arterial hypertension. *J Heart Lung Transplant* 2020;39:1389–1397.
44. White RJ, Levin Y, Wessman K, Heiningner A, Frutiger K. Subcutaneous treprostinil is well tolerated with infrequent site changes and analgesics. *Pulm Circ* 2013;3:611–621.
45. Boucly A, Savale L, Jaïs X, Bauer F, Bergot E, Bertoletti L, *et al.* Association between initial treatment strategy and long-term survival in pulmonary arterial hypertension. *Am J Respir Crit Care Med* 2021;204: 842–854.
46. Matsubara H, Ogawa A. Treatment of idiopathic/hereditary pulmonary arterial hypertension. *J Cardiol* 2014;64:243–249.
47. Ogawa A, Ejiri K, Matsubara H. Long-term patient survival with idiopathic/hereditary pulmonary arterial hypertension treated at a single center in Japan. *Life Sci* 2014;118:414–419.
48. Benza RL, Doyle M, Lasorda D, Parikh KS, Correa-Jaque P, Badie N, *et al.* Monitoring pulmonary arterial hypertension using an implantable hemodynamic sensor. *Chest* 2019;156:1176–1186.
49. Provencher S, Sitbon O, Humbert M, Cabrol S, Jaïs X, Simonneau G. Long-term outcome with first-line bosentan therapy in idiopathic pulmonary arterial hypertension. *Eur Heart J* 2006;27:589–595.
50. Badagliacca R, Pezzuto B, Poscia R, Mancone M, Papa S, Marcon S, *et al.* Prognostic factors in severe pulmonary hypertension patients who need parenteral prostanoid therapy: the impact of late referral. *J Heart Lung Transplant* 2012;31:364–372.
51. Olsson KM, Richter MJ, Kamp JC, Gall H, Heine A, Ghofrani HA, *et al.* Intravenous treprostinil as an add-on therapy in patients with pulmonary arterial hypertension. *J Heart Lung Transplant* 2019;38:748–756.
52. van de Veerdonk MC, Kind T, Marcus JT, Mauritz GJ, Heymans MW, Bogaard HJ, *et al.* Progressive right ventricular dysfunction in patients with pulmonary arterial hypertension responding to therapy. *J Am Coll Cardiol* 2011;58:2511–2519.
53. Badagliacca R, Papa S, Matsubara H, Lang IM, Poscia R, Manzi G, *et al.* The importance of right ventricular evaluation in risk assessment and therapeutic strategies: raising the bar in pulmonary arterial hypertension. *Int J Cardiol* 2020;301:183–189.
54. Weatherald J, Boucly A, Chemla D, Savale L, Peng M, Jevnikar M, *et al.* Prognostic value of follow-up hemodynamic variables after initial management in pulmonary arterial hypertension. *Circulation* 2018;137: 693–704.
55. Tello K, Richter MJ, Yogeswaran A, Ghofrani HA, Naeije R, Vanderpool R, *et al.* Sex differences in right ventricular-pulmonary arterial coupling in pulmonary arterial hypertension. *Am J Respir Crit Care Med* 2020; 202:1042–1046.
56. Tedford RJ, Mudd JO, Girgis RE, Mathai SC, Zaiman AL, Hosten-Harris T, *et al.* Right ventricular dysfunction in systemic sclerosis-associated pulmonary arterial hypertension. *Circ Heart Fail* 2013;6:953–963.
57. Badagliacca R, Papa S, Manzi G, Miotti C, Luongo F, Sciomer S, *et al.* Usefulness of adding echocardiography of the right heart to risk-assessment scores in prostanoid-treated pulmonary arterial hypertension. *JACC Cardiovasc Imaging* 2020;13:2054–2056.
58. Badagliacca R, Poscia R, Pezzuto B, Papa S, Reali M, Pesce F, *et al.* Prognostic relevance of right heart reverse remodeling in idiopathic pulmonary arterial hypertension. *J Heart Lung Transplant* 2018;37: 195–205.
59. Laskey WK, Ferrari VA, Palevsky HI, Kussmaul WG. Pulmonary artery hemodynamics in primary pulmonary hypertension. *J Am Coll Cardiol* 1993;21:406–412.
60. Al-Naamani N, Preston IR, Hill NS, Roberts KE. The prognostic significance of pulmonary arterial capacitance in pulmonary arterial hypertension: single-center experience. *Pulm Circ* 2016;6: 608–610.
61. Mahapatra S, Nishimura RA, Sorajja P, Cha S, McGoon MD. Relationship of pulmonary arterial capacitance and mortality in idiopathic pulmonary arterial hypertension. *J Am Coll Cardiol* 2006;47: 799–803.
62. Ghio S, D'Alto M, Badagliacca R, Vitulo P, Argiento P, Mulè M, *et al.* Prognostic relevance of pulmonary arterial compliance after therapy initiation or escalation in patients with pulmonary arterial hypertension. *Int J Cardiol* 2017;230:53–58.
63. Brener MI, Burkhoff D, Sunagawa K. Effective arterial elastance in the pulmonary arterial circulation: derivation, assumptions, and clinical applications. *Circ Heart Fail* 2020;13:e006591.
64. Tedford RJ, Hsu S, Kass DA. Letter by Tedford *et al.* regarding article, “Effective arterial elastance in the pulmonary arterial circulation: derivation, assumptions, and clinical applications”. *Circ Heart Fail* 2020; 13:e007081.
65. Badagliacca R, D'Alto M, Ghio S, Argiento P, Bellomo V, Brunetti ND, *et al.* Risk reduction and hemodynamics with initial combination therapy in pulmonary arterial hypertension. *Am J Respir Crit Care Med* 2021; 203:484–492.
66. Hoeper MM, Al-Hiti H, Benza RL, Chang SA, Corris PA, Gibbs JSR, *et al.*; REPLACE investigators. Switching to riociguat versus maintenance therapy with phosphodiesterase-5 inhibitors in patients with pulmonary arterial hypertension (REPLACE): a multicentre, open-label, randomised controlled trial. *Lancet Respir Med* 2021;9: 573–584.
67. Hoeper MM, Simonneau G, Corris PA, Ghofrani H-A, Klinger JR, Langleben D, *et al.* RESPITE: switching to riociguat in pulmonary arterial hypertension patients with inadequate response to phosphodiesterase-5 inhibitors. *Eur Respir J* 2017;50: 1602425.
68. Sitbon O, Channick R, Chin KM, Frey A, Gaine S, Galie N, *et al.*; GRIPHON Investigators. Selexipag for the treatment of pulmonary arterial hypertension. *N Engl J Med* 2015;373: 2522–2533.
69. Chin KM, Rubin LJ, Channick R, Di Scala L, Gaine S, Galie N, *et al.* Association of N-terminal pro brain natriuretic peptide and long-term outcome in patients with pulmonary arterial hypertension. *Circulation* 2019;139:2440–2450.
70. Lang IM, Gaine SP. Recent advances in targeting the prostacyclin pathway in pulmonary arterial hypertension. *Eur Respir Rev* 2015;24: 630–641.
71. Farber HW, Gin-Sing W. Practical considerations for therapies targeting the prostacyclin pathway. *Eur Respir Rev* 2016;25:418–430.
72. Rich S, McLaughlin VV. The effects of chronic prostacyclin therapy on cardiac output and symptoms in primary pulmonary hypertension. *J Am Coll Cardiol* 1999;34:1184–1187.
73. Jain S, Khera R, Girotra S, Badesch D, Wang Z, Murad MH, *et al.* Comparative effectiveness of pharmacologic interventions for pulmonary arterial hypertension: a systematic review and network meta-analysis. *Chest* 2017;151:90–105.
74. Sofer A, Ryan MJ, Tedford RJ, Wirth JA, Fares WH. A systematic review of transition studies of pulmonary arterial hypertension specific medications. *Pulm Circ* 2017;7:326–338.