

Endoscopic diagnosis of gastric intestinal metaplasia in patients with autoimmune gastritis using narrow-band imaging: does pseudopyloric metaplasia muddy the waters?



Authors

Emanuele Dilaghi¹, Gianluca Esposito¹, Giulia Pivetta¹, Gloria Galli¹, Emanuela Pillozzi², Bruno Annibale¹, Edith Lahner¹

Institutions

- 1 Department of Medical-Surgical Sciences and Translational Medicine, Sant'Andrea Hospital, Sapienza University of Rome, Rome, Italy
- 2 Department of Clinical and Molecular Medicine, Sant'Andrea Hospital, University Sapienza, Rome, Italy

submitted 12.7.2021

accepted after revision 14.12.2021

Bibliography

Endosc Int Open 2022; 10: E434–E440

DOI 10.1055/a-1776-7628

ISSN 2364-3722

© 2022. The Author(s).

This is an open access article published by Thieme under the terms of the Creative Commons Attribution-NonDerivative-NonCommercial License, permitting copying and reproduction so long as the original work is given appropriate credit. Contents may not be used for commercial purposes, or adapted, remixed, transformed or built upon. (<https://creativecommons.org/licenses/by-nc-nd/4.0/>)

Georg Thieme Verlag KG, Rüdigerstraße 14,
70469 Stuttgart, Germany

Corresponding author

Edith Lahner, MD, PhD, Associate Professor of Gastroenterology, Sapienza University of Rome, Medical-Surgical Department of Clinical Sciences and Translational Medicine, Via Grottarossa 1035, 00189 Rome, Italy
Fax: +390633775099
edith.lahner@uniroma1.it

ABSTRACT

Background and study aims In autoimmune atrophic gastritis (AAG), associated with intestinal (IM) and/or pseudopyloric metaplasia (PPM), endoscopic surveillance is recommended for gastric cancer risk mainly linked to IM. Endoscopic Grading of Gastric Intestinal Metaplasia (EGGIM) reliably identifies IM, but has not been assessed in AAG. We aimed to assess the performance of EGGIM (index test) versus histology (reference test) of corpus IM in AAG.

Patients and methods This was a cross-sectional study of 210 AAG patients undergoing surveillance gastroscopy with narrow-band imaging (NBI): corpus IM scored according to EGGIM, histology according to updated Sydney system, and morphological criteria.

Results NBI identified corpus IM in 88.6% of AAG patients: EGGIM were 0, 1, 2, 3, 4 in 11.4%, 0.5%, 33.3%, 1.9%, and 52.9%, respectively. Histology identified corpus IM in 78.1% and PPM in 79.5% of patients. PPM was present with IM in 57.6% and without IM in 21.9% patients, 20.5% had IM without PPM. EGGIM, compared to histology, correctly classified 76.2% of patients, showing high sensitivity (91.5%, 95%CI 86.1–95.3). EGGIM correctly classified 93% of patients with IM without PPM, 90.9% with both metaplasias, and 21.7% with PPM without IM yielding low specificity (21.7%, 95%CI 10.9–36.4).

Conclusions In AAG, EGGIM showed high accuracy and sensitivity identifying >90% of patients with histological corpus IM. EGGIM overestimated IM when PPM without IM was present, yielding low specificity. These findings raise the question of whether in AAG, PPM and IM may display similar endoscopic features on NBI.

Introduction

Autoimmune atrophic gastritis (AAG) is an immune-mediated condition, with loss of corpus oxyntic glands replaced by metaplastic tissue and a spared antral mucosa. Two types of gastric corpus metaplasia are present: pseudopyloric metaplasia (PPM) and intestinal metaplasia (IM) [1]. AAG is linked to an increased

risk of gastric cancer (GC) [2]. IM is positively related to the increased risk of GC [2, 3].

A link between PPM and GC has been hypothesized [3, 4] but is less clear.

Surveillance of AAG patients to early detect GC is recommended and high-resolution (HR) and/or electronic chromoendoscopy should be used to increase positive case findings [5, 6].

Narrow-band imaging (NBI) chromoendoscopy, an optical image-enhancement technology that permits enhanced visualization of microvascular architecture and micro-surface structure, reliably identifies IM with a pooled sensitivity and specificity of 0.79 and 0.91 and 0.84 and 0.95 in a per-patient analysis and a per-biopsy analysis, respectively [7], in patients undergoing gastroscopy for upper gastrointestinal symptoms or GC screening, thus opening the perspective to limit and even waive gastric biopsies in the absence of IM, saving time and money [8]. Endoscopic grading of gastric IM (EGGIM) has been validated to score endoscopic assessment of IM with the use of HR-NBI gastroscopes [9].

AAG patients undergo life-long surveillance gastroscopies with multiple biopsies at scheduled intervals between 3 and 5 years, depending on country-specific protocols, with a high burden for both endoscopy and pathology. Thus, reliably recognizing IM and correctly targeting biopsies in clinical practice may have clinical implications in this setting. To the best of our knowledge, in AAG, the real-life reliability of EGGIM has not been addressed before. We aimed to assess the diagnostic performance of EGGIM (index test) versus histological assessment (reference test) of corpus-IM in patients with a known diagnosis of AAG presenting for surveillance gastroscopy.

Patients and methods

Study population and design

A cross-sectional study of 210 consecutive AAG patients (women 67.7%, median-age 61 years [range, 20–88]) undergoing surveillance gastroscopy with HR-NBI-gastroscopes was conducted. The study period ranged from December 2015, when HR-NBI gastroscopes were first available in our center, to April, 2021. Inclusion criteria were age ≥ 18 years, histological AAG diagnosis defined by the presence of corpus atrophy and a spared antrum [1,2]; surveillance gastroscopy performed with HR-NBI gastroscopes with targeted or random biopsies of gastric mucosa according to the updated Sydney system [10]; endoscopic assessment of EGGIM score [9]; and histological assessment of gastric biopsies according to the updated Sydney system [10]. To confirm diagnosis of corpus atrophy, serum pepsinogen I levels assessed at diagnosis (ELISA Bio hit Oyi, Helsinki, Finland) were low (< 30 ng/mL) in all patients [2, 11]. The positivity toward parietal cell antibodies was not necessary for inclusion and presence of *Helicobacter pylori* infection was not a reason for exclusion [1,2]. Patients were excluded when they were not willing to participate, the surveillance gastroscopy was performed with other than HR-NBI gastroscopes, EGGIM score was not assessed, or biopsy sampling was inappropriate for histology.

The study was performed according to STARD [12]: endoscopic assessment of IM during HR-NBI gastroscopy expressed as EGGIM score was the index test and histological assessment of IM by updated Sydney system was the reference test to address the diagnostic performance of EGGIM in the setting of AAG. ► **Fig. 1** shows the STARD diagram reporting the flow of participants through the study and ► **Table 1** shows the main clinical characteristics of included patients with AAG. Informed

consent and approval from a local ethics committees were obtained (no.7022/2020).

HR-NBI gastroscopy and bioptic sampling

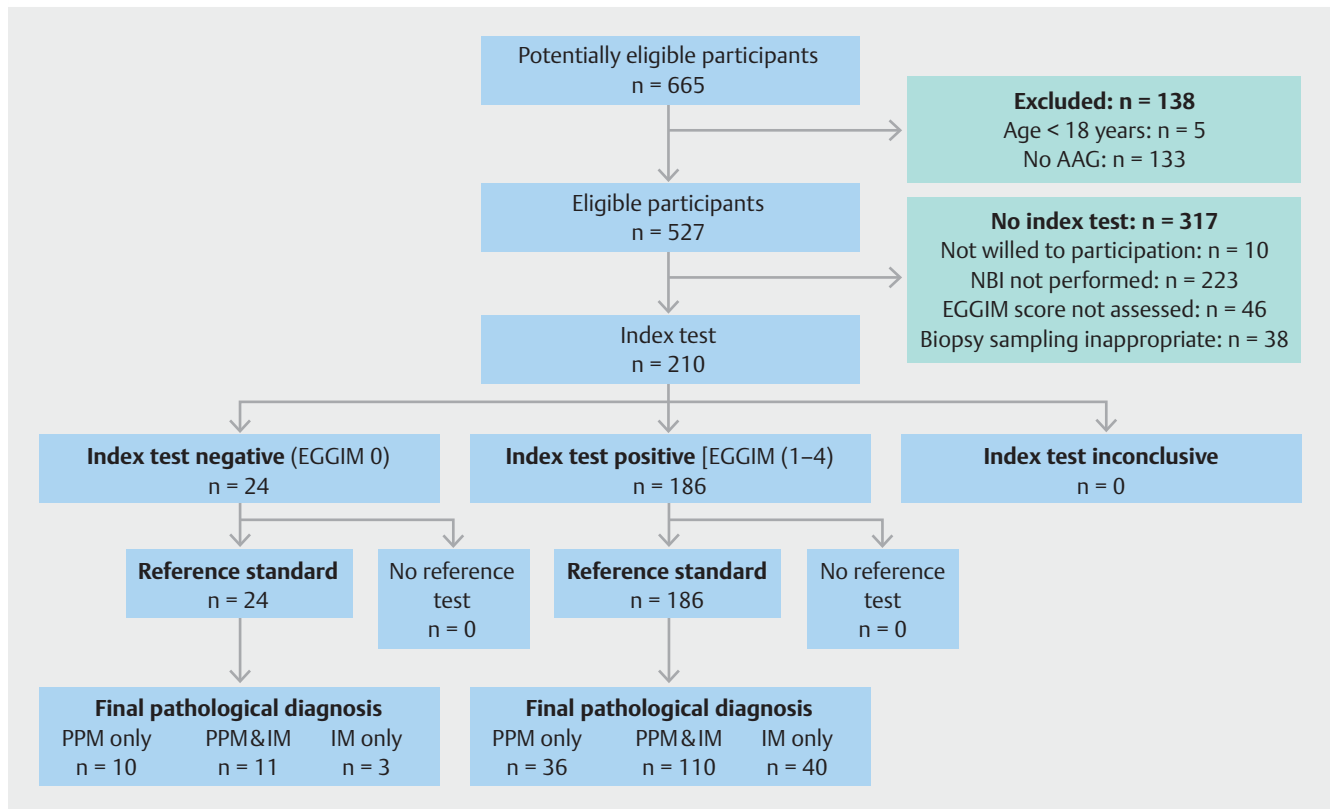
Gastroscopies were performed by an expert endoscopist (> 100 HR-NBIs/year) or trainees under the supervision of the expert endoscopist. The procedures were performed using Olympus scopes (GIF-H185/GIF-HQ190) with patients under conscious sedation (xylocaine spray, midazolam). Gastroscopy was first conducted with the use of white-light endoscopy (WLE) and then with HR-NBI [9]. For this study, two different areas were considered: lesser and greater curvature of the corpus (the antrum was not assessed because it is spared in AAG). In each area, 0 points were assigned if no IM was present, 1 if focal IM was present ($\leq 30\%$ of the area), 2 points if IM was present in $> 30\%$ of the area, for a total of 4 points. If IM was endoscopically suspected, biopsies were targeted to suspicious areas of IM; otherwise, random biopsies were taken [10]. At the end of the HR-NBI evaluation, the assigned EGGIM score was registered in the endoscopy report. The endoscopic assessment of presence of IM in the corpus mucosa by NBI was performed according to the classification of Pimentel [13, 14]: in detail, regular tubulovillous or ridge mucosal patterns and the presence of light blue crest, i.e. the presence or not of blue-whitish slightly raised areas, were taken into consideration. As minimum criteria to satisfy the endoscopic diagnosis of IM (EGGIM-positive) in each of the two different areas of the corpus mucosa, the presence of a regular tubulovillous or ridge mucosal pattern with or without the presence of light blue crest was required. Eventual discrepancies concerning the NBI assessment of IM and/or the assigned EGGIM score between the trainee endoscopist and the expert endoscopist were solved by discussion until agreement was reached.

Histological assessment

Gastric biopsies were independently evaluated by an expert gastrointestinal pathologist blinded to EGGIM. Histopathological evaluation was reported according to the updated Sydney system [10]. AAG was defined as mild, moderate, or severe gastric mucosal atrophy restricted to the corpus-fundus glands of the stomach, sparing the antrum, i.e. without atrophic or metaplastic changes in the antral mucosa [10, 15]. Corpus mucosa IM was defined as the substitution of the normal oxyntic glands with intestinalized glands [10]; PPM was defined as the replacement of the oxyntic glands by glands resembling the mucosecreting cell-lined glands normally present in the antrum [15].

Statistical analysis

Data were expressed as median (range) and/or number/total (percentage, %). The diagnostic performance of endoscopic assessment of IM by NBI expressed by EGGIM (index test) was evaluated in comparison to cumulative histological IM of gastric corpus biopsies assessed by the updated Sydney system (reference test) and expressed as sensitivity, specificity, positive and negative predictive values (PPV, NPV), diagnostic accuracy, and 95% confidence intervals (95%CI). Differences between subgroups were analyzed using the Chi-squared test/Fisher's exact



► **Fig. 1** STARD diagram to report flow of participants through the study. From: *Cohen JF, Korevaar DA, Altman DG et al. STARD 2015 guidelines for reporting diagnostic accuracy studies: explanation and elaboration. BMJ Open 2016; 6: e012799*

► **Table 1** Main clinical features of the 210 included patients with autoimmune atrophic gastritis.

	Number (%)
Female	142 (67.6)
Median age, years, median (range)	61 (20–88)
Active smoking	88 (41.9)
First-degree family history for gastric cancer	17 (8.0)
Body mass index > 25 kg/m ²	77 (36.7)
Dyspepsia	74 (35.2)
Positivity to parietal cell antibodies	136 (64.8)
Corpus <i>H pylori</i> positivity at histology	21 (10.0)
Iron-deficiency anemia	33 (15.7)
Pernicious anemia	77 (36.7)
Corpus atrophy severity score ¹	
▪ Mild	22 (10.5)
▪ Moderate	63 (30.0)
▪ Severe	125 (59.5)

¹ According to the updated Sydney system.

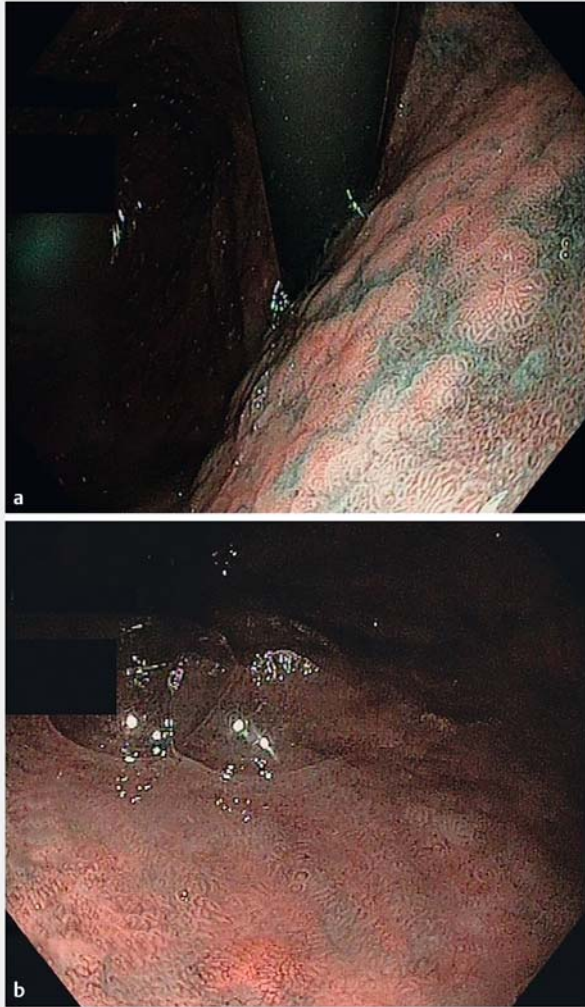
test. Two-tailed $P < 0.05$ was considered statistically significant. To calculate the sample size, taking into consideration the NBI accuracy values for IM not inferior to 85% [7, 8, 13] and hypothesizing that in the AAG setting accuracy of about 75% could have been reached, 207 patients would have been required at a type I error (alpha, significance) and a type II error (beta, 1-power) of 0.05. Statistical analyses were performed by MedCalc Statistical Software version 19.6.4 (MedCalc Software Ltd, Ostend, Belgium; <https://www.medcalc.org>; 2021).

Results

Endoscopic-histological distribution of gastric corpus metaplasia

NBI identified corpus IM in 186 AAG patients (88.6%), and EGGIM scores were 0, 1, 2, 3, and 4 in 24 (11.4%), 1 (0.5%), 70 (33.3%), 4 (1.9%), and 111 (52.9%), respectively. ► **Fig. 2** shows an endoscopic image of the fundus (**a**) and another one of the corpus mucosa (**b**) providing a representative NBI finding of IM.

Histological assessment ascertained corpus IM in 164 patients (78.1%) and 77 (36.7%), 78 (37.1%), and nine patients (4.3%) were classified as having mild, moderate, or severe corpus-IM. PPM was histologically ascertained in 167 patients (79.5%), which was concomitantly present with corpus IM in 121 (57.6%), while 46 (21.9%) had PPM without the concomitant presence of corpus IM; corpus IM without PPM was identified in 43 (20.5%).



► **Fig. 2** Endoscopic images of the **a** fundus and **b** corpus mucosa providing representative NBI findings of IM

Diagnostic accuracy of EGGIM

Compared to histology, EGGIM showed an overall diagnostic accuracy in 160 patients (76.2%), yielding a sensitivity of 91.5% (95%CI 86.1%–95.3%) and a PPV of 80.6% (95%CI 78.0%–83.0%) (► **Table 2**). Concerning histological severity, EGGIM correctly identified (true positives) all nine patients (100%) with severe, 71 (91.0%) with moderate, and 70 (90.9%) with mild corpus IM. The proportion of true positives of patients with EGGIM scores 3 to 4 was higher than that of those with EGGIM scores 1 to 2 (EGGIM scores 3–4: 99/115 (86.1%) versus EGGIM scores 1 to 2 51/71 (71.8%), $P=0.02$). ► **Table 3** shows EGGIM scores with respect to the type of histologically diagnosed type of corpus gastric metaplasia. Considering the gastric metaplasia type (► **Fig. 2**), EGGIM was positive in 40 patients (93.0%) with corpus IM in the absence of PPM, and in 110 (90.9%) with both IM and PPM (true positives). Of the 46 patients histologically identified as having PPM without concomitant corpus IM, 10 (21.7%) were correctly classified as EGGIM 0 (true negatives), yielding a specificity of 21.7% (95%CI 10.9%–

► **Table 2** Diagnostic accuracy of endoscopic assessment of gastric intestinal metaplasia in the corpus mucosa by narrow-band imaging chromoendoscopy expressed as EGGIM scores (index test) compared to histological assessment of intestinal metaplasia by updated Sydney system (reference test) in 210 patients with autoimmune atrophic gastritis.

	% (95% confidence interval)
Sensitivity	91.5 (86.1 to 95.2)
Specificity	21.7 (10.9 to 36.4)
Positive predictive value	80.6 (78.0 to 83.0)
Negative predictive value	41.7 (25.4 to 60.0)
Accuracy	76.2 (69.8 to 81.8)

EGGIM, endoscopic grading of gastric intestinal metaplasia.

36.4%). EGGIM was falsely positive in the remaining 36 patients (78.3% with PPM without corpus IM, overestimating 20 (43.5%) as EGGIM 2 and 16 (34.8%) as EGGIM 4.

EGGIM showed diagnostic “inaccuracy” overall in 50 patients (23.8%), underestimating the presence of corpus IM in 14 (false negatives) and overestimating it in 36 (false positives). In 47 of 50 (94%) of the endoscopically incorrectly assessed patients, histology ascertained the presence of PPM: in 11 of the underestimated EGGIM scores at histology, both IM and PPM were identified, and in all 36 of the overestimated EGGIM scores at histology, PPM without IM was identified (► **Fig. 3**).

Discussion

This is the first real-life study using the EGGIM score and assessing its diagnostic performance in clinical practice for corpus IM recognition compared to histology in AAG patients. All 210 patients were on endoscopic histological surveillance for GC prevention [5, 6]. Our results showed a good diagnostic performance, since EGGIM achieved an overall sensitivity of 91.5% and a PPV of 80.6%, properly classifying 76.2% of patients. NBI is highly accurate for the diagnosis of precancerous conditions [7, 8, 13]. The easily reproducible EGGIM classification was validated with accuracy rates >85% to 90% for IM diagnosis in patients undergoing gastroscopy due to upper gastrointestinal symptoms and surveillance [14]. In patients with iron deficiency anemia and dyspepsia, NBI was reported to be superior to WLE in identifying IM [16], showing NBI as a reliable resource for IM diagnosis. The findings of the current study show that in AAG patients, EGGIM may represent a useful approach for endoscopic assessment of IM, and thus, individual GC risk stratification.

In our study, EGGIM showed a similar ability to identify patients with severe, moderate, or mild scores for corpus IM as assessed by histology ($P>0.05$). In a multicenter prospective study, EGGIM showed a 94% global diagnostic accuracy, and the benefit of NBI in IM recognition was higher in more advanced IM stages [13] with an area under the curve-receiver operating characteristics of 0.983 for extensive IM (OLGIM III/IV) [13]. Similar data were confirmed in a recent study [17]. We

► **Table 3** Endoscopic grading of gastric intestinal metaplasia (EGGIM) scores with respect to type of histologically diagnosed type of corpus gastric metaplasia.

	PPM only n = 46 (21.9)	PPM & IM n = 121 (57.6)	IM only n = 43 (20.5)
EGGIM 0	10 (21.7)	11 (9.1)	3 (7.0)
EGGIM 1	0	1 (0.8)	0
EGGIM 2	20 (43.5)	34 (28.1)	16 (37.2)
EGGIM 3	0	3 (2.5)	1 (2.3)
EGGIM 4	16 (34.8)	72 (59.5)	23 (53.5)

Data expressed as numbers (%).

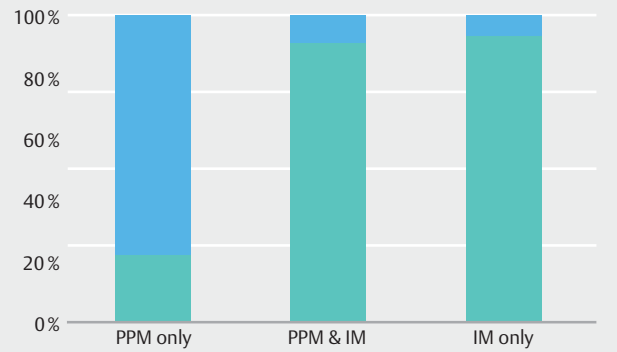
PPM, pseudopyloric metaplasia; IM, intestinal metaplasia.

did not consider OLGIM-classification because in AAG, by definition, IM is restricted to the gastric corpus and the highest possible score is OLGIM II, making this risk stratification inappropriate in AAG [1, 2]. Our study showed that EGGIM scores 3 to 4 were more frequently correctly assigned than EGGIM scores 1 to 2, showing that a diffuse pattern of corpusIM is probably more promptly recognizable by HR-NBI than a focal-patchy pattern.

Our results further showed that in 94% of AAG patients in whom EGGIM endoscopically misclassified IM, the histological presence of PPM was detected. In 78.3% of the patients in whom EGGIM endoscopically overestimated the supposed presence of IM, PPM without IM was present at histology. In contrast, EGGIM showed a high diagnostic performance when IM was histologically present, alone (93%) or with PPM (90.9%). These results raise the question of whether in AAG at HR-NBI PPM may display similar endoscopic features as IM, thus leading to overestimation of IM.

GC develops through a sequence of histological changes, first chronic inflammation, progressively leading to atrophy, IM, dysplasia, and subsequent intestinal-type adenocarcinoma [18]. Surveillance of precancerous stages may lead to early diagnosis of GC, improving survival [5, 6]. IM is considered the “point of no return” of the steps eventually leading to gastric carcinogenesis and its presence is linked to a higher GC risk [3]. Therefore, recognizing IM may be considered as a cornerstone in endoscopic surveillance, and surveillance programs including EGGIM staging are expected to be a practical approach to helping to achieve better risk stratification [8].

Gastric metaplastic transformation could be seen as a stepwise evolution, beginning with PPM, probably arising from trans-differentiated chief cells in chronic inflammation, leading to atrophy, and over time, possibly to IM [3, 15]. PPM and IM may represent sequential steps in the progression to GC [19]. In human gastric biopsies, the direct transformation from columnar metaplasia without goblet cells to cancer skipping the step of IM has never been observed. Prospective data on corpus PPM and its link to the GC development are scanty. A recent report showed that AAG patients with PPM seem to have a very low risk of developing neoplastic lesions [20]. Thus, to reliably



► **Fig. 3** Diagnostic accuracy of Endoscopic grading of gastric intestinal metaplasia (EGGIM) assessed during narrow-band imaging with respect to the type of gastric metaplasia. In patients with both types of gastric metaplasia or with intestinal metaplasia only, the endoscopic classification was correct in more than 90% (true positives), but in patients with pseudopyloric metaplasia only without intestinal metaplasia, EGGIM overestimated the presence of intestinal metaplasia in 78% of patients (false positives). PPM only, presence of pseudopyloric metaplasia without intestinal metaplasia; PPM and IM, presence of both, pseudopyloric and intestinal metaplasia; IM only, presence of intestinal metaplasia without pseudopyloric metaplasia. Green: Endoscopic assessment of IM accurate; blue: Endoscopic assessment of IM inaccurate.

recognize IM and to differentiate it from PPM by endoscopy may have important clinical implications for endoscopically stratifying the GC risk of an individual patient in real time, therefore, studies addressing the differential endoscopic features of PPM and IM are welcome.

The histological presence of foveolar hyperplasia has been reported as a possible confounder eventually leading to endoscopic overestimation of IM during HR-NBI [9, 13]. In our study, among AAG patients in whom EGGIM overestimated IM, in only four patients foveolar hyperplasia was observed, which was in three in the endoscopically normal antral mucosa and in the remaining patient in a 3-mm polyp in the corpus, thus reasonably excluding the role of foveolar hyperplasia in endoscopically overestimating IM.

In our study population, 21 patients were *H pylori*-positive at histology. A previous study [9] showed that *H pylori* infection did not influence the diagnostic performance of EGGIM. In the current study, of the 21 *H pylori*-positive patients, 15 were EGGIM-positive and six EGGIM-negative. Among EGGIM-negatives, there were two false-negatives since at histology IM was present alone in one patient and together with PPM in the other patient. Among EGGIM-positives, there were seven false-positives, since at histology the presence of IM was not confirmed in these seven patients. The rate of *H pylori*-positives in this study was too low for a comparative statistical analysis. However, when the 21 *H pylori*-positive patients were excluded, diagnostic performance of EGGIM did not substantially change (sensitivity 92%, 95%CI 87–96; specificity 17%, 95%CI 7–37; PPV 83%, 95%CI 81–85, NPV 33% 95%CI 17–55, accuracy 78%, 95% 72–84), when compared to the entire study population in-

cluding *H pylori*-positives, thus showing that *H pylori* positivity does not play a substantial role in endoscopic overestimation or underestimation of corpus IM and supporting the findings of the previous study.

A strength of our study was that endoscopic procedures were performed/supervised by an expert endoscopist with significant NBI experience. Our center has significant high experience in management of AAG patients and significant expertise with NBI. This may be a limit of the study, since it was single-center and our findings may not be generalizable to other endoscopy units, although NBI was previously proved to be easy to learn [21]. Another limit could be that endoscopists were not blinded to AAG diagnoses and this may have represented a bias for EGGIM scoring, eventually contributing to overestimation or underestimation. Immunohistochemistry was not performed to determine the histopathological profile of PPM, but good intraobserver agreement between morphology and immunohistochemistry for detection of PPM has been reported [12]. The single NBI mucosal patterns for endoscopic assessment of IM were not recorded, but endoscopic diagnosis of IM was directly expressed as EGGIM score. For this reason, subanalyses of the NBI pattern with respect to the type of gastric metaplasia could not be performed.

Conclusions

In conclusion, in AAG, EGGIM had good accuracy and high sensitivity, reliably identifying more than 90% of patients with histological corpus IM, thus representing a useful approach for individual GC risk stratification in AAG patients. EGGIM overestimated the presence of IM when PPM was present, thus yielding low specificity. These findings raise the question of whether in AAG, PPM and IM may display similar endoscopic features on NBI. Identifying possible distinctive NBI features between PPM and IM may be clinically important because the neoplastic risk seems to be more pronounced for the latter condition.

Acknowledgments

Funded in part by Sapienza University Rome, Funds “Ateneo 2019–2020”.

Competing interests

The authors declare that they have no conflict of interest.

Funding

Sapienza Università di Roma Ateneo 2019–2020

References

- [1] Lenti MV, Rugge M, Lahner E et al. Autoimmune gastritis. *Nat Rev Dis Primers* 2020; 6: 56
- [2] Lahner E, Zagari RM, Zullo A et al. Chronic atrophic gastritis: Natural history, diagnosis and therapeutic management. A position paper by the Italian Society of Hospital Gastroenterologists and Digestive Endoscopists [ALGO], the Italian Society of Digestive Endoscopy [SIED], the Italian Society of Gastroenterology [SIGE], and the Italian Society of Internal Medicine [SIMI]. *Dig Liver Dis* 2019; 51: 1621–1632
- [3] Giroux V, Rustgi AK. Metaplasia: tissue injury adaptation and a precursor to the dysplasia-cancer sequence. *Nat Rev Cancer* 2017; 17: 594–604
- [4] Goldenring JR. Pyloric metaplasia, pseudopyloric metaplasia, ulcer-associated cell lineage and spasmolytic polypeptide-expressing metaplasia: reparative lineages in the gastrointestinal mucosa. *J Pathol* 2018; 245: 132–137
- [5] Pimentel-Nunes P, Libânio D, Marcos-Pinto R et al. Management of epithelial precancerous conditions and lesions in the stomach (MAPS II): European Society of Gastrointestinal Endoscopy, European Helicobacter and Microbiota Study Group, European Society of Pathology, and Sociedade Portuguesa de Endoscopia Digestiva guideline update 2019. *Endoscopy* 2019; 51: 365–388
- [6] Banks M, Graham D, Jansen M et al. British Society of Gastroenterology guidelines on the diagnosis and management of patients at risk of gastric adenocarcinoma. *Gut* 2019; 68: 1545–1575
- [7] Rodríguez-Carrasco M, Esposito G, Libânio D et al. Image-enhanced endoscopy for gastric preneoplastic conditions and neoplastic lesions: a systematic review and meta-analysis. *Endoscopy* 2020; 52: 1048–1065
- [8] Marcos P, Brito-Gonçalves G, Libânio D et al. Endoscopic grading of gastric intestinal metaplasia on risk assessment for early gastric neoplasia: can we replace histology assessment also in the West? *Gut* 2020; 69: 1762–1768
- [9] Esposito G, Pimentel-Nunes P, Angeletti S et al. Endoscopic grading of gastric intestinal metaplasia (EGGIM): a multicenter validation study. *Endoscopy* 2019; 51: 515–521
- [10] Dixon MF, Genta RM, Yardley JH et al. Classification and grading of gastritis. The updated Sydney System. International Workshop on the Histopathology of Gastritis, Houston 1994. *Am J Surg Pathol* 1996; 20: 1161–1181
- [11] Lahner E, Marzotto I, Lampasona V et al. Autoantibodies toward ATP4A and ATP4B subunits of gastric proton pump H⁺,K⁺-ATPase are reliable serological pre-endoscopic markers of corpus atrophic gastritis. *Clin Transl Gastroenterol* 2020; 11: e00240
- [12] Cohen JF, Korevaar DA, Altman DG et al. STARD 2015 guidelines for reporting diagnostic accuracy studies: explanation and elaboration. *BMJ Open* 2016; 6: e012799
- [13] Pimentel-Nunes P, Libânio D, Lage J et al. A multicenter prospective study of the real-time use of narrow-band imaging in the diagnosis of premalignant gastric conditions and lesions. *Endoscopy* 2016; 48: 723–730
- [14] Pimentel-Nunes P, Dinis-Ribeiro M, Soares JB et al. A multicenter validation of an endoscopic classification with narrow band imaging for gastric precancerous and cancerous lesions. *Endoscopy* 2012; 44: 236–246
- [15] Rugge M, Sacchi D, Genta RM et al. Histological assessment of gastric pseudopyloric metaplasia: Intra- and inter-observer consistency. *Dig Liver Dis* 2021; 53: 61–65
- [16] Buxbaum JL, Hormozdi D, Dinis-Ribeiro M et al. Narrow-band imaging versus white light versus mapping biopsy for gastric intestinal metaplasia: a prospective blinded trial. *Gastrointest Endosc* 2017; 86: 857–865
- [17] Zhang G, Zheng J, Zheng L et al. Gastric intestinal metaplasia assessment between linked color imaging based on endoscopy and pathology. *Scand J Gastroenterol* 2021; 56: 103–110

- [18] Correa P. Human gastric carcinogenesis: a multistep and multifactorial process—First American Cancer Society Award Lecture on Cancer Epidemiology and Prevention. *Cancer Res* 1992; 52: 6735–6740
- [19] Weis VG, Goldenring JR. Current understanding of SPEM and its standing in the preneoplastic process. *Gastric Cancer* 2009; 12: 189–197
- [20] Dilaghi E, Baldaro F, Pillozzi E et al. Pseudopyloric metaplasia is not associated with development of gastric cancer. *Am J Gastroenterol* 2021; 116: 1859–1867
- [21] Dias-Silva D, Pimentel-Nunes P, Magalhães J et al. The learning curve for narrow-band imaging in the diagnosis of precancerous gastric lesions by using Web-based video. *Gastrointest Endosc* 2014; 79: 910–920