

# Diffusion magnetic resonance in cervical carcinoma: the role of apparent diffusion coefficient in the evaluation of treatment response

G.M. Barelli<sup>1</sup>, F. Carbonetti<sup>1</sup>, V. De Sanctis<sup>2</sup>, I. Martini<sup>1</sup>, P. Bonome<sup>2</sup>, C. Briani<sup>1</sup>, E. Iannicelli<sup>1</sup>

<sup>1</sup>Radiology Unit, <sup>2</sup>Radiotherapy Unit, Sapienza University of Rome, Sant'Andrea Hospital; Rome (Italy)

## Summary

**Purpose:** The aim of the study was to determinate the role of apparent diffusion coefficient (ADC) in order to find cut-off values in the evaluation of treatment response. **Materials and Methods:** A retrospective study was undertaken on MRIs of three groups of patients: 17 with histologically proven cervical carcinoma (group 1), 16 with complete regression after chemo-radiotherapy (group 2), and 46 without pathology (group 3). Three non-overlapping ROIs were manually drawn through neoplastic tissue and normal cervical areas, regions of interest (ROIs) median values were calculated. Student *t*-test, ANOVA test, receiver operating characteristic (ROC) curves, and Youden Index were performed. **Results:** The most important data was obtained by ROC curve and Youden index calculated between free from disease merged group (groups 2+3) and ill patients (group 1):  $1.18 \times 10^{-3} \text{mm}^2/\text{s}$  (94% sensibility, 100% specificity), was the cut-off ADC value. Values below this cut-off could be considered as recurrent pathology with high accuracy. **Conclusions:** ADC represents a fundamental quantitative tool in follow-up of chemo-radiant treatment response in advanced cervical carcinoma.

**Key words:** ADC mapping; Chemoradiation; Diffusion weighted magnetic resonance; Quantitative study; Residual cervical carcinoma.

## Introduction

Cervical cancer is the second most common neoplasm in women aged 30-40 years worldwide. Epidemiological data show a progressive increase in incidence in developing countries such as Africa, South America, and South East Asia [1, 2].

Staging and management of cervical carcinoma are mainly based on clinical and surgical examination i.e. International Federation of Gynecology and Obstetrics (FIGO) 2009 guidelines [3] and Tumor Node Metastasis (TNM) classification of the American Joint Committee on Cancer (AJCC)[4]. Guidelines for staging with MRI were also provided in 2011 by the European Society of Urogenital Radiology (ESUR)[5].

As FIGO guidelines define, early stages of cervical carcinoma (IA-IIA1) are treated with hysterectomy, while a combination of chemotherapy and radiotherapy, both external and intracavitary are performed in advanced stages (IIB-IV)[6, 7]. Thus, it is fundamental to achieve a correct staging in order to determinate the right treatment and to preserve fertility and female identity, as it is possible.

The role of MRI in staging is nowadays widely accepted, due to the high accuracy and feasibility of the MRI in defining tumor size and parametrial and pelvic side wall invasion [8-10].

The emerging role of MRI concerns the evaluation of clinical response to the chemo-radiant treatment in the advanced stages in order to define the complete regression of neoplasm [11]. In radio-chemotreated patients follow-up the main goal is to differentiate the radio-induced fibrotic tissue from the persistence of pathological one. Morphological high resolution T2-weighted sequences, which represent the core of MRI pelvis protocol seem to be not enough for this discernment.

Some studies demonstrate the role of MRI diffusion weighted imaging-apparent diffusion coefficient (DWI-ADC) sequences to assess the treatment response and this issue is open to new researches being DWI-ADC a fairly new tool [12-14]. The aim of the present study was to better assess the role of DWI-ADC to discern pathological tissue from healed one. Finding possible ADC cut-off values could be helpful to distinguish pathological tissues from fibrotic and normal ones, by considering both fibrotic and normal tissue such as clinical regression of pathology. By using ADC values, the radiologist could have a quantitative and precise tool to refer when discerning absence of pathology from neoplastic tissue, reducing the risk of misunderstandings due to qualitative evaluation of T2-weighted images.

Revised manuscript accepted for publication March 13, 2018

## Materials and Methods

This study retrospectively reviewed 73 MRIs of 57 patients admitted to this Hospital from January 2014 to December 2016. Age distribution was from 20 to 74 years and mean age was  $57.6 \pm 14.02$  years. In collaboration with the Departments of Radiotherapy and Pathology of this hospital the authors selected 17 patients with histologically confirmed diagnosis of advanced squamous cervical carcinoma who had performed a successful chemo-radio treatment and were disease-free at one-year follow-up. A control group of 40 patients was then formed. All included patients had standard MRI exam of pelvic region with DWI-ADC sequences for review purposes.

MRI analysed images were divided into three groups: group one (Figure 1): MRI examinations of 17 patients affected by squamous cervical carcinoma (from 40- to 70-years-old with a mean age of  $59 \pm 10.2$  years), tumour Stage IIB-IV based on the FIGO 2009 guidelines as it follows: IIB seven patients, IIIA five patients, IIIB two patients, and IVA three patients. Group two (Figure 2): MRI examinations of same patients of group one, healed

after a successful radio-chemotherapy treatment. One patient (staged as IIIB) of group one died due to a heart-attack so the number of patients reduced to 16. All patients were tumour-free within a year follow-up controls. Standard references for absence of disease were clinical exam, cytological sample and standard MRI pelvic protocol with DWI-ADC sequences performed every four months according to European Society of Urogenital Radiology (ESUR) 2011 guidelines [5]. Group three (Figure 3): control group. 40 patients aged from 26 to 63 years with a mean age of  $56 \pm 15.5$  years had MRI examinations due to abdominal-pelvic discomfort with no evidence of pathological MRI findings. All patients did not have previous oncological pelvic disease and did not undergo previous surgery or radio-chemotherapy treatment of pelvic region. MRI studies were performed with a 1.5T MR scanner with a four-channel phased-array body coil for signal reception.

Patients were recommended to fast for four to six hours; to reduce motion artefacts from bowel peristalsis, 20 mg intravenously of an antiperistaltic agent such as hyoscine butylbromide (20 mg

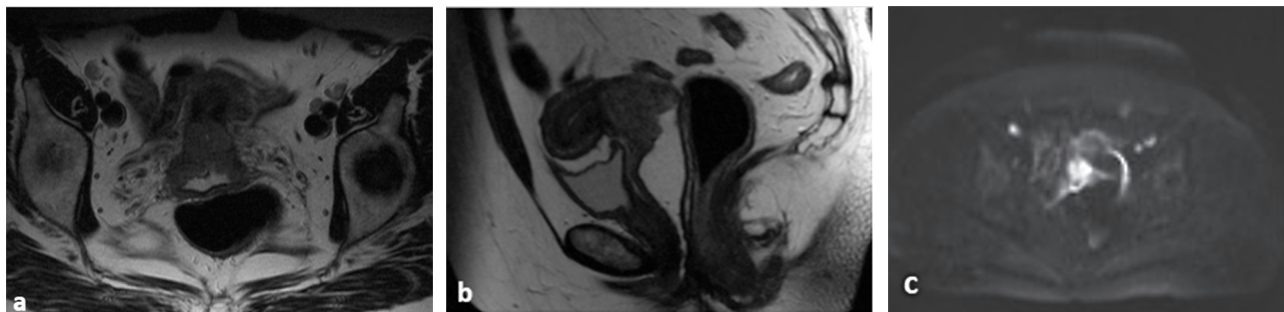


Figure 1. — MRIs of a 36-years-old patient with histologically proven cervical carcinoma Stage IIIB. MR T2-weighted images, sagittal view (a). MRI T2-weighted images, axial view (b). MR-DW images and ADC maps reconstructions (c-d).

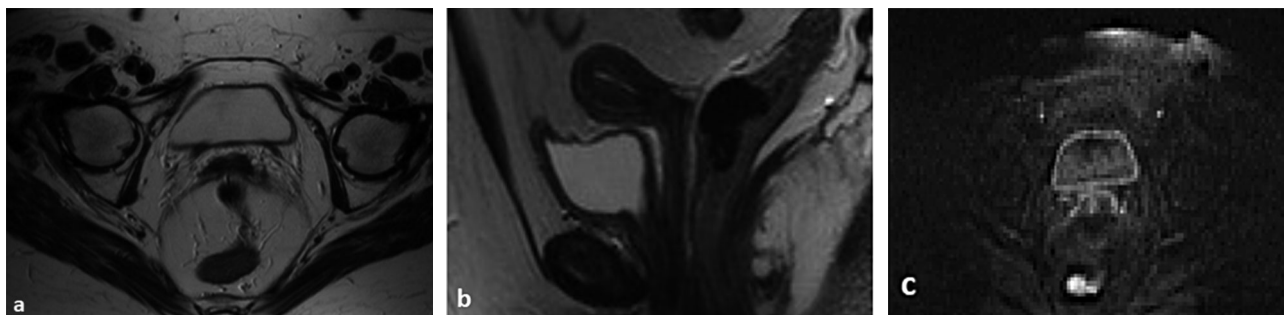


Figure 2. — Same patient in Figure 1 with complete regression of pathology after chemo-radiant treatment. MRI T2-weighted images, sagittal view (a). MRI T2-weighted images, axial view (b). MRI DW images and ADC map reconstructions (c-d).

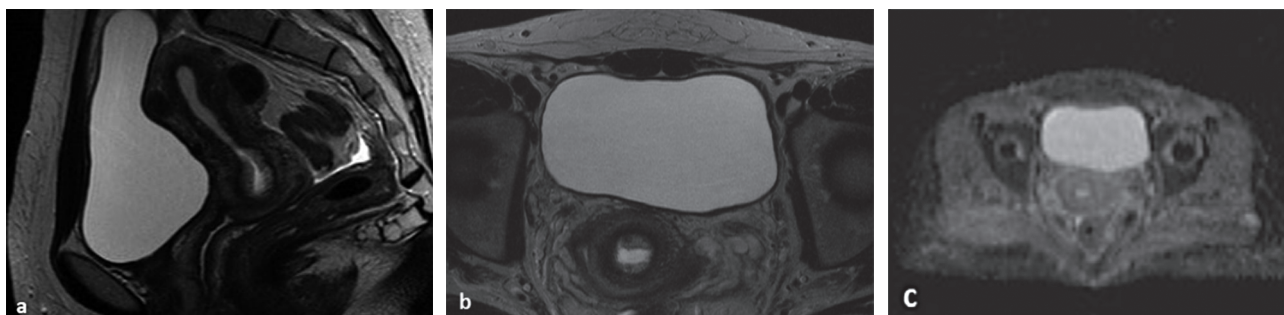


Figure 3. — MRIs of a 54-year-old woman from group 3. MRI T2-weighted images, sagittal view (a). MR T2-weighted images, axial view (b). MRI DW images and ADC map reconstructions (c-d).

Table 1. — Descriptive statistic analysis.

Group	Number	Age	ADC±SD*	ADCmax	ADCmin	Median
1	17	59	0.84±0.16	1.26	0.53	0.82
2	16	58	1.44±0.16	1.76	1.23	1.40
3	40	56	1.57±0.12	1.81	1.32	1.59

\*Every ADC value is expressed in  $10^3\text{mm}^2/\text{s}$ .

intravenously) were used.

Sequences used for pelvic MRI were as follows: fast slow angle shot (FLASH 2D) axial T1-weighted images (acquisition time 30 seconds, TR/TE 319 ms/3.82 ms; slice thickness 5 mm, field of view (FOV) 380, slice gap 1, flip angle 70 degrees); axial T2-weighted turbo spin-echo (TSE) images (acquisition time 30 s, TR/TE, 4000 ms/103 ms, slice thickness 5 mm, FOV 370, slice gap 1, flip angle 180 degrees); T2 high resolution (HR) images were acquired in the three planes: sagittal, axial, and coronal (acquisition time 5 minutes, TR/TE 5000/104, slice thickness 3 mm, FOV 280, slice gap 1, flip angle 180 degrees).

Axial DWI was acquired using three increasing b-values, (50 to 400 to 800  $\text{s}/\text{mm}^2$ ) with echo planar imaging (EPI) sequence with respiratory triggering. ADC maps were derived automatically on a voxel-by-voxel basis by using commercially available software. DWI parameters were as follows: acquisition time 4 minutes, TR/TE/ 3200/68, slice thickness 5 mm, FOV 400, flip angle 90 degrees. Then transverse SE T1-weighted images (acquisition time 30 seconds, TR/TE 319 ms/3.82 ms was obtained; slice thickness 5 mm, field of view (FOV) 380, slice gap 1, flip angle 70 degrees) after intravenous bolus injection of a gadolinium chelate i.e. gadopentetate demeglumine 0.05 mmol performing in all the patients a three phases contrast enhanced study, arterial-late-equilibrium, being the administration of contrast medium recommend in cervix cancer staging [5]. All images were analysed by two MRI radiologists experienced in pelvic MRIs.

ADC maps were generated on scanner console using  $b=50$ ,  $b=400$ , and  $b=800$ . ADC values were measured. For each exam three circular non-overlapping regions of interest (ROIs), with the same squared area i.e.  $9.8\text{mm}^2$  and a standard deviation of zero, were manually drawn in the selected area and the average was accepted.

For the first group, the lesion was identified as a hyperintensity signal in the T2 data set. T2 axial image where the tumour showed its maximum diameter was selected and automatically crossed with the EPI- DWI sequence and then matched with the ADC map where the three ROIs were manually drawn. For the second group, involved cervical site was chosen in the T2 data set, usually seen as an area with hypo- or isosignal intensity after chemoradiation, by comparison with previous pre-treatment MRI examination. T2 image where treated zone showed its maximum diameter was chosen, then crossed with the DWI and matched with the ADC map were three ROIs were manually drawn. For the third group, MRI could not detect signal alteration in the cervical zone and ROIs were manually drawn in a normal cervical tissue area that normally have a low signal on T2- WI.

Concurrent chemoradioterapy is the standard of care for patients with advanced cervical cancer. Definitive therapy consists of a combination of external beam radiotherapy and brachytherapy; addition of brachytherapy represents an integral part of radiation therapy for cervical cancer shown to improve overall survival.

All patients received extended field 3D-RT or IMRT (6 MV or 15 MV photons, 1.8 Gy per fraction, one fraction per day, five fractions per week) from pelvis to para-aortic area, depending on their work-up, with concurrent weekly cisplatin ( $40\text{mg}/\text{m}^2$ ) for five or six cycles.

Table 2. — P-value performed with Student t-test analysis.

Comparison	p-value
Group 1 to 3	0.82
Group 1 to 2	1.40
Group 2 to 3	1.59

All patients underwent reimaging using MRI before BT. HDR was given at the completion of EBRT: brachytherapy was administered using  $^{192}\text{Iridium}$  with an initial nominal specific activity of 10 Ci and a MicroSelectron HDR after-loading system. The BT boost was accomplished with one insertion using Fletcher applicator delivering 15 to 21 Gy (5 or 7 Gy per fraction) to a high-risk clinical target volume. The radiation dose was prescribed at the target surface and incident point A doses, ICRU 38 bladder and rectal point doses were recorded in 2 gy EQDs (by adding EBRT doses and EQD2 brachiterapy doses).

All data were analysed by SPSS statistics system (version 20.0.0.0). Mean ADC values were considered as continuous variables and the comparisons between groups 1 and 2, groups 2 and 3, and groups 1 and 3 were evaluated with Student *t*-test and ANOVA test. A *p*-value  $< 0.05$  was considered statistically significant.

Receiver operating characteristic (ROC) analysis was made to evaluate diagnostic performance of ADC value such as a quantitative measurement to differentiate the three groups. Three ROC curves were performed. First ROC curve compared groups 1 and 2, second ROC curve compared groups 2 and 3, and third ROC curve compared group 1 with a merged group obtained by adding patients of the groups 2 and 3, (radiotreated tissues and normal ones) in order to have a group of 56 patients free from disease and thus a larger diagnostic sample. Thanks to ROC analysis, cut-off values were obtained with the highest accuracy by the Youden Index ( $\text{sens}+\text{spec}-1$ ). Descriptive statistic was performed. Mean ADC values, standard deviation, median values, and minimum and maximum ADC values for every group are presented in (Table 1).

Pathological tissue had a mean ADC value of  $0.84 \pm 0.16 \times 10^{-3}\text{mm}^2/\text{s}$ , treated healed tissue had a mean ADC value of  $1.44 \pm 0.16 \times 10^{-3}\text{mm}^2/\text{s}$ , while normal cervical tissue had a mean ADC value of  $1.57 \times 10^{-3}\text{mm}^2/\text{s}$ .

Statistically significant differences were confirmed by Student *t*-test analysis. In every comparison we obtained a *p*-value  $< 0.05$ . ANOVA Test was performed to enforce the significance of the comparison adding a simultaneous and direct comparison between the groups. The test shows a statistical significance with a *p*-value  $< 0.0001$  (Table 2). Using ROC curves, cut-off values to discriminate the groups with the highest accuracy were obtained, thanks to the Youden Index.

The first ROC curve compared normal cervical tissue with pathological one (Figure 4). The test showed a high significance. The Youden Index assess a cut off value of  $1.28 \times 10^{-3}\text{mm}^2$  corresponds to a sensitivity and specificity of 100%

The second ROC curve compared ADC values of the radiotreated tissues with normal ones (Figure 5). In this case the AUC was 0.739; this value approximates 1 but to this data corresponds a cut-off value of  $1.51 \times 10^{-3}\text{mm}^2$  with 73% sensibility and 75% specificity. In this comparison some overlapping and similar values were shown. This data helped this study to consider both fibrotic and normal tissue as a clinical regression of pathology.

The third ROC curve merged groups 2 and 3 (radiotreated tissues and normal ones) in order to obtain a group of 56 patients clinically free from disease, and compared it with group 1 towards ROC analysis (Figure 6). This curve (Figure 6) was significant

Table 3. — A comparison of ADC cut-off values in the literature.

Study	Year	Normal ADC	Carcinoma ADC	Control ADC group	Cut off healthy/tumor	Cut off healthy/treated	Cut off tumor/merged group
Naganawa <i>et al.</i> [12]	2004	1.79 ± 0.24*	1.09 ± 0.2	1.48 ± 0.2			
Kuang <i>et al.</i> [13]	2012	1.48 ± 0.19	0.86 ± 0.14		1.24 95.7% sens. 100% spec.		
Kilickesmez <i>et al.</i> [14]	2010	1.71 ± 0.17	0.91 ± 0.14		1.05 95.8% sens. 94.5% spec.		
Charles Edwards <i>et al.</i> [21]	2008	1.331 ± 0.15	0.757 ± 0.1				
Xue <i>et al.</i> [24]	2008	1.73 ± 0.31	1.08 ± 0.12		1.25 100% sens. 95.8% spec.		
McVeigh <i>et al.</i> [23]	2008	2.09 ± 0.46	1.09 ± 0.2				
Chen <i>et al.</i> [24]	2008	1.59 ± 0.15	1.11 ± 0.17	1.436 ± 0.1	1.36 100% sens. 84.8% spec.	1.525 70% sens. 81.8% spec.	
Ho <i>et al.</i> [25]	2009	0.89 ± 0.14					
Harry <i>et al.</i> [26]	2008	1.25 ± 0.18					
Hoogendam <i>et al.</i> [27]	2010	1.53 ± 0.25	100.8 ± 0.2		1.33 95.1% sens. 94.7% spec.		
Present work	2016	1.57 ± 0.11	0.84 ± 0.16	1.44 ± 0.15	1.28 100% sens. 100% spec.	1.51 81% sens. 50% spec.	1.18 73% sens. 100% spec.

with an AUC of 0.999, and a cut off value of  $1.18 \times 10^{-3} \text{mm}^2/\text{s}$  to which correspond a sensibility of 73% and a specificity of 100%.

## Discussion

Several studies demonstrated that MRI instrumental staging based on T2-weighted images has a higher accuracy than FIGO clinical staging, and in 25% of patients, therapeutic decisions changed thanks to MRI prior analysis [15, 16].

Several studies evaluated MRI accuracy to assess treatment response of advanced cervical carcinoma to chemoradiotherapy adding to the qualitative morphological sequences (HR T2-weighted images), DWI sequences, and ADC maps as a quantitative and accurate information being this technique capable to reflect important biological characteristics of tissue [16-28].

Usually, neoplastic cervical tissue shows hypersignal intensity in T2-WI and DWI images with a restricted hypointense ADC map, while cervical chemoradiotreated tissue can show ambiguous T2 signal intensity being the radio treated area usually hypo or hysointense [17-20].

DWI with ADC maps could provide quantitative and precise information of the tissue behaviour. Further studies validated the role of ADC in differentiation of normal from pathological tissue [12-14; 21-27].

Naganawa *et al.* in 2004 first gave a baseline that was taken as an example by others [12]. Next to Naganawa *et al.*, other authors such as Chen *et al.*, Hoogendam *et al.*,

and McVeigh *et al.* were interested in finding cut-off ADC values [23, 24, 27]. All studies showed statistically relevant cut-off ADC values; furthermore Chen *et al.* calculated an ADC cut-off value comparing a group of oncologic patients with a group of treated ones [15].

The main limits of the previous studies were: the inclusion of both adenocarcinomas and squamocellular cervical tumors, single, and not standardized areas to set ROIs, short follow up timing (three months) in which the tissue preserve an active microenvironment with edema, hypoxia, and granulation tissue induced by radiotherapy that could lead to false positive results [14, 22, 24, 27-29].

ADC cut-off values have a statistic relevant impact between pathological and healthy tissues (Table 3). This information could be accurately assessed by T2 morphological analysis, and there is no added role of ADC values in clinical management of oncological patients.

The present study included a comparison between advanced cervical carcinoma ADC values and ADC values of a merged group made by combining control group and healed patients after treatment (Table 3).

The most positive data obtained is the third ROC curve (Figure 6). As we can see this curve compares a group of healthy patients (merged control group with treated and healed one) with a group of ill patients, and as the Youden Index of this curve shows, the authors obtained a cut-off value of  $1.18 \times 10^{-3} \text{mm}^2/\text{s}$  with a high sensitivity and specificity. The present study permitted to state with relative certainty that the values beneath  $1.18 \times 10^{-3} \text{mm}^2/\text{s}$  related to the

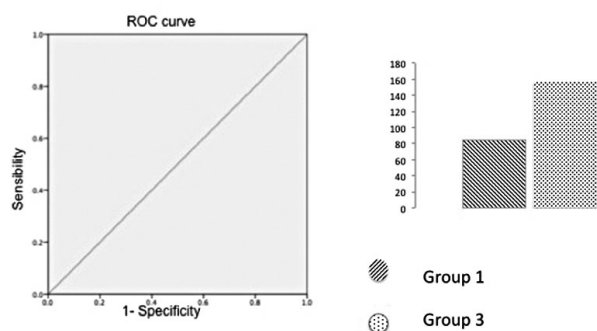


Figure 4. — Figure shows the first ROC curve obtained by comparing groups 1 and 3. The Youden Index assess a cut off value of  $1.28 \times 10^{-3} \text{mm}^2$  (100% sensitivity and specificity).

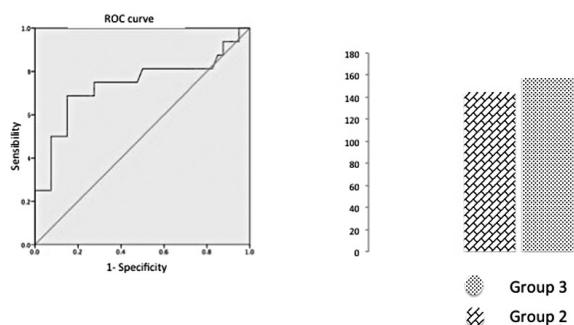


Figure 5. — Figure shows the second ROC curve obtained by comparing groups 3 and 2. The Youden Index assess a cut off value of  $1.51 \times 10^{-3} \text{mm}^2$  (73% of sensibility and 75% of specificity)

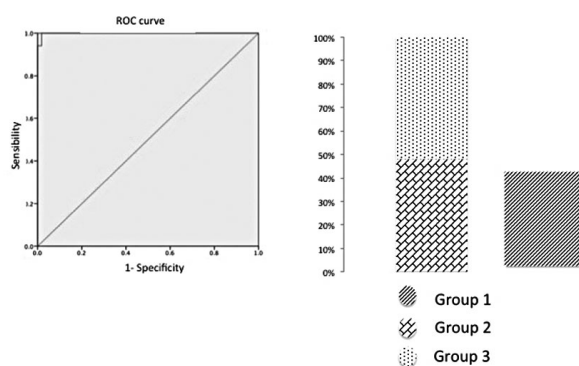


Figure 6. — Figure shows the third curve obtained by comparing the merged (radiotreated tissues and normal ones) and group 1. The Youden Index assess a cut off value of  $1.18 \times 10^{-3} \text{mm}^2$  (sensitivity 73% and specificity of 100%).

recurrence of pathological areas, and all the values above  $1.18 \times 10^{-3} \text{mm}^2/\text{s}$  related to healed patients with a sensitivity of 73% and a specificity of 100%, that decrease the possibility of making unsightly mistakes. This data could have a clinical impact in the management of cervical cancer follow up. Concerning follow up protocols, the authors can

affirm that ADC value could be a useful element to solve the radiological issue to differentiate pathological tumour from fibrotic radio-induced ones and from recurrent disease.

In conclusion, the present results showed that ADC could be included in follow up protocols as a useful marker to discriminate healed patients from ill ones. Being ADC a quantitative value, it is more immediate, precise, and accurate compared to qualitative investigations that leaves unsolved ambiguities in follow up protocols used nowadays. Further and wider investigations are needed in order to collect more data, for a correct and robust validation of ADC values, in the evaluation of treatment response in cervical cancer.

## Conclusion

Values below  $1.18 \times 10^{-3} \text{mm}^2/\text{s}$  could be considered as a recurrent pathology with relative certainty. As quantitative data, it is a more precise tool compared to T2-weighted images for the radiological evaluation during follow-up of chemo-radio treated patients. A certain and non-invasive radiological evaluation is fundamental to preserve female identity and fertility in young women.

## Acknowledgements

During the years working on this study, many professors, surgeons, students, and technicians offered their help. The authors received collaboration and help from the Department of Gynecology and Oncology of their Hospital, so they would like to thank these special people to have made this study possible.

## References

- [1] Jemal A., Siegel R., Xu J., Ward E.: "Cancer statistics, 2010". *CA Cancer J. Clin.*, 2010, 60, 277.
- [2] Kesic V., Rodolakis A., Denschlag D., Schneider A., Morice P., Amant F., Reed N.: "Fertility preserving management in gynecologic cancer patients: the need for centralization". *Int. J. Gynecol. Cancer*, 2010, 20, 1613e9.
- [3] Pecorelli S., Zigliani L., Odicino F.: "Revised FIGO staging for carcinoma of the cervix". *Int. J. Gynaecol. Obstet.*, 2009, 105, 107.
- [4] Edge S.B., Byrd D.R., Compton C.C., Fritz A.G., Greene F.L., Trotti A.: "Cervix uteri". *AJCC Cancer Staging Manual*. 7<sup>th</sup> ed. New York, NY: Springer, 2010, 395.
- [5] Balleyquier C., Sala E., Da Cunha T., Bergman A., Brkljacic B., Danza F., *et al.*: "Staging of uterine cervical cancer with MRI: guidelines of the European Society of Urogenital Radiology". *Eur. Radiol.*, 2011, 21, 1102.
- [6] Querleu D., Morrow C.P.: "Classification of radical hysterectomy". *Lancet. Oncol.*, 2008, 9, 297.
- [7] Denny L., Hacker N.F., Gori J., Jones H.W. III, Ngan H.Y.S., Pecorelli S.: FIGO Committee on Gynecologic Oncology. Staging Classifications and Clinical Practice. Guidelines for Gynaecologic Cancers. Available at: [http://www.figo.org/publications/staging\\_classifications](http://www.figo.org/publications/staging_classifications)
- [8] Thomeer M.G., Gerestein C., Spronk S., Van Doorn H.C., Van der

- Ham E., Hunink M.G.: "Clinical examination versus magnetic resonance imaging in the pretreatment staging of cervical carcinoma: Systematic review and meta-analysis". *Eur. Radiol.*, 2013, 23, 2005.
- [9] Dhoot N.M., Kumar V., Shinagare A., Katakai A.C., Barmon D., Bhuyan U.: "Evaluation of carcinoma cervix using magnetic resonance imaging: correlation with clinical FIGO staging and impact on management". *J. Med. Imaging Radiat. Oncol.*, 2012, 56, 58.
- [10] Stenstedt K., Hellstrom A.C., Fridsten S., Blomqvist L.: "Impact of MRI in the management and staging of cancer of the uterine cervix". *Acta Oncol.*, 2011, 50, 420.
- [11] Le Bihan D.: "Apparent diffusion coefficient and beyond: what diffusion MR imaging can tell us about tissue structure". *Radiology*, 2013, 268, 318.
- [12] Naganawa S., Sato C., Kumada H., Ishigaki T., Miura S., Takizawa O.: "Apparent diffusion coefficient in cervical cancer of the uterus: comparison with the normal uterine cervix". *Eur. Radiol.*, 2005, 15, 71.
- [13] Kuang F., Ren J., Zhong Q., Liyuan F., Huan Y., Chen Z.: "The value of apparent diffusion coefficient in the assessment of cervical cancer". *Eur. Radiol.*, 2013, 23, 1050.
- [14] Kilickesmez O., Bayramoglu S., Inci E., Cimilli T., Kayhan A.: "Quantitative diffusion-weighted magnetic resonance imaging of normal and diseased uterine zones". *Acta Radiol.*, 2009, 50, 340.
- [15] Dhoot N.M., Kumar V., Shinagare A., Katakai A.C., Barmon D., Bhuyan U.: "Evaluation of carcinoma cervix using magnetic resonance imaging: Correlation with clinical FIGO staging and impact on management". *J. Med. Imaging Radiat. Oncol.*, 2012, 56, 5.
- [16] Padhani A.R., Liu G., Koh D.M., Chenevert T.L., Thoeny H.C., Takahara T., et al.: "Diffusion-weighted magnetic resonance imaging as a cancer biomarker: consensus and recommendations". *Neoplasia*, 2009, 11, 102.
- [17] Whittaker C.S., Coady A., Culver L., Rustin G., Padwick M., Padhani A.R.: "Diffusion-weighted MR imaging of female pelvic tumors: a pictorial review". *Radiographics*, 2009, 29, 759.
- [18] Hameeduddin A., Sahdev A.: "Diffusion-weighted imaging and dynamic contrast-enhanced MRI in assessing response and recurrent disease in gynaecological malignancies". *Cancer Imaging*, 2015, 15, 3.
- [19] Schreuder, M.D., Lensing R., Stoker J., Bipat S.: "Monitoring Treatment Response in Patients Undergoing Chemoradiotherapy for Locally Advanced Uterine Cervical Cancer by Additional Diffusion-Weighted Imaging: A Systematic Review". *J. Magn. Reson. Imaging*, 2015, 42, 572.
- [20] Okamoto Y., Tanaka Y.O., Nishida M., Tsunoda H., Yoshikawa H., Itai Y.: "MR imaging of the uterine cervix: imaging-pathologic correlation". *Radiographics*, 2003, 23, 425.
- [21] Charles-Edwards E.M., Messiou C., Morgan V.A., De Silva S.S., McWhinney N.A., Katesmark M., et al.: "Diffusion-weighted imaging in cervical cancer with an endovaginal technique: potential value for improving tumor detection in stage Ia and Ib1 disease". *Radiology*, 2008, 249, 541.
- [22] Xue H.D., Li S., Sun F., Sun H.Y., Jin Z.Y., Yanq J.X., Yu M.: "Clinical application of body diffusion weighted MR imaging in the diagnosis and preoperative N staging of cervical cancer". *Chinese Medical Sciences Journal*, 2008, 23, 133.
- [23] McVeigh P.Z., Syed A.M., Milosevic M., Fyles A., Haider M.A.: "Diffusion-weighted MRI in cervical cancer". *Eur. Radiol.*, 2008, 18, 1058.
- [24] Chen J., Zhang Y., Liang B., Yang Z.: "The utility of diffusion-weighted MR imaging in cervical cancer". *Eur. J. Radiol.*, 2010, 74, e101.
- [25] Ho K.C., Lin G., Wang J.J., Lai C.H., Chanq C.J., Yen T.C.: "Correlation of apparent diffusion coefficients measured by 3T diffusion-weighted MRI and SUV from FDG PET/CT in primary cervical cancer". *Eur. J. Nucl. Med. Mol. Imaging*, 2009, 36, 200.
- [26] Harry V.N., Semple S.I., Gilbert F.J., Parkin D.E.: "Diffusion-weighted magnetic resonance imaging in the early detection of response to chemoradiation in cervical cancer". *Gynecol. Oncol.*, 2008, 111, 213.
- [27] Hoogendam J.P., Klerkx W.M., de Kort G.A., Bipat S., Zweemer R.P., Sie-Go D.M., et al.: "The influence of the b-value combination on apparent diffusion coefficient based differentiation between malignant and benign tissue in cervical cancer". *J. Magn. Reson. Imaging*, 2010, 32, 376.
- [28] Levy A., Caramella C., Chargari C., Medjhouli A., Rey A., Zareski E., et al.: "Accuracy of diffusion-weighted echo-planar MR imaging and ADC mapping in the evaluation of residual cervical carcinoma after radiation therapy". *Gynecol. Oncol.*, 2011, 123, 110.
- [29] Vincens E., Balleyquier C., Rey A., Uzan C., Zareski E., Gouy S., et al.: "Accuracy of magnetic resonance imaging in predicting residual disease in patients treated for stage IB2/II cervical carcinoma with chemoradiation therapy: correlation of radiologic findings with surgical-pathologic results". *Cancer*, 2008, 113, 2158.

Corresponding Author:  
 G.M. BARELLI, M.D.  
 Radiology Unit, Sapienza University of Rome  
 Sant'Andrea Hospital  
 Via di Grottarossa 1035  
 00189 Rome (Italy)  
 e-mail: giuliamarta.barelli@gmail.com