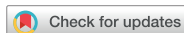

Images in Cardiovascular Disease



Echocardiographic Visualization of Retroaortic Anomalous Coronary Artery

Noemi Bruno , MD, Iliaria Ferrari , MD, Francesco Pelliccia , MD, Carlo Gaudio , MD, and Luca Monzo , MD, PhD

Department of Clinical Internal, Anesthesiology and Cardiovascular Sciences, Sapienza University, Rome, Italy

OPEN ACCESS

Received: Jun 8, 2021

Revised: Jul 3, 2021

Accepted: Jul 12, 2021

Address for Correspondence:

Luca Monzo, MD, PhD

Department of Clinical Internal,
Anesthesiology and Cardiovascular Sciences,
Sapienza University, Viale del Policlinico, 155,
00161 Rome, Italy.
E-mail: luca.monzo@uniroma1.it

Copyright © 2021 Korean Society of
Echocardiography

This is an Open Access article distributed
under the terms of the Creative Commons
Attribution Non-Commercial License (<https://creativecommons.org/licenses/by-nc/4.0/>)
which permits unrestricted non-commercial
use, distribution, and reproduction in any
medium, provided the original work is properly
cited.

ORCID iDs

Noemi Bruno
<https://orcid.org/0000-0003-4847-9885>
Iliaria Ferrari
<https://orcid.org/0000-0002-7215-3757>
Francesco Pelliccia
<https://orcid.org/0000-0003-1260-1308>
Carlo Gaudio
<https://orcid.org/0000-0002-8265-5945>
Luca Monzo
<https://orcid.org/0000-0003-2958-943X>

Conflict of Interest

The authors have no financial conflicts of
interest.

Author Contributions

Conceptualization: Pelliccia F, Gaudio C,
Monzo L; Data curation: Bruno N, Ferrari I;

A 65-year-old female was admitted to our clinic for sudden onset of typical chest pain at rest lasting few minutes. Her medical background included systemic hypertension, type 2 diabetes, dyslipidemia and mild obesity. Upon arrival in the emergency room, clinical examination was unremarkable and the electrocardiogram revealed sinus rhythm at 70 bpm without any sign of acute myocardial ischemia. Serial cardiac troponin T measurements were persistently negative. A transthoracic echocardiogram (TTE) was also performed showing mild ventricular hypertrophy, no regional wall motion abnormalities and a preserved left ventricular ejection fraction of 55%. A highly echogenic tubular structure, located slightly on the atrial side of the atrioventricular groove was noted (arrows) in apical 4-chamber (**Figure 1A; Supplementary Video 1**), 2-chamber (**Figure 1B; Supplementary Video 2**), and 3-chamber (**Figure 1C; Supplementary Video 3**) view. Its persistence in more than an echocardiographic plane excluded an artifact. Indeed, its tubular shape was suggestive of a vascular structure, but its location was atypical for a normal vessel.

According to patient's clinical history and her high cardiovascular risk profile she was referred for coronary angiography, which revealed no critical stenosis but the anomalous aortic origin of a coronary artery (AAOCA) from the inappropriate sinus of Valsalva (**Figure 1D; Supplementary Video 4**). In particular, we showed that the left main coronary artery (LMCA) arose, sharing the origin with the right coronary artery, from the right coronary cusp and then took a caudal posterior loop running posterior to the aortic root (**Figure 1E and F**). Hence, we could recognize the tubular structure seen at TTE as the retroaortic course of LMCA, a finding recently described as retroaortic anomalous coronary (RAC) sign.

Among AAOCA, the retroaortic course of the LMCA is an uncommon diagnosis in adults, and its association with a single coronary origin is extremely rare.¹⁾ Although it has been usually considered a benign clinical entity, it may pose troubles during valve surgery²⁾ and some reports described an increased risk in morbidity and mortality.³⁾ In a recent study, the presence of RAC sign was demonstrated to be highly suggestive of an anomalous coronary artery (specificity 93.9%) and strongly associated with retroaortic LMCA course at computed tomography angiography exam.⁴⁾ Accordingly, it is of utmost importance for cardiologists to recognize the RAC sign and its significance, since it may provide key clues for a correct diagnosis. It should be acknowledged that the RAC sign may mimics other common TTE findings, such as image artifacts and annular or valvular calcifications, and therefore should be carefully differentiated from them.

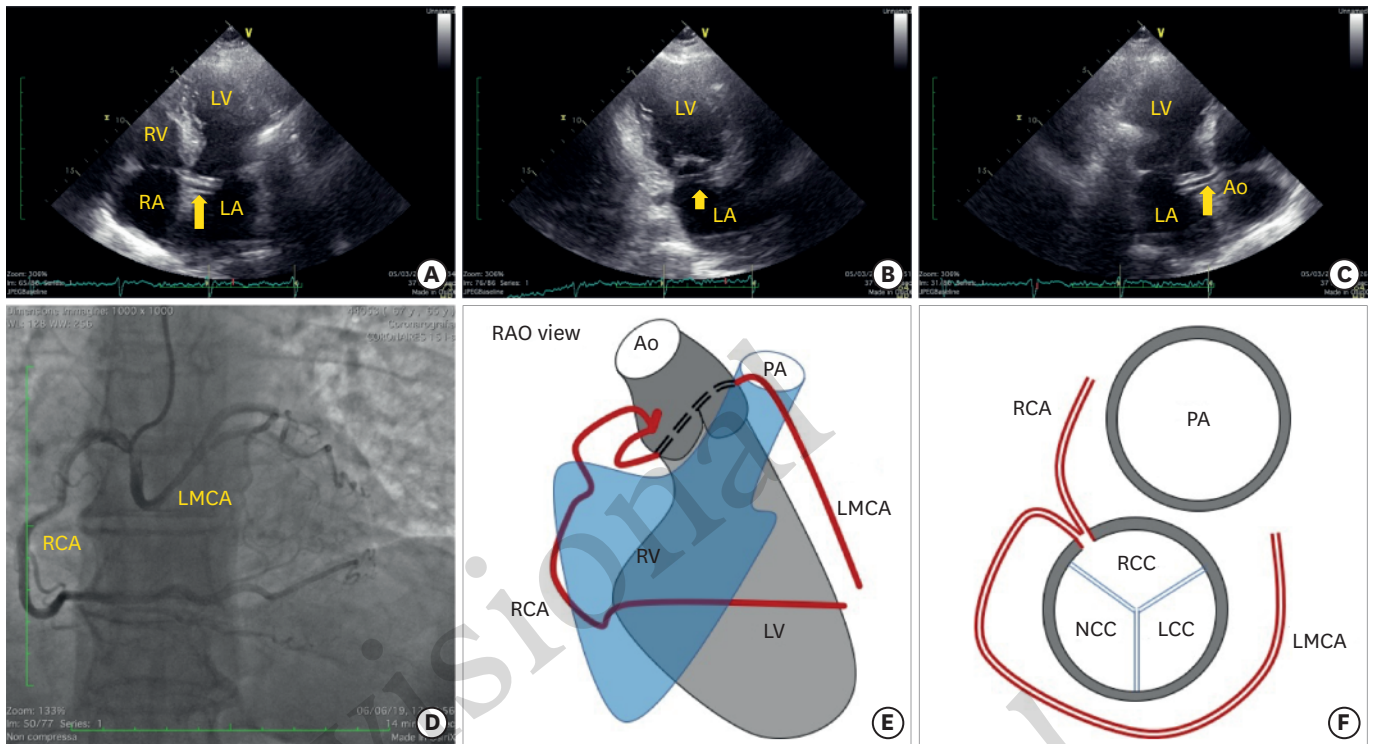


Figure 1. Transthoracic echocardiogram showing the RAC sign (arrow) in the apical 4-chamber (A), 2-chamber (B) and 3-chamber (C) view. Coronary angiography in the RAO view demonstrating the anomalous origin of the LMCA from RCC and its course (D). Diagrammatic illustrations of the course and origin of the anomalous LMCA in the angiographic RAO projection (E) and at sinuses of Valsalva (F).
Ao: aorta, LA: left atrium, LCC: left coronary cusp, LMCA: left main coronary artery, LV: left ventricle, NCC: non-coronary cusp, PA: pulmonary artery, RA: right atrium, RAC: retroaortic anomalous coronary, RAO: right anterior oblique, RCC: right coronary cusp, RCA: right coronary artery, RV: right ventricle.

Investigation: Bruno N, Ferrari I, Monzo L;
Software: Ferrari I; Supervision: Pelliccia F,
Gaudio C, Monzo L; Validation: Pelliccia F,
Gaudio C, Monzo L; Visualization: Monzo L;
Writing - original draft: Bruno N; Writing -
review & editing: Pelliccia F, Gaudio C, Monzo L.

SUPPLEMENTARY MATERIALS

Supplementary Video 1

Ref. (A) RAC sign in the apical 4-chamber view.

[Click here to view](#)

Supplementary Video 2

Ref. (B) RAC sign in the apical 2-chamber view.

[Click here to view](#)

Supplementary Video 3

Ref. (C) RAC sign in the apical 3-chamber view.

[Click here to view](#)

Supplementary Video 4

Ref. (D) Coronary angiography in the right anterior oblique view demonstrating the anomalous aortic origin of the left main coronary artery.

[Click here to view](#)

REFERENCES

1. Reig J, Jornet A, Petit M. Anomalous left coronary artery originating in the right aortic sinus with retroaortic course: a postmortem study. *Angiology* 1994;45:57-60.
[PUBMED](#) | [CROSSREF](#)
2. Vaishnava P, Pyo R, Filsoufi F, Sharma S. Compression of an anomalous left circumflex artery after aortic and mitral valve replacement. *Ann Thorac Surg* 2011;92:1887-9.
[PUBMED](#) | [CROSSREF](#)
3. Kejriwal NK, Tan J, Gordon SP, Newman MA. Retroaortic course of the anomalous left main coronary artery: is it a benign anomaly? A case report and review of literature. *Heart Lung Circ* 2004;13:97-100.
[PUBMED](#) | [CROSSREF](#)
4. Witt CM, Elvert LA, Konik EA, Ammash NM, Foley DA, Foley TA. The RAC sign: retroaortic anomalous coronary artery visualization by transthoracic echocardiography. *JACC Cardiovasc Imaging* 2018;11:648-9.
[PUBMED](#) | [CROSSREF](#)

Provisional
Provisional