

Flares of mixed cryoglobulinaemia vasculitis after vaccination against SARS-CoV-2

Studies on the safety and immunogenicity of SARS-CoV-2 vaccination in patients with inflammatory rheumatic diseases have so far not included mixed cryoglobulinaemia (MC) vasculitis.¹⁻³ We report a prospective observational multi-centre study on this disorder.

Participants were followed at four tertiary referral centres and were instructed to promptly inform the attending physicians about unusual events felt as possibly related to vaccination. Seventy-one patients were recruited: they had infection-cured hepatitis C virus (HCV)-related MC, either uncomplicated (HCV-MC, n=50) or complicated by low-grade non-Hodgkin's lymphoma (MC-NHL, n=8), or essential MC (EMC, n=13). The characteristics of the patients, exclusion criteria and definition of bona fide vaccination-related flare are described in online supplemental methods.

Overall, 9 of 71 (12.7%) patients had postvaccination MC vasculitis flare. However, 8 of 71 patients had experienced within 12 months before vaccination spontaneous flares, where 7 cases required rituximab and 3 of them (37.5%) had postvaccination flare (see online supplemental information). Thus, to exclude the confounding effects of high proneness to spontaneous flare as the facilitator and of rituximab as the preventor, we further restricted the evaluation of postvaccination flare rate to 63 patients off-therapy and without spontaneous flares for 20–48 months before vaccination (see online supplemental information). In none of them rituximab was postponed in view of vaccination.

Six of the 63 patients (9.5%) with stable MC had bona fide vaccination-related flares (table 1). Flares were more frequent in patients with EMC (3 of 8, 37%) than with HCV-cured HCV-MC or MC-NHL (3 of 55, 5.4%) (p=0.023). Flares were characterised by purpura, new onset in one case, which subsided within 1–2 weeks; in three cases the purpura was so diffuse (online supplemental figure 1) that one patient defined it as 'never experienced before' and another refused the second dose. Two patients also had flare of peripheral neuropathy that had remained stable for

several months. Cryoglobulins (online supplemental figure 2A) increased in 2 of 6 patients with and in 0 of 25 patients without flare tested (p=0.032).

Anti-SARS-CoV-2 IgG responses were measured 8–14 days after the second dose of vaccine in 50 patients. Five of 43 (11.6%) rituximab-free and 5 of 7 (71%) rituximab-treated patients (p=0.002) proved seronegative (<7 binding antibody units/mL) (online supplemental figure 2B). Seronegativity was more frequent (p=0.04) among patients with EMC (2 of 5) than with HCV-MC (1 of 33) (online supplemental figure 2C), suggesting lower immune dysregulation in HCV-MC due to reversion of B cell abnormalities after clearance of infection.⁴ Among rituximab-treated patients, seronegativity correlated with B cell count <5 cells/ μ L (online supplemental table 2). No correlations were found between seronegativity and vasculitis flare or cryocrit level (online supplemental figure 2D,E).

Concerning possible mechanism(s) of post-vaccination flare, it is interesting that pathogenic rheumatoid factor-specific B cells expanded in MC are unresponsive to the stimulation of the B cell receptor and of toll-like receptors (TLR) 7 and 9, but can be activated by the simultaneous engagement of these receptors⁵; thus, vaccination-induced immune complexes acting as autoantigen for rheumatoid factor-specific B cells and vaccine nucleic acids acting as TLR 7/9 ligands could work together in activating pathogenic B cells in vivo.

The overall rate of postvaccination flare observed in patients with MC is similar to that reported in other autoimmune rheumatic diseases¹⁻³; importantly, flares did not endanger patients and subsided spontaneously. This reassures the safety of SARS-CoV-2 vaccination in patients with MC.


While in other inflammatory rheumatic diseases lack of immunogenicity of the SARS-CoV-2 vaccine was mostly attributed to immunosuppression especially with rituximab,^{1,2} the 11.6% seronegativity rate in treatment-free patients with MC suggests that disease-related factors may impair vaccine immunogenicity in this disorder. Two patients contracted mild COVID-19, one (rituximab-treated, seronegative) 3 weeks after and one (rituximab-untreated, seropositive) 17 weeks after the second dose of

Table 1 Demographic, clinical and immunological features of patients who had flare of stable MC vasculitis bona fide caused by vaccination against SARS-CoV-2

Patient	Age (years)/sex	MC type	SVR (months)	Last active symptoms and RTX before vaccination (months)			Symptoms after first dose	Symptoms after second dose	Cryocrit, %		SARS-CoV-2 Antibody titre (Binding Antibody Units/mL)
				Symptoms	RTX	Vaccine			Prevaccination	Flare	
1	70/male	EMC	N/A	P (40)	N/T	AstraZeneca	Diffuse P (day 3)	Second dose refused	1	6	N/A
2	41/female	EMC	N/A	P (20)	20	Pfizer	None	Diffuse P (day 1)	0	0	900
3	76/female	EMC	N/A	P (27)	N/T	Pfizer	None	Diffuse P (day 5)	0	0	2961
4	57/female	HCV-MC	67	PN (42)	N/T	Pfizer	None	Moderate P, PN (day 10)	Traces	Traces	694
5	66/female	HCV-MC	62	P, PN (48)	N/T	Pfizer	None	Moderate P, PN (day 7)	Traces	0	3115
6	63/female	HCV-MC	30	P, PN (26)	N/T	Pfizer	None	Moderate P (day 7)	0	10	2430

EMC, essential mixed cryoglobulinaemia; HCV-MC, hepatitis C virus-related mixed cryoglobulinaemia; MC, mixed cryoglobulinaemia; N/A, not applicable; N/T, never treated; P, purpura; PN, peripheral neuropathy; RTX, rituximab therapy; SVR, sustained virological response after antiviral therapy.

vaccine (see online supplemental information). Our observations encourage administering vaccine booster⁶ to patients with MC and postponing vaccination of rituximab-treated patients after B cell repopulation.

Marcella Visentini ¹, Laura Gragnani,² Stefano Angelo Santini,^{3,4} Teresa Urraro,⁵ Annalisa Villa,¹ Monica Monti,² Andrea Palladino,¹ Luisa Petracchia,² Francesca La Gualana,¹ Serena Lorini,² Silvia Marri,² Francesco Madia,² Lucia Stefanini,¹ Stefania Basili,¹ Massimo Fiorilli,¹ Clodoveo Ferri,^{6,7} Anna Linda Zignego,² Milvia Casato¹

¹Department of Translational and Precision Medicine, University of Rome La Sapienza, Rome, Italy

²MASVE Interdepartmental Center, Department of Experimental and Clinical Medicine, University of Florence, Firenze, Italy

³Department of Basic, Clinical, Intensive and Perioperative Biotechnological Sciences, Catholic University School of Medicine, Rome, Italy

⁴Synlab Italia, Monza, Italy

⁵Rheumatology Unit, M Scarlato Hospital, Scafati, Italy

⁶Rheumatology Unit, Università degli Studi di Modena e Reggio Emilia, Modena, Italy

⁷Rheumatology Unit, Madonna dello Scoglio Hospital, Cotronei, Italy

Correspondence to Dr Marcella Visentini, Department of Translational and Precision Medicine, University of Rome La Sapienza, 00185 Rome, Lazio, Italy; marcella.visentini@uniroma1.it

Handling editor Josef S Smolen

Contributors MV and LG contributed equally to this paper. Study design: MV, LG, MF, CF, ALZ, MC. Sample collection: LG, TU, MM, LP, SL, SM, FM. Experiments and data analysis: SAS, AV, AP, FLG. Tables and figures: MV, MF. Data interpretation: MV, LG, SAS, LS, SB, MF, CF, ALZ, MC. Writing of the manuscript: MV, MF, MC. Critical proof-reading of the manuscript: all authors.

Funding The study was funded by the Sapienza University Intramural Research Programme (grants RM11916B7567F9E4 and RM120172B8BE02DA) and by department funds of the centres participating in the study.

Competing interests None declared.

Patient consent for publication Consent obtained directly from patient(s).

Ethics approval This study was performed in accordance with the principles of the Declaration of Helsinki and was approved by the Ethics Committee of Sapienza University of Rome (prot. 0486/2021). The participants provided informed consent.

Provenance and peer review Not commissioned; externally peer reviewed.

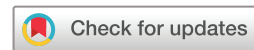Supplemental material This content has been supplied by the author(s). It has not been vetted by BMJ Publishing Group Limited (BMJ) and may not have been peer-reviewed. Any opinions or recommendations discussed are solely those of the author(s) and are not endorsed by BMJ. BMJ disclaims all liability and responsibility arising from any reliance placed on the content. Where the content

includes any translated material, BMJ does not warrant the accuracy and reliability of the translations (including but not limited to local regulations, clinical guidelines, terminology, drug names and drug dosages), and is not responsible for any error and/or omissions arising from translation and adaptation or otherwise.

This article is made freely available for use in accordance with BMJ's website terms and conditions for the duration of the covid-19 pandemic or until otherwise determined by BMJ. You may use, download and print the article for any lawful, non-commercial purpose (including text and data mining) provided that all copyright notices and trade marks are retained.

© Author(s) (or their employer(s)) 2021. No commercial re-use. See rights and permissions. Published by BMJ.

► Additional supplemental material is published online only. To view, please visit the journal online (<http://dx.doi.org/10.1136/annrheumdis-2021-221248>).



To cite Visentini M, Gragnani L, Santini SA, *et al.* *Ann Rheum Dis* Epub ahead of print: [please include Day Month Year]. doi:10.1136/annrheumdis-2021-221248

Received 27 July 2021

Accepted 9 November 2021

Ann Rheum Dis 2021;**0**:1–2. doi:10.1136/annrheumdis-2021-221248

ORCID iD

Marcella Visentini <http://orcid.org/0000-0002-4053-6091>

REFERENCES

- 1 Furer V, Eviatar T, Zisman D, *et al.* Immunogenicity and safety of the BNT162b2 mRNA COVID-19 vaccine in adult patients with autoimmune inflammatory rheumatic diseases and in the general population: a multicentre study. *Ann Rheum Dis* 2021;80:1330–1338.
- 2 Izmirlir PM, Kim MY, Samanovic M, *et al.* Evaluation of immune response and disease status in SLE patients following SARS-CoV-2 vaccination. *Arthritis Rheumatol* 2021. doi:10.1002/art.41937. [Epub ahead of print: 04 Aug 2021].
- 3 Connolly CM, Ruddy JA, Boyarsky BJ, *et al.* Disease flare and reactogenicity in patients with rheumatic and musculoskeletal diseases following two-dose SARS-CoV-2 messenger RNA vaccination. *Arthritis Rheumatol* 2021. doi:10.1002/art.41924. [Epub ahead of print: 04 Aug 2021].
- 4 Del Padre M, Todi L, Mitrevski M, *et al.* Reversion of anergy signatures in clonal CD21^{low} B cells of mixed cryoglobulinemia after clearance of HCV viremia. *Blood* 2017;130:35–8.
- 5 Visentini M, Cagliuso M, Conti V, *et al.* Clonal B cells of HCV-associated mixed cryoglobulinemia patients contain exhausted marginal zone-like and CD21 low cells overexpressing STRA13. *Eur J Immunol* 2012;42:1468–76.
- 6 Callaway E. COVID vaccine boosters: the most important questions. *Nature* 2021;596:178–80.

Flares of mixed cryoglobulinemia vasculitis after vaccination against SARS-CoV-2

Marcella Visentini, Laura Gragnani, Stefano Angelo Santini, Teresa Urraro, Annalisa Villa, Monica Monti, Andrea Palladini, Luisa Petraccia, Francesca La Gualana, Serena Lorini, Silvia Marri, Francesco Madia, Lucia Stefanini, Stefania Basili, Massimo Fiorilli, Clodoveo Ferri, Anna Linda Zignego, Milvia Casato

Supplementary Information

Methods

Study design

We conducted this observational multicentre study on the clinical and immunological outcomes of SARS-CoV-2 vaccination in MC patients by recruiting consecutive participants attending the tertiary referral centres in Rome, Florence, Cotronei and Scafati, Italy. Participants received the first dose of vaccine between February 2 and May 19, 2021.

Participant involvement

The potential benefits and risks of SARS-CoV-2 vaccination for patients with MC and the importance of gaining information on these issues were thoroughly discussed with participants on the basis of the available knowledge. Participants were instructed to promptly inform their referral centres about any unusual event that they felt as potentially related to vaccination and, possibly, to provide digital images of unusual cutaneous or mucosal lesions.

Demographic and clinical characteristics of patients

The 71 patients recruited into the study had either hepatitis C virus-related MC (HCV-MC), essential MC (EMC), or MC complicated by low-grade non-Hodgkin lymphoma (NHL). All patients with HCV-MC or HCV-related MC-NHL had been treated with direct acting antivirals except for one HCV-MC patient treated with interferon; all patients had sustained virologic responses lasting since 5 to 131 (median 48) months in the case of HCV-MC, and 12 to 97 (median 62) months in the case of HCV-related MC-NHL.

Criteria for bona fide vaccine-related flare of MC vasculitis

The criteria for classifying the clinical manifestations and the severity of vasculitis have been described previously.[1]

We did not consider as suggestive of flare those manifestations such as fever, arthralgia, myalgia or lymphadenopathy that are known side effects of SARS-CoV-2 vaccination. We did not consider as bona fide vaccine-related the vasculitis flares that occurred more than one month after vaccination.

We excluded that flares of purpura occurring in our patients after vaccination were due to vaccine-induced immune thrombocytopenia[2,3] since platelet counts remained

normal in all of them. New onset non-thrombocytopenic leukocytoclastic purpura after SARS-CoV-2 vaccination has been described in exceedingly rare patients;^[4,5] thus, we felt reasonable to believe that post-vaccination episodes of non-thrombocytopenic purpura in MC patients represented bona fide vasculitis flares.

Patient subgroups

Eight patients had experienced spontaneous flares of MC vasculitis within 12 months before vaccination, and 7 of them (5 with EMC and 2 with MC-NHL) needed rituximab therapy. Three of the 8 patients had post-vaccination flare; 2 of them had been treated with rituximab.

- A 40-year-old female with HCV-MC plus low-grade NHL had been treated with rituximab for persisting purpura, her only vasculitis manifestation, 33 weeks before the first dose of Pfizer vaccine, and had remained free of vasculitis symptoms thereafter. Eight days after the second dose she had flare of purpura and, thereafter, developed new-onset kidney disease (24-h urine total protein content of 1,100 mg, hypoalbuminemia and oedema) and was treated with rituximab; purpura and proteinuria subsided within one month.
- A 75-year-old male with EMC was treated with rituximab 4 months before the first dose of Pfizer vaccine because of persisting purpura. Six days after the first dose he had a flare of unusually diffuse purpura that subsided after 5 days; 10 days after the second dose he had a new flare of purpura that subsided within 1 week.
- A 77-year-old female with HCV-MC, was excluded from the evaluation of flare rate since her post-vaccination flare was eventually considered as hardly classifiable; in fact, although she had flare of purpura after both doses of Moderna vaccine (10 days after the first and 1 day after the second), highly suggestive for a causative connection, she had experienced a spontaneous purpura flare 9 months before vaccination.

We took into consideration the possible confounding effect of a high proneness to spontaneous flare in increasing the risk of vaccination-related flare, which indeed was 37.5% in the 8 patients who had disease flares within the 12 months before vaccination. Vice versa, we also took into consideration the possible confounding effect of recent rituximab therapy in preventing flares. Based on these considerations, we separately analysed the remaining 63 patients to gain information on the risk of vaccination-related flare when the disease is stable. All these patients had remained off-therapy, except for brief courses of low-dose glucocorticoid (≤ 10 mg prednisone or equivalent per day), for 20 to 48 months before vaccination.

Outcome of patients with symptoms of MC vasculitis at vaccination

Twenty-four of 63 patients with stable disease had chronic MC symptoms at the time of vaccination (supplementary Table 1). None of them had flare of the persisting symptoms or new-onset manifestations for 20 to 48 months before vaccination. Nineteen of the 24 symptomatic patients had stable paresthesia that substantially reflected established nerve damage rather than active peripheral neuropathy. Nine patients had purpura, with skin ulcers in one case, witnessing chronic active vasculitis. None of the 24 patients with persisting symptom(s) at the time of vaccination had post-vaccination flare.

Supplementary Table 1. Demographic and clinical features at the time of vaccination of 63 MC patients with stable disease.

Variable	HCV-MC	EMC	MC-NHL*
Participants	49	8	6
Female gender	39	6	4
Age y, median (range)	79 (44-88)	78.5 (42-86)	80.5 (60-83)
Vasculitis activity:			
None	29 (59%)	5 (63%)	5 (83%)
Mild**	19 (39%)	3 (37%)	1 (17%)
Severe	1 (2%)		
Symptoms:			
Peripheral neuropathy#	16 (33%)	2 (25%)	1 (17%)
Purpura	7 (10%)	2 (25%)	
Chronic kidney disease#	5 (10%)		1 (17%)
Skin ulcer	1 (2%)		
Therapy:			
None	44 (90%)	6 (75%)	5 (83%)
Low-dose glucocorticoid	5 (10%)	2 (25%)	1 (17%)
Vaccine:			
Pfizer/BioNTech	42 (86%)	7 (88%)	6 (100%)
Moderna	4 (8%)		
AstraZeneca	2 (4%)	1 (12%)	
Janssen	1 (2%)		

* NHL associated with HCV-cured HCV-MC.

** Including substantially stable paresthesia related to previous nerve damage.

Stable paresthesia with minor fluctuations or chronically impaired kidney function.

COVID-19 after vaccination

Two patients had symptomatic SARS-CoV-2 infection after 2 doses of Pfizer vaccine.

A 41-year-old female with EMC (patient #2 in Table 1 of the main text), with an antibody titre of 900 BAU/ml, had flare of purpura after the second vaccine dose; 17 weeks after the second dose she was diagnosed with COVID-19 (fever, dry cough, sore throat, ageusia); symptoms lasted for 7 days and one day after their disappearance she had a transient flare of diffuse purpura. The nasopharyngeal swab was negative 14 days after the diagnosis.

A 50-year-old female with EMC had been treated with rituximab 4 months before the first vaccine dose because of the persistence of moderate purpura. She failed to produce anti-SARS-CoV-2 antibodies and, 3 weeks after the second dose, had COVID-19 (fever, sore throat, diarrhoea); she was treated with anti-spike monoclonal antibodies and had moderate flare of purpura one day after infusion. COVID-19 symptoms lasted for 6 days and the nasopharyngeal swab was negative 15 days after the diagnosis.

SARS-CoV-2 serology

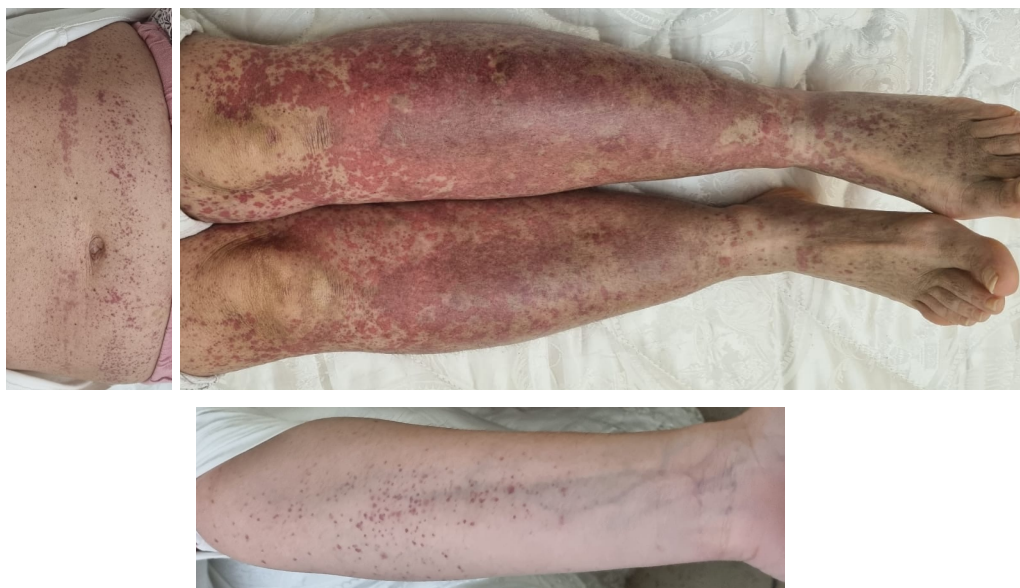Anti-SARS-CoV-2 spike IgG antibodies were measured at a single referral laboratory using the SARS-CoV-2 IgG II Quant antibody test (Abbott Laboratories, Chicago, IL). Antibody titres are expressed as Binding Antibody Units (BAU)/ml, with a cutoff for positive testing of 7 BAU/ml.

Statistical analysis

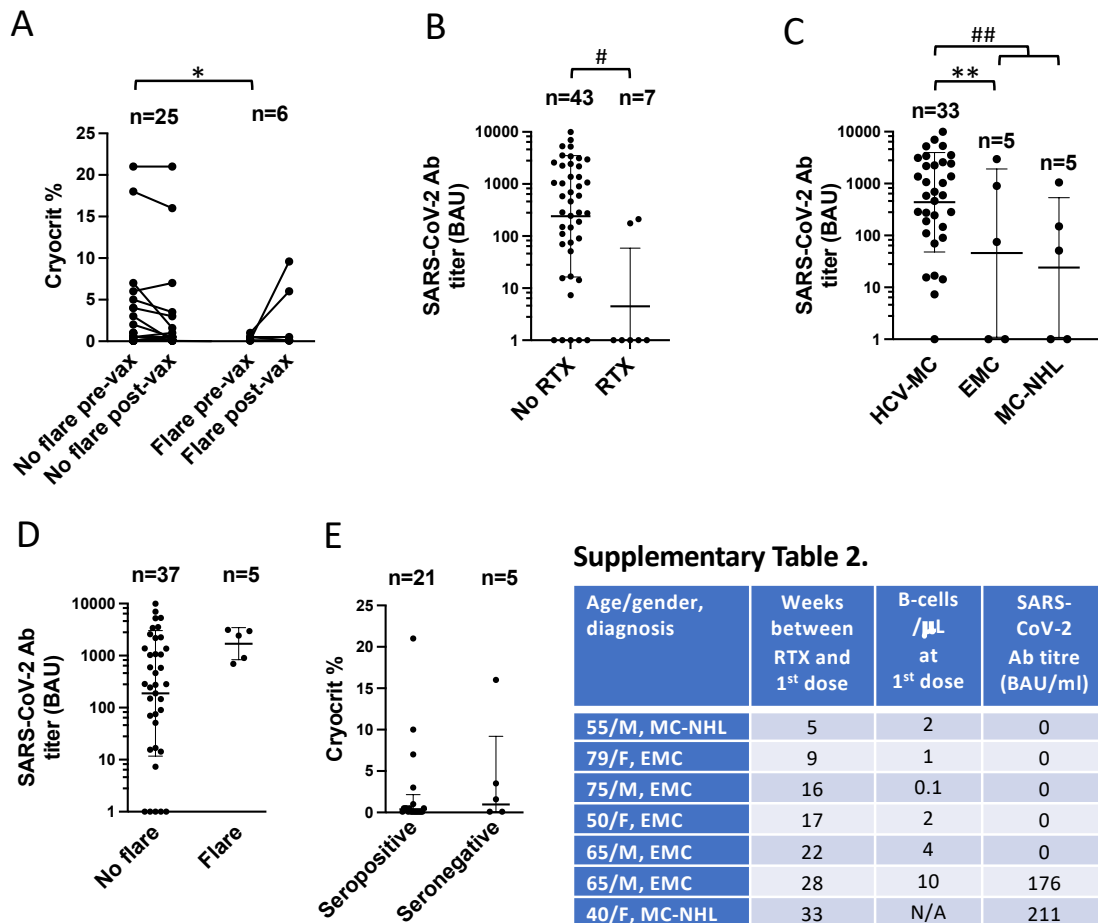
Descriptive summary statistics are reported as medians and ranges or as geometric means and geometric standard deviations. For between-group comparisons we used two-tailed Wilcoxon matched-pairs signed rank test, Mann Whitney test or the Fisher's exact test as appropriate; p values <0.05 were considered significant. All analyses were done using GraphPad Prism v9 (GraphPad Software).

References

1. Gagnani L, Visentini M, Fognani E, et al. Prospective study of guideline-tailored therapy with direct-acting antivirals for hepatitis C virus-associated mixed cryoglobulinemia. *Hepatology*. 2016;64:1473-82.
2. Simpson, C.R., Shi, T., Vasileiou, E. et al. First-dose ChAdOx1 and BNT162b2 COVID-19 vaccines and thrombocytopenic, thromboembolic and hemorrhagic events in Scotland. *Nat Med*. 2021; 27:1290–7.
3. Welsh KJ, Baumblatt J, Chege W, Goud R, Nair N. Thrombocytopenia including immune thrombocytopenia after receipt of mRNA COVID-19 vaccines reported to the Vaccine Adverse Event Reporting System (VAERS). *Vaccine*. 2021;39:3329-32.
4. Cebeci F, Kartal İ. Petechial skin rash associated with CoronaVac vaccination: first cutaneous side effect report before phase 3 results. *Eur J Hosp Pharm*. 2021 May 24:ejhpharm-2021-002794. doi: 10.1136/nejpharm-2021-002794.
5. Cazzato G, Romita P, Foti C, et al. Purpuric Skin Rash in a Patient Undergoing Pfizer-BioNTech COVID-19 Vaccination: Histological Evaluation and Perspectives. *Vaccines*. 2021;9:760.
6. Visentini M, Tinelli C, Colantuono S, et al. Efficacy of low-dose rituximab for the treatment of mixed cryoglobulinemia vasculitis: Phase II clinical trial and systematic review. *Autoimmun Rev*. 2015;14:889-96.
7. Thiel J, Rizzi M, Engesser M, et al. B cell repopulation kinetics after rituximab treatment in ANCA-associated vasculitides compared to rheumatoid arthritis, and connective tissue diseases: a longitudinal observational study on 120 patients. *Arthritis Res Ther*. 2017;19:101.



Supplementary Fig. 1. Representative images of diffuse purpura occurring 1 day after the 2nd dose of Pfizer/BioNTech vaccine (patient n. 2 in Table 1 of the main text). The digital images have been produced by the patient 4 days after the onset of flare.



Supplementary Fig. 2.

- (A) Cryocrit was measured before vaccination and 1-2 weeks after the second (n=30) or the first (1 patient with flare after the first dose who refused the second) vaccine dose. Increase of cryocrit value occurred in 2/6 patients with and in 0/25 without post-vaccination flare; *p=0.032 by Fisher's exact test.
- (B) Patients not treated with RTX had a lower seronegativity rate (5/43) than patients recently treated with RTX (5/7); # p=0.002. A correlation of the time lapse between rituximab therapy and first dose of vaccine with the serologic response after the second dose is illustrated in supplementary Table 2; seropositivity of the 2 patients treated with rituximab 7 or more months before vaccination is coherent with the B-cell repopulation time of approximately 6 months reported in most patients.[6, 7]
- (C) Five of 43 (11.6%) patients not treated with rituximab (RTX) failed to mount an antibody response to SARS-CoV-2. Patients with infection-cured HCV-MC had a lower seronegativity rate (1/33) than patients with EMC or infection-cured MC-NHL. ** HCV-MC vs EMC patients, p=0.04; ## HCV-MC vs pooled EMC/MC-NHL patients, p=0.0075.
- (D) No difference in the seronegativity rate among patients who had or did not have post-vaccination flare; one patient was excluded because of unclassifiable flare.
- (E) No difference in post-vaccination cryocrit values between seropositive and seronegative patients.