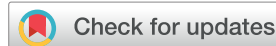

# Stillbirth and fetal capillary infection by SARS-CoV-2



Cira di Gioia, MD, PHD; Fabrizio Zullo, MD; Roberta Costanza Bruno Vecchio, MD; Cristina Pajno, MD; Giuseppina Perrone, MD, PHD; Paola Galoppi, MD, PHD; Francesco Pecorini, XX; Daniele Di Mascio, MD; Raffaella Carletti, Tech Lab, PHD; Carla Prezioso, Bs, PHD; Valeria Pietropaolo, Bs, PHD; Laura Masuelli, MD; Roberto Bei, MD; Costantino Ciallella, MD; Carlo Della Rocca, MD, PHD; Antonella Giancotti, MD, PHD; Roberto Brunelli, MD, PHD

We presented the case of stillbirth in a paucisymptomatic mother affected by SARS-CoV-2. At gross examination, the placenta showed a diffuse marble appearance and a focal hemorrhagic area. Multiple areas of hemorrhagic or ischemic necrosis with central and peripheral villous infarctions and thrombosis of several maternal and fetal vessels with luminal fibrin and platelet deposition were observed. All lesions seemed to be synchronous. Virus particles were identified within the cytoplasm of endothelial cells using electron microscopy, whereas SARS-CoV-2 RNA was detected in the placental tissue using real-time reverse transcription-polymerase chain reaction. Here, fetal vascular malperfusion was associated with infection; in fact, electron microscopy images showed that marked SARS-CoV-2

endotheliotropism involved the intravillous fetal capillaries. Furthermore, we confirmed that syncytiotrophoblast is the major target cell type for SARS-CoV-2 infection of the placenta. In conclusion, the possible consequences of the action of the placentotropic SARS-CoV-2 included the occurrence of vertical transmission, as reported in the literature, and/or stillbirth: the latter possibility may be triggered by a hampered maternal and/or fetal perfusion of the placenta. The diffuse thrombosis and subsequent ischemia of fetal capillaries induced by COVID-19 cannot be predicted by standard clinical surveillance.

## Introduction

In the setting of seasonal influenza epidemics, pregnancy is associated with a higher risk of severe complications because of the physiological changes of the immune, cardiovascular, and respiratory systems.<sup>1</sup> Although there is little information published regarding the impact of COVID-19 on pregnancy outcomes, increased rates of pregnancy loss, stillbirth, and preterm delivery have been reported.<sup>1</sup> In particular,

the 2020 report of the United Nations Inter-agency Group for Child Mortality Estimation (UNIGME) underlined the possible association between the lack of adequate and quality obstetrical care and increased incidence of stillbirth during the pandemic.<sup>2</sup>

The rate of positive COVID-19 tests in infants born to mothers affected by SARS-CoV-2 was very low with a pooled proportion of vertical transmission of 3.2%.<sup>3</sup> However, the exact mechanism of vertical transmission and placental damage still needed to be defined.

**Cite this article as:** di Gioia C, Zullo F, Bruno Vecchio RC, et al. Stillbirth and fetal capillary infection by SARS-CoV-2. *Am J Obstet Gynecol MFM* 2021;4:100523.

From the The Departments of Radiological, Oncological, and Pathological Sciences, Sapienza University of Rome, Rome, Italy; Maternal and Child Health and Urological Sciences, Sapienza University of Rome, Rome, Italy; Translational and Precision Medicine, Sapienza University of Rome, Rome, Italy; Public Health and Infectious Diseases, Sapienza University of Rome, Rome, Italy; L'Istituto di Ricovero e Cura a Carattere Scientifico San Raffaele Roma, Rome, Italy; Department of Experimental Medicine, Sapienza University of Rome, Rome, Italy; Department of Clinical Sciences and Translational Medicine, University of Rome Tor Vergata, Rome, Italy; Department of Anatomical, Histological, Forensic Medicine, and Orthopedic Sciences, Sapienza University of Rome, Rome, Italy; Department of Medico-Surgical Sciences and Biotechnologies, Sapienza University of Rome, Latina, Italy.

Received August 3, 2021; revised October 14, 2021; accepted October 18, 2021.

The authors report no conflict of interest.

This study received no financial support.

Corresponding author Fabrizio Zullo, MD. [f.zullo@hotmail.it](mailto:f.zullo@hotmail.it)

2589-9333/\$36.00

© 2021 Elsevier Inc. All rights reserved.

<http://dx.doi.org/10.1016/j.ajogmf.2021.100523>

## Case

A 33-year-old White woman, gravida 3, para 2, was referred to our Obstetric Emergency department, Policlinico Umberto I, Sapienza University of Rome, at 36 1/7 weeks' gestation, with preterm labor and a positive nasopharyngeal swab (NFS) for SARS-CoV-2, leading to a diagnosis of asymptomatic COVID-19. Vital parameters at hospital admission were normal. However, the ultrasonographic assessment showed absent fetal movement and heartbeat. Shortly after arrival, a dead male fetus was delivered vaginally, with meconium-stained amniotic fluid.

The patient's past medical history was unremarkable. Previous routine pregnancy examinations, including ultrasonographic assessments and noninvasive prenatal tests, showed no abnormality. At 34 weeks' gestation, the patient developed a fever that lasted 5 days, with a daily average body temperature of 39°C. An NFS for SARS-CoV-2 was performed, and the test returned positive. No other symptom was observed that could have affected the clinical course of the infection.

After hospital admission, hospitalization was uneventful. A chest computerized tomography scan found no sign of pulmonary involvement, disventilatory areas, pneumonialike consolidation, and interstitial pneumonia. Isolated increases of C-reactive protein and white blood cells were observed. Thrombophilia screening was negative; C3 and C4 and coagulation factors were within the normal range. No recent infection of hepatitis B and C, HIV, toxoplasma, human cytomegalovirus, parvovirus B19, syphilis, and rubella was detected. The patient was discharged 4 days after delivery.

### Pathology findings

The autoptotic findings showed that neonatal death occurred in a time ranging between 24 hours and 5 days before delivery. Swabs obtained from the fetal right and left main bronchi, small intestine, and rectum via reverse transcription-polymerase chain reaction (RT-PCR) assay returned negative for SARS-CoV-2 RNA.

### Placental gross examination

The maternal and fetal surfaces showed no macroscopic alteration with normal amniochorionic membranes. Sectioning and examination showed a diffuse marbled appearance and a focal hemorrhagic area (a diameter of 1.5 cm) near the basal plate (Figure 1). The umbilical cord showed a normal diameter, 3 umbilical vessels, and hypercoiling with a normal umbilical coiling index.

### Placental light microscopy and immunohistochemistry

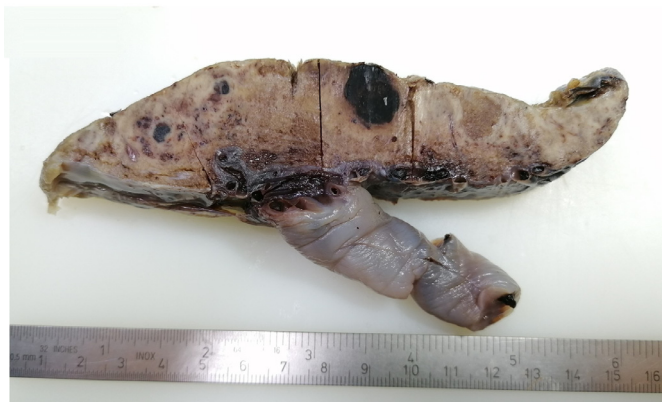At light microscopy, the placental tissue showed multiple areas of hemorrhagic or ischemic necrosis with central and peripheral villous infarctions (Figure 2, A). Thrombosis of several fetal and maternal vessels with luminal fibrin and platelet depositions was observed with some suggestive figures of intramural fibrin deposition in a vessel of the chorionic plate (Figure 2, B and C). All lesions seemed to be synchronous. There was no histologic sign of chorioamnionitis or umbilical arteritis.

The villi showed SARS-CoV spike immunohistochemical positivity of syncytiotrophoblasts and endothelial cells (Figure 3, A and B).

### Placental ultrastructural analysis

Ultrastructural analysis of the placental tissue showed a partially preserved structure owing to postmortem alterations and delayed tissue fixation with different extents of cellular swelling. Virus particles were identified mainly within the cytoplasm of endothelial cells, in the cytosol, and in cytoplasmic vacuoles or adjacent to damaged endothelial cells (Figure 4, A–C). Furthermore, the budding of viral particles was observed. The size of the virus particles was 80 to 105 nm

**FIGURE 1**  
**Formalin-fixed placenta**



The placental cut surface shows a diffuse marbled appearance and a focal hemorrhagic area (diameter of 1.5 cm) near the basal plate.

*di Gioia. Stillbirth and fetal capillary infection by SARS-CoV-2. Am J Obstet Gynecol MFM 2021.*

in diameter, which was consistent with the size and shape of SARS-CoV-2.

### Placental molecular findings

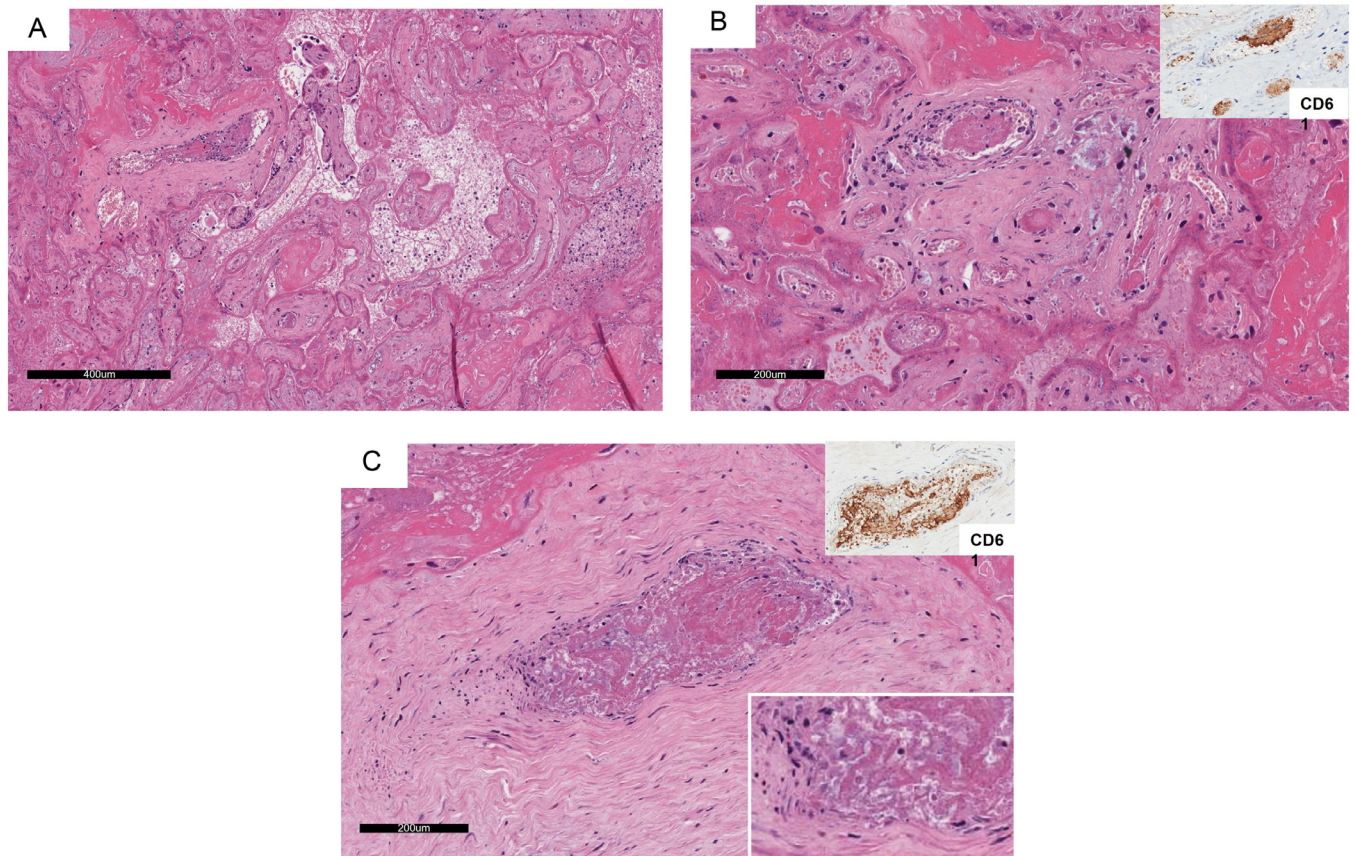
RNA was extracted from full-thickness paraffined sections of the placental parenchyma, which included both maternal and fetal sides and used to assess the presence of SARS-CoV-2 RNA via real-time RT-PCR assay. Probes used to detect the RNA-dependent RNA polymerase (RdRp), envelope (E), nucleocapsid (N) viral genes, and internal control were in FAM, Cal Red 610, Quasar 670, and HEX channels, respectively. In the extracted placental tissue, SARS-CoV-2 RNA was detectable with average cycle threshold (Ct) values and standard deviations: *RdRp*,  $24.4 \pm 0.24$ ; *E*,  $20.8 \pm 0.18$ ; and *N*,  $23.4 \pm 0.02$ . The results were considered valid only when the Ct value of the reference gene was  $\leq 40$  and positive when the Ct values of even 1 single target gene were  $\leq 40$ .

### Discussion

The risk of vertical transmission of SARS-CoV-2 represented an obvious concern. However, the occurrence of vertical transmission was rare, with an overall proportion of approximately 3%.<sup>4</sup>

In contrast, the risk of stillbirth among pregnant women with a confirmed peripartum SARS-CoV-2 infection was significantly increased.<sup>5</sup>

**FIGURE 2**  
**Serial H&E stained paraffin sections of placental tissue.**



At light microscopy view, the placental tissue shows areas of ischemic necrosis with villous infarctions (**A**) (10  $\times$ ) because of luminal thrombosis of both fetal (**B**) (20  $\times$ ) and maternal (**C**) (20  $\times$ ) vessels with suggestive figures of intramural fibrin deposition in a chorionic vessel (**C** insert). In the insert, we showed a positivity of thrombus for immunoperoxidase staining for antiplatelets, CD61 monoclonal antibody (Leica Biosystems, Newcastle upon Tyne, United Kingdom; catalog number PA0308; BOND Ready-to-Use prediluted CD61 antibody; incubation at room temperature).

H&E, hematoxylin and eosin.

di Gioia. Stillbirth and fetal capillary infection by SARS-CoV-2. *Am J Obstet Gynecol MFM* 2021.

In a previous series<sup>6</sup> of 5 stillborn infants, all placentas were characterized by the presence of chronic histiocytic intervillitis, syncytiotrophoblast necrosis, and massive fibrin deposition, leading to a condition of intervillous malperfusion that likely leads to fetal demise.

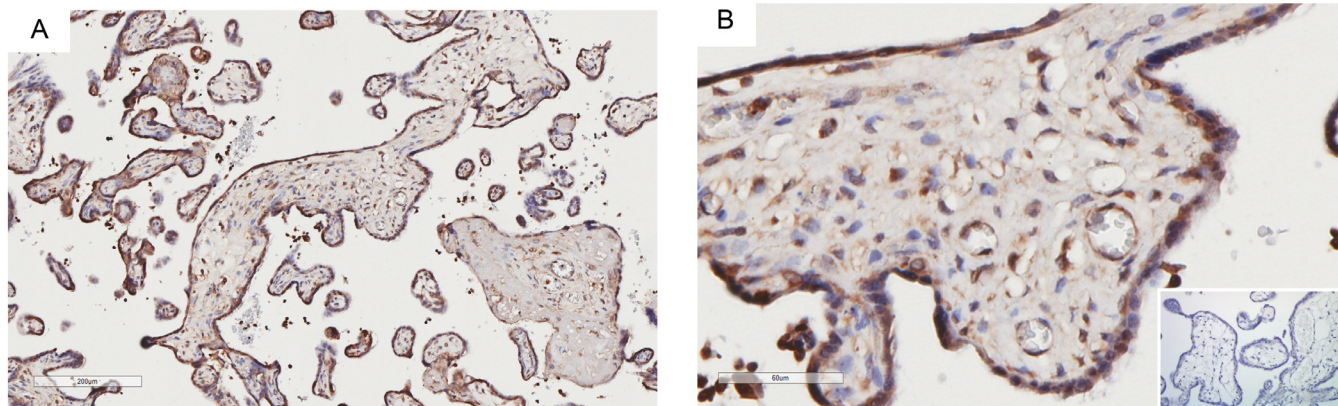
Notably, another report highlighted the contribution of fetal vascular malperfusion as a hallmark of placental histopathologic alterations attributable to SARS-CoV-2 while confirming the presence of decidual inflammation and perivillous fibrin deposition.<sup>7</sup>

Here, we reported a case of stillbirth occurring in the absence of vertical transmission. Virus localization in the endothelial cells of intravillous capillaries was not paralleled by intervillous inflammation or massive syncytiotrophoblast necrosis; however, diffuse thrombosis of fetal intravillous vessels seemed as the hallmark of placenta infection.

In this case, fetal vascular malperfusion was likely associated casually rather than being simply coincident with the infection; in fact, our electron microscopy images showed that the marked SARS-CoV-2 endotheliotropism involved

FIGURE 3

## Immunohistochemical staining on placental tissue with anti-SARS-CoV spike antibody



Villous syncytiotrophoblasts and endothelial cells show positivity to SARS-CoV spike protein (A) (20  $\times$ ); (B) (40  $\times$ ). The insert of (B) shows the control negative of the procedure, a placental tissue from a pregnancy terminated for a congenital cardiac pathology with histologic examination in 2018, before the COVID-19 pandemic (antirabbit polyclonal antibody against SARS-CoV spike S1 subunit protein [Sino Biological, Eschborn, Germany]; catalog number 40150-T62-COV2; incubation at room temperature; antibody dilution 1:200).

di Gioia. Stillbirth and fetal capillary infection by SARS-CoV-2. *Am J Obstet Gynecol MFM* 2021.

the tiny intravillous fetal capillaries, leading to cell dysfunction and procoagulant activity.

Of note, scoring SARS-CoV-2 in the endothelium of villous capillaries indicated that the virus transfer toward the fetal circulation follows a classical transendothelial route and does not involve the Trojan horse mechanism of maternal-fetal cell transfer described for other placentotropic agents.<sup>8</sup>

We confirmed that syncytiotrophoblast is the major target cell type for SARS-CoV-2 infection of the placenta, possibly because of the highly expressed levels of angiotensin-converting enzyme 2.

As syncytiotrophoblast may be crossed by COVID-19 even in the presence of subtle defects, the epidemiologic evidence of a low vertical transmission rate predicts the role of additional local factors, including the still uncertain modulation of Hofbauer cells in either preventing or permitting virus transmission and replication.<sup>9</sup>

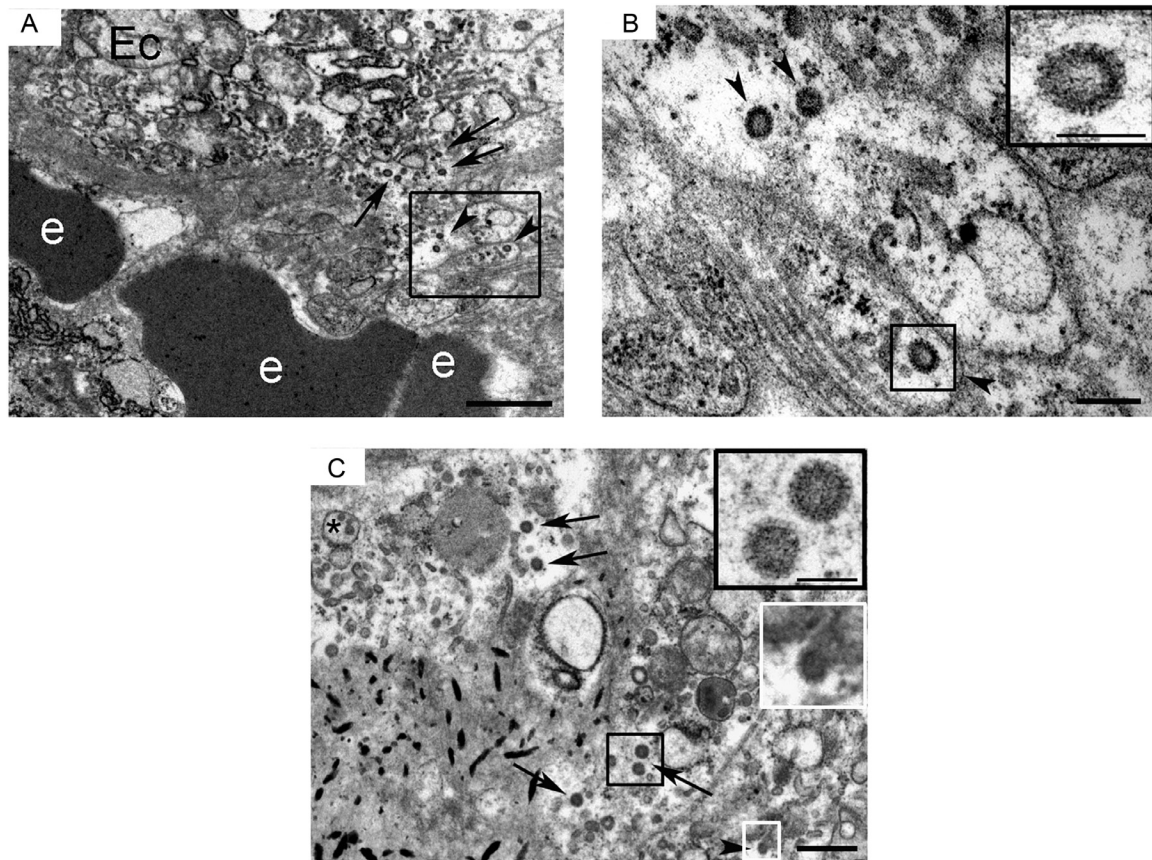
As placental infection does not always correlate with infection of the fetus, it is plausible that a time interval may emerge

between these 2 processes; a stillbirth that occurs in this time frame can be mechanistically explained by an overriding process of severe endothelial dysfunction occurring within intravillous capillaries or massive hypoperfusion of the intervillous space.

However, we cannot disregard that negative evidence of COVID-19 transmission in the setting of an intrauterine fetal demise must be interpreted with caution because of the sensitivity of testing for SARS-CoV-2 in neonatal autopsy specimens.

In conclusion, the possible consequences of the action of the placentotropic SARS-CoV-2 included the occurrence of vertical transmission and/or stillbirth, similar in our case: this latter possibility may be triggered by a hampered maternal and/or fetal perfusion of the placenta. The diffuse thrombosis and subsequent ischemia of fetal capillaries induced by COVID-19 cannot be predicted by standard clinical surveillance or prevented by anticoagulants and represented a severe burden of SARS-CoV-2 infection. ■

**FIGURE 4**  
**Ultrastructural analysis of the placenta from a patient with SARS-CoV-2**



**A**, Virus particles are detected in the cytoplasm of endothelial cells (*arrows*) and cytoplasmic vacuoles (*arrowheads*). The “e” indicates erythrocytes, and the *bar* corresponds to 1  $\mu\text{m}$ . **B**, Higher magnification of the square in **A**: virus particles are indicated by the *arrowheads* (the *bar* corresponds to 200 nm). The insert shows a higher magnification of a virus particle with well-evident spikes on the surface (the *bar* corresponds to 100 nm). **C**, Virus particles are visible close to a damaged endothelial cell (the *bar* corresponds to 600 nm). The *black*-surrounded insert shows a higher magnification of the *black square* in the figure showing 2 virus particles (the *bar* corresponds to 100 nm). The *white*-surrounded insert shows a higher magnification of the *white square* in the figure showing the budding of viral particles from the cell membrane. The *arrows* indicate viral particles, the *arrowhead* indicates a budding viral particle, and the *asterisk* indicates vacuoles containing viral particles.

*di Gioia. Stillbirth and fetal capillary infection by SARS-CoV-2. Am J Obstet Gynecol MFM 2021.*

## REFERENCES

1. Di Mascio D, Khalil A, Saccone G, et al. Outcome of coronavirus spectrum infections (SARS, MERS, COVID-19) during pregnancy: a systematic review and meta-analysis. *Am J Obstet Gynecol MFM* 2020;2:100107.
2. UNICEF. United Nations Inter-Agency Group for child mortality estimation (UN IGME). 2020. Available at: <https://data.unicef.org/resources/a-neglected-tragedy-stillbirth-estimates-report>. Accessed July 29, 2021.
3. Kotlyar AM, Grechukhina O, Chen A, et al. Vertical transmission of coronavirus disease 2019: a systematic review and meta-analysis. *Am J Obstet Gynecol* 2021;224: 35–53.e3.
4. Gurol-Urganci I, Jardine JE, Carroll F, et al. Maternal and perinatal outcomes of pregnant women with SARS-CoV-2 infection at the time of birth in England: national cohort study. *Am J Obstet Gynecol* 2021. [Epub ahead of print].
5. Richtmann R, Torloni MR, Oyamada Otani AR, et al. Fetal deaths in pregnancies with SARS-CoV-2 infection in Brazil: a case series. *Case Rep Womens Health* 2020;27:e00243.
6. Resta L, Vimercati A, Cazzato G, et al. SARS-CoV-2 and placenta: new insights and perspectives. *Viruses* 2021;13:723.
7. Facchetti F, Bugatti M, Drera E, et al. SARS-CoV2 vertical transmission with adverse effects on the newborn revealed through integrated immunohistochemical, electron microscopy and molecular analyses of placenta. *EBioMedicine* 2020;59:102951.
8. Mavilia MG, Wu GY. Mechanisms and prevention of vertical transmission in chronic viral hepatitis. *J Clin Transl Hepatol* 2017;5:119–29.
9. Delorme-Axford E, Sadovsky Y, Coyne CB. The placenta as a barrier to viral infections. *Annu Rev Virol* 2014;1:133–46.