Interdisciplinary Neurosurgery: Advanced Techniques and Case Management 26 (2021) 101318

Contents lists available at ScienceDirect

Interdisciplinary Neurosurgery: Advanced Techniques and Case Management

journal homepage: www.elsevier.com/locate/inat

Management of frontal sinus fractures: A comprehensive review and treatment algorithm from Sapienza university of Rome

Roberto Becelli [a], Mauro Palmieri [b], Valerio Facchini [a,*], Daniele Armocida [b], Alessandro Pesce [c], Aleksandr Kapitonov [a], Marta Zappalà [b], Walter Colangeli [a], Fabrizio Bozza [a], Maurizio Salvati [d], Antonio Santoro [b], Alessandro Frati [b,e]

[a] Maxillofacial Surgery Department, "La Sapienza" University, Azienda Ospedaliera Sant'Andrea, via di Grottarossa 1035/1039, 00189 Rome (RM), Italy
[b] Human Neurosciences Department Neurosurgery Division "La Sapienza" University, Policlinico Umberto I, viale del Policlinico 155, 00161 Rome (RM), Italy
[c] Neurosurgery Department, Ospedale Santa Maria Goretti, via Lucia Scaravelli, 04100 Latina (LT), Italy
[d] Neurosurgery Department, Policlinico Tor Vergata, Viale Oxford, 81, 00133 Roma (RM), Italy
[e] IRCCS "Neuromed", via Atinense 18, 86077 Pozzilli (IS), Italy

ARTICLE INFO

Keywords:
Head trauma
Facial fractures
Frontal sinus fractures

ABSTRACT

Frontal sinus (FS) fractures are uncommon and depending on the impact's force the fracture may involve the anterior table, the adjacent skull, the posterior table and the frontal sinus outflow tract (FSOT). The treatment is based on correcting anti-aesthetic alteration, avoiding the complications, protecting intracranial structures and treating cerebrospinal fluid (CSF) leak. However, the indication and type of treatment of FS fractures is still controversial.

The purpose of this study is to evaluate and to propose a surgical algorithm for FS fractures treatment based on relevant data found in current literature.

A comprehensive Literature review on FS fractures management was performed to define the most used treatment approaches. In this review, we sought in the Medical Literature for patterns that describe injuries of the FS and evaluated the quality of the classification schemes in terms of validity and reliability, severity assessment, treatment guidance and prognosis estimation. We identified 705 articles on the topic and after the screening process, we included 4 documents. In this 4 papers, the four most used classifications in the modern Literature were proposed. Therefore, we analyzed and discussed these main four classifications and, consequentially, we developed an algorithm that represents an attempt to provide a general guideline for the management of FS injuries.

Here an intuitive multidisciplinary algorithm based on both radiological and clinical presentation of the fracture is proposed, trying to guide the surgeon in the correct treatment choice. We believe that a complete classification system must take into account not only the different involvement between anterior and posterior table fractures, but also the involvement of the FSOT and define for each type a therapeutic combined approach between neurosurgeons and maxillofacial surgeons.

1. Introduction

Facial trauma with frontal sinus (FS) fractures represents 15% of traumatic facial injuries [1,2,3]. FSs are located within the frontal bone above the orbits and ahead of the anterior cranial fossa and consist of an anterior and a posterior bony table [4]. FSs are variable in shape and dimension, while 15% of the population presents a single FS, and 5% have sinus aplasia [5].

Abbreviations: CSF, Cerebrospinal Fluid; FS, Frontal sinus; FDA, American Food and Drug Administration; ORIF, open reduction internal fixation; CT, computed tomography scan; FSOT, frontal sinus outflow tract.

* Corresponding author at: via San Godenzo 16, 00189 Rome, Italy.

E-mail addresses: r.becelli@libero.it (R. Becelli), mauro.palmieri10@gmail.com (M. Palmieri), valerio.facchini@uniroma1.it (V. Facchini), danielearmocida@yahoo.it (D. Armocida), ale_pesce83@yahoo.it (A. Pesce), dr.kapitonov.aleksandr@gmail.com (A. Kapitonov), marta.zappala.95@gmail.com (M. Zappalà), walter.colangeli@alice.it (W. Colangeli), fbozza@yahoo.it (F. Bozza), salvatimaurizio1959@gmail.com (M. Salvati), antonio.santoro@uniroma1.it (A. Santoro), alex.frati@gmail.com (A. Frati).

https://doi.org/10.1016/j.inat.2021.101318
Received 5 May 2021; Received in revised form 27 June 2021; Accepted 18 July 2021
Available online 22 July 2021

Frontal cranial bones have greater thickness than other parts of the skull [4]. The anterior table of the sinus is thicker than the posterior one with an average ratio of 2:1, therefore the anterior table is particularly resistant to fractures [6]. As a consequence of this feature, greater kinetic energy is required in order to cause this kind of fractures. Consequentially, they occur less frequently than other forms of skull fractures, and often present with concurrent injuries such as lacerations, abrasions, and other soft tissue injuries which can potentially be very harmful and for which life-saving interventions is required [7]. The presence of frontal bone depression, rhinorrhoea or epistaxis, periorbital edema, ecchymosis, and neurological signs such as diplopia or paresthesia may be FS fracture symptoms [8].

Depending on the impact's force, the fracture may involve the anterior table, the adjacent skull, the posterior table, and the FSOT [9]. Two-third of all FS fractures include both the anterior and posterior tables. Isolated anterior table fractures account for about 25% of cases, whereas 1–7% involve only the posterior one [9].

Even if the posterior table's involvement is uncommon, it is highly associated with severe complications/conditions such as pneumocephalus, CSF leakage, and epidural hematoma [3]. Persistent rhinorrhoea is high suspicious of posterior table fractures with dura mater injury and consequent CSF leakage. FS floor's fractures, anterior ethmoid cells' fractures, and bony obstruction of the FSOT represent nasofrontal duct injury [8]. In these cases, critical evaluation and treatment of these injuries are mandatory.

The surgical treatment of these fractures is based on correcting antiaesthetic alterations, avoiding complications (i.e., frontal sinusitis, mucocele, brain abscess, and meningitis), protecting intracranial structures, and treating CSF leakage [3]. An appropriate classification system that considers the type of fracture, its characteristics, concurrent injuries and the evaluation of different indications for surgical repair is currently missing. According to the most relevant studies, we propose an intuitive algorithm based on the fracture's radiological and clinical presentation, in order to guide the surgeon in the correct treatment choice.

2. Materials and methods

We performed a comprehensive Literature review on FS fractures management to define the most used classification systems. In this review, we sought in the Medical Literature for patterns that describe injuries in the FS and evaluated the quality of the classification schemes in terms of validity and reliability, severity assessment, treatment guidance and prognosis estimation. The research was conducted without a disposable review protocol for this topic.

2.1. Eligibility criteria

The current Literature was investigated using MEDLINE, the NIH Library, PubMed, and Google Scholar. The last search date was March 15, 2021. Search terms included: "frontal sinus fracture" or "frontal sinus injury" in combination with "management" or "treatment." Simultaneously, we performed an investigation with terms that included "frontal sinus" combined with the term "classification". Selection of abstracts were limited to human studies and English language, we also excluded papers published before 1978, since surgical techniques and diagnostic methods before the aforementioned year are considered obsolete. Backward citation tracking was applied to identify articles not retrieved by electronic searches. Therefore, additional relevant articles were extracted from the references of the initial full texts. Duplicate studies were eliminated.

From potentially relevant abstract obtained we applied the following exclusion criteria:

- We excluded report of single case and case series, and commentaries;
- Papers addressed to other pathologies or topic;
- Papers that not mentioned surgical management;
- Papers that analysed reported iatrogenic FS fractures;
- Studies who apply algorithms proposed by other authors

The full text of the remaining articles was then studied to gather all classifications and injury schemes that described the FS injuries and further summaries, or duplicated papers were excluded. No statistical tests of any kind were performed in the current study.

2.2. Informations source and study selection

The aforementioned exclusion criteria were applied to this initial cohort, obtaining 4 papers reporting statistically relevant results.

From many classification systems reported, the most used and widely accepted are four: Metzinger [10], Gonty [11], Torre [12], and Lofgren [7]. Based on this research and our experience, we propose and discuss our classification system; data are reassumed in Table 1. This table showed all the included studies, their key characteristics and also the key characteristics of our algorithm scheme.

3. Results

Two independent authors selected abstracts for the literature review based on predefined inclusion and exclusion criteria, reported below. Studies were eligible if they reported original data on the diagnosis and surgical treatment of any lesions involving the frontal sinus. The first review returned 705 papers.

Studies were excluded, at first, if they had no available abstracts for selection (123 papers excluded) and paper written in other language besides English (13 papers excluded), we also excluded case reports or case series (185 papers excluded), commentaries or review articles summarizing the results of the previous series (90 papers excluded). 21 papers were excluded because published before 1978. Moreover, we excluded abstract that addressed other disease entities or treatment options (201 papers excluded). Papers that did not mention any surgical management (13 papers) regarding iatrogenic fractures or secondary diseases (4 papers) were excluded as well. We excluded articles that were summaries of other articles (7 papers). Finally, we excluded articles in which were used treatment algorithm proposed by other authors (44).

Each Author reviewed the abstracts independently and generated a list of studies to retrieve in order to perform full-text review. When the research was completed 4 full articles were evaluated (Table 2).

Our comprehensive review of the current Literature highlighted several validated classification systems. The widely accepted classification systems of these fractures are essentially four: one proposed by Metzinger et al. [10] for its simplicity and intuitiveness; the classification used by Gonty et al. [11] is certainly one of the most used classifications for its high descriptive capacity [13], in fact is widely used in clinical practice; the classification described by Torre et al. [12], present a classification and treatment scheme based on maximal measured dislocation and involvement of surrounding structures (nasolacrimal system, orbit and CSF leak) and classifies fracture patterns into four descriptive types without suggestions for evaluation and treatment [12]; Lofgren et al., in their classification [7], suggest the first step for the treatment of different types of fractures. Here, the procedure of FS obliteration with cranialization is generally indicated in patients who have comminuted anterior table fractures with a linear fracture of the posterior table without bony displacement or involvement of the FSOT. Another indication is a significant mucosal disruption of the sinus or severely comminuted fractures of the anterior table. These conditions entail removing all sinus mucosa, occlusion of the FSOT, and filling of the sinus cavity with bone grafts or other materials [7].

The classifications proposed by Metzinger et al. [10] and Gonty et. al. [11] are descriptive and capable of summarizing the main radiological characteristics of the fractures, useful for the surgeon in order to choose

Table 1
Classification systems: in table 1 we summarize the characteristics of the various recognized and used treatment schemes, including in the last column the characteristics of the algorithm proposed in this article.

Metzinger et al [10]	Gonty et al [11]	Torre et al [13]	Logfren et al. [7]	Present study
1. Open/Closed fractures 2. Linear/Comminuted fractures 3. Displaced/ Nondisplaced 4. Anterior/Posterior Wall/Anterior and posterior walls 5. With/Without nasofrontal ostia involvement 6. With/Without central nervous system involvement	Type 1 Anterior table fractures a. Isolated to anterior table b. Accompanied by supraorbital rim fractures c. Accompanied by nasoethmoidal complex fractures Type 2 Anterior and posterior table fractures a. Linear fractures 1. Transverse 2. Vertical Comminuted fractures 1. Involving both tables 2. Accompanied by nasoethmoidal complex fractures Posterior table fracture Type 3 Posterior table fracture Type 4 Through and through frontal sinus fracture	Type A: No displacement: Observation Type B: 0 to 2 mm displacement No concomitant injury: observation Concomitant injury: surgical repair Type C: 2 to 5 mm displacement No concomitant injury: observation Concomitant injury: surgical repair Type D: greater than 5 mm displacement: Surgical repair	1. Minimally displaced anterior table fractures (<1–2 mm), without nasofrontal recess injury: Observation with Close Follow-Up 2. Fractures of the anterior table (>2 mm) without the involvement of the nasofrontal recess or in patients with an obvious cosmetic forehead deformity: ORIF 3. Comminuted anterior table fractures with a linear nondisplaced posterior table fracture or involvement with the frontonasal duct. Significant mucosal disruption of the sinus or severely comminuted fracture of the anterior table: Frontal Sinus Obliteration/Ablation 4. Posterior table fractures with significant displacement or comminution, intracranial injury, or CSF leak: Cranialization	1. Anterior table fractures a. Without both nasal frontal recess involvement and anterior table displacement/comminution: observation b. Without nasal frontal recess involvement but with none/mild anterior table displacement/comminution: ORIF c. Without nasal frontal recess involvement but with moderate/severe anterior table displacement/ comminution: obliteration d. With nasal frontal recess involvement: obliteration 2. Posterior table fractures a. Without nasal frontal recess involvement, posterior table displacement and CSF leak: observation b. Without nasal frontal recess involvement and posterior table displacement but with CSF leak: obliteration/cranialization c. Without nasal frontal recess involvement and CSF leak, but with posterior table mild comminution: obliteration/cranialization d. Without nasal frontal recess involvement and CSF leak, but with posterior table severe comminution: cranialization. e. Without nasal frontal recess involvement but with CSF leak: cranialization f. With nasal frontal recess involvement: cranialization/obliteration

the most appropriate treatment option, but they take in minor consideration the clinical and diagnostic aspects of the fractures, especially in the case of a CSF leakage. Torre's classification has the advantage of being easily descriptive by focusing on the extent of displacement. There are also classifications that do not give any indications deriving from the simultaneous involvement of the anterior and the posterior walls, which instead represents the main criterion in Gonty's classification, also offering a topographical criterion on the portions of bone involved. Lofgren et al. introduce the presence of CSF leakage and intracranial injury by including them within type 4 fractures for the classifications regarding posterior wall lesions. However, none of these classifications consider, in the same scheme, the topographical description, the presence of CSF fistula, and the therapeutic algorithm.

4. Discussion

The history of FS fractures' surgical treatment started in 1898 when Reidel [14] described the removal of the anterior and posterior table of the FS as a treatment for these kinds of injuries for the first time. This procedure allowed to avoid many complications such as brain infection and mucocele.

This technique's main flaw was the cosmetic deformity due to the collapse of the skin upon the underlying dura. Many surgeons modified this technique to improve the aesthetic results [15,16], but only in the second half of 1900, with the introduction of the sinus's obliteration with autologous fat proposed by Bergara et al. [17,18] the surgical treatment of FS fractures was revolutionized. The anomalous communication between the sinus compartments and the intracranial content and consequent CSF leakage certainly represents one of the most fearful complications that must be readily recognized and treated. FS's obliteration and cranialization are becoming the gold standard for FS fractures with the injury of the FSOT and dura mater [19]. Despite this, the treatment of FS fractures is still controversial. Appropriate classification and indications for surgical repair of FS fractures remain problematic, resulting in various management strategies. Therefore, the difficulty in creating a correct diagnostic and therapeutic algorithm is often determined by the complexity of the sinus system's anatomy, making challenging to identify the actual risk of aesthetic, functional, or infectious damage.

The most important diagnostic test is a non-contrast enhanced computed tomography scan (CT) of the head and facial bones. The axial slices permit the evaluation of the anterior and posterior table, the coronal slices better visualize the sinus floor and the orbital roof, while the sagittal slices are helpful to assess the integrity of the FSOT. Three-dimension reconstructions are useful to show the fracture's entity and its eventual cosmetic impact [20]. Angiography can be considered if the provider is concerned about possible vascular involvement and Ultrasound can detect quickly fractures using the linear probe in a superficial mode; however, no recommendations or guidelines are attesting which diagnostic investigation is prioritary in the management of FS fractures [21,22]. As previously mentioned, classification and treatment guidelines are not universal [2,9,12,15,23], which could account for variations in patient management.

Despite this lack of consensus, a posterior table fracture with displacement greater than 5 mm is generally accepted as an absolute surgical indication. Most procedures should occur within 12 to 48 h from initial presentation barring any other life-threatening injuries [7,24–27]. In our opinion an early and definitive management of FS injuries is recommendable, in order to protect intracranial structures and to avoid further complications due to delayed treatment.

Table 2
Review process: in this table we show the process of selecting articles for review, specifying the reasons for exclusion of the articles.

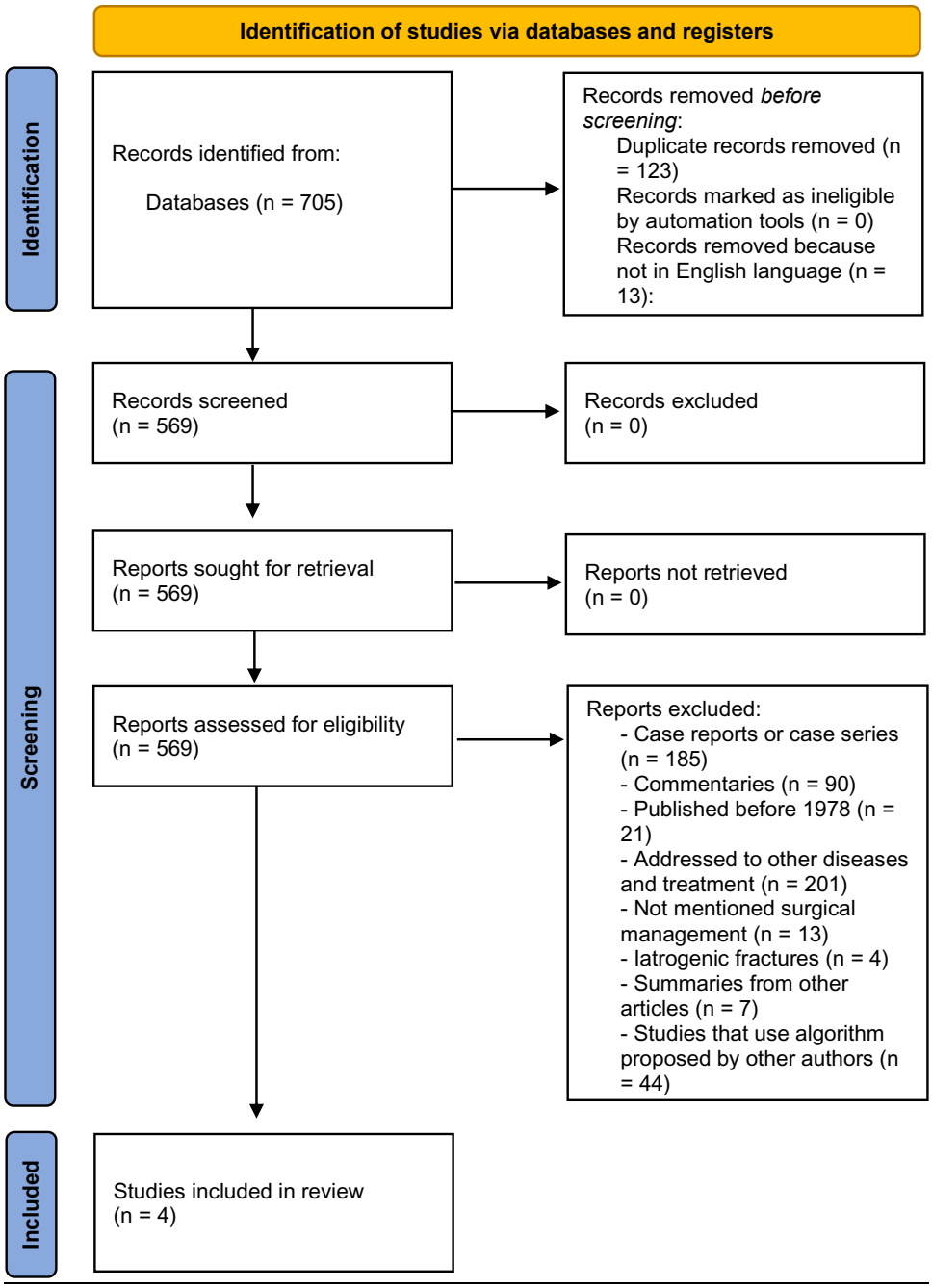

4.1. Our proposal of a classification system and flow chart

In our classification system and treatment flow-chart (showed in Fig. 1) we take into consideration the different approach that should be taken according to whether the anterior wall is involved compared to the posterior wall in first place. Consequentially, we immediately consider the importance of identifying the involvement of the FSOT. This priority is determined by the fact that for FS, FSOT is the main communication link to the middle nasal meatus. The FS drains inferiorly into either the middle meatus or ethmoid infundibulum through the FSOT [23,28]. The relevance of evaluating FSOT involvement in FS injuries is due to the consequential FSOT obstruction [9], which may cause frontal sinusitis or mucocele [29]. The presence of anterior table medial wall or frontal sinus floor fractures are high suggestive of FSOT involvement [9], which patency can be assessed through intraoperative use of Fluorescein or a solution of methylene blue. When the FSOT is involved, obliteration or cranialization of the FS is required, even though stenting procedures with endogenous or exogenous materials may be taken into account [29]. In fact, nowadays, endoscopic techniques allow sinus preservation when possible, avoiding sinus obliteration [30].

Many treatments options were reported in Literature for these fractures [3,31], such as a classical drainage system's reconstruction, FSOT obliteration or stenting, reconstruction with mucosal flaps, and endoscopic reconstruction. Despite that, frontal sinus obliteration is considered the gold-standard for frontal recess injuries for its long-term efficacy. Many materials have been experimented for sinus obliteration, such as autologous fat, muscle and bone, alloplastic bone, cement, and

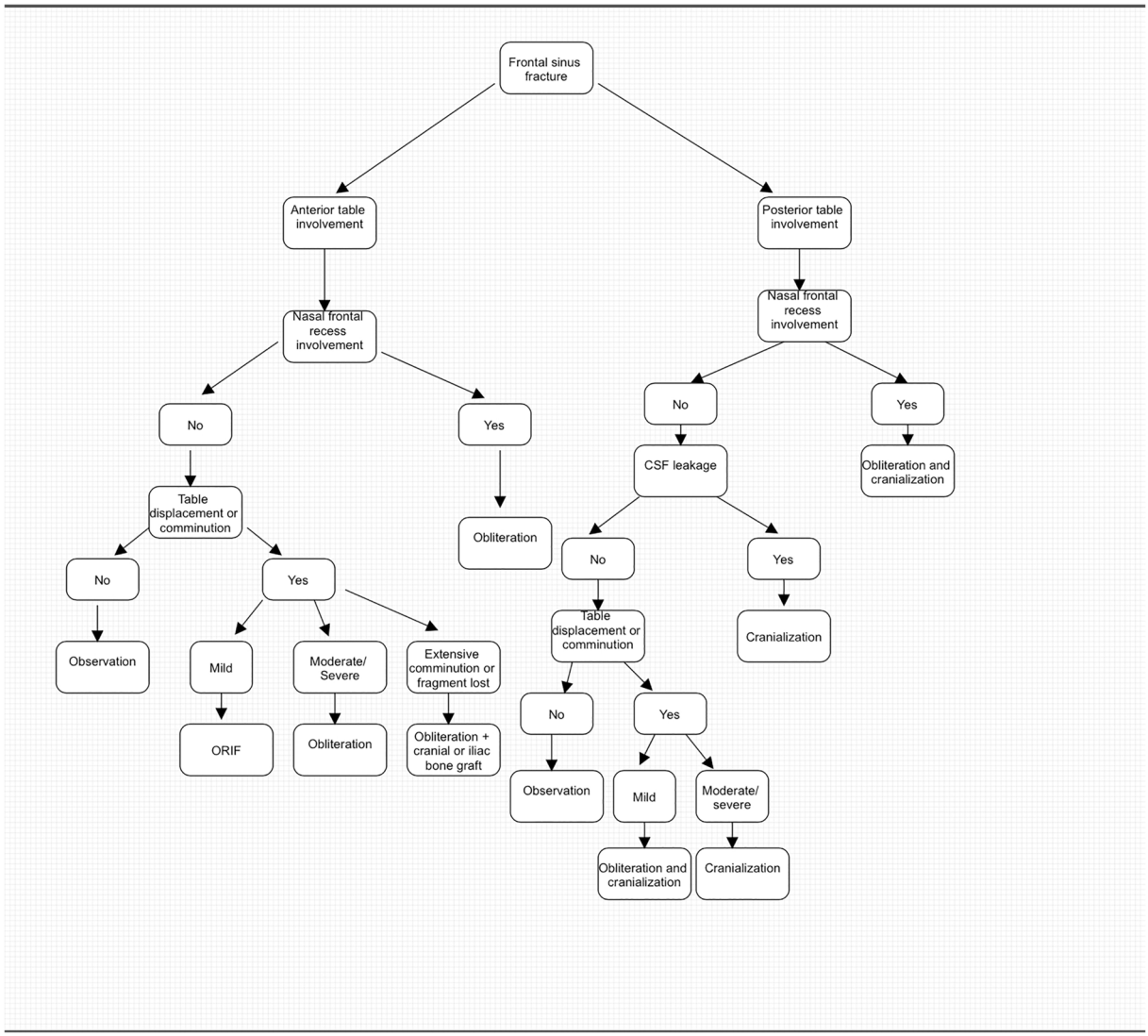

Fig. 1. The flow-chart of our algorithm.

other polymers (i.e., calcium phosphate, hydroxyapatite, and glass ionomer) [8,32]. Considering that neither calcium phosphate nor hydroxyapatite cement is approved by FDA (American Food and Drug Administration) for sinus obliteration with poor long-term outcome and considering the lack of strong evidence about the results of glass ionomer (approved by the FDA), autologous abdominal fat nowadays remains the gold standard for frontal sinus obliteration [32].

First of all, we evaluate which bony wall of the FS is involved, the anterior and/or the posterior one.

Therefore, three main variables were considered for the treatment algorithm: the entity of the table displacement, presence of comminution and CSF leakage.

Regarding the evaluation of the table displacement, according to Torre et al., fractures with 0–2 mm dislocation were classified as minimally displaced, fractures with 2–5 mm as moderate and the ones with more than 5 mm as severe [12].

4.2. Anterior table fractures

Isolated anterior table fractures of the frontal sinus occur in up to nearly 25% of the cases [9]. Generally anterior table fractures minimally or non-displaced without injury of the FSOT do not require surgical treatment, where in almost all cases of these fractures can be monitored with observation and close clinical follow-up. In the case of FS fracture with an overlying laceration (deemed open fracture), it is imperative to administer appropriate antibiotics and tetanus prophylaxis/immunoglobulin [7].

In case of FSOT involvement or moderately and severely comminuted and displaced fractures should be treated with sinus obliteration to avoid mucocele and mucosal entrapment.

Mildly displaced or comminuted fractures may require open reduction and internal fixation (ORIF), in which the main surgical goals are the treatment of the cosmetic deformity and the removal of the entrapped mucosa of the sinus [9,33]. In fractures with extensive comminution or fragments lost, the anterior table could be reconstructed with bone graft (i.e., cranial and iliac bone graft) [33].

If surgery is required, soft tissue lacerations may be used as surgical access point to achieve proper exposure of fracture rim. Surgical intervention with the coronal incision is necessary in the case of severe displacement. Moreover, a coronal incision remains the gold standard allowing perfect visualization of the surgical field with good aesthetic results [3].

4.3. Posterior table fractures

The posterior table fractures are mostly associated with the anterior

table and FSOT fractures. Coronal approach is preferred to treat dural lesion and ease neurosurgical treatment. Coronal approach is also recommended in combined anterior-posterior table fractures [33].

As described for anterior table injuries, non-displaced fractures of the posterior wall may be observed. Cranialization is indicated for posterior table fractures with significant displacement or comminution, intracranial injury, or CSF leakage [9,34]. It involves removing the entire frontal sinus contents, including the mucosa, bone fragmentation, and the frontal sinus's posterior table. Any anterior table defects must be reconstructed to protect further the brain and dura that have herniated into the FS.

According to Rohrich and Hollier [19], in the posterior table's displacement of more than one table width, many treatment options should be considered, such as sinus exploration, dura repair, and sinus obliteration or cranialization.

Mildly comminuted fractures require sinus obliteration, while for severely comminuted ones, cranialization is the best option. Also, Dalla Torre et al. [12] reported a high incidence of CSF leakage in the displacement greater than 5 mm; in these cases, cranialization is strongly recommended.

4.4. Limitations of the study

The main methodological limitation of the current purpose is that our FS injury classification preference is directly deduced from our experience without a structured study in which this new classification system is applied. Furthermore, the present Literature review lacks statistical validation through proper analysis and was limited to the English language. There could exist FS injury classifications in other languages as well, that might be potentially very useful. Moreover, there could exist FS injury classifications that are not popular, but still be potentially very useful in clinical practice.

5. Conclusions

Nowadays, there is no universally accepted algorithm to manage FS fractures. We found that most of the proposed classifications independently affected fractures of maxillofacial competence, with prevalent involvement of the anterior wall of the FS, and fractures of neurosurgical competence, with prevalent involvement of the posterior wall, completely lacks a unique diagnostic and therapeutic flow-chart. The present algorithm represents an attempt to provide a general and intuitive guideline for the multidisciplinary management of FS injuries and it might represent an effective starting point for further studies.

6. Statements

This article has not been presented elsewhere and it is not under consideration from other journals.

This research did not receive any specific grant from funding agency in the public, commercial, or not-for-profit sectors.

We confirm that the manuscript has been read and approved by all named authors and that there are no other persons who satisfied the criteria for authorship but are not listed. We further confirm that the order of authors listed in the manuscript has been approved by all of us.

We confirm that we have given due consideration to the protection of intellectual property associated with this work and that there are no impediments to publication, including the timing of publication, with respect to intellectual property. In so doing we confirm that we have followed the regulations of our institutions concerning intellectual property.

We understand that the Corresponding Author is the sole contact for the Editorial process (including Editorial Manager and direct communications with the office). He/she is responsible for communicating with the other authors about progress, submissions of revisions and final approval of proofs. We confirm that we have provided a current, correct email address which is accessible by the Corresponding Author and which has been configured to accept email.

Declaration of Competing Interest

The authors declare that they have no known competing financial interests or personal relationships that could have appeared to influence the work reported in this paper.

References

[1] S. Manolidis, L.H. Hollier, Management of frontal sinus fractures, Plast Reconstr Surg. 120 (Supplement 2) (2007) 32S–48S.
[2] C. Xie, N. Mehendale, D. Barrett, C.J. Bui, S.E. Metzinger, 30-year retrospective review of frontal sinus fractures: The Charity Hospital experience, J Craniomaxillofac Trauma 6 (1) (2000) 7–18.
[3] Bernal-Sprekelsen M.; Stilianos E.; Kountakis Metin Önerci (eds). Rhinologic and sleep apnea surgical techniques. Eur Arch Otorhinolaryngol 265, 855–856, 2008.
[4] H.H. De Boer, A.E. Van der Merwe, V.V. Soerdjbalie-Maikoe, Human cranial vault thickness in a contemporary sample of 1097 autopsy cases: relation to body weight, stature, age, sex and ancestry, Int. J. Legal Med. 130 (5) (2016) 1371–1377.
[5] L. Bernstein, The Caldwell-Luc operation, Otolaryngol Clin North Am. 4 (1) (1971) 69–77.
[6] A.M. Nahum, The biomechanics of maxillofacial trauma, Clin Plast Surg. 2 (1) (1975) 59–64.
[7] D.H. Lofgren, D. McGuire, A. Gotlib, Frontal Sinus Fractures. StatPearls. Treasure Island (FL), StatPearls Publishing, 2020.
[8] Eledeissi A.; Ahmed M.; Helmy E. Frontal Sinus Obliteration Utilizing Autogenous Abdominal Fat Graft. Open Access Maced J Med Sci. 2018;6(8):1462-1467. Published 2018 Jul 21.
[9] Arnold MA.; Tatum SA.; 3rd. Frontal Sinus Fractures: Evolving Clinical Considerations and Surgical Approaches. Craniomaxillofac Trauma Reconstr. 2019, 12(2):85-94.
[10] S.E. Metzinger, A.B. Guerra, R.E. Garcia, Frontal sinus fractures: management guidelines, Facial Plast Surg. 21 (3) (2005) 199–206.
[11] A.A. Gonty, R.D. Marciani, D.C. Adornato, Management of frontal sinus fractures: a review of 33 cases, J. Oral Maxillofac. Surg. 57 (4) (1999) 372–379.
[12] D. Dalla Torre, D. Burtscher, A. Kloss-Brandstätter, M. Rasse, F. Kloss, Management of frontal sinus fractures–treatment decision based on metric dislocation extent, J Craniomaxillofac Surg. 42 (7) (2014) 1515–1519.
[13] Gerbino G.; Roccia F.; Benech A.; Caldarelli C.; Analysis of 158 frontal sinus fractures: current surgical management and complications. J Craniomaxillofac Surg, 2000, Jun;28(3):133-9.
[14] Reidel R.; Schenke. Inaug dissertation. Jena, 1898.
[15] G. Killian, Die Killianische Radicaloperation chronischer stirnhohleneiterungen: II. Weiteres kasuistisches material und zusammenfassung, Arch Laryngol Rhinol 13 (1904) 59.
[16] R.C. Lynch, The technique of a radical frontal sinus operation which has given me the best results. (original communications are received with the understanding) that they are contributed exclusively to the laryngoscope.), The Laryngoscope 31 (1) (1921) 1???5, https://doi.org/10.1288/00005537-192101000-00001.
[17] A. Bergara, Itioz O; Experimental study of the behavior of adipose tissue within the frontal sinus of the dog, Argent Rev Otorhinolaryngol 184 (1951) 184.
[18] A.R. Bergara, A.O. Itoiz, Present state of the surgical treatment of chronic frontal sinusitis, Arch Otolaryngol 61 (6) (1955) 616–628.
[19] R.J. Rohrich, L.H. Hollier, Management of frontal sinus fractures, Changing concepts. Clin Plast Surg. 19 (1) (1992) 219–232.
[20] E.B. Strong, Frontal sinus fractures: current concepts, Craniomaxillofac Trauma Reconstr. 2 (3-4) (2009) 161–175.
[21] McRae M.; Momeni R.; Narayan D. Frontal sinus fractures: a review of trends, diagnosis, treatment, and outcomes at a level 1 trauma center in Connecticut. Conn Med. 2008 Mar;72(3):133-8.
[22] S.E. Metzinger, R.C. Metzinger, Complications of frontal sinus fractures, Craniomaxillofac Trauma Reconstr. 2 (1) (2009) 27–34.
[23] J.B. Anon, M. Rontal, S.J. Zinreich, et al., Anatomy of the Paranasal Sinuses, Thieme Medical Publishers, New York, 1996, pp. 22–24.
[24] Jin HR.; Shim WS.; Jung HJ. Minimally Invasive Technique to Reduce the Isolated Anterior Wall Fracture of the Frontal Sinus. J Craniofac Surg., 2019, Nov-Dec; 30 (8):2375-2377.
[25] P. Jeyaraj, Frontal Bone Fractures and Frontal Sinus Injuries: Treatment Paradigms, Ann Maxillofac Surg. 9 (2) (2019) 261, https://doi.org/10.4103/ams.ams_151_19.
[26] A. Vincent, W. Wang, T. Shokri, E. Gordon, J.C. Inman, Y. Ducic, Management of Frontal Sinus Fractures, Facial Plast Surg. 35 (06) (2019) 645–650.
[27] R.A. Pollock, J.L. Hill, D.L. Davenport, D.C. Snow, H.C. Vasconez, Cranialization in a cohort of 154 consecutive patients with frontal sinus fractures (1987–2007): review and update of a compelling procedure in the selected patient, Ann Plast Surg. 71 (1) (2013 Jul) 54–59.
[28] H.R. Stammberger, D.W. Kennedy, The Anatomic Terminology Group Paranasal sinuses: anatomic terminology and nomenclature, Ann Otol Rhinol Laryngol Suppl. 104 (10_suppl) (1995) 7–16.
[29] Y.H. Kim, B.K. Kim, Approach to Frontal Sinus Outflow Tract Injury, Arch Craniofac Surg. 18 (1) (2017) 1–4, https://doi.org/10.7181/acfs.2017.18.1.1.

[30] M. Elkahwagi, A. Eldegwi, What Is the Role of the Endoscope in the Sinus Preservation Management of Frontal Sinus Fractures? J Oral Maxillofac Surg. 78 (10) (2020) 1811.e1–1811.e9, https://doi.org/10.1016/j.joms.2020.04.025.
[31] J.W. Grayson, H. Jeyarajan, E.A. Illing, D.-Y. Cho, K.O. Riley, B.A. Woodworth, Changing the surgical dogma in frontal sinus trauma: transnasal endoscopic repair, Int Forum Allergy Rhinol. 7 (5) (2017) 441–449.
[32] R.B. Bell, E.J. Dierks, P. Brar, J.K. Potter, B.E. Potter, A protocol for the management of frontal sinus fractures emphasizing sinus preservation, J Oral Maxillofac Surg. 65 (5) (2007) 825–839.
[33] L. Doonquah, P. Brown, W. Mullings, Management of frontal sinus fractures, Oral Maxillofac Surg Clin North Am. 24 (2) (2012) 265–ix, https://doi.org/10.1016/j.coms.2012.01.008.
[34] J.L. Freeman, K.R. Winston, Breach of Posterior Wall of Frontal Sinus: Management with Preservation of the Sinus, World Neurosurg. 83 (6) (2015) 1080–1089, https://doi.org/10.1016/j.wneu.2014.12.023.