Research article

Clin Ter 2021; 172 (4):347-357 doi: 10.7417/CT.2021.2339

Early identification of keratoconus using pachymetric indexes obtained with spectral domain optical coherence tomography

L. Scuderi[1,*], G. Anselmi[2,*], A. Greco[2], B. Abdolrahimzadeh[3], M. C. Costa[4], G. Scuderi[2]

[1]*Ophthalmology Unit, Department of Sense Organs, Policlinico Umberto I, Rome, Italy;* [2]*Ophthalmology Unit, NESMOS Department, Sant'Andrea Hospital, Faculty of Medicine and Psychology "Sapienza" University of Rome, Rome, Italy,* [3]*Northwest PPG Ophthalmology NHS, Rochdale, Manchester, UK;* [4] *Vito Fazzi Hospital, Lecce, Italy*

**The first two authors contributed equally*

Abstract

Purpose. To evaluate the diagnostic ability of pachymetric indexes obtained with Spectral Domain Optical Coherence Tomography (SD-OCT) for early detection of keratoconus (Kc).

Methods. 64 patients with Kc in at least one eye (95 eyes, 46 men and 18 women, average age 27.84 ±13.50), 59 healthy control subjects (100 eyes, 28 men and 31 women, average age 27.15 ±16.14). All patients underwent detailed clinical examination, topography and anterior segment OCT. 37 subjects (37 eyes, 27 men and 10 women, average age 24.23 ± 14.24) having one eye with manifest Kc and the fellow eye without clinical signs of Kc were identified. We studied two groups of pachymetric indexes: C_1-C_2, M_1-M_2, $_p$CLMI, P_{min}-P_2 (Group 1 indexes) and PPD, PSD, PSSD and PASD (Group 2 indexes). A ROC (Receiver Operating Characteristic) curve was developed to compare the diagnostic accuracy, relative sensitivity and specificity for each index.

Results. In manifest keratoconus, C_1-C_2, M_1-M_2, and *p*CLMI are significantly higher compared to the control group ($P<0.0001$); for suspect keratoconus, all Group 1 indexes are significantly higher compared to healthy subjects ($P<0.0001$) excluding M_1-M_2 obtained using a constant area circle ($P = 0.02$). Furthermore, for manifest and suspect keratoconus, PPD, PSD, PSSD and PASD are significantly higher compared to the control group ($P <0.0001$).

Conclusion. The studied pachymetric indexes in patients with Kc have high diagnostic accuracy and are statistically significant when compared with healthy subjects ($p<0.0001$) and can provide a useful tool for keratoconus screening. ***Clin Ter 2021; 172 (4):347-357. doi: 10.7417/CT.2021.2339***

Key words: *keratoconus, cornea, SD-OCT, corneal crosslinking, PRK, pachymetry*

Introduction

Keratoconus (Kc) is a condition where the cornea becomes thin and develops a cone like bulge (1-3,5,7). Prevalence of this corneal degeneration is variable: many studies suggest a value between 50 to 230 per 10000 cases due to variability of diagnostic criteria (4,6). Corneal topography, slit-lamp biomicroscopy, retinoscopy and keratometry are the most common exams used in the diagnosis of Kc (1,2). Nevertheless, early detection of Kc remains a clinical challenge. Considering the unpredictable nature of this pathology it is also crucial to screen candidates for Kc when considering a refractive laser procedure (7,8). In fact, some authors suggest that 2.6% of patients presenting for a refractive surgery assessment have a suspect form of keratoconus (7,8). Several parameters and topographic indexes are available for the study of corneal shape changes and to assess the risk of Kc. Keratoconus Prediction Index (KPI) and Cone Location Magnitude Index (CLMI) are the most complex corneal topographic systems that can detect the presence or absence of a keratoconus pattern in anterior corneal topography maps (9-11). In addition to the topographic exam, anterior segment optical coherence topography (OCT) may be useful to determine pachymetric maps of the central cornea (12). The aim of this study is to evaluate the diagnostic accuracy of pachymetric indexes for anterior segment OCT to detect Kc.

Materials and Methods

64 patients with Kc in at least one eye (95 eyes, 46 men and 18 women, average age 27.84 ±13.50) and 59 healthy control subjects (100 eyes, 28 men and 31 women, average age 27.15 ±16.14) were recruited in the Ophthalmology Department at Sant' Andrea Hospital, University of Rome. All subjects provided written informed consent. The study followed the tenets of the Declaration of Helsinki and was approved by ethics committee of our institute. All patients

Correspondence: Luca Scuderi, email: lucascuderi@hotmail.com

ISSN 1972-6007

were evaluated after at least 10 days of soft contact lenses usage suspension and 1 month suspension for semi-rigid lenses. Subjects enrolled in the present study underwent corneal topography and anterior segment OCT alongside a detailed ophthalmic examination including assessment of visual acuity, refraction, biomicroscopy, applanation tonometry and fundus examination. The diagnosis of Kc was made according to corneal topography (Keratron, Opticon- Rome), and presence of any of the following clinical signs was documentated: Fleischer's ring, Rizzuti's sign, Munson's sign, stromal thinning or "scissor reflex" (1,6). Patients with corneal opacity, other corneal disease, or previous surgical treatment were excluded. 41 of keratoconus patients had allergic/vernal conjunctivitis, 2 strabismus, 2 glaucoma, 1 arcus juvenilis, and 1 Fuchs' dystrophy (Table 1).

Table 1. Ocular disease associated with Kc in our patients.

Ocular disease associated	Cases	%
Allergic / Vernal conjunctivitis	41	61.19
Strabismus	2	2.98
Glaucoma	2	2.98
Fuchs' corneal dystrophy	1	1.49
Arcus juvenilis	1	1.49

Topographic examination was performed in all subjects by acquiring three images for each eye. A central area with diameter of 12 mm was evaluated to obtain axial, tangential and altitudinal maps. We used the CLMI index to calculate and determine keratoconus probability. We identified 37 subjects (37 eyes, 27 men and 10 women, average age 24.23 ± 14.24) with one eye with manifest Kc and the fellow eye without clinical signs of Kc (no slit lamp findings, no scissoring on retinoscopy and asymmetric bowtie/skewed radial axes pattern on videokeratography) and with normal topographic map or with a suspect Kc according to CLMI staging system and Krumeich classification (maximum curvature < 48, myopia and astigmatism <5D, minimum corneal pachymetry > 500 µm) (11,13). All patients of this group had a visual acuity of 20/20. In cases where there was a suspect keratoconus, the ectasic area was not in the optic zone.

A pachymetric map was obtained using the Fourier-domain OCT system (RTVue, Optovue, Inc.) with a corneal adaptor module. During the exam the patient fixed on a blue pointer on the center of the lens. According to previous studies, the corneal map was considered properly centered when artifact vertical lines appear in all scans (12). The instrument measures the 6 central corneal millimeters on 8 meridians. Pachymetric maps were obtained three times for each eye. Artifacts resulting from eyes or eyelid movements were considered exclusion criteria.

For each OCT pachymetry a XML file was obtained. We used a software (Ragonesi L.) that recreated the pachymetric map from the XML file and measured the pachymetric values in different points. The values obtained with Ragonesi's software and RTVue software were the same.

A first group (Group 1) of pachymetric indexes was developed. Similarly to CLMI, we localized the point with the lowest thickness (P_{min}) and we calculated the corneal thickness average of the points placed in 1 millimeter diameter circles (C_1) with center in P_{min}. In addition, we calculated the same values for the points located in the diametrically opposite circle (C_2) to the first one (Fig.1). 1 mm radius was deliberately chosen instead of 2 mm as in CLMI, because the analyzed area diameter is half compared to the area analyzed with the topography and because a larger area could include pachymetric map points with a similar thickness to normal values, resulting in a lower diagnostic capability.

We set the following indexes:

- **C_1-C_2**;
- **M_1-M_2**: similarly to CLMI, M_1 and M_2 indicate the difference between pachymetric values average for the points outside and inside respectively of the circles C_1 and C_2;
- ***p*CLMI**: at first we found P_{min} (the point with the lowest pachymetry), then we assessed the average pachymetric values for all points inside a 1 mm diameter circle (C_1) with the center P_{min}; we detected the diametrically opposite point to P_{min} (P_2) and the same was assessed for the pachymetric average in a 1 mm diameter circle (C_2) with P_2 as center. We identified M_1, defined as the average of the pachymetric values for all external points to C_1 minus the average of the points inside C1. We identified M_2, defined as the average of the pachymetric values of all external points to C_2 minus the average of the points inside C_2; if the distance of P_{min} from the center of the map is more than 1 mm, then *p*CLMI = M_1-M_2; otherwise it would be calculated as M_1-(3rM_2), where r is the distance of P_{min} from the center of the map;
- **P_{min}-P_2:** P_{min} pachymetric value minus P_2 pachymetric value (P_2 is the point diametrically opposite to P_{min}).

C_1-C_2, M_1-M_2 and *p*CLMI were assessed for circle and ellipsoid shaped patterns, at variable distances from the centre of the map (Fig. 2).

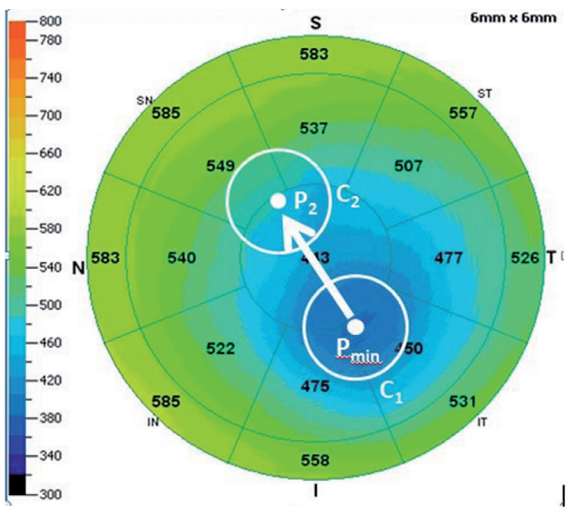

Fig. 1. 1mm circle construction around P_{min} (C_1) and the diametrically opposite circle around P_2 (C_2).

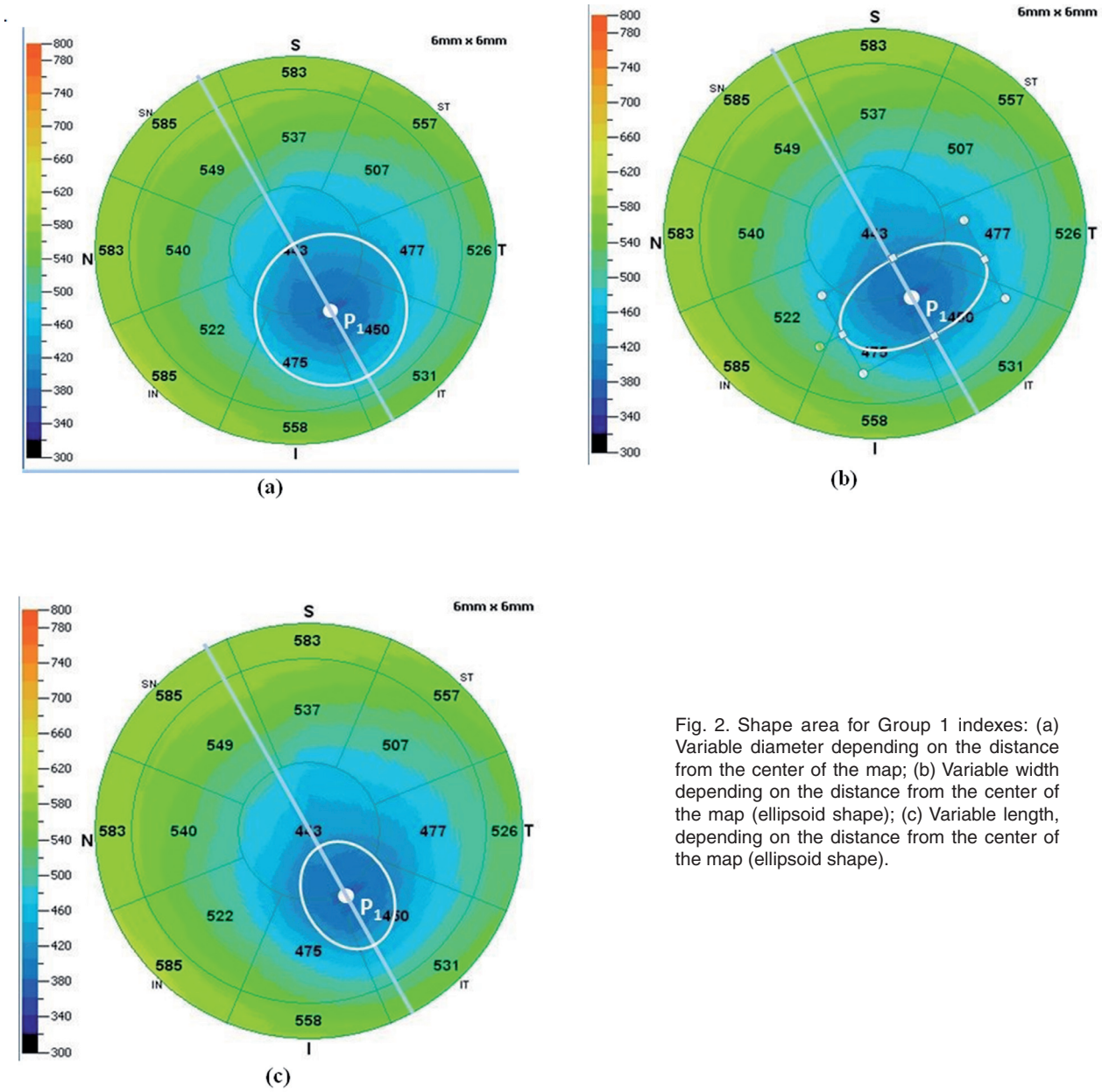

Fig. 2. Shape area for Group 1 indexes: (a) Variable diameter depending on the distance from the center of the map; (b) Variable width depending on the distance from the center of the map (ellipsoid shape); (c) Variable length, depending on the distance from the center of the map (ellipsoid shape).

We developed a second group of indexes (Group 2) inspired to the KPI system, particularly to "IAI" (Irregular Astigmatism Index) (Fig. 3):

- **PPD**: we assessed the average of the pachymetric values for the diametrically opposite points placed on the 8 diameters, measured by OCT, at 1 mm from the center of the map (Fig. 3a).
- **PSD**: at first, we calculated the pachymetric values average for each point of a 1 mm segment placed on each of 8 map diameters, measured by OCT, and with midpoint at 1 mm from the center; then, we assessed the average of the difference for each diametrically opposite segments couple values; this average is the PSD index (Fig. 3b).
- **PSSD**: we found the point with the lowest pachymetric value (P_{min}); we considered this point as the mean point of a 1 mm segment placed on the map diameter; We identified the symmetric segment on the map; we found a diametrically opposite segment and we calculated the pachymetric values average for every point for each of those segments; PSSD is the difference between those averages (Fig. 3c).
- **PASD**: we identified, as for PSSD, the segments for each of the eight diameters, but we considered also other 0,5 mm segments placed on consecutive diameters to those previously used and with middle points at the same Pmin distance from the center; the pachymetric values averages were assessed considering all three segments; then we calculated the same average for diametrically opposite segments; PASD is the difference between those averages (Fig. 3d).

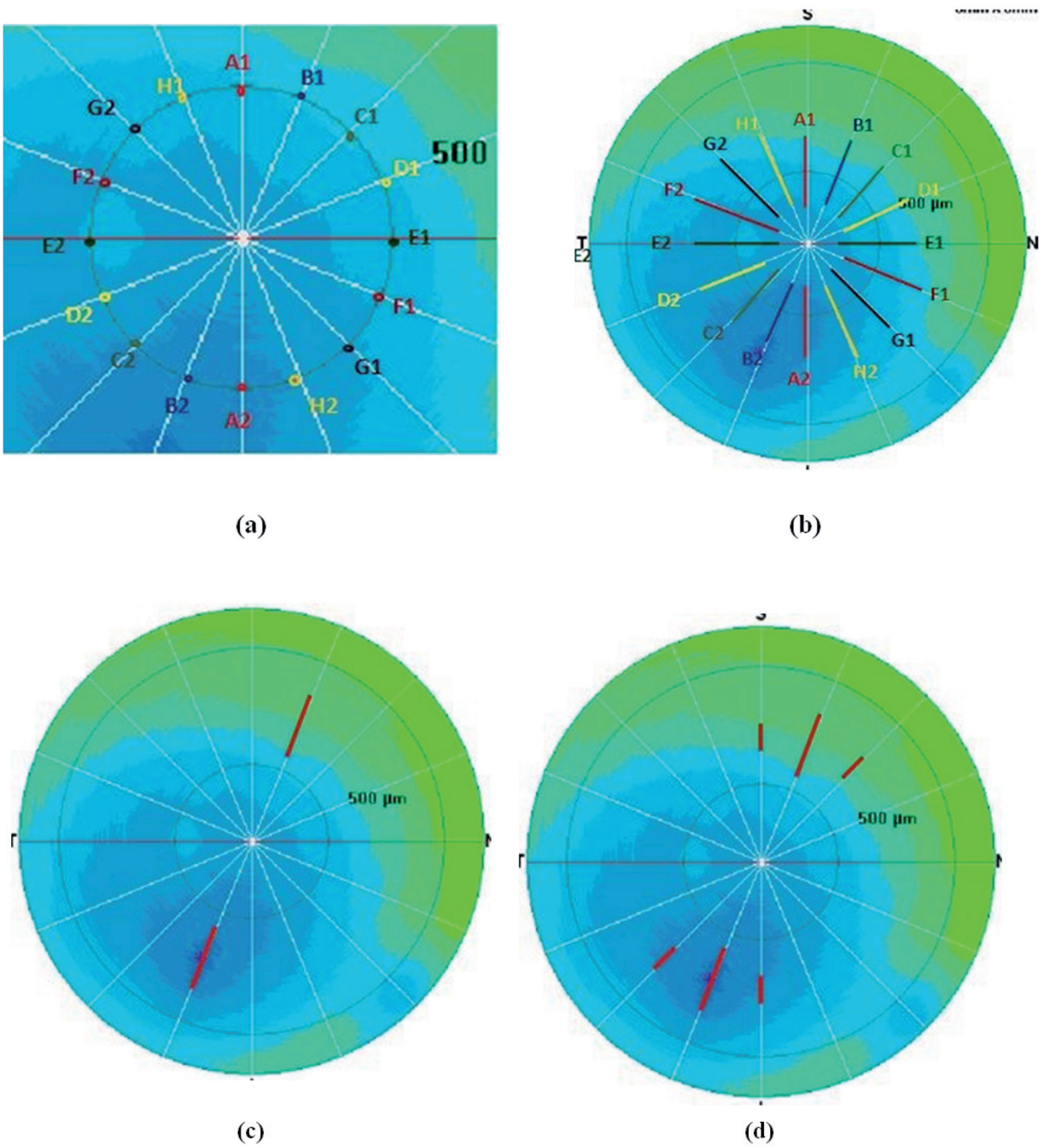

Fig. 3. Group 2 indexes: (a) PPD: A1-A2, B1-B2, C1-C2, D1-D2, E1-E2, F1-F2, G1-G2, H1-H2; (b) PSD: A1-A2, B1-B2, C1-C2, D1-D2, E1-E2, F1-F2, G1-G2; (c) PSSD; (d) (PASD).

For statistical analysis a ROC curve (Receiver Operating Characteristic) was developed to compare the diagnostic accuracy for each index (expressed as AROC, Area under Receiver Operating characteristic Curve) and the relative sensitivity and specificity using Origin Lab Pro 8 and STATA software.

Results

The CLMI topographic index values were 0.75 ± 0.53 for the control group, 9.38 ± 5.2 for the manifest keratoconus and 1.72 ± 1.05 for suspect keratoconus groups. According to a recent study, the best accuracy (92%), sensitivity (89%) and specificity (94%) of CLMI is obtainable through setting the cut-off at 1.82. The average values for each index are reported in Table 2 and Table 3.

Table 2. Group 1 index values obtained for manifest Kc, suspect Kc and healthy subjects.

	Constant Area Circle				Variable Area Based on Distance from the Center Circle		
	C_1-C_2	M_1-M_2	pCLMI		C_1-C_2	M_1-M_2	pCLMI
Manifest KC	15.40 ± 11.44	213.00 ± 86.80	356.23 ± 169.82		43.85 ± 31.82	44.51 ± 73.74	90.39 ± 32.50
Suspect KC	5.98 ± 3.04	248.45 ± 73.70	142.98 ± 136.90		15.91 ± 7.59	15.91 ± 7.71	85.01 ± 66.10
Control group	2.08 ± 1.62	116.97 ± 50.40	153.89 ± 87.29		6.45 ± 4.79	40.94 ± 40.86	6.51 ± 4.85
	Variable Width Area Circle				Variable Length Area Circle		
	C_1-C_2	M_1-M_2	pCLMI		C_1-C_2	M_1-M_2	pCLMI
Manifest KC	41.10 ± 30.58	42.58 ± 31.67	1594.52 ±610.45		16.28 ± 11.99	16.28 ± 11.99	126.24 ± 11.96
Suspect KC	16.40 ± 8.43	16.99 ± 8.73	1589.74 ± 588.70		6.21 ± 3.23	6.21 ± 3.23	98.14 ± 74.27
Control group	5.36 ± 4.41	5.56 ± 4.57	1029.29 ± 520.49		2.11 ± 1.67	2.11 ± 1.67	44.71 ±46.10
P_{min}-P_2							
Manifest KC	58.88 ± 33.11						
Suspect KC	27.28 ± 15.60						
Control group	13.34 ± 7.08						

For all patients with manifest keratoconus, C_1-C_2, M_1-M_2, and *p*CLMI are significantly higher compared to the control group (P<0.0001); for suspect keratoconus all Group 1 indexes are significantly higher compared to healthy subjects (P<0.0001) excluding M_1-M_2 obtained using a constant area circle (P = 0.02).

For manifest and subclinical keratoconus, PPD, PSD, PSSD and PASD are significantly higher compared to the control group (P <0.0001).

Cut-off of 1- percentiles for Group 1 and 2 indexes are shown in Appendix A (Tables 4 and 5)

Sensitivity, specificity, AROC and ROC curves for Group 1 and Group 2 indexes in manifest Kc and suspect Kc are shown in Appendix B and C respectively.

The diagnostic values of analyzed parameters shifted from low to high for manifest kc (from 0.719 to 0.986) and subclinical keratoconus (from 0.614 to 0.911) at 1-percentile cut-off. We also found the highest AROC index at C1-C2

Table 3. Group 2 index values obtained for manifest Kc, suspect Kc and healthy subjects.

	PPD	**PSD**	**PSSD**	**PASD**
Manifest KC	36.60 ± 19.53	32.36 ± 17.17	51.01 ± 31.43	49.47 ± 30.85
Suspect KC	16.56 ± 5.21	15.33 ± 5.00	20.94 ± 14.65	19.91 ± 14.14
Control group	11.19 ± 4.26	10.31 ± 4.04	8.44 ± 8.19	7.98 ± 7.59

using a variable width area circle. PSSD and PSAD parameters showed the best accuracy in identifying subclinical keratoconus (AROC 0.787) in second group indices.

Conclusion

Keratoconus is a progressive, non inflammatory corneal dystrophy characterized by progressive thinning and apical protrusion of the cornea (14,15). Early diagnosis of Kc is very important because of the possibility to treat keratoconus in initial stages using corneal crosslinking procedures, and the importance of keratoconus screening in patients that are to undergo photorefractive surgical procedures.

It is well known that unidentified or suspect kc is a primary risk factor for development of corneal ectasia, a serious complication of refractive surgery (16-18). keratectasia can occur following photorefractive procedures, which are therefore contraindicated even in suspect keratoconus.

In our experience, in patients who are to undergo a photorefractive procedure, the most important considerations in the preoperative assessment are the evaluation of the expectations and personality/ psychology of the patient, and a meticulous clinical examination to rule out kc (19-23). Currently, corneal topography is the most common exam used in the detection of kc (24-27). However, this diagnostic tool may not identify all cases of initial kc because corneal topography only evaluates the anterior corneal surface, while it is well known that the first changes in the corneal morphology appear in the posterior corneal surface and in corneal pachimetry, and only in later stages changes are seen in the anterior corneal surface (12,17,24). Interestingly, many authors have reported cases of normal pre-op topographies which then resulted in post-operative keratectasia (25).

According to our data, anterior Segment OCT could be an additional diagnostic tool to detect initial stages of kc (12,28-33). Our data shows a high diagnostic accuracy for some of the proposed parameters, such as C1-C2 (AROC = 0.985, sensitivity = 94.74%, specificity = 94.00%) compared to the values proposed by Yan Li (AROC minimum value = 0.954).

In some cases of initial kc, corneal topography is normal or borderline, while OCT pachymetric indexes show values outside the normal range, detecting the presence of corneal changes associated with keratoconus in 91.89% of cases (C1-C2 Index calculated with variable width circle shows AROC = 0.911, Sensitivity 91.89%, Specificity 72.00%).

In conclusion, OCT is able to accurately detect the slightest corneal thickness changes in relation to the corneal topographic morphology, and to potentially analyse corneal geometry. When used with the proposed indexes it may be useful in the early diagnosis of kc in patients with suspected Kc that present a normal corneal topography. This would allow detection of kc in very early stages, allowing for potential treatments such as corneal cross-linking, and as an additional diagnostic tool to assess patients prior to photo refractive surgery.

Funding: This research received no external funding

Conflicts of Interest: The authors declare no conflict of interest

Appendix A

Table 4. 1-percentile cut-off for group 1 indexes.

	COSTANT AREA CIRCLE				VARIABLE AREA BASED ON DISTANCE FROM THE CENTER CIRCLE		
	C_1-C_2	M_1-M_2	pCLMI		C_1-C_2	M_1-M_2	pCLMI
1-percentile cut-off	4.86	152.7	224.8		14.24	14.89	49.59

	VARIABLE WIDTH AREA CIRCLE				VARIABLE LENGTH AREA CIRCLE		
	C_1-C_2	M_1-M_2	pCLMI		C_1-C_2	M_1-M_2	pCLMI
1-percentile cut-off	14.99	11.37	12.68		4.89	4.89	78.04

P_{min}-P_2	
1-percentile cut-off	24.99

Table 5. 1-percentile cut-off for group 2 indexes.

	PPD	PSD	PSSD	PASD
1-percentile cut-off	18.98	16.49	20.74	15.12

Appendix B

Tables showing sensitivity, specificity, AROC and ROC curves for Group 1 indexes in manifest Kc, apparently normal or suspect Kc

COSTANT AREA CIRCLE				
		C_1-C_2	M_1-M_2	pCLMI
Manifest KC	Sensibility	94.74	78.95	80.00
	Specificity	94.00	78.00	83.00
	AROC	0.985	0.843	0.864
Suspect KC	Sensibility	83.78	70.27	59.46
	Specificity	80.00	87.00	63.00
	AROC	0.897	0.614	0.712

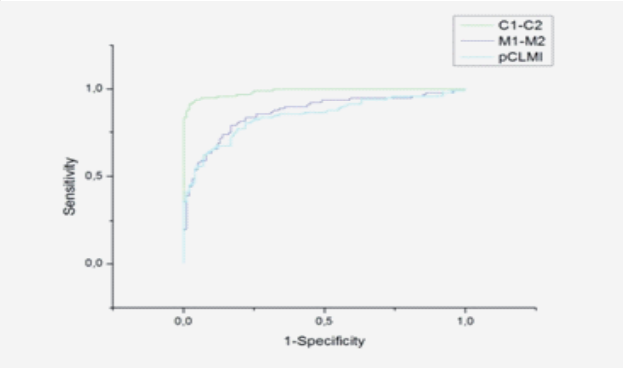

MANIFEST KC

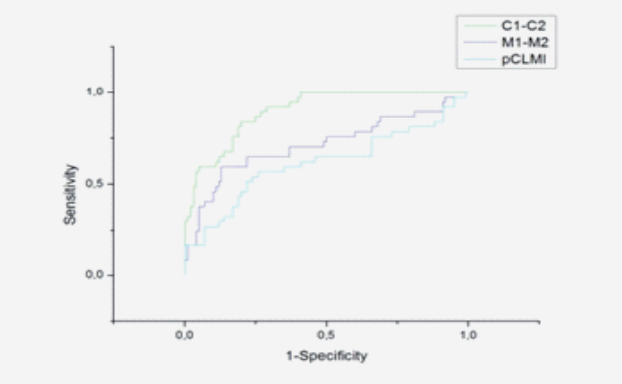

SUSPECT KC

	VARIABLE AREA BASED ON DISTANCE FROM THE CENTER CIRCLE			
		C_1-C_2	M_1-M_2	pCLMI
Manifest KC	Sensibility	94.74	94.74	65.26
	Specificity	95.00	96.00	69.00
	AROC	0.982	0.981	0.719
Suspect KC	Sensibility	62.16	72.97	70.27
	Specificity	89.00	80.00	61.00
	AROC	0.861	0.861	0.704

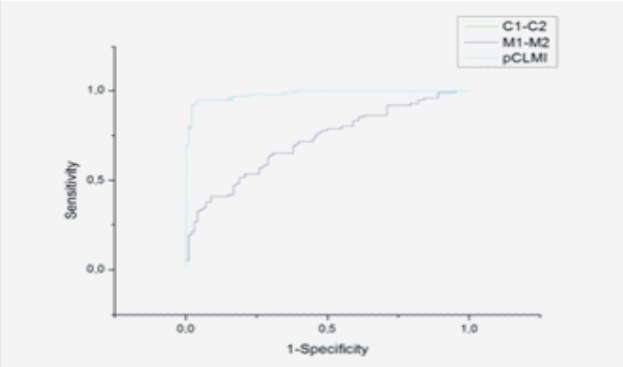

MANIFEST KC

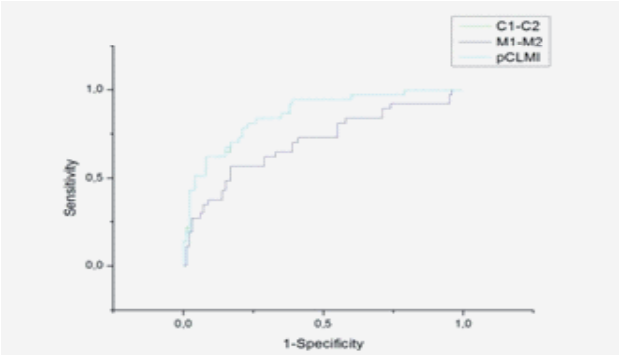

SUSPECT KC

VARIABLE WIDTH AREA CIRCLE				
		C_1-C_2	M_1-M_2	pCLMI
Manifest KC	Sensibility	92.63	95.79	70.53
	Specificity	98.00	86.00	70.00
	AROC	0.984	0.984	0.764
Suspect KC	Sensibility	91.89	70.27	89.19
	Specificity	72.00	69.00	76.00
	AROC	0.911	0.911	0.767

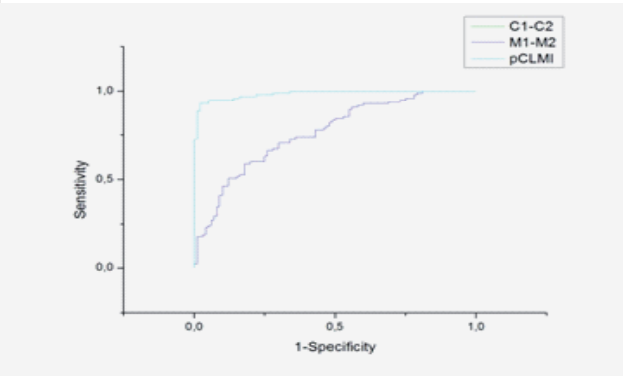

MANIFEST KC

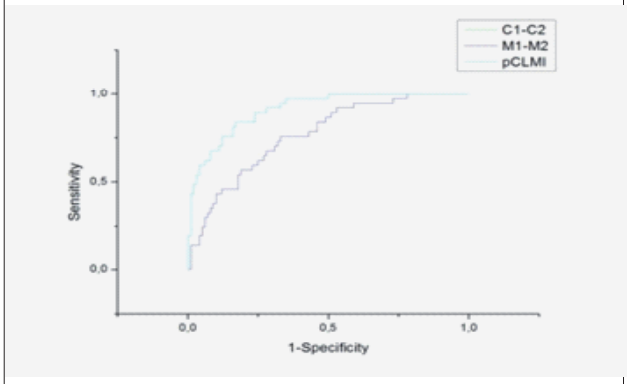

SUSPECT KC

VARIABLE LENGTH AREA CIRCLE				
		C_1-C_2	M_1-M_2	pCLMI
Manifest KC	Sensibility	95.79	95.79	65.26
	Specificity	93.00	81.00	93.00
	AROC	0.986	0.986	0.788
Suspect KC	Sensibility	81.08	78.38	91.89
	Specificity	80.00	61.00	69.00
	AROC	0.896	0.896	0.724

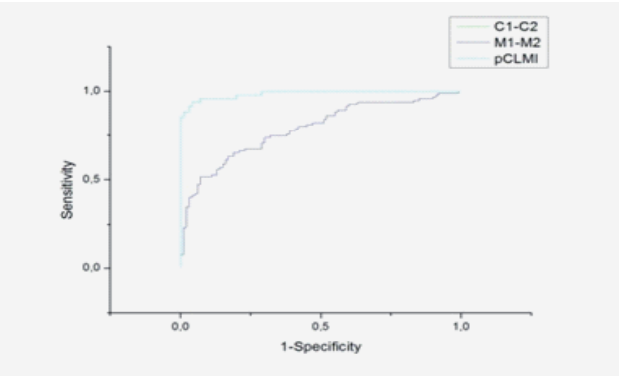

MANIFEST KC

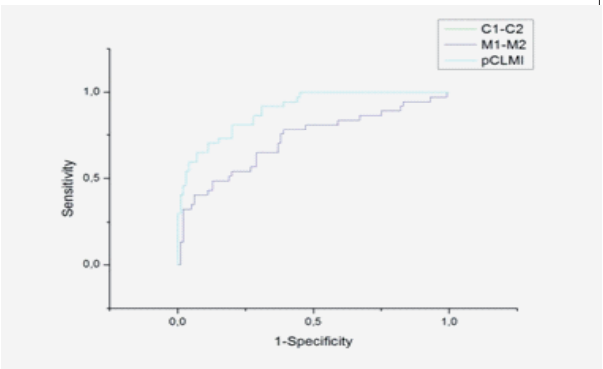

SUSPECT KC

P_{min}-P_2		
Manifest KC	Sensibility	89.47
	Specificity	92.00
	AROC	0.963
Suspect KC	Sensibility	86.49
	Specificity	51.00
	AROC	0.808

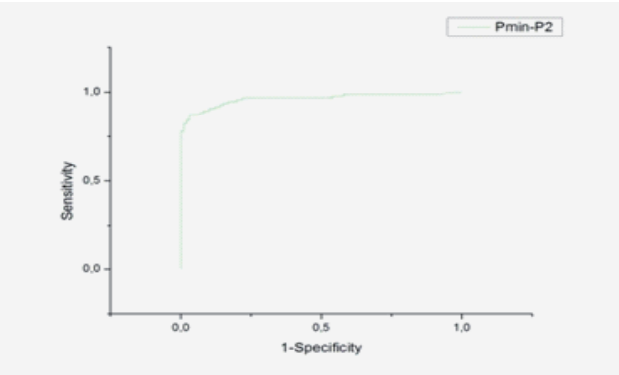

MANIFEST KC

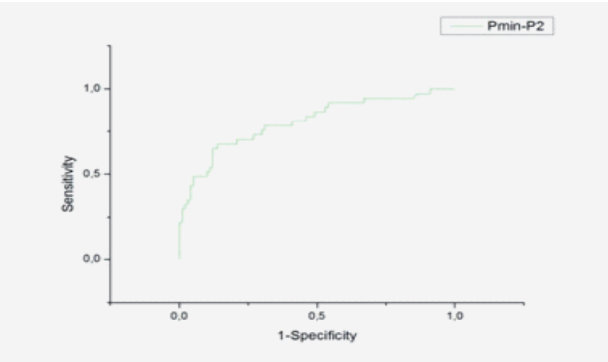

SUSPECT KC

Appendix C

Tables showing sensitivity, specificity, AROC and ROC curves for Group 2 indexes in manifest Kc, apparently normal or sspect Kc.

		PPD	PSD	PSSD	PASD
Manifest KC	Sensibility	92.63	93.68	86.32	94.74
	Specificity	95.00	94.00	92.00	87.00
	AROC	0,970	0.970	0.954	0.960
Suspect KC	Sensibility	56.76	67.57	67.57	62.16
	Specificity	88.00	76.00	83.00	87.00
	AROC	0.786	0.783	0.787	0.787

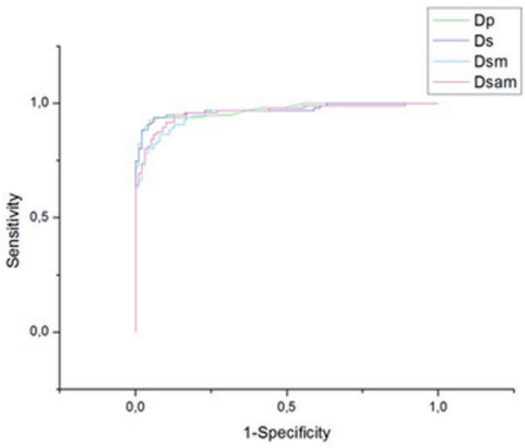

MANIFEST KC

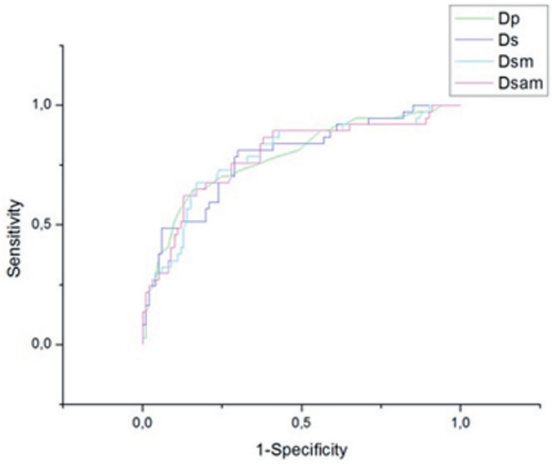

SUSPECT KC

References

1. Krachmer JH, Feder RS, Belin MW. Keratoconus and related noninflammatory corneal thinning disorders. Surv Ophthalmol 1984; 28:293-322
2. Duke-Elder S, Leigh AG. Disease of the outer eye. System of Ophthalmology 1965; 8:964-976
3. Hofstetter HW. A keratoscopic survey of 13,395 eyes. Am J Optom Arch Am Acad Optom 1959; 36:3-11
4. Kennedy RH, Bourne WM, Dyer JA. A 48-year clinical and epidemiologic study of keratoconus. Am J Ophthalmol 1986; 101:267-73
5. Edwards M, McGhee CN, Dean S. The genetics of keratoconus. Clin Experiment Ophthalmol 2001; 29:345-51
6. Ihalainen A. Clinical and epidemiological features of keratoconus genetic and external factors in the pathogenesis of the disease. Acta Ophthalmol Suppl 1986; 178:1-64
7. Nesburn AB, Bahri S, Salz J, et al. Keratoconus detected by videokeratography in candidates for photorefractive keratectomy. J Refract Surg 1995; 11:194-201
8. Wilson SE, Klyce SD. Screening for corneal topographic abnormalities before refractive surgery. Ophthalmology. 1994; 101:147-52
9. Maeda N, Klyce SD, Smolek MK. Comparison of methods for detecting keratoconus using videokeratography. Arch Ophthalmol 1995; 113:870-4
10. Maeda N, Klyce SD, Smolek MK, Thompson HW (1994) Automated keratoconus screening with corneal topography analysis. Invest Ophthalmol Vis Sci 1995; 35:2749-57
11. Mahmoud AM, Roberts CJ, Lembach RG, et al. CLEK Study Group. Cornea 2008; 27:480–87
12. Li Y, Shekhar R, Huang D. Corneal pachymetry mapping with high-speed optical coherence tomography. Ophthalmology 2006; 113:792-9
13. Goebels S, Eppig T, Wagenpfeil S, et al. Staging of keratoconus indices regarding tomography, topography, and biomechanical measurements. Am J Ophthalmol 2015; 159:733–8
14. Armitage JA, Bruce AS, Phillips AJ, et al. Morphological variants in keratoconus: anatomical observation or aetiologically significant? Aust N Z J Ophthalmol 1998; 26:68-70
15. Maguire LJ, Meyer RF. Ectasic corneal degeneration, in Kaufman H (ed): The Cornea. 1998; 485-510
16. Amsler M. The “forme fruste” of keratoconus. Wien Klin Wochenschr 1961; 73:842-3
17. Saad A, Gatinel D. Topographic and tomographic properties of forme fruste keratoconus corneas. Invest Ophthalmol Vis Sci 2010; 51:5546-55
18. Seiler T, Quurke AW. Iatrogenic keratectasia after LASIK in a case of forme fruste keratoconus. J Cataract Refract Surg 1998; 24:1007-9
19. Balacco Gabrieli C, Pacella E, Abdolrahimzadeh S, et al. Excimer laser photorefractive keratectomy for high myopia

and myopic astigmatism. Ophthalmic Surgery and Lasers 30 1999; 442-448
20. Pacella E, Abdolrahimzadeh S, Balacco Gabrieli C. Excimer laser photorefractive keratectomy for hyperopia. Ophthalmic Surgery and Lasers 2001; 32:30-34
21. Hori-Komai Y, Toda I, Asano-Kato N. Reasons for not performing refractive surgery. J Cataract Refract Surg 2002; 28: 795-797
22. Hardten DR, Vrushali V, Gosavi MD. Photerefractive keratectomy in patients with atypical topography. J Cataract Refract Surg 2009; 35:1437-1444
23. Scuderi G, Pompili M, Innamorati M, et al. Affective temperaments are associated with higher hopelessness and perceived disability in patients with open-angle glaucoma. Int J Clin Practice 2011; 65:976-984
24. Rabinowitz YS, Klyce SD, Krachmer JH et al. Videokeratography, keratoconus, and refractive surgery. Opinions. Refract Corneal Surg 1992; 5:403-407
25. Rabinowitz YS, Rasheed K. KISA % index: a quantitative videokeratography algorithm embodying minimal topographic criteria for diagnosing keratoconus. J Cataract Refract Surg 1999; 25:1327-35
26. Rabinowitz YS, McDonnell PJ. Computer-assisted corneal topography in keratoconus. Refract Corneal Surg 1989; 5: 400-8
27. Rabinowitz YS. Videokeratographic indices to aid in screening for keratoconus. J Refract Surg 1995; 11:371-9
28. Szalai E, Berta A, Hassan Z, et al. Reliability and repeatability of swept-source Fourier-domain optical coherence tomography and Scheimpflug imaging in keratoconus. J Cataract Refract Surg 2012; 38:485-94
29. Keller P, Van Saarloos P. Fourier transformation of corneal topography data. Aust N Z J Ophthalmol 1997; 25:53-5
30. Li Y, Meisler DM, Tang M, et al. Keratoconus diagnosis with optical coherence tomography pachymetry mapping. Ophthalmology 2001; 15:2159-66
31. Qin B, Chen S, Brass R, et al. Keratoconus diagnosis with optical coherence tomography based pachymetric scoring system. J Cataract Refract Surg 2013; 39:1864-71
32. Shirayama-Suzuki M, Amano S, Honda N, et al. Longitudinal analysis of corneal topography in suspected keratoconus. Br J Ophthalmol 2009; 93:815-9
33. Jafri B, Li X, Yang H, et al. Higher order wavefront aberrations and topography in early and suspected keratoconus. J Refract Surg 2007; 23:774-81