



Case report

Case report: An epidural cavernous hemangioma mimicking a dumbbell-shaped neuroma



Riccardo Caruso^{a,b,*}, Valentina Martines^a, Luigi Marrocco^b, Emanuele Piccione^b, Venceslao Wierzbicki^b, Mariangela Lombardi^c

^a Sapienza University of Rome, Department of Human Neuroscience, Viale dell'Università 30, 00185 Roma, Italy

^b Army Hospital of Rome "Celio", Neurosurgery Department, Via S. Stefano Rotondo n. 4, 00184 Roma, Italy

^c Army Hospital of Rome "Celio", Clinical Pathology Department, Via S. Stefano Rotondo n. 4, 00184 Roma, Italy

ARTICLE INFO

Keywords:

Case report
Spinal tumor
Neuroma
Epidural hemangioma
MRI
Differential diagnosis
Rare hemangioma
Rare spinal lesion

ABSTRACT

Introduction and importance: Spinal epidural cavernous hemangiomas are a rare occurrence. This particular case is made even more distinctive by the fact that the lesion mimicked a dumbbell-shaped neuroma. Moreover, it had a very unique localization (wholly epidural, at cervical-thoracic -C7-D1- level). The importance of this case is linked not only to its remarkable rarity, but also to the diagnostic avenues explored.

The surgery was carried out by Prof. Riccardo Caruso, Head of the Neurosurgical Department of the Military Hospital of Rome and Professor of Neurosurgery of Sapienza University of Rome, assisted by Dr. Luigi Marrocco, Senior Neurosurgeon of the Military Hospital of Rome. Postsurgical recovery was managed by Dr. Venceslao Wierzbicki, Senior Neurosurgeon of the Military Hospital of Rome.

Case presentation: In 2020, a 71 year-old man, suffering from intense pain in the left scapular region and in the ulnar area of the left forearm, underwent surgery for the removal of a spinal epidural cavernous hemangioma involving the left C7-D1 foramen. Prior to surgery, the lesion had been misdiagnosed as a neuroma by a radiologist.

Clinical discussion: In the Literature there are other, rare cases of hemangiomas partly located in the spinal canal, and partly located intra and extra foramen. In the case here presented, differential diagnosis as well as a potential Schwannoma, suggested by the dumbbell shape of the lesion, should have considered also the possibility of a meningioma. Two teams of radiologists examined the images, the radiologists of our team, Dr. Valentina Martines and Dr. Emanuele Piccione, thanks to a close inspection of the features of the lesion, postulated the extradural position. Other aspects of the scans were then analyzed to help guide future diagnosis of similar lesions. **Conclusion:** With a spinal tumor affecting the foramen, a close examination of the images allows for accurate presurgical differential diagnosis, differentiating between the more frequent neuroma and other rarer tumors, such as a hemangioma.

1. Introduction

In this paper, we present a rare case of cavernous hemangioma of the spine [1].

Two elements make this a very interesting and distinctive case:

- 1) The epidural position of the hemangioma, not rooted in the vertebrae
- 2) The C7-D1 area affected, when these lesions are more likely to be found in the dorsal and lumbar regions.

- 3) Its appearance, which greatly resembled that of a dumbbell-shaped neuroma of the spine.

The surgery was carried out by Prof. Riccardo Caruso, Head of the Neurosurgical Department of the Military Hospital of Rome and Professor of Neurosurgery of Sapienza University of Rome, assisted by Dr. Luigi Marrocco, Senior Neurosurgeon of the Military Hospital of Rome. Postsurgical recovery was managed by Dr. Venceslao Wierzbicki, Senior Neurosurgeon of the Military Hospital of Rome.

The case has been reported in line with SCARE criteria [2].

* Corresponding author at: Via Pietro Da Cortona 1, Italy.

E-mail address: riccardo.caruso@uniroma1.it (R. Caruso).

<https://doi.org/10.1016/j.ijscr.2021.106069>

Received 5 May 2021; Received in revised form 29 May 2021; Accepted 2 June 2021

Available online 9 June 2021

2210-2612/© 2021 The Authors. Published by Elsevier Ltd on behalf of IJS Publishing Group Ltd. This is an open access article under the CC BY-NC-ND license

(<http://creativecommons.org/licenses/by-nc-nd/4.0/>).

2. Case report

In February 2020 a 71 year old man was admitted to the Military Hospital in Rome after suffering from a sharp, fast-degenerating pain in the left scapular region and in the ulnar area of the left forearm for about two months. The pain increased when the patient was lying down.

Neurological examination showed:

- a) hyporeflexia of the left triceps reflex;
- b) slight hypoesthesia along the ulnar area of the left forearm;
- c) an accentuated left knee-jerk reflex compared to the right side;
- d) mute left plantar reflex;
- e) there was no deficit in strength or motility.

Ten days prior to admission the patient had undergone an MRI scan, with and without contrast; the report diagnosed a probable localized spinal neuroma at D1, partly involving the left C7-D1 foramen (Figs. 1, 2, 3). The images were subsequently examined by the radiologists of our team, who suggested a different diagnosis to the one made in the report, hypothesizing the extradural nature of the lesion.

The patient underwent a laminectomy at C7 and D1, which evidenced the presence of a well encapsulated lesion of a red hue, entirely external to the dura, in the axilla of the C8 root. The lesion had also

dislocated the dural sac at the back and side from left to right, while the root at foramen level had been shifted upwards.

After opening the tumor capsule, we retrieved samples for histological examination, and then completely removed the lesion with an ultrasonic aspirator.

During removal there was copious bleeding from the lesion, which was promptly managed by efficient and speedy extraction. After completion, hemostasis was easily achieved. The entire operation was carried out under neurophysiological monitoring, which did not highlight any suffering of the spinal cord or root.

Within 24 h from surgery, the patient felt the pain recede. Three days after the operation, the patient was discharged.

Histological examination revealed a cavernous hemangioma (Fig. 4). An MRI scan six months after the operation confirmed the complete removal of the lesion.

3. Discussion

Hemangiomas are vascular malformations that frequently exhibit a cavernous structure, similar to the case presented here; while in rare instances they can display a capillary, venous, or arteriovenous structure; non-vascular elements can also be found within a hemangioma, such as fat, hemosiderin deposits, fibrous tissue and muscle fibers [3,4].

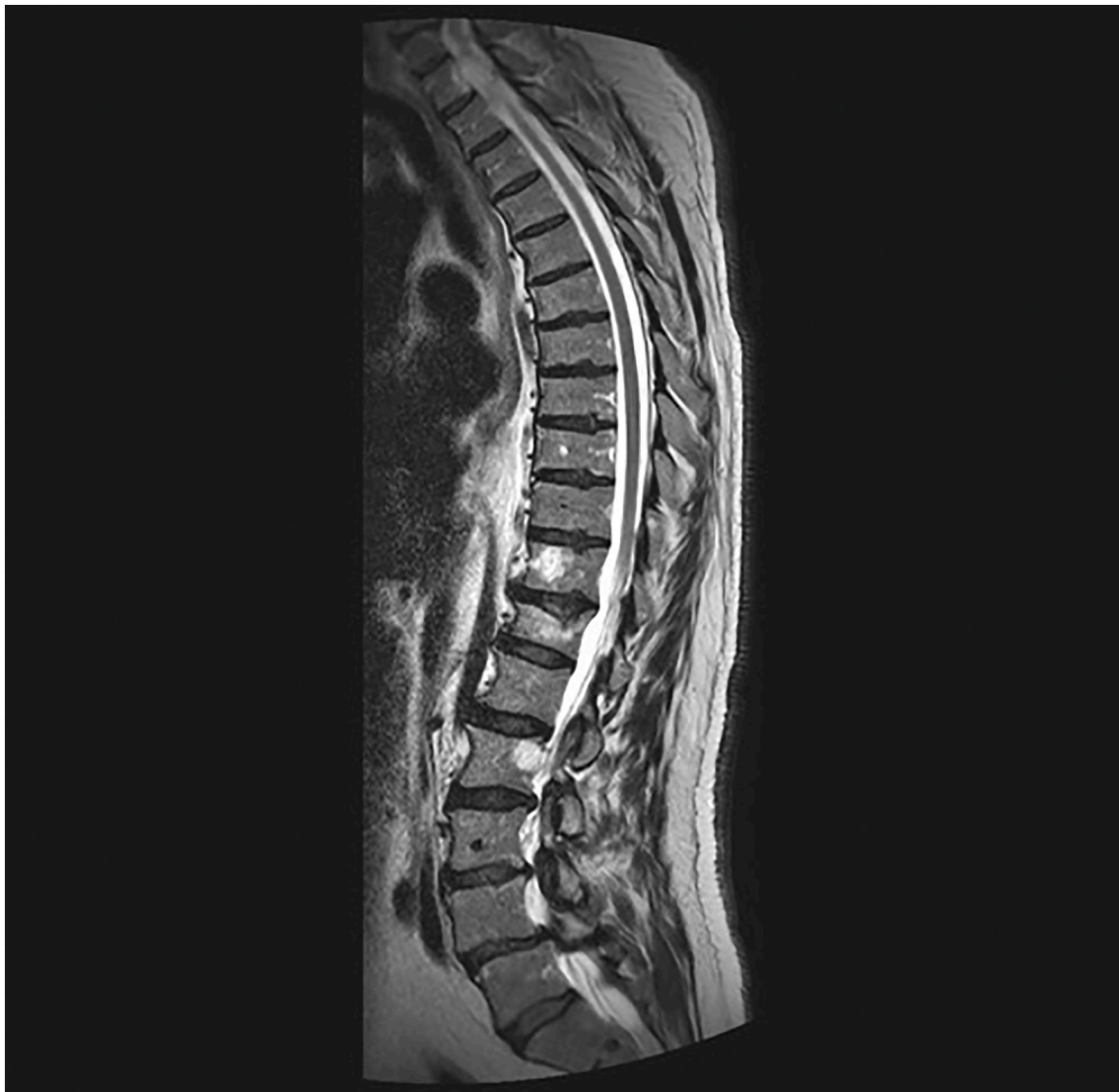

Fig. 1. MRI in sagittal projection. An intracanal lesion is seen at the D1 vertebra level; it is hyperintense in the T2-weighted sequence.

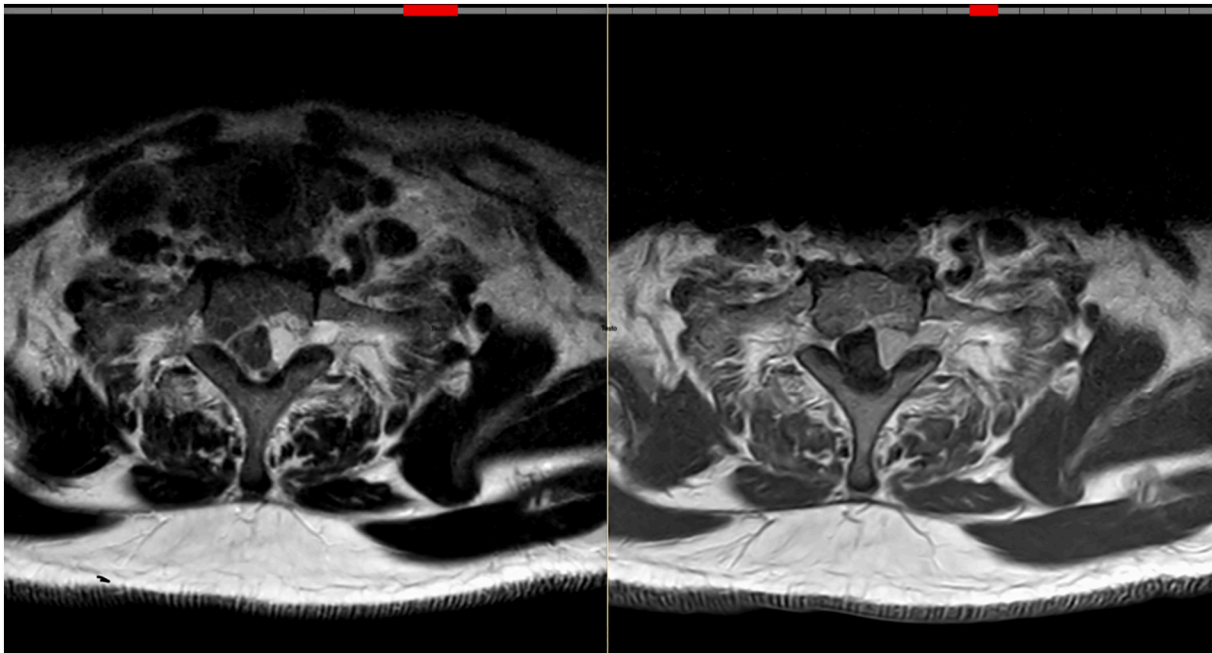


Fig. 2. MRI in transverse projection. The lesion appears substantially homogeneous, slightly hyperintense in the T2-weighted sequence, isohypointense in the T1-weighted sequence and shows homogeneous enhancement after intravenous contrast injection. It has the classic look of a dumbbell-shaped spinal neuroma.

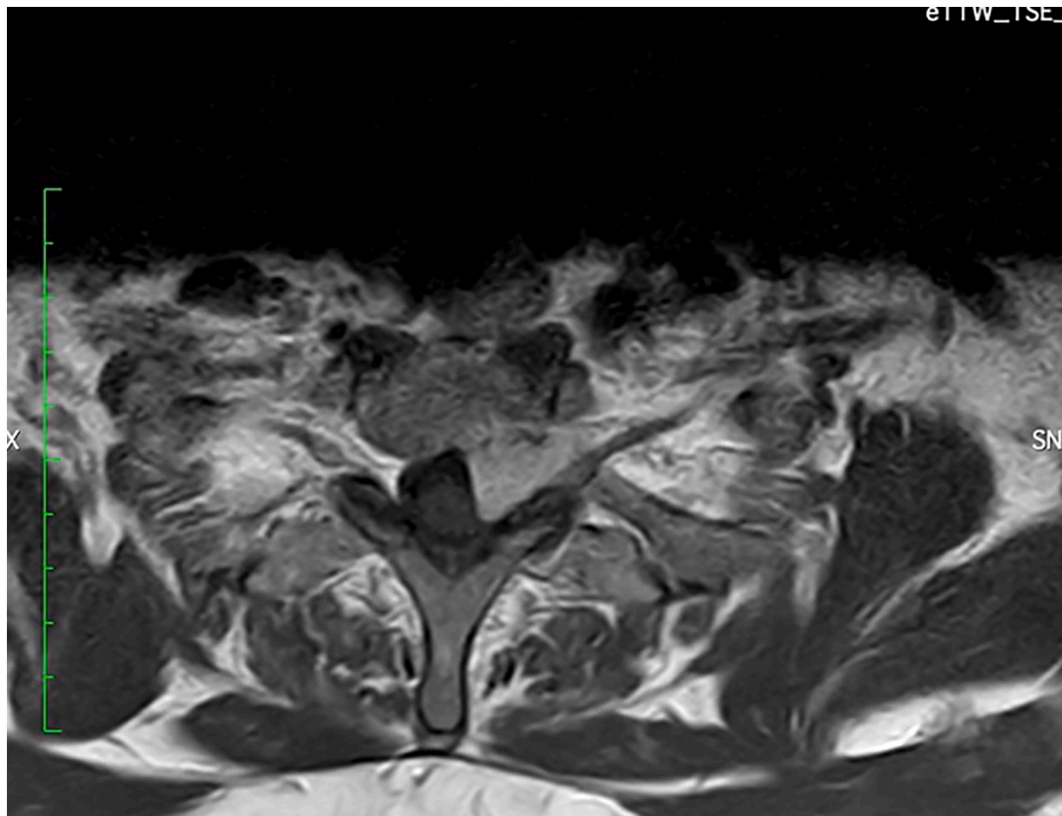


Fig. 3. in this MRI slice, it is possible to glean that the C8 root is posteriorly dislocated by the tumor in the foramen, rather than being the origin of the lesion.

These malformations are usually found in the vertebrae; the over-spreading into the epidural space is considered an extension of the vertebral position, whereas the pure epidural localization is rare [5], and it is incidentally relatively more common in the dorsal and lumbar regions, rather than in the cervical region. Epidural hemangiomas

represent 1–2% of all spinal hemangiomas, and 4% of all epidural lesions [5,6]. Sometimes, like in our case, in the epidural location there can be the secondary involvement of the bone.

The appearance is generally hypointense in T1 and hyperintense in T2, with intense and homogenous post contrast enhancement. In the

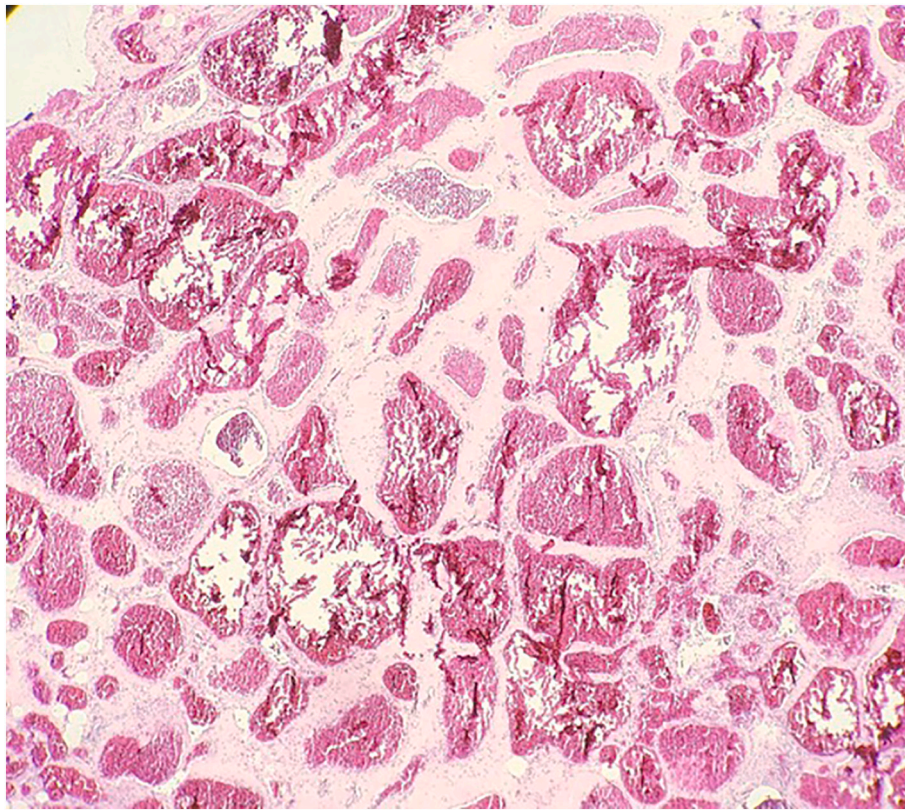


Fig. 4. histological finding showing a cavernous hemangioma. The magnification is 20× and the staining is hematoxylin-eosin.

hemangiomas exceeding from the bone of the vertebral body into the spinal canal, sometimes, in the sagittal plane, it is possible to recognize the hypointense posterior longitudinal ligament that defines the posterior margin. At times a capsule can also be discerned [7].

In the Literature there are other cases of hemangiomas partly located in the spinal canal and partly located intra and extra foramen [8–16]. The location of the case presented here is remarkably rare.

Differential diagnosis ought to have considered, beside the potential Schwannoma indicated by the dumbbell appearance of the lesion, also a meningioma [17].

In this instance, the MRI data on intensity were not particularly useful, while the morphological aspects of the lesion were to guide diagnosis. The involvement of the vertebral area on the left back side of the D1 vertebral body, evidenced by the signal alteration, did not suggest a Schwannoma; there was no real widening of the foramen affected by the dumbbell-shaped lesion. Furthermore, in one of the MRI slices, it was possible to glean that the C8 root was posteriorly dislocated by the tumor in the foramen, rather than being the origin of the lesion.

The medial profile of the lesion appeared relatively straight, contrary to the appearance of an intradural lesion and/or of a lesion that is rooted in the dura, which is usually round with a large homogenous curve. This morphological feature led to the hypothesis that the lesion might be located in the epidural space.

In regards to the potential meningioma diagnosis, we noticed that the dura on the left posterior margin, at the height of the left transvers process of C7 seemed thicker, similarly to the dural tail of meningiomas, but differently from what is expected in a meningioma, it defined a sharp angle to the main portion of the lesion. The margins of the lesion in the intracanal-free portion were well defined, but lumpy, similar to a blackberry or raspberry, a strange feature for a meningioma considering also the size of the lesion.

4. Conclusion

With a spinal tumor affecting the foramen, the most probable and frequent diagnosis is that of a neuroma. However, it is necessary to consider also other, albeit less frequent, possibilities: one of these is the epidural hemangioma. It is a rare occurrence, especially at cervical and upper thoracic level, however a close examination of the images can deliver an accurate presurgical differential diagnosis and significantly aid surgery.

Consent

Written informed consent was obtained from the patient for publication of this case report and accompanying images. A copy of the written consent is available for review by the Editor-in-Chief of this journal on request.

Provenance and peer review

Not commissioned, externally peer-reviewed.

Sources of funding

None.

Ethical approval

The ethical committee of the Military Hospital of Rome has approved the case report.

Author contribution

Riccardo Caruso: Head Neurosurgeon of this case and first author of the case report.

Valentina Martines: Radiologist who examined the scans.

Luigi Marrocco: Assistant Neurosurgeon of this case.

Emanuele Piccione: Radiologist who also viewed and examined the scans.

Venceslao Wierzbicki: Neurosurgeon who followed the patient post-surgery.

Mariangela Lombardi: Histopathologist who carried out the histological examination and took pictures of the slides.

Research registration

Non applicable.

Guarantor

Riccardo Caruso.

Declaration of competing interest

None.

References

- [1] M.R. Khalatbari, K. Abbassioun, A. Amirjshidi, Solitary spinal epidural cavernous angioma: report of nine surgically treated cases and review of the literature, *Eur. Spine J.* 22 (3) (2013) 542–547, <https://doi.org/10.1007/s00586-012-2526-2>. Mar. (Epub 2012 Oct 6. PMID: 23053760; PMCID: PMC3585645).
- [2] R.A. Agha, T. Franchi, C. Sohrabi, G. Mathew, for the SCARE Group, The SCARE 2020 guideline: updating consensus surgical CAse REport (SCARE) guidelines, *Int. J. Surg.* 84 (2020) 226–230.
- [3] B. Badinand, C. Morel, N. Kopp, V.A. Tran Min, F. Cotton, Dumbbell-shaped epidural capillary hemangioma, *AJNR Am. J. Neuroradiol.* 24 (2) (2003 Feb) 190–192 (PMID: 12591632).
- [4] M.P. Rajeev, P.Y. Waykule, V.M. Pavitharan, B.N. Nandeesh, Spinal epidural capillary hemangioma: a rare case report with a review of literature, *Surg. Neurol. Int.* 8 (2017) 123, https://doi.org/10.4103/sni.sni_94_17. Jun 21. (PMID: 28713627; PMCID: PMC5502299).
- [5] N. Aoyagi, K. Kojima, H. Kasai, Review of spinal epidural cavernous hemangioma, *Neurol. Med. Chir. (Tokyo)* 43 (10) (2003) 471–475. Oct. (discussion 476. doi: 10.2176/nmc.43.471. PMID: 14620197).
- [6] W.J. Jeong, I. Choi, H.Y. Seong, S.W. Roh, Thoracic extradural cavernous hemangioma mimicking a dumbbell-shaped tumor, *J. Korean Neurosurg. Soc.* 58 (1) (2015) 72–75, <https://doi.org/10.3340/jkns.2015.58.1.72>. Jul. (Epub 2015 Jul 31. PMID: 26279817; PMCID: PMC4534743).
- [7] J.H. Shin, H.K. Lee, S.C. Rhim, S.H. Park, C.G. Choi, D.C. Suh, Spinal epidural cavernous hemangioma: MR findings, *J. Comput. Assist. Tomogr.* 25 (2) (2001) 257–261, <https://doi.org/10.1097/00004728-200103000-00019>. Mar-Apr. (11242225).
- [8] R. Carlier, S. Engerand, S. Lamer, C. Vallee, B. Bussel, M. Polivka, Foraminal epidural extra osseous cavernous hemangioma of the cervical spine: a case report, *Spine (Phila Pa 1976)* 25 (5) (2000) 629–631, <https://doi.org/10.1097/00007632-200003010-00016>. Mar 1, 10749642.
- [9] F. Cofano, N. Marengo, F. Pecoraro, F. Penner, L. Bertero, F. Zenga, Spinal epidural capillary hemangioma: case report and review of the literature, *Br. J. Neurosurg.* (2019) 1–4, <https://doi.org/10.1080/02688697.2018.1562034>. Mar 4. Epub ahead of print, 30829069.
- [10] C. Cossandi, A. Fanti, A. Gerosa, E. Crobeddu, S. Forgnone, L. Magrassi, P. Car, A. Bianco, R. Fornaro, G. Panzarasa, Rare case of dumbbell-shaped spinal cavernous Hemangioma and literature review, *World Neurosurg.* 120 (2018) 181–184, <https://doi.org/10.1016/j.wneu.2018.09.003>. Dec. Epub 2018 Sep 10, 30213678.
- [11] G. D'Andrea, O.E. Ramundo, G. Trillò, R. Roperto, A. Isidori, L. Ferrante, Dorsal foraminal extraosseous epidural cavernous hemangioma, *Neurosurg. Rev.* 26 (4) (2003) 292–296, <https://doi.org/10.1007/s10143-003-0275-8>. Oct. Epub 2003 Jun 14, 14520522.
- [12] K. Egu, S. Kinata-Bambino, M. Mounadi, M. Rachid El Maaqili, N. El Abbadi, Hémangiome capillaire épidual lombosacré mimant un neurinome en sablier : à propos d'un cas et revue de la littérature [Lombosacral epidural capillary hemangioma mimicking a dumbbell-shaped neuroma: a case report and review of the literature], *Neurochirurgie* 62 (2) (2016) 113–117. Apr. French.
- [13] M.A. García-Pallero, C.V. Torres, E. García-Navarrete, C. Gordillo, J. Delgado, J. R. Penanes, M.T. García-Campos, R.G. Sola, Dumbbell-shaped epidural capillary Hemangioma presenting as a lung mass: case report and review of the literature, *Spine (Phila Pa 1976)* 40 (14) (2015) E849–E853, <https://doi.org/10.1097/BRS.0000000000000970>. Jul 15, 25946721.
- [14] K.T. Huang, M. McAvoy, J. Helgager, V. Vasudeva, J.H. Chi, Spinal hemangioma mimicking a dumbbell-shaped schwannoma: case report and review of the literature, *J. Clin. Neurosci.* 50 (2018) 160–162, <https://doi.org/10.1016/j.jocn.2018.01.037>. Apr. Epub 2018 Feb 2, 29398191.
- [15] J.S. Kang, K.O. Lillehei, Kleinschmidt-Demasters BK. Proximal nerve root capillary hemangioma presenting as a lung mass with bandlike chest pain: case report and review of literature, *Surg. Neurol.* 65 (6) (2006) 584–589. Jun. (discussion 589. doi:10.1016/j.surneu.2005.07.070. PMID: 16720181).
- [16] A. Santoro, M. Piccirilli, R. Bristol, V. di Norcia, M. Salvati, R. Delfini, Extradural spinal cavernous angiomas: report of seven cases, *Neurosurg. Rev.* 28 (4) (2005) 313–319, <https://doi.org/10.1007/s10143-005-0390-9>. Oct. Epub 2005 May 31, 15926084.
- [17] K.K. Koeller, R.Y. Shih, Intradural extramedullary spinal neoplasms: radiologic-pathologic correlation, *Radiographics* 39 (2) (2019) 468–490, <https://doi.org/10.1148/rg.2019180200>. Mar-Apr. (30844353).