

Three-dimensional assessment of the spheno-occipital synchondrosis and clivus after tooth-borne and bone-borne rapid maxillary expansion: A retrospective CBCT study using voxel-based superimposition

Rosalia Leonardi^a; Vincenzo Ronsivalle^b; Manuel O. Lagravere^c; Ersilia Barbato^d; Gaetano Isola^e; Antonino Lo Giudice^f

ABSTRACT

Objectives: To assess changes in spheno-occipital synchondrosis after rapid maxillary expansion (RME) performed with conventional tooth-borne (TB) and bone-borne (BB) appliances.

Materials and Methods: This study included 40 subjects with transverse maxillary deficiency who received TB RME or BB RME. Cone-beam computed tomography images (CBCT) were taken before treatment (T0), and after a 6-month retention period (T1). Three-dimensional surface models of the spheno-occipital synchondrosis and basilar part of the occipital bone were generated. The CBCTs taken at T0 and T1 were registered at the anterior cranial fossa via voxel-based superimposition. Quantitative evaluation of Basion displacement was performed with linear measurements and Euclidean distances. The volume of the synchondrosis was also calculated for each time point as well as the Nasion-Sella-Basion angle (N-S-Ba°). All data were statistically analyzed to perform inter-timing and intergroup comparisons.

Results: In both groups, there was a small increment of the volume of the synchondrosis and of N-S-Ba° ($P < .05$). Basion showed a posterosuperior pattern of displacement. However, no significant differences ($P > .05$) were found between the two groups.

Conclusions: Although TB and BB RME seemed to have some effects on the spheno-occipital synchondrosis, differences were very small and clinically negligible. (*Angle Orthod.* 0000;00:000–000.)

KEY WORDS: Rapid maxillary expansion; Spheno-occipital synchondrosis; Bone-borne RME; Tooth-borne RME

INTRODUCTION

Rapid maxillary expansion (RME) is the treatment of choice for the correction of transverse maxillary deficiency in growing subjects.^{1,2} The most common design of RME is a tooth-anchored (TB) expander.³ Common undesirable results in conventional RME have been described² and, to moderate these side effects, clinicians have used tooth-bone-borne (TBB) or bone-borne (BB) expanders supported by the use of temporary skeletal anchorage devices (TSADs).³

Although the main purpose of RME is to correct maxillary arch discrepancies, its effect is not limited to the maxillary alveolus and midpalatal suture but is expected to affect several other adjacent structures in the face and the cranium.⁴ The transverse forces generated during rapid maxillary expansion are transmitted via the pterygomaxillary connection to the unpaired sphenoid of the cranial base where they lead

^a Full Professor, Department of Orthodontics, School of Dentistry, University of Catania, Catania, Italy.

^b Research Fellow, Department of Orthodontics, School of Dentistry, University of Catania, Catania, Italy.

^c Professor, Orthodontic Graduate Program, University of Alberta, Edmonton, Canada.

^d Full Professor, Department of Oral and Maxillofacial Sciences, School of Dentistry, "Sapienza" University of Rome, Italy.

^e Assistant Professor, Department of Periodontology, School of Dentistry, University of Catania, Catania, Italy.

^f Adjunct Professor, Department of Orthodontics, School of Dentistry, University of Catania, Catania, Italy.

Corresponding author: Antonino Lo Giudice, DDS, PhD, MSc, Department of Orthodontics, School of Dentistry, University of Catania, Policlinico Universitario "Vittorio Emanuele", Via Santa Sofia 78, Catania 95123, Italy (e-mail: nino.logiudice@gmail.com)

Accepted: April 2021. Submitted: January 2021.

Published Online: June 15, 2021

© 0000 by The EH Angle Education and Research Foundation, Inc.

to stress, the extent and effects of which have yet to be determined more clearly.⁵

Few studies have been done on the effect of RME on the spheno-occipital synchondrosis (SOS) and these have dealt mainly with experimental models based on finite element analysis (FME),⁵⁻⁷ organ culture studies,⁸ and animal studies.⁹ Findings from these previous investigations pointed out that SOS seems to be affected by RME. Also, few studies were carried out on human subjects by using either a bone scintigraphy method¹⁰ or low-dose computed tomography¹¹ and lateral cephalometric head films.¹² In this regard, the changes occurring at the SOS during maxillary expansion could be of clinical relevance since the opening of the SOS could account for forward and downward movement of the midface which, in turn, could favor the treatment of subjects with Class III malocclusion.^{11,13}

For the same reason, it would be interesting to assess the changes at SOS during maxillary expansion performed with TB and BB appliances, considering that previous studies evaluated only TB expanders. In fact, existing evidence from randomized trials on RME for transverse maxillary deficits indicated that bone-borne RME might be associated with greater skeletal expansion at the craniofacial bones compared to tooth-borne (TB) RME treatment,¹⁴ but no evidence on SOS has been ever reported. Therefore, the aim of this study was to assess the changes in the SOS after RME treatment with conventional TB and bone-borne (BB) expansion via CBCT and voxel-based superimposition, which was found to be reliable, precise, and more accurate than landmark-based methods.^{15,16} The null hypothesis was that TB and BB would have no different expansion patterns and magnitudes on the SOS in young adolescents.

MATERIALS AND METHODS

The research protocol of this study was approved by the Ethics Review Board of Indiana University–Purdue University (IRB protocol number: 1708606623) and included a retrospective sample of young subjects treated with TB or BB RME at the Orthodontic Clinic of the University of Alberta (Edmonton, Canada, USA).

The sample consisted of 20 individuals (17 boys, 23 girls) with a mean age of 12.7 ± 1.17 years, into the TB group (11 girls, nine boys; mean age: 12.6 ± 1.09 years) and BB group (12 girls, eight boys; mean age: 12.9 ± 1.28 years).

The inclusion criteria were: skeletal transverse deficiency; good-quality pretreatment (T0) and post-retention (T1) CBCT scans; synchondrosis closure stages scored as completely open (Stage 0, Unfused) or partially closed (Stage 1, fused endocranially).¹⁷ The

exclusion criteria were: dentofacial deformities and/or facial asymmetry; previous orthodontic treatment, maxillofacial surgery or facial trauma; temporomandibular joint disorder; impacted/unerupted mandibular tooth/teeth; and anterior crossbite.

The characteristics of the RME protocol used in this study were previously described.¹⁸ In the TB group, the Hyrax expander was anchored with bands on the permanent first molars and first premolars. In the BB group, two miniscrews were inserted in the palate between the permanent first molar and the second premolar (length: 12 mm; diameter: 1.5 mm; Straumann GBR [guided bone regeneration] System, Andover, MA) and connected with the expander (Palex II Extra-Mini Expander, Summit Orthodontic Services, Munroe Falls, OH). The activation rate was 0.25 mm/turn of the screw in both groups, the RME protocol included two turns per day and activations were stopped once overexpansion was achieved. Finally, the appliance was kept in place for 6 months.

Cone-beam computed tomography images were acquired with the i-CAT machine (Imaging Sciences International, Hartfield, PA) using the same setting protocol (120 kVp, 23.87 mAS, 8.9-second exposure time, large field of view [FOV], 0.3-mm voxel size), before treatment (T0) and immediately after appliance removal (T1) (mean interval, 6.7 months \pm 0.8).

DICOM (Digital Imaging and Communications in Medicine) files of CBCTs taken at T0 were imported into the Dolphin 3D software (Dolphin Imaging1, version 11.0, Chatsworth, CA, USA) to perform the reorientation of the skull according to a validated protocol.^{19,20} Figure 1 illustrates the coronal, sagittal, and axial reconstruction slices after head orientation. Once CBCTs were reoriented, the following steps were carried out to measure Basion (Ba) displacement in two and three dimensions.

STEP 1 Voxel-Based Superimposition

The anterior cranial base area was selected using the sub-region box in Dolphin software (Figure 2). Using the defined edges, the software matched the voxels of each CBCT in this area and automatically superimposed them between T0 and T1. Then, the CBCT taken at T1 was exported as a new DICOM file.

STEP 2 Segmentation of Synchondrosis and Basilar Part and Na-S-Ba Angle Measurements

T0 and T1 CBCTs were imported into Mimics Research software (version 21.0.0.406, Materialise NV, Leuven, Belgium) to generate the segmentation masks and to obtain the 3D volumetric models (Figures 3 and 4). Also, in the multiple planar section of the software, the Nasion, Sella, and Basion points were

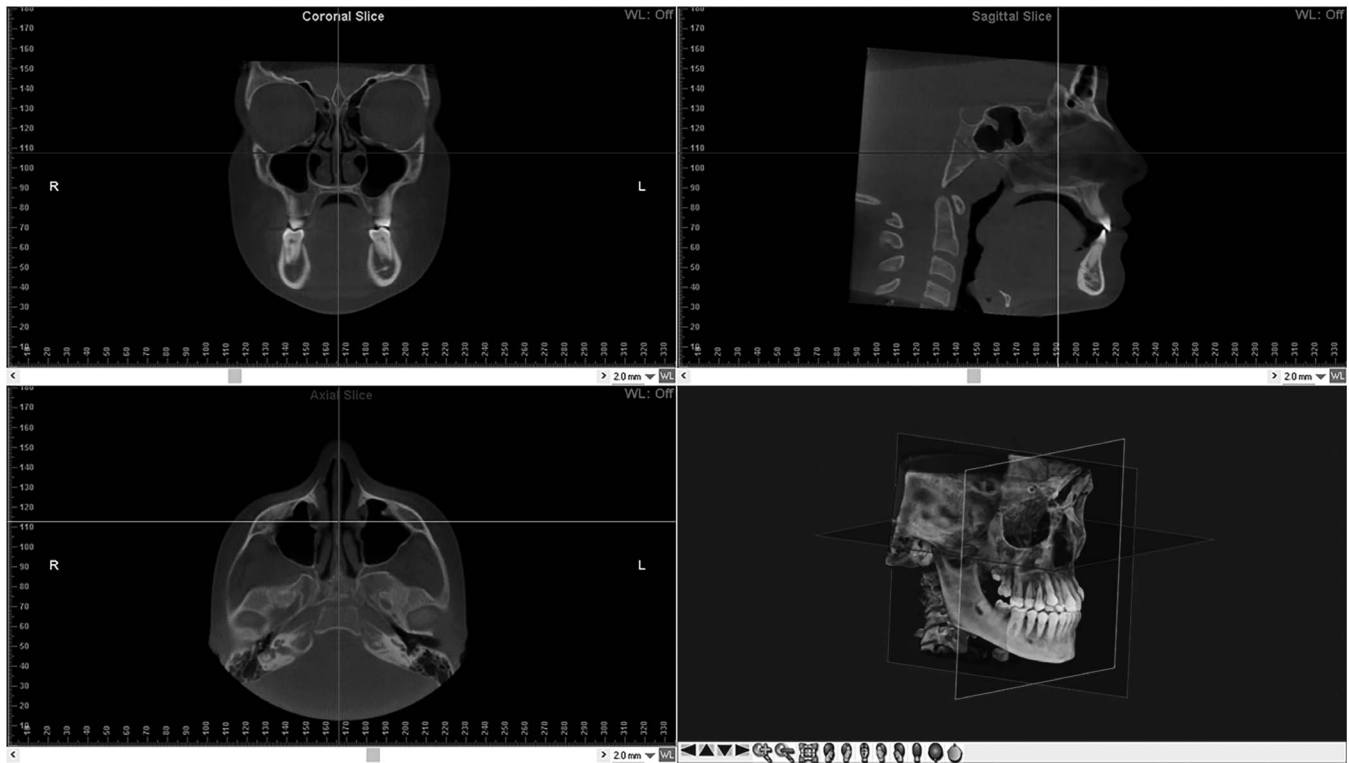


Figure 1. Head reorientation in the axial, sagittal and coronal planes of CBCT scans. The 3D image shows the head orientation in 3D space. Lines represent the reference axes. CBCT indicates cone-beam computed tomography; 3D, three-dimensional.

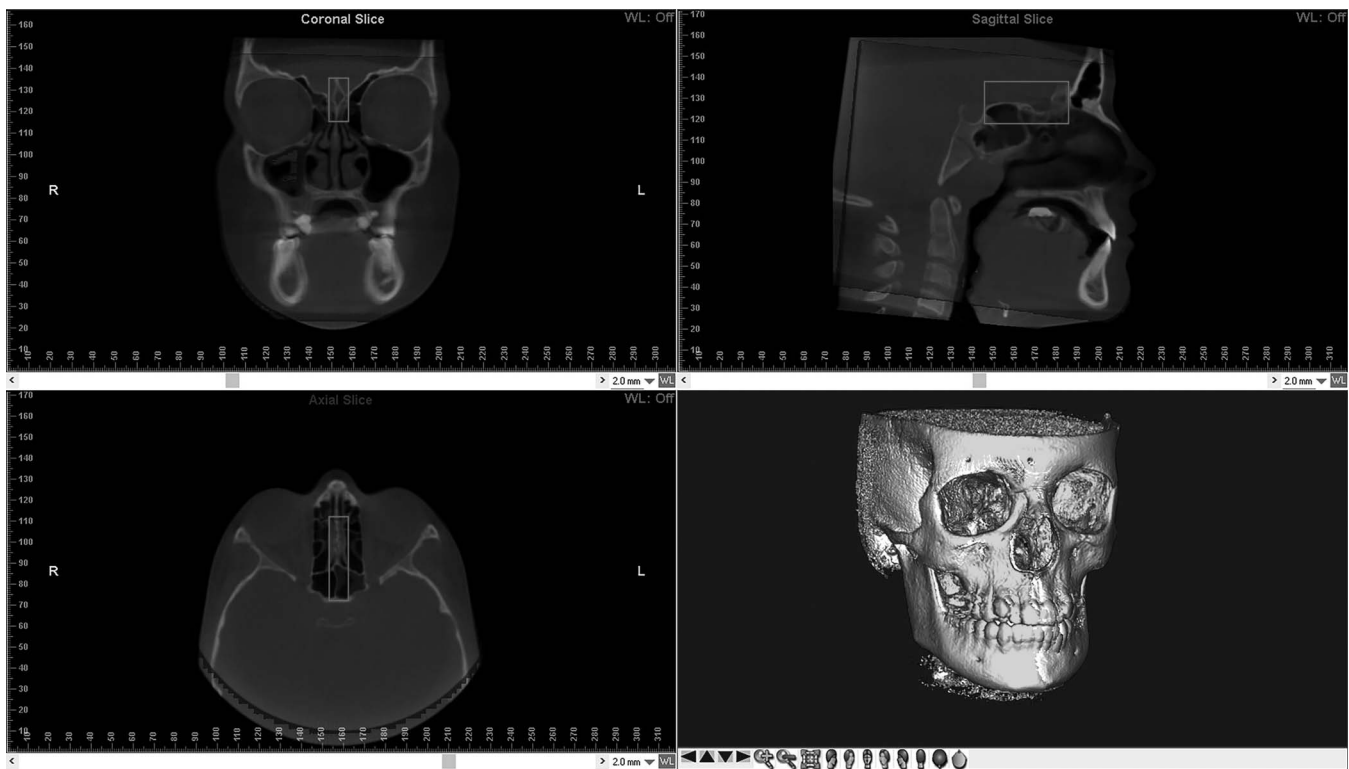


Figure 2. Voxel-based superimposition on the anterior cranial base. The red box is used to define, in three dimensions, the area of the cranial base to be used as a stable reference for the superimposition.

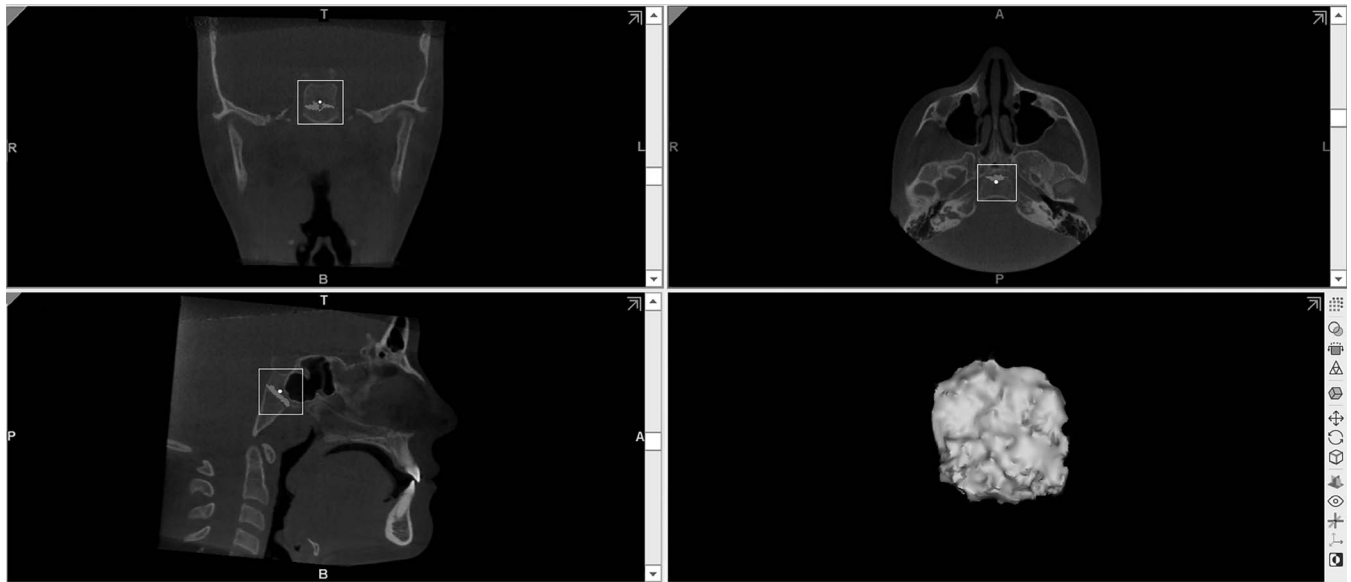


Figure 3. Procedure of segmentation of the sphenoid-occipital synchondrosis and generation of the 3D rendered model.

identified on the midsagittal plane to calculate the Nasion-Sella-Basion angle (Na-S-Ba°) (Figure 5).

STEP 3 Basion Displacement Measurement and Euclidean Distances Registration

The T0 and T1 CBCTs and the 3D models were imported into 3D Slicer software (version 4.11, <https://www.slicer.org>) to evaluate the displacement of Basion. In this regard, Basion was landmarked in the multiplanar sections and pre-labeled with a 0.2-mm spherical dot and inter-timing point-to-point displacement was assessed using the Q3DC extension of the

software.²¹ Displacement was considered as the linear projection in the multiplanar 2D Cartesian coordinates (X, Y, and Z) between time points. Positive and negative values (mm) indicated Basion displacement along the X, Y, and Z coordinates according to the following pattern:

- In the X direction, a negative value denoted lateral displacement while a positive denoted medial displacement.
- In the Y direction, a negative value denoted posterior displacement and a positive value denoted anterior displacement.

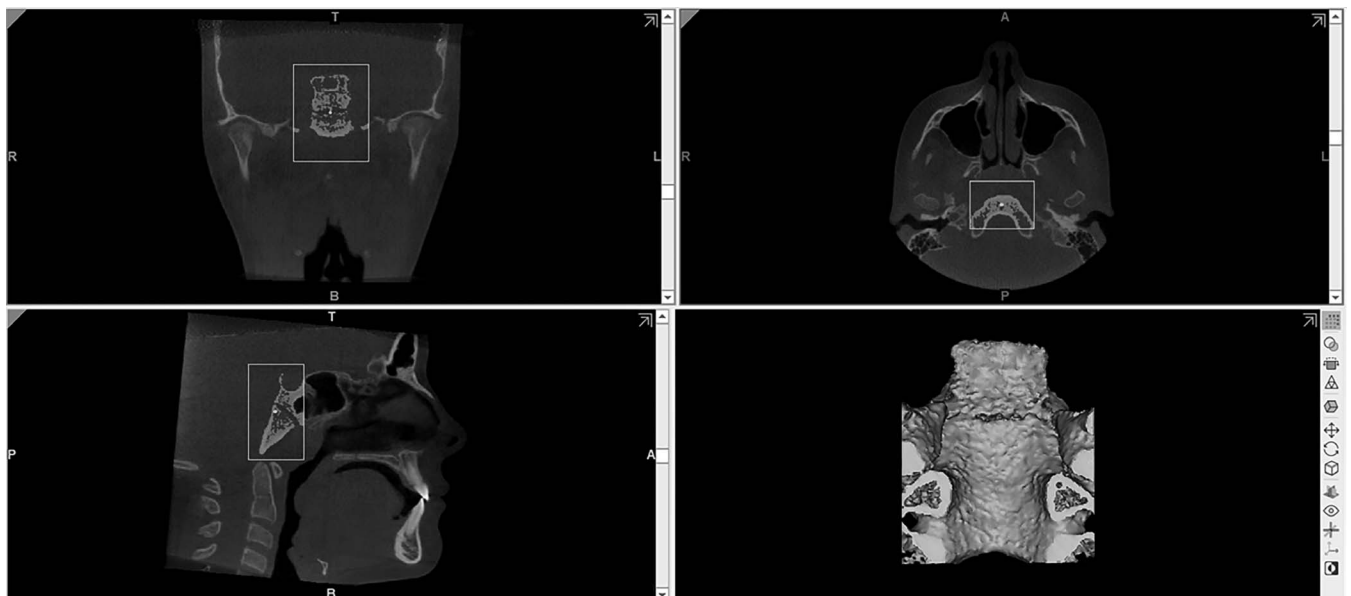


Figure 4. Procedure of segmentation of the basilar part of the occipital bone and generation of the 3D rendered model.

Table 1. Inferential Statistics of the Volumetric Measurements of the Spheno-Occipital Synchondrosis Before Treatment (T0) and After Retention (T1) Stages^a

| Timing | N | Mean Volume (mm ³) | SD | 95% CI | | Significance* | |
|--------|----|--------------------------------|--------|-------------|-------------|---------------|----------------|
| | | | | Upper Limit | Lower Limit | | |
| TB | T0 | 20 | 431.84 | 69.68 | 399.23 | 464.45 | <i>P</i> < .05 |
| | T1 | 20 | 437.34 | 67.89 | 405.56 | 469.11 | |
| BB | T0 | 20 | 355.29 | 49.97 | 331.91 | 378.68 | <i>P</i> < .05 |
| | T1 | 20 | 363.13 | 52.96 | 338.35 | 387.92 | |

^a TB, tooth-borne group; BB indicates bone-borne group; CI, coefficient interval; N, sample number; SD, standard deviation.

* Significance set at *P* < .05 and based on paired Student's *t*-test.

- In the Z direction, a negative value denoted superior displacement and positive value denotes inferior displacement.
- Finally, the 3D changes (Euclidean distance) of Basion between time points were recorded.

Statistical Analysis

Calculation of sample size power was carried out using data from 20 subjects (10 in the TB group and 10 in the BB group). The analysis indicated that 28 patients were required to reach the 80% power to detect a mean difference of 0.32 mm in Basion displacement after RME with a confidence level of 95% and a beta error level of 20%. However, according to the inclusion criteria, 40 subjects were recruited, which increased the robustness of the data.

A preliminary evaluation of the normal distribution and equality of variance of the data was performed with Shapiro-Wilk normality test and Levene's test. Paired Student's *t*-test was used for inter-timing assessments, unpaired Student's *t*-test and Mann-Whitney *U*-test were used for intergroup comparisons.

Ten patients were randomly selected and the entire procedure was repeated by the same expert investigator (ALG) after 4 weeks. The same patients were also remeasured by a second expert operator (VR). Intra-examiner and interexaminer reliability were assessed using intraclass correlation coefficient (ICC) and the analysis of the method error was performed using Dahlberg's formula.

Table 2. Comparisons of Mean Changes of the Spheno-Occipital Synchondrosis Volume Between Tooth-Borne (TB) and Bone-Borne (BB) Groups^a

| Timing | Groups | N | Mean Differences (mm ³) | SD | Median Differences (mm ³) | Minimum | Maximum | Significance* |
|--------|--------|----|-------------------------------------|------|---------------------------------------|---------|---------|---------------|
| T0-T1 | TB | 20 | 5.50 | 8.45 | 9.51 | -13.10 | 23.85 | NS |
| | BB | 20 | 7.84 | 7.37 | 7.65 | -7.70 | 23.72 | |

^a N indicates sample number; SD, standard deviation; T0, before treatment; T1, after maxillary expansion; T2, after retention.

* Significance set at *P* < .05 and based Mann-Whitney *U*-test.

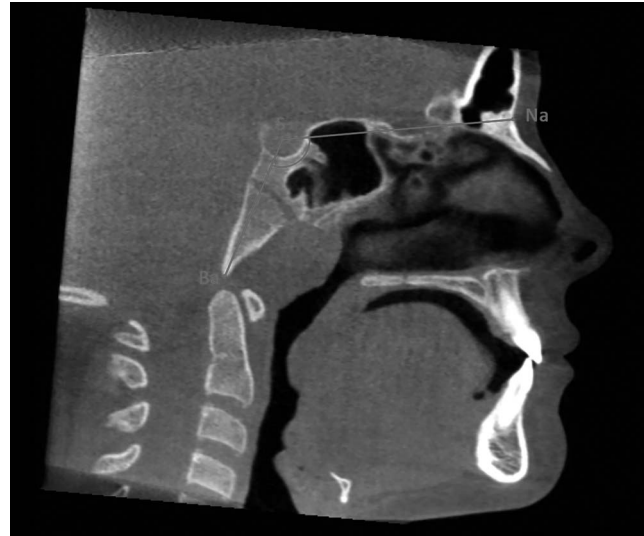


Figure 5. Identification of the Nasion, Sella, and Basion points on the midsagittal plane and calculation of the Nasion-Sella-Basion angle (Na-S-Ba°).

RESULTS

In both TB and BB groups, there was a slight increment of the volume of the SOS, which increased at T1; the changes were statistically significant in both groups (*P* > .05) (Table 1). However, no significant differences were found in the T0-T1 volumetric changes between the TB (5.50 mm³ ± 8.45) and BB (7.84 mm³ ± 7.37) groups (*P* > .05) (Table 2).

Both TB and BB groups showed a small increment of the N-S-Ba° at T1 that was statistically significant (*P* < .05) (Table 3). However, no significant differences were found in the T0-T1 changes of the N-S-Ba° values between the TB (0.62° ± 0.57) and BB (0.53° ± 0.43) groups (*P* > .05) (Table 4).

Table 5 shows the linear displacement of Basion between the T0 and T1 time points in the projected X, Y, Z axes and the Euclidean 3D distance. Positive values indicate displacement to the right (X), backward (Y), and upward (Z); negative values indicate displacement to the left (X), forward (Y), and downward (Z).

After RME, Basion showed a posterosuperior pattern of displacement with a mean displacement of 0.77 mm in the vertical plane, 0.54 mm in the sagittal plane, and

Table 3. Inferential Statistics of the Nasion-Sella-Basion (N-S-Ba[^]) Values Before Treatment (T0) and After Retention (T1) Stages^a

| | Timing | N | N-S-Ba | | 95% CI | | Significance* |
|----|--------|----|--------------|------|-------------|-------------|---------------|
| | | | Angle (Mean) | SD | Upper Limit | Lower Limit | |
| TB | T0 | 20 | 133.68 | 8.16 | 129.87 | 137.50 | $P < .05$ |
| | T1 | 20 | 134.30 | 8.24 | 130.44 | 138.16 | |
| BB | T0 | 20 | 131.91 | 7.11 | 128.58 | 135.24 | $P < .05$ |
| | T1 | 20 | 132.44 | 7.01 | 129.16 | 135.72 | |

^a TB, tooth-borne group; BB indicates bone-borne group; CI, coefficient interval; N, sample number; SD, standard deviation.

* Significance set at $P < .05$ and based on paired Student's *t*-test.

0 mm in the horizontal plane in the BB group and a mean displacement of 0.62 mm in the vertical plane, 0.52 mm in the sagittal plane, and 0.01 mm in the horizontal plane in the TB group. No statistically significant differences were found between the TB and BB groups in the 3D Euclidean changes of Basion as well as in the linear displacement along the Y axis ($P > .05$).

The reliability of the methodology was high, with correlation indices ranging from 0.889 to 0.987 between intra-operator readings and from 0.896 to 0.966 for interoperator readings. The random error ranged from 0.71 mm³ to 0.80 mm³ for volumetric measurements, from 0.01° to 0.02° for angular measurements, and from 0.01 mm to 0.005 mm for the assessment of three-dimensional (3D) displacement.

DISCUSSION

Cranial base synchondroses are regarded as important growth centers of the craniofacial skeleton, affecting development of the maxilla, midface, and lower facial complex.²² Therefore, the role of the SOS is of great importance since it completes the ossification process later than the intersphenoidal and ethmoidal synchondroses, which could increase its influence on the position of the maxillary-mandibular complex if modifications occur.²³

The factors governing the growth of synchondroses remain a controversial topic in the literature. Some researchers associated SOS with the epiphyseal cartilage in the lone bone growth plate and thus considered SOS as an independent growth center of the cranium. Others asserted that the growth pattern of

SOS was influenced by external mechanical force as demonstrated in organ culture studies.²⁴ In this regard, chondrocytes of the cranial base cartilage are sensitive to exogenous mechanical stimuli, and the increase in the recruitment of osteoblasts and chondroclasts directly contributes to the removal of cartilage and the deposition of bony tissues, leading to enhanced endochondral ossification in the SOS.⁸

Accordingly, the involvement of the SOS during expansion therapy has important research and clinical implications, which could explain the useful treatment effect of RME in certain malocclusions. In fact, the opening of the SOS could account for the forward and downward movement of the midface during RME therapy, and this could be favorable for Class III malocclusion patients.^{11,13}

Recent evidence suggested that BB expanders seemed to produce greater orthopedic effects compared to TB expanders.¹⁴ Such differences could be attributed to the different treatment concepts since BB expanders are attached to the bones while TB expanders are anchored to the dentition, which can lead to the difference in the tensile forces transmitted to further structures. Thus, the knowledge of whether BB RME can produce greater orthopedic changes at the SOS level compared to the TB RME appears of clinical relevance since it would help clinicians in choosing the type of expander appliance according to specific clinical conditions.

To achieve consistent results, voxel-based superimposition¹⁶ was used, identifying the anterior cranial base as the gold-standard reference area for the present study since previous evidence reported that its growth is completed at nearly the age of 7.²³ When comparing the two different treatment modalities, RME showed a similar effect on the SOS since the Basion landmark was displaced posteriorly and superiorly in both the TB and BB groups. Similarly, the Na-S-Ba angle and SOS volume slightly increased with TB and BB expanders.

The findings are hardly comparable with finite element method (FEM) studies,⁵⁻⁷ as FEM has some limitations. When the FEM model is constructed, the thickness and morphology of any scanned data are transformed to the finite element model, through the mathematical and computational model creation, thus attempting to simulate real-life conditions.

Table 4. Comparisons of Mean Changes of Nasion-Sella-Basion (N-S-Ba[^]) Angle Between Tooth-Borne (TB) and Bone-Borne (BB) Groups^a

| Timing | Groups | N | Mean Differences N-S-Ba (°) | SD | Median Differences N-S-Ba (°) | Minimum | Maximum | Significance* |
|--------|--------|----|-----------------------------|------|-------------------------------|---------|---------|---------------|
| T2-T0 | TB | 20 | 0.62 | 0.57 | 0.67 | -0.80 | 1.64 | NS |
| | BB | 20 | 0.53 | 0.43 | 0.43 | -0.44 | 1.72 | |

^a N indicates sample number; SD, standard deviation; T0, before treatment; T1, after maxillary expansion; T2, after retention.

* Significance set at $P < .05$ and based Mann-Whitney *U*-test.

Table 5. Comparison of the X, Y, Z, and 3D Changes of Basion Between Pretreatment (T0) and Post-Retention (T2) Stages^a

| | Coordinates | Groups | Mean (mm) | SD | Median (mm) | Minimum (mm) | Maximum (mm) | Differences Mean (mm) | Significance* |
|-------|-------------|--------|-----------|------|-------------|--------------|--------------|-----------------------|---------------|
| T0-T1 | x | TB | 0.01 | 0.02 | 0.00 | -0.03 | 0.05 | 0.01 | NS |
| | | BB | 0.00 | 0.03 | 0.01 | -0.12 | 0.02 | | |
| | y | TB | 0.52 | 0.19 | 0.55 | 0.17 | 0.87 | 0.02 | NS |
| | | BB | 0.54 | 0.28 | 0.49 | 0.07 | 1.06 | | |
| | z | TB | 0.62 | 0.25 | 0.58 | 0.24 | 1.01 | 0.15 | NS |
| | | BB | 0.77 | 0.44 | 0.74 | 0.18 | 1.70 | | |
| | 3D | TB | 0.81 | 0.30 | 0.81 | 0.29 | 1.33 | 0.17 | NS |
| | | BB | 0.98 | 0.43 | 0.97 | 0.34 | 1.77 | | |

^a BB indicates bone-borne; SD, standard deviation; TB, tooth-borne.

* Significance set at $P < .05$ and based on paired Student's *t*-test.

The scientific evidence regarding the immediate changes in the SOS is very limited. In the study of Lagravere et al.,²⁵ the age range tested, and consequently the degree of maturity of the SOS, differed compared to this study. Additionally, that study analyzed different areas of the sphenoid bone and not the Basion displacement nor SOS volume. On the other hand, results from the current investigation were in agreement to some extent with those from the study of Leonardi et al.¹¹ and those obtained by Silvestrini-Biavati¹² on lateral cephalometric x-rays taken 1 year after treatment. In this study, the effects of BB and TB RME on SOS were described in 3D according to CBCT and voxel-based superimposition, in the short term. The findings were that one appliance was not different from the other in its influence on the SOS, since differences in SOS volume, Basion displacement, and Na-S-Ba° changes between TB and BB were very small and clinically negligible. As a consequence, within the limitations of this study, it could be assumed that different expander designs should not interfere with the influence of the SOS on the maxilla-mandibular position.

Limitations

The absence of a control group was the main limitation of the present study. In this regard, age-matched untreated controls would have provided information about normal changes occurring at SOS. However, due to ethical concerns, unnecessary or additional radiation exposure to the patients was avoided^{26,27} and the retrieved materials made possible a comparison between two expander groups.

The acquisition protocol included an isotropic voxel size of 0.3 mm and a slight underestimation of the SOS volume could not be excluded due to the documented effect of mean partial volume computation.²⁸ However, since subjects in both groups were scanned with the same CBCT unit, this potential limitation did not affect the reliability of comparative data.

CONCLUSIONS

- TB and BB RME appliance resulted in an increase of Na-S-Ba angle and SOS volume while the Basion landmark was displaced posteriorly and superiorly in the short term. These effects were similar between the two types of maxillary expanders and the differences between them were very small and clinically negligible.

REFERENCES

1. Liu S, Xu T, Zou W. Effects of rapid maxillary expansion on the midpalatal suture: a systematic review. *Eur J Orthod.* 2015;37:651–655.
2. Bucci R, D'Anto V, Rongo R, Valletta R, Martina R, Michelotti A. Dental and skeletal effects of palatal expansion techniques: a systematic review of the current evidence from systematic reviews and meta-analyses. *J Oral Rehabil.* 2016;43:543–564.
3. Lin L, Ahn HW, Kim SJ, Moon SC, Kim SH, Nelson G. Tooth-borne vs bone-borne rapid maxillary expanders in late adolescence. *Angle Orthod.* 2015;85:253–262.
4. Ghoneima A, Abdel-Fattah E, Hartsfield J, El-Bedwehi A, Kamel A, Kula K. Effects of rapid maxillary expansion on the cranial and circummaxillary sutures. *Am J Orthod Dentofacial Orthop.* 2011;140:510–519.
5. Holberg C. Effects of rapid maxillary expansion on the cranial base—an FEM-analysis. *J Orofac Orthop.* 2005;66:54–66.
6. Boryor A, Geiger M, Hohmann A, Wunderlich A, Sander C, Martin Sander F, et al. Stress distribution and displacement analysis during an intermaxillary disjunction—a three-dimensional FEM study of a human skull. *J Biomech.* 2008;41:376–382.
7. Jafari A, Shetty KS, Kumar M. Study of stress distribution and displacement of various craniofacial structures following application of transverse orthopedic forces—a three-dimensional FEM study. *Angle Orthod.* 2003;73:12–20.
8. Lei WY, Wong RW, Rabie AB. Factors regulating endochondral ossification in the sphenoid-occipital synchondrosis. *Angle Orthod.* 2008;78:215–220.
9. Gardner GE, Kronman JH. Cranioskeletal displacements caused by rapid palatal expansion in the rhesus monkey. *Am J Orthod.* 1971;59:146–155.

10. Baydas B, Yavuz I, Uslu H, Dagsuyu IM, Ceylan I. Nonsurgical rapid maxillary expansion effects on craniofacial structures in young adult females. A bone scintigraphy study. *Angle Orthod.* 2006;76:759–767.
11. Leonardi R, Cutrera A, Barbato E. Rapid maxillary expansion affects the spheno-occipital synchondrosis in youngsters. A study with low-dose computed tomography. *Angle Orthod.* 2010;80:106–110.
12. Silvestrini-Biavati A, Angiero F, Gambino A, Ugolini A. Do changes in spheno-occipital synchondrosis after rapid maxillary expansion affect the maxillomandibular complex? *Eur J Paediatr Dent.* 2013;14:63–67.
13. Garib DG, Henriques JF, Carvalho PE, Gomes SC. Longitudinal effects of rapid maxillary expansion. *Angle Orthod.* 2007;77:442–448.
14. Krusi M, Eliades T, Papageorgiou SN. Are there benefits from using bone-borne maxillary expansion instead of tooth-borne maxillary expansion? A systematic review with meta-analysis. *Prog Orthod.* 2019;20:9.
15. Ghoneima A, Cho H, Farouk K, Kula K. Accuracy and reliability of landmark-based, surface-based and voxel-based 3D cone-beam computed tomography superimposition methods. *Orthod Craniofac Res.* 2017;20:227–236.
16. Bazina M, Cevidanes L, Ruellas A, Valiathan M, Queresby F, Syed A, et al. Precision and reliability of Dolphin 3-dimensional voxel-based superimposition. *Am J Orthod Dentofacial Orthop.* 2018;153:599–606.
17. Alhazmi A, Vargas E, Palomo JM, Hans M, Latimer B, Simpson S. Timing and rate of spheno-occipital synchondrosis closure and its relationship to puberty. *PLoS One.* 2017;12:e0183305.
18. Kavand G, Lagravere M, Kula K, Stewart K, Ghoneima A. Retrospective CBCT analysis of airway volume changes after bone-borne vs tooth-borne rapid maxillary expansion. *Angle Orthod.* 2019;89:566–574.
19. Obelenis Ryan DP, Bianchi J, Ignacio J, Wolford LM, Goncalves JR. Cone-beam computed tomography airway measurements: Can we trust them? *Am J Orthod Dentofacial Orthop.* 2019;156:53–60.
20. Guijarro-Martinez R, Swennen GR. Three-dimensional cone beam computed tomography definition of the anatomical subregions of the upper airway: a validation study. *Int J Oral Maxillofac Surg.* 2013;42:1140–1149.
21. Okano KS, Cevidanes LHS, Cheib PL, de Oliveira Ruellas AC, Yatabe M, Nguyen T, et al. Three-dimensional assessment of the middle cranial fossa and central skull base following Herbst appliance treatment. *Angle Orthod.* 2018;88:757–764.
22. Currie K, Sawchuk D, Saltaji H, Oh H, Flores-Mir C, Lagravere M. Posterior cranial base natural growth and development: a systematic review. *Angle Orthod.* 2017;87:897–910.
23. Sejrsen B, Jakobsen J, Skovgaard LT, Kjaer I. Growth in the external cranial base evaluated on human dry skulls, using nerve canal openings as references. *Acta Odontol Scand.* 1997;55:356–364.
24. Proffit WRF, Fields, HW, Sarver DM. Section II, the development of orthodontic problems. In: *Contemporary Orthodontics*. 4th ed. Mosby, Elsevier, St. Louis, MO, USA. 2007;99–102.
25. Afrand M, Oh H, Flores-Mir C, Lagravère-Vich MO. Growth changes in the anterior and middle cranial bases assessed with cone-beam computed tomography in adolescents. *Am J Orthod Dentofacial Orthop.* 2017;151:342–350 e342.
26. Jaju PP, Jaju SP. Cone-beam computed tomography: time to move from ALARA to ALADA. *Imaging Sci Dent.* 2015;45:263–265.
27. Yeung AWK, Jacobs R, Bornstein MM. Novel low-dose protocols using cone beam computed tomography in dental medicine: a review focusing on indications, limitations, and future possibilities. *Clin Oral Investig.* 2019;23:2573–2581.
28. Garib DG, Calil LR, Leal CR, Janson G. Is there a consensus for CBCT use in Orthodontics? *Dental Press J Orthod.* 2014;19:136–149.