

LETTER

Polymorphic eruption of pregnancy as a possible COVID-19 manifestation

Dear Editor,

Coronavirus disease 2019 (COVID-19) outbreak, caused by the severe acute respiratory syndrome coronavirus 2 (SARS-CoV-2), started in December 2019 in Wuhan, Hubei Province of China. On 11 March 2020, the World Health Organization (WHO) declared it a pandemic.¹ According to the WHO, 80% of SARS-CoV-2 infections are mild or asymptomatic, 15% are severe (requiring oxygen therapy) and 5% are critical (requiring mechanical ventilation).² Fever and cough are the most common signs reported among symptomatic patients.³ To date, many cutaneous manifestations have been signaled: erythematous, varicelliform, morbilliform, petechial and urticarial rashes.⁴⁻⁶ Pregnant women represent a high-risk population, due to physiological and mechanical changes characteristic of gestation. In particular, T-helper 2 system dominance, though protecting the fetus, makes pregnant woman more susceptible to infections. The most common signs of SARS-CoV-2 infection during gestation, similarly to general population, are fever, cough, dyspnea and lymphopenia.⁷ However, COVID-19 cutaneous manifestations in pregnant and lactating patients have not yet been adequately investigated in the literature.

We report the case of a 32-year-old Caucasian woman who presented to our attention complaining about a pruritic rash on abdomen and breasts. She also reported to be affected by headache and diarrhea for a few days. Five days before, at 39 and 2/7 weeks of pregnancy, she had delivered eutocically a baby girl with Apgar score of 9. Ten days before childbirth, giving the fact that her husband was affected by COVID-19, she had been screened for COVID-19; reverse transcriptase-polymerase chain reaction showed that she was positive. Her medical and pharmacological history was otherwise unremarkable. Physical examination revealed confluent non-scaly erythematous macules and papules limited to almost the entire skin surface of breasts and supraumbilical quadrants of the abdomen, with sparing of the linea alba (Figure 1). She denied any respiratory symptom and her thoracic physical examination resulted normal. Her body temperature was 37.5°C and O₂ saturation 97% (pulse oximetry). Routine laboratory findings were within normal limits, except for a mild sideropenic anemia. A therapy with betamethasone was initiated (1 mg, 3 cp/die), but it was interrupted after 5 days because of cutaneous rash progression. Instead of betamethasone, methylprednisolone was prescribed (16 mg, 2 cp/die for 3 days and then tapered off slowly). After 3 days of therapy, cutaneous rash has considerably improved (Figure 2). Her body temperature is 36.5°C and her thoracic physical examination remains normal. Nevertheless, the patient has been rescreened for COVID-19 and her results are still positive.

Clinically, the patient's cutaneous eruption was consistent with the diagnosis of "pruritic urticarial papules and plaques of pregnancy"

(PUPPP): pruritic small erythematous and edematous macules and papules first started in the stretch marks of the trunk and then coalesced to form larger urticarial plaques often surrounded by blanched halos, with periumbilical sparing. PUPPP is the most common benign gestational dermatosis. Nevertheless, PUPPP presenting in the postpartum period, such as in our patient, is extremely rare. In fact, in most cases, it occurs during the last trimester of pregnancy, especially in primigravidas, resolving spontaneously after an average of 4 weeks or with delivery. In addition, the detection of abdominal striae distensae is relevant for differential diagnosis; however, these lesions were not observed in this case.⁸

Moreover, our patient referred that fever, headache and diarrhea had started simultaneously with the cutaneous rash, suggesting the assumption of the role of SARS-CoV-2 in its pathogenesis. Furthermore, prompt regression of the rash with high doses of corticosteroids, even if the patient is still infective, leads us to suspect an hypersensitivity reaction against viral antigens as a possible pathogenetic mechanism.

In conclusion, hormonal and immune changes characteristic of pregnancy could affect COVID-19 cutaneous manifestations and it would be advisable to investigate them, particularly in this critical period of pandemic.

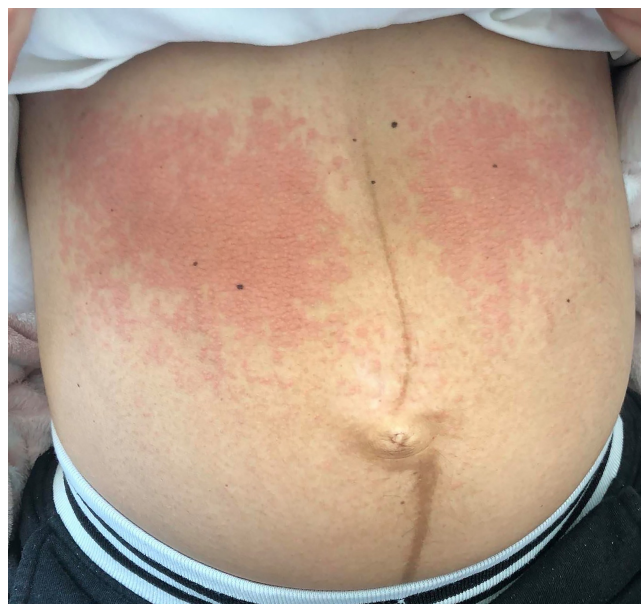

FIGURE 1 Erythematous macules and papules on the supraumbilical quadrants of the abdomen, with sparing of the linea alba

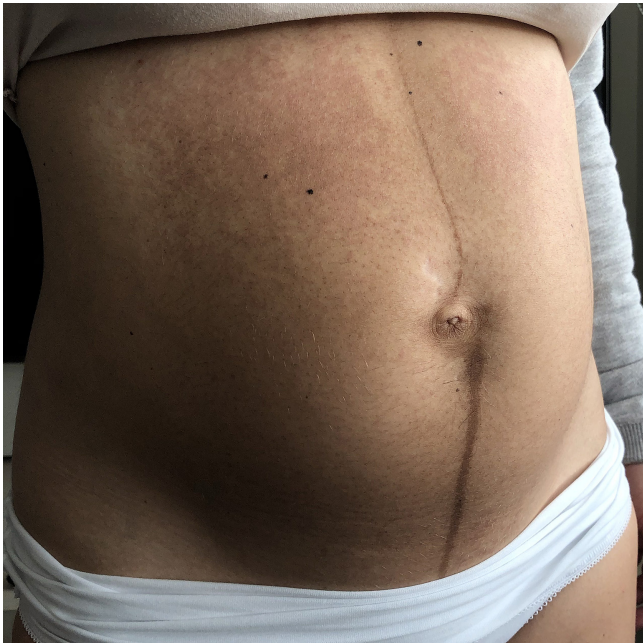







FIGURE 2 Considerable improvement of the skin rash after 3 days of therapy

ACKNOWLEDGMENT

The patient in this manuscript has given written informed consent for publication of her case details.

CONFLICT OF INTEREST

The authors declare no conflicts of interest.

Ilaria Proietti 
 Nicoletta Bernardini
 Ersilia Tolino 
 Alessandra Mambrin
 Veronica Balduzzi
 Anna Marchesiello 
 Simone Michelini 
 Nevena Skroza 
 Concetta Potenza

Department of Medical-Surgical Sciences and Biotechnologies,
 Dermatology Unit "Daniele Innocenzi", Sapienza University of Rome, Polo
 Pontino, Italy

Correspondence

Dr Ilaria Proietti, Dermatology Unit "Daniele Innocenzi", "A. Fiorini"
 Hospital, Via Firenze, 1, 04019, Terracina (LT), Italy.
 Email: proiettilaria@gmail.com

ORCID

Ilaria Proietti  <https://orcid.org/0000-0003-3795-3190>

Ersilia Tolino  <https://orcid.org/0000-0001-7861-9338>

Anna Marchesiello  <https://orcid.org/0000-0002-5863-4829>

Simone Michelini  <https://orcid.org/0000-0002-3374-7384>

Nevena Skroza  <https://orcid.org/0000-0003-4478-5404>

REFERENCES

1. World Health Organization. Rolling updates on coronavirus disease (COVID-19). <https://www.who.int/emergencies/diseases/novel-coronavirus-2019/events-as-they-happen>. Accessed March 24, 2020.
2. World Health Organization. WHO coronavirus disease 2019 (COVID-19) situation report 46. https://www.who.int/docs/default-source/coronaviruse/situation-reports/20200306-sitrep-46-covid-19.pdf?sfvrsn!496b04adf_2. Accessed March 14, 2020.
3. Guan W-J, Ni Z-Y, Hu Y, et al. Clinical characteristics of coronavirus disease 2019 in China. *N Engl J Med*. 2020;382(18):1708-1720. <https://doi.org/10.1056/NEJMoa2002032>.
4. Recalcati S. Cutaneous manifestations in COVID-19: a first perspective. *J Eur Acad Dermatol Venereol*. 2020;34(5):e212-e213. <https://doi.org/10.1111/jdv.16387>.
5. Hunt M, Koziatek C. A case of COVID-19 pneumonia in a young male with full body rash as a presenting symptom. *Clin Pract Cases Emerg Med*. 2020;4(2):219-221. <https://doi.org/10.5811/cpcem.2020.3.47349>.
6. Joob B, Wiwanitkit V. COVID-19 can present with a rash and be mistaken for dengue. *J Am Acad Dermatol*. 2020;82(5):177. <https://doi.org/10.1016/j.jaad.2020.04.016>.
7. Dashraath P, Wong J-L-J, Lim M-X-K, et al. Coronavirus disease 2019 (COVID-19) pandemic and pregnancy. *Am J Obstet Gynecol*. 2020;222(6):521-531. <https://doi.org/10.1016/j.ajog.2020.03.021>.
8. Kim EH. Pruritic urticarial papules and plaques of pregnancy occurring postpartum treated with intramuscular injection of autologous whole blood. *Case Rep Dermatol*. 2017;9(1):151-156. <https://doi.org/10.1159/000473874>.