

# Anal excision of perianal fibroadenoma: Expect the unexpected

SAGE Open Medical Case Reports  
Volume 9: 1–3  
© The Author(s) 2021  
Article reuse guidelines:  
sagepub.com/journals-permissions  
DOI: 10.1177/2050313X211035568  
journals.sagepub.com/home/sco



Chiara Eberspacher , Francesco Nardi, Lisa Fralleone and Domenico Mascagni

## Abstract

Breast fibroadenomas are a common benign tumour in women that may need to be surgically excised. A mammary-like fibroadenoma can exceptionally be found in the pathological report after an anal polyp removal. A 60-year-old woman presented with huge anal polyp of 25 mm. It was surgically removed transanally. Histologic examination revealed a breast fibroadenoma pattern with glandular structures. Proctologist specialists must be aware that mammary-like tumours are a possible differential diagnosis for anal masses despite their rarity in the literature.

## Keywords

Anal fibroadenoma, anal polyp, perianal mammary-like fibroadenoma

Date received: 14 December 2020; accepted: 7 July 2021

## Introduction

Breast fibroadenomas are common in women, as is their standard removal. However, finding a histological report of a mammary-like fibroadenoma after surgical excision of a large polyp of the distal anal canal is exceptional. Anogenital mammary-like tumours derive from ectopic mammary tissue or normal adnexal structures of this skin area. These tumours can be found in both sexes but are more common in females, and they are benign more often than malignant.<sup>1</sup> In the literature, there are some reports of different anogenital mammary-like tumours, from fibroadenoma to phyllodes tumour:<sup>2</sup> Kazakov et al.<sup>3</sup> reported the most extensive series of 13 fibroepithelial neoplasms involving anogenital mammary-like glands; 4 of that were low-grade malignant and 1 recurrent. This article describes the case of a huge perianal mammary-like fibroadenoma that was operated on in a female patient. In addition, this article reviews and discusses the literature and the pathological and clinical implications of this rare condition.

## Case report

A 60-year-old woman with an anal mass of 25 millimetres (mm) maximum diameter, which had already been revealed 20 years ago and had been increasing in size over time, presented at the outpatient room for recent rectal bleeding and pain during and after defecation. She had a medical history

of hypertension and no previous surgery. Patient underwent periodic mammography screening without evidence of any mammary lesion in the past.

Physical examination of the anorectal and perianal region was performed with the patient in the left lateral decubitus position (Sims' position). At the 5 o'clock position in the left posterolateral region, a polypoid lesion of 25 mm maximum diameter was attached to the distal anal canal wall, with a base which measured approximately 20 mm (Figure 1). This mass was covered with normal skin; the patient did not experience spontaneous or induced pain or bleeding. The lesion's consistency was fibrotic without soiling or pus emission. A fissure was demonstrated in the anus posteriorly in the anal canal, likely cause of the patient's symptoms (i.e. bleeding and pain at defecation) and of the proctologic visit request.

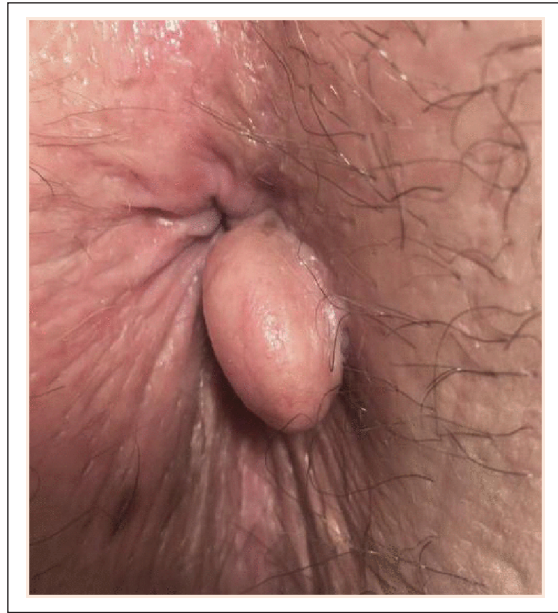
In the operation theatre, the patient was submitted to a colonoscopy (in propofol) to confirm the absence of any other lesion of the colon and rectum. Then, after local anaesthesia (n°10 mL naropin 7.5 mg/mL and n°10 mL lidocaine 1%) was given, the perianal mass was removed using diathermy without any bleeding. The mass did not

Department of Surgical Sciences, 'Sapienza' University of Rome, Rome, Italy

### Corresponding Author:

Chiara Eberspacher, Department of Surgical Sciences, 'Sapienza' University of Rome, Viale Regina Elena, 324, 00100 Rome, Italy.  
Email: chiara.eberspacher@gmail.com





**Figure 1.** The polypoid perianal lesion.

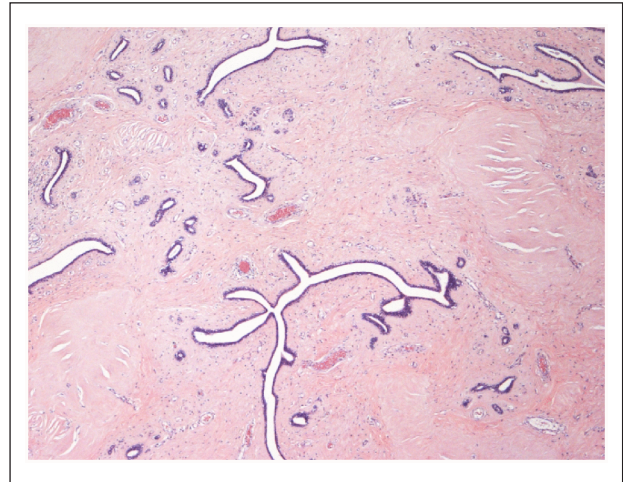
involve anal sphincter or other muscular structures. No stitches were applied: the wound was left open. The mass was capsulated and was not cut by the surgeon; it was given ‘en bloc’ to the pathologist. The surgeon believed that a benign tumour (leiomyoma) or a big fibrotic haemorrhoidal pile had been removed. The postoperative course was uneventful.

The mass was completely removed, as confirmed both by the surgeon and a pathologist. Macroscopically, it was a polypoid lesion, oval, well-circumscribed, covered by regular skin, fibrous, firm in consistency and grey-white on the cut surface. It measured 25 mm × 15 mm × 20 mm.

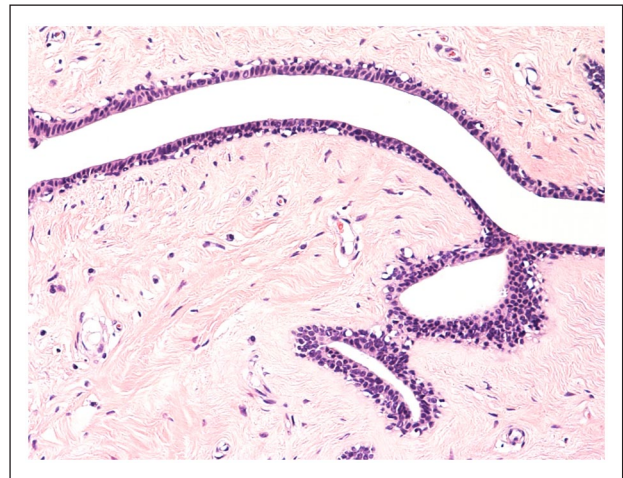Histologic examination revealed a fibroepithelial proliferation with abundant fibrous stroma similar to breast fibroadenoma. Within the stroma, some glandular structures maintained a round configuration similar to a pericanalicular fibroadenoma, while others had an elongated ductular structure like the intracanalicular pattern of a fibroadenoma (Figure 2). The glands were covered by cuboidal/low columnar epithelial cells without cytologic atypia resting on a myoepithelial cell layer (Figure 3).

## Discussion

In 1991, van der Putte<sup>4</sup> described the presence of the anogenital mammary-like glands for the first time. These glands are located in the vulva, perineum and perianal areas and have varied histology – eccrine, apocrine and mammary – similar to the histology and immunophenotype of breast tumours. These anogenital mammary-like glands can be the origin of different breast lesions, including benign or malignant epithelial or stromal tumours. Fibroadenomas, as well



**Figure 2.** Histological examination revealed a fibroepithelial proliferation with abundant fibrous stroma and glandular structures (H&E, ×40).



**Figure 3.** Glands covered by cuboidal/low columnar epithelial cells resting on a myoepithelial cell layer (H&E, ×100).

as other mammary-like gland tumours (e.g. Paget’s disease, lobular intraductal and phyllodes tumours), are found in the anogenital region.<sup>4,5</sup> They are typically found in female patients, but not always, and are more likely to be near the vulva than the anus.

Less than 50 cases of fibroadenomas of the anal region have been reported in the literature, and these polyps of the distal anal canal or the perianal region are usually asymptomatic with slow growth.<sup>6,7</sup> Only in some cases, it can become painful, especially if associated with an abscess; usually, no recurrence is reported after the excision, according to a review of case reports and literature.<sup>1,6</sup> Patients typically go to the proctologist only when the mass has become larger than 1 cm in size or when associated anorectal pathologies become symptomatic (like in the present case). The differential

diagnoses are usually haemorrhoids (i.e. fibrotic piles),<sup>8</sup> abscess or anal cancer.

## Conclusion

Knowing in advance whether the lesion is a mammary-like fibroadenoma polyp of the anal canal or the anal region is not necessary; this information does not change surgical planning and diagnosis of a fibroadenoma is usually only a histological ‘surprise’. Moreover, no additional postoperative therapy or particular follow-up is required for these patients. However, knowing that these mammary-like tumours, which are more frequently benign but can also rarely be malignant, can be located in the anal and perianal region is useful in providing a differential diagnosis of anal masses/polyps of this area.

## Author contributions

D.M. and C.E. contributed to the conceptualization, writing, final review and final approval. F.N. contributed to the acquisition, analysis of data, revision of the article critically for important intellectual content and final approval. L.F. contributed to the acquisition, interpretation of data, revision of the article and final approval.

## Availability of data and material

All data and material are available on request.

## Declaration of conflicting interests

The author(s) declared no potential conflicts of interest with respect to the research, authorship, and/or publication of this article.

## Ethical approval

Our institution does not require ethical approval for reporting individual cases or case series.

## Funding

The author(s) received no financial support for the research, authorship, and/or publication of this article.

## Informed consent

Written informed consent was obtained from the patient for her anonymized information to be published in this article.

## ORCID iD

Chiara Eberspacher  <https://orcid.org/0000-0001-7973-6990>

## References

1. Kazakov DV, Spagnolo DV, Kacerovska D, et al. Lesions of anogenital mammary-like glands: an update. *Adv Anat Pathol* 2011; 18(1): 1–28.
2. Ho SP, Tseng HH, King TM, et al. Anal phyllodes tumor in a male patient: a unique case presentation and literature review. *Diagn Pathol* 2013; 8: 49.
3. Kazakov DV, Spagnolo DV, Stewart CJ, et al. Fibroadenoma and phyllodes tumors of anogenital mammary-like glands: a series of 13 neoplasms in 12 cases, including mammary-type juvenile fibroadenoma, fibroadenoma with lactation changes, and neurofibromatosis-associated pseudoangiomatous stromal hyperplasia with multinucleated giant cells. *Am J Surg Pathol* 2010; 34(1): 95–103.
4. van der Putte SC. Mammary-like glands of the vulva and their disorders. *Int J Gynecol Pathol* 1994; 13(2): 150–160.
5. Grube-Pagola P, Gámez-Siu V, Maldonado-Barrón R, et al. Perianal fibroadenoma. *Colorectal Dis* 2012; 14: e633–e634.
6. Assor D and Davis J. Multiple apocrine fibroadenomas of the anal skin. *Am J Clin Pathol* 1977; 68(3): 397–399.
7. Choi WW, Tadros TS and Majmudar B. Anal fibroadenoma: report of a common tumor type in an unusual location. *South Med J* 2007; 100(9): 914–915.
8. Mascagni P, Eberspacher C, Saraceno F, Felli et al. Routine pathology examination in the era of the value based health-care: the case of haemorrhoids specimens. *Updates Surg* 2020; 72(1): 83–88.