Digestive Diseases and Sciences
https://doi.org/10.1007/s10620-021-06966-8

DDS–SIRC COOPERATIVE CONFERENCES

CEing More—Assessing Small Bowel Crohn's with Capsule Endoscopy (CE)

Carlo Calabrese[1] · Nikolas Dussias[1] · Giovanna Impellizzeri[2] · Augusto Lauro[1] · Nico Pagano[1]

Accepted: 12 March 2021

Abstract

Introduction Small bowel involvement is very common in Crohn's disease. Ileocolonoscopy, cross-sectional imaging modalities, and video capsule endoscopy are the tools currently used to investigate such involvement.

Areas Covered Herein we report the case of a 47-year-old man with a history of ileocolic Crohn's disease and persistent, unexplained iron deficiency anemia.

Expert Commentary Capsule endoscopy, by accurately identifying small intestinal mucosal lesions, can improve outcomes.

Keywords Crohn's disease · Capsule endoscopy · Aphthous ulcers · Strictures · Iron deficiency anemia

Abbreviations

CD	Crohn's disease
EGD	Esophagous-gastro-duodenoscopy
Hgb	Hemoglobin
WBC	White blood cell count
MCV	Mean corpuscular volume
CE	Capsule endoscopy
CTE	Computed tomography enterography
MRE	Magnetic resonance enterography
IBD	Inflammatory bowel disease
PC	Patency capsule

Case Presentation and Evolution

We report a case of a 47-year-old man affected by ileocolic Crohn's disease (CD) since age 24, previously treated in 1998 with ileocolic resection. Past medical history included hypertension and osteopenia, treated by angiotensin receptor blockers and vitamin D supplementation. He remained in good health during the following 20 years, except for flares treated with azathioprine. Due to worsening disease, a 50 cm resection of the ileocolic anastomosis was performed and an ileostomy created in August 2018. Four months later, he underwent reconnection with the creation of a new ileocolic anastomosis. Since 2019, the patient has had chronic iron deficiency anemia without evidence of overt gastrointestinal bleeding. An EGD revealed no evidence of a bleeding source, whereas ileocolonoscopy revealed a few 7–8 mm ulcers proximal to the anastomosis. Furthermore, capsule endoscopy (CE) revealed a patent, hyperemic anastomosis with the presence of at least three < 10 mm ulcerations. CE also showed a few < 10 mm ileal erosions proximal to the anastomosis. The patient was treated with oral iron and adalimumab (80 mg induction dose, followed by 40 mg per week). The patient was in good clinical condition with Hgb 11.3 g/dL for over one year, but on July, 2020, he became weak and fatigued, associated with presyncopal episodes. Severe anemia (Hgb 6.4 g/dL) was diagnosed which was treated with intravenous iron supplementation after which the Hgb increased to 10.8 g/dL (August 2020). A second ileocolonoscopy showed a normal 15 cm of pre-anastomotic ileum and ileocolic anastomosis, but detected a few friable small ulcers with a fibrinous base on the colonic side of the anastomosis. The remaining colonic and rectal mucosa appeared normal. In view of these findings, the patient, although asymptomatic, was admitted to our hospital. His abdomen was tender to palpation, with regular peristalsis. Laboratory values included a normal WBC, electrolytes (with the only exception of hypophosphatemia, treated with

A profile of Nikolas Dussias is available at https://doi.org/10.1007/s10620-021-06964-w.

✉ Augusto Lauro
augustola@yahoo.com

[1] IRCCS Azienda Ospedaliero-Universitaria di Bologna, Via Albertoni 15, Bologna, Italy

[2] Gastroenterology and Digestive Endoscopy Unit, Azienda USL Modena, Carpi, Italy

Published online: 09 April 2021

supplementation), and C-reactive protein. Hgb value was 10.9 g/dL, with a normal MCV and iron studies. Folate and vitamin B12 were normal although 25-hydroxy vitamin D at the lower limit of normal despite oral supplementation. A second gastroscopy did not show significant pathological findings, while CT enterography (CTE) showed a moderate wall thickening (≤5 mm) of the mid-upper rectum and on the ileal side of the ileo-colic anastomosis, with slight contrast hyperenhancement. Subcentimeter mesenteric lymphadenopathy was also described with no abnormal fluid collections or fistulas. The patient was discharged in stable condition with adalimumab 40 mg per week plus budesonide and vitamin D supplementation for 2 months.

After good intestinal preparation, a follow-up CE showed normal duodenal mucosa but, distal to the duodenum, erosions with aphthous ulcers and few deeper ulcerations were found together with a single non-ulcerated substenosis (Fig. 1). In the middle third of the small bowel, further aphthous ulcers and erosions were present, while in the lower third, the mucosa was focally edematous with ulcers present. The ileocolic anastomosis appeared edematous with 2 erosions, whereas the colonic mucosa was normal. The total Lewis score was 908, indicative of moderate–severe active jejunoileal CD. CE documented the true extent and severity of the disease that was underestimated by cross-sectional imaging. Due to the persistence of moderate–severe active disease, adalimumab was stopped due to secondary failure and the patient was switched to infliximab with induction of clinical remission, subsequent normalization and stabilization of Hgb values.

Discussion

CE is the most sensitive diagnostic modality for detecting mucosal lesions in suspected or established CD. According to Western population-based epidemiological studies, small bowel involvement occurs in > 50% of CD patients [1–5]. A complete evaluation of small bowel CD involvement requires a multimodal approach with optical and cross-sectional imaging studies. Though CTE and MRE are superior to endoscopy alone for assessing small bowel strictures, penetrating complications and transmural or extraluminal disease, the addition of CE enables assessment of small bowel mucosal disease that is below the diagnostic threshold of CTE/MRE and beyond the reach of standard endoscopy [6–10] (Table 1). Previous meta-analyses of Western populations demonstrated that CE has a higher diagnostic yield in suspected and established CD patients than do alternative modalities [11–13]. CE has the potential to identify the presence of active disease that may not be evident through conventional biomarkers, or to identify mucosal lesions that are not visible on cross-sectional imaging, adding diagnostic and prognostic information without the use of ionizing radiation [6, 14, 15]. In established CD, CE can be supportive in difficult

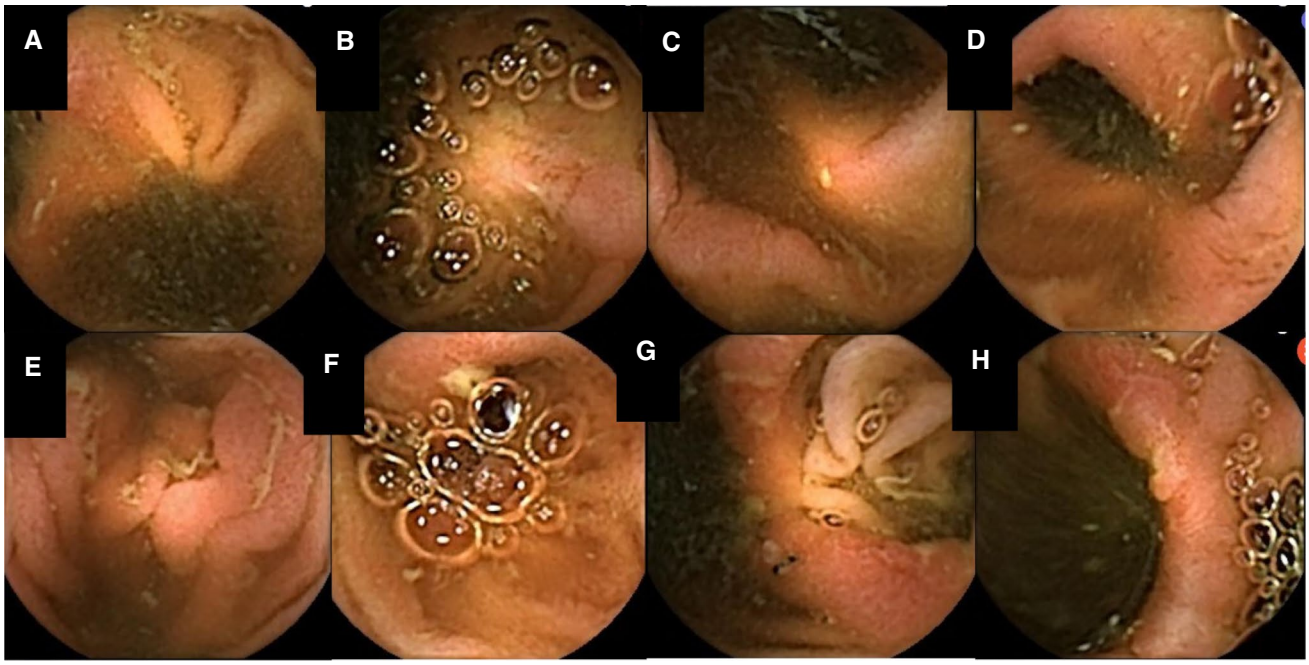

Fig. 1 **a–d** istal to the duodenum erosions and aphthous ulcers are present. **d** single transitable, non-ulcerated low-grade stricture. **e–f** In the lower third of small bowel, the mucosa appeared focally edematous, with the presence of ulcers. **g–h** Ileo-colic anastomosis appeared edematous, with two erosions

Table 1 International Literature: incremental yield of capsule endoscopy over the other modalities in patients with established Crohn's Disease [7–9]

	Yield of capsule endoscopy (%)	Yield of other modalities (%)	% Incremental yield for capsule endoscopy (95% CI)	NNT	P
vs Small bowel radiography	78	32	51 (0.31–0.70)	2	< 0.001
vs Ileoscopy	86	60	26 (0.08–0.43)	4	0.002
vs CT enterography	68	38	30 (0.12–0.48)	–	< 0.01

CT Computed tomography, *NNT* Number needed to treat

clinical situations, such as unexplained anemia, persistent symptoms, suspected postoperative recurrence, and diagnosing unclassified IBD, often leading to a change in management in a significant number of cases [6]. One of the major issues limiting the use of CE in established CD is the risk of CE retention; in two recent meta-analyses, the rate of retention in patients with suspected CD was 2.8% for adults [25] and 2.5% for pediatric patients [26], respectively. The use of a patency capsule (PC) reduces but does not eliminate the risk of retention. In established CD, the use of a PC is recommended to confirm functional patency of the small bowel [27]. In our case, we did not use a PC since there was no clinical or radiologic suggestion of luminal obstruction.

Conclusions

In this case, CE identified small bowel non-obstructing structures and ulcerations, providing the true extent of disease, whereas CTE significantly underestimated the extent of mucosal involvement. Without CE, surgery may have been considered, whereas when the true extent of disease was identified, the patient was successfully treated with alternate medical therapy. Since in CD patients CE provides information that can alter patient management, we suggest to use cross-sectional imaging techniques complementary to endoscopy in the evaluation of disease activity and complications, before making therapeutic decisions.

Key Messages

- Small bowel involvement is very common in CD.
- CE can often give essential additional information to other imaging modalities, which could change patient management.
- Cross-sectional imaging studies and CE are complementary strategies in assessing small bowel CD severity and extent.

Declarations

Conflict of interest All authors declare that they have no conflict of interest.

References

1. Vind I, Riis L, Jess T et al. Increasing incidences of inflammatory bowel disease and decreasing surgery rates in Copenhagen City and County, 2003–2005: a population-based study from the Danish Crohn colitis database. *Am J Gastroenterol* 2006;101:1274–1282.
2. Solberg IC, Vatn MH, Høie O et al. Clinical course in Crohn's disease: results of a Norwegian population-based ten-year follow-up study. *ClinGastroenterolHepatol* 2007;5:1430–1438.
3. Gower-Rousseau C, Vasseur F, Fumery M et al. Epidemiology of inflammatory bowel diseases: new insights from a French population-based registry (EPIMAD). *Dig Liver Dis* 2013;45:89–94.
4. Nuij VJ, Zelinkova Z, Rijk MC et al. Phenotype of inflammatory bowel disease at diagnosis in the Netherlands: a population-based inception cohort study (the Delta Cohort). *Inflamm Bowel Dis* 2013;19:2215–2222.
5. Sjöberg D, Holmström T, Larsson M et al. Incidence and clinical course of Crohn's disease during the first year: results from the IBD Cohort of the Uppsala Region (ICURE) of Sweden 2005–2009. *J Crohns Colitis* 2014;8:215–222.
6. Hansel SL, McCurdy JD, Barlow JM. Clinical benefits of capsule endoscopy in Crohn's disease. Impact on patient management and prevalence of proximal small bowel involvement. *Inflamm Bowel Dis.* 2018;24:1582–1588.
7. Triester SL, Leighton JA, Leontiadis GI et al. A meta-analysis of the yield of capsule endoscopy compared to other diagnostic modalities in patients with non-stricturing small bowel Crohn's disease. *Am J Gastroenterol* 2006;101:954–964.
8. Calabrese C, Diegoli M, Dussias N et al. Performance of capsule Endoscopy and cross-sectional techniques in detecting small bowel lesions in patients with Crohn's disease. *Crohn's Colitis* 2020;360:otta046.
9. Tontini GE, Rizzello F, Cavallaro F et al. Usefulness of panoramic 344-viewing in Crohn's disease capsule endoscopy: a proof of concept pilot study with the novel PillCam™Crohn's system. *BMC Gastroenterol* 2020;20:97.
10. Saibeni S, Rondonotti E, Iozzelli A et al. Imaging of the small bowel in Crohn's disease: a review of old and new techniques. *World J Gastroenterol* 2007;13:3279–3287.
11 Marmo R, Rotondano G, Piscopo R et al. Meta-analysis: capsule enteroscopy vs. conventional modalities in diagnosis of small bowel diseases. *Aliment PharmacolTher* 2005;22:595–604.
12. Dionisio PM, Gurudu SR, Leighton JA et al. Capsule endoscopy has a significantly higher diagnostic yield in patients with

suspected and established small-bowel Crohn's disease: a meta-analysis. *Am J Gastroenterol* 2010;105:1240–1248.
13. Park SK, Ye BD, Kim KO. Guidelines for video capsule endoscopy: emphasis on Crohn's disease. *ClinEndosc* 2015;48:128–135.
14. Lazarev M, Huang C, Bitton A et al. Relationship between proximal Crohn's disease location and disease behavior and surgery: a cross-sectional study of the IBD Genetics consortium. *Am J Gastroenterol.* 2013;108:106–112.
15 Flamant M, Trang C, Maillard O et al. A. The prevalence and outcome of jejunal lesions visualized by small bowel capsule endoscopy in Crohn's disease. *Inflamm Bowel Dis.* 2013;19:1390–1396.
16. Collins PD. Video capsule endoscopy in inflammatory bowel disease. *World J GastrointestEndosc.* 2016;8:477–488.
17. Kopylov U, Nemeth A, Koulaouzidis A et al. Small bowel capsule endoscopy in the management of established Crohn's disease: clinical impact, safety, and correlation with inflammatory biomarkers. *Inflamm Bowel Dis.* 2015;21:93–100.
18. Cohen SA, Gralnek IM, Ephrath H et al. The use of a patency capsule in pediatricCrohn's disease: a prospective evaluation. *Dig Dis Sci.* 2011;56:860–865.
19. Gralnek IM, Cohen SA, Ephrath H et al. Small bowel capsule endoscopy impacts diagnosis and management of pediatric inflammatory bowel disease: a prospective study. *Dig Dis Sci.* 2012;57:465–471.
20. Min SB, Le-Carlson M, Singh N et al. Video capsule endoscopy impacts decision making in pediatric IBD: a single tertiary care center experience. *Inflamm Bowel Dis.* 2013;19:2139–2145.
21. Dussault C, Gower-Rousseau C, Salleron J et al. Small bowel capsule endoscopy for management of Crohn's disease: a retrospective tertiary care centre experience. *Dig Liver Dis.* 2013;45:558–561.
22. Long MD, Barnes E, Isaacs K et al. Impact of capsule endoscopy on management of inflammatory bowel disease: a single tertiary care center experience. *Inflamm Bowel Dis* 2011;17:1855–1862.
23. Lorenzo-Zuniga V, de Vega VM, Domenech E et al. Impact of capsule endoscopy findings in the management of Crohn's disease. *Dig Dis Sci* 2010;55:411–414.
24. Santos-Antunes J, Cardoso H, Lopes S et al. Capsule enteroscopy is useful for the therapeutic management of Crohn's disease. *World J Gastroenterol* 2015;21:12660–12666.
25. Liao Z, Gao R, Xu C et al. Indications and detection, completion, and retention rates of small-bowel capsule endoscopy: a systematic review. *Gastrointest Endosc.* 2010;71:280–286.
26. Cohen SA, Klevens AI. Use of capsule endoscopy in diagnosis and management of pediatric patients, based on meta-analysis. *ClinGastroenterolHepatol.* 2011;9:490–496.
27. Pennazio M, Spada C, Ellakim R et al. Small-bowel capsule endoscopy and device-assisted enteroscopy for diagnosis and treatment of small bowel disorders: European Society of Gastrointestinal Endoscopy (ESGE) Clinical Guideline. *Endoscopy* 2015;47:352–376.