



Episode of massive pulmonary embolism after bilateral breast augmentation

Fabrizio Schonauer, Gisella Nele, Annalena Di Martino, Mariangela Santoro & Fabio Santanelli di Pompeo

To cite this article: Fabrizio Schonauer, Gisella Nele, Annalena Di Martino, Mariangela Santoro & Fabio Santanelli di Pompeo (2015) Episode of massive pulmonary embolism after bilateral breast augmentation, Case Reports in Plastic Surgery and Hand Surgery, 2:3-4, 80-83, DOI: 10.3109/23320885.2015.1112747

To link to this article: <http://dx.doi.org/10.3109/23320885.2015.1112747>



© 2015 The Author(s). Published by Taylor & Francis.



Published online: 10 Dec 2015.



Submit your article to this journal [↗](#)



Article views: 128



View related articles [↗](#)



View Crossmark data [↗](#)

CASE REPORT

 OPEN ACCESS

Episode of massive pulmonary embolism after bilateral breast augmentation

Fabrizio Schonauer^a, Gisella Nele^a, Annalena Di Martino^a, Mariangela Santoro^a and Fabio Santanelli di Pompeo^b

^aPlastic Surgery Unit, School of Medicine and Surgery, University "Federico II", Naples, Italy; ^bPlastic Surgery Unit, Sant'Andrea Hospital, School of Medicine and Psychology, "Sapienza" University of Rome, Rome, Italy

ABSTRACT

Pulmonary embolism is a rare postsurgical complication, even more so following breast augmentation. Herein we present a case of a 23-year-old woman who survived an episode of massive pulmonary embolism after breast implant surgery. Current literature about this subject is very scarce.

ARTICLE HISTORY

Received 19 August 2015
Accepted 21 October 2015

KEYWORDS

Pulmonary embolism, breast augmentation, thrombophilia, deep venous thrombosis

Introduction

Pulmonary embolism following breast augmentation surgery is a rare and life-threatening complication. Although guidelines regarding venous thromboembolism (VTE) risk assessment models and prophylactic measures can be found in published literature, they are not always applied to plastic surgery procedures. It can be assumed that this can be ascribed to a lack of knowledge about the real incidence of VTE and to the concern over other complications such as bleeding, secondary to anticoagulant prophylaxis [1].

Herein we report on a case of massive pulmonary embolism in a 23-year-old patient after bilateral breast implant surgery.

Case report

A 23-year-old patient presented at our clinic with breast hypoplasia and multiple bilateral fibroadenomas. Her clinical history did not reveal any previous history of deep venous thrombosis nor any family history of thrombotic event or disease. Chest X Ray, ECG, blood tests, clotting tests were performed pre-operatively and resulted normal. A pre-operative ultrasound scan revealed two fibroadenomas in the right breast and three in the left one. The patient was not on oral contraceptive treatment. Deep venous thrombosis risk was assessed and scored 1 (low risk) [2].

Thromboprophylaxis consisted of wearing anti-embolism stockings only.

Surgery was performed under general anaesthetic. An intravenous access was placed in her left median cubital vein. Fibroadenomas were excised through a hemiperiareolar access bilaterally. Allergan 275 g round textured implants were placed in a partial sub-pectoral pocket (dual plane technique). The operation lasted 1 h, 10 min. A compressive brassiere and a Velcro pressure bandage on top of the bra were positioned. The patient went home the following day. Drains were removed post-operatively on day 4 in the clinic (<30 ml/24 h) after draining a total of 210 cc on the right side and 190 cc on the left side.

On her way home that same evening, the patient experienced a syncopal episode and dyspnoea. Subsequently she was admitted to the Emergency Department of her local hospital. D-dimer tested positive (>400 ng/ml) and an Angio CT scan showed bilateral massive pulmonary embolism (Figures 1 and 2). Patient was started on thrombolytic treatment with rtPA and aggressive anti-coagulative treatment with IV unfractionated heparin (UFH) infusion (to target pTP around 50). An oral anti-coagulation with warfarin was started on the same day to target INR between 2.5 and 3.5. After 6 h the patient started to bleed at the breast drainage holes and developed an extremely large haematoma (Figure 3) in her left breast. After informed consent was signed, the

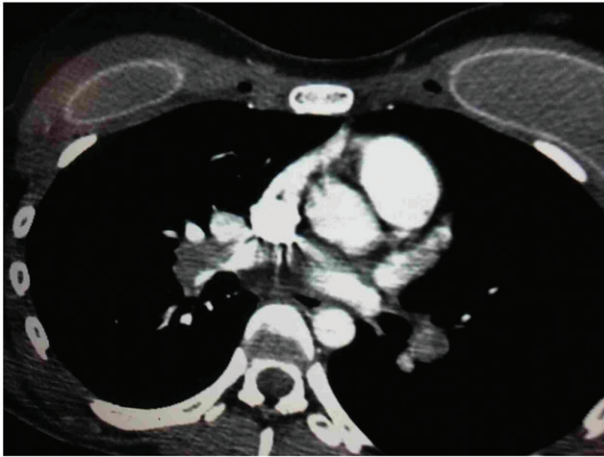

Figure 1. Axial angio CT image showing bilateral pulmonary embolism and the presence of breast implants.

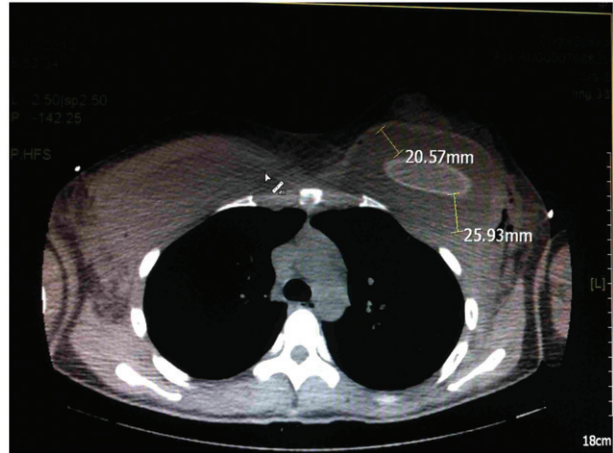


Figure 3. CT scan revealed the presence of haematoma with greatest dimensions of 20.57 mm and 25.93 mm.

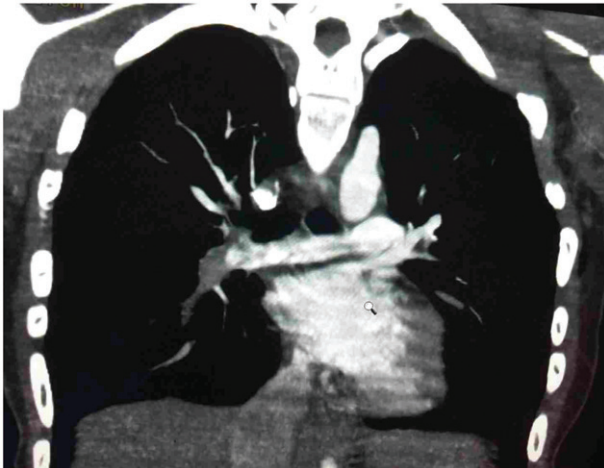


Figure 2. Coronal angio CT image showing pulmonary embolism.

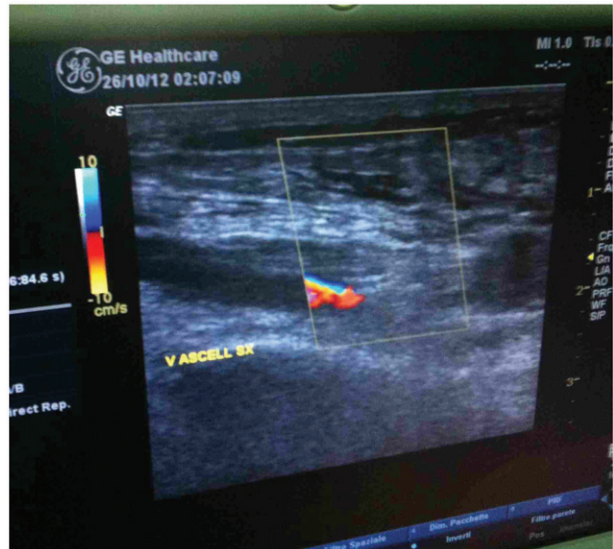


Figure 4. Color Doppler ultrasound scan showing a deep vein thrombosis in the left axillary vein.

patient was returned to the operating theatre where the left breast haematoma was drained. Patient's implants were bilaterally removed without replacement which permitted an aggressive chest pressure bandaging.

A Color Doppler ultrasound scan of upper and lower limbs showed a deep venous thrombosis in the left axillary vein (Figure 4). After breast implants removal, the patient spent 5 weeks in the hospital, first in the sub-intensive care and then in the cardiology unit. After her discharge from the hospital, the patient began rehab and anti-coagulative medications were prescribed. No further complications were reported.

Patient was then tested for hypercoagulability and her thrombophilia panel showed the presence of a number of mutations:

(1) heterozygosis for factor V R2 polymorphism (His1299Arg).

- (2) heterozygous carriers of the G20210A prothrombin gene mutation.
- (3) combined MTHFR C677T/A1298C genotype.

After a haematological evaluation the patient's mother showed the same mutations. At a 2-year follow-up an Angio CT scan showed a clear pulmonary arterial tree (Figure 5).

Patient refused any other plastic surgery procedure.

Discussion

In the UK great interest has arisen in the incidence rate of VTE episodes and pulmonary embolism (PE) events in the in-hospital patient population so as to encourage the establishment national guidelines [2]. VTE represents a well-documented surgical risk and includes two

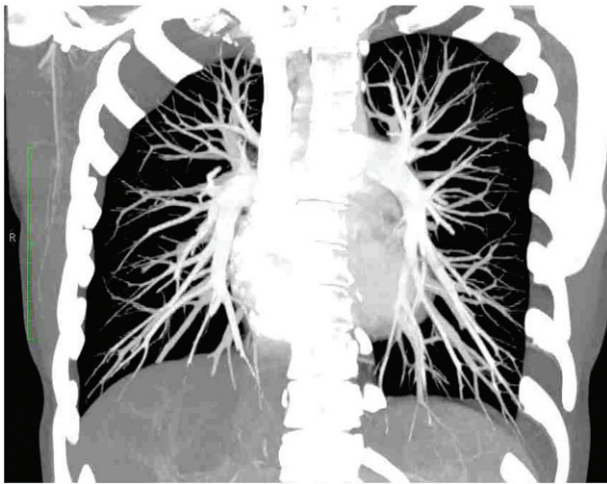


Figure 5. Two years' follow-up angio CT scan showing clear pulmonary tree.

conditions: deep vein thrombosis (DVT) and PE. Although there is less information about the risk of VTE and PE in plastic surgery than in other surgical specialties, a recent survey reported that 80% of plastic surgeons encountered DVT complications in their patients at least once in their career, whereas 53% experienced PE [3]. Breast augmentation is the most common plastic surgery cosmetic procedure in the USA. According to TOPS (Tracking operations and Outcomes for Plastic Surgeons) and CosmetAssure databases, rates of DVT or PE ranged from 0.02% to <0.01% for single-procedure breast augmentation [4].

In most reported cases DVT involved the lower extremities whereas for the upper extremities deep venous thrombosis (UEDVT) was considered a rare condition (4–10%). Pre-disposing factors for UEDVT include anatomic variations such as thoracic outlet syndrome, repeated micro trauma to the axillary-subclavian vein, malignancy, central venous catheters, parenteral nutrition, arm surgery or immobilization, oral contraceptive use and pregnancy. Moreover, the prevalence of coagulation abnormalities in patients with UEDVT ranges from 8% to 61%. Inherited thrombophilia was associated with a 5- to 6-fold increased risk of UEDVT in carriers of thrombophilia due to deficiencies of the naturally occurring anticoagulant proteins antithrombin III, protein C, or protein S and to the mutations of factor V (Factor V Leiden) and prothrombin (G20210). Association of thrombophilic mutations was found to be related to a higher risk of DVT [5].

Important limitations exist in establishing adequate guidelines for VTE prophylactic measures in plastic surgery as true VTE incidence is unknown and no agreement yet exists on dosage and timing of

prophylaxis [3]. Moreover, as large anatomical areas are dissected and anatomical pockets are created during plastic surgery procedures, there is still concern about possible secondary complications such as bleeding and haematoma after anticoagulant treatment [1].

The association between systemic anticoagulation and increased bleeding or haematoma formation is controversial. Despite the difficulty in predicting specific timing of the first dose and the duration of prophylaxis [3], a recent study suggests starting the treatment between 6 and 12 h after the procedure [1].

A common practice is to apply a compression thoracic dressing for the first week following a breast augmentation procedure so as to avoid blood collection at the implant pocket and to stabilize implants at the inframammary fold. However, such thoracic bandaging could cause micro trauma to the axillary-subclavian vein [5].

Several VTE risk assessment models (RAM), first group risk assessments and subsequently individual assessments [6], have been developed that seek to define the risk more accurately utilizing a patient-made score. The results can be used to determine several aspects of prophylaxis such as length, prophylactic agent and timing of a first dose.

In 2011 the American Society of Plastic Surgeons (ASPS) approved the Venous Thromboembolism Task Force Report [7]. The recommendations were divided into risk stratification based on the 2005 Caprini RAM and prevention [7]. Caprini RAM is a detailed individual risk assessment model that can be used to evaluate both medical and surgical patients. It was last updated in 2010 [6]. In the 2010 version of Caprini RAM, ~40 risk factors were listed with weights of 1–5 points each (including known thrombophilic status). The total risk factor score was then used to classify patients into four categories (low, moderate, high and highest risk), each with a recommended prophylactic regimen. Additional questions addressed prophylactic safety concerns about increased risks of bleeding [6]. The Caprini assessment tool has been clinically evaluated and supported by ASPS [7]. It has also been modified for specific use in patients undergoing plastic surgery and validated in a recent study [8].

Recently, an iOS app has been developed that can be easily applied to calculate risk and offer the appropriate preventive and therapeutic measures for each patient [9]. In our patient NICE guidelines [2] were used to evaluate VTE risk whereby the patient scored 1 (expected operating time >60 min, low risk of VTE), indicating that the prophylaxis therapy should consist of anti-embolism stockings only. However, it should be noted that, according to the 2010 Caprini RAM [6], our patient would have scored a 2 (Major surgery

[>45 min] = 2 points, moderate risk of VTE) which would have indicated a prophylaxis consisting of anti-embolism stockings and 2000 U.I. Enoxaparin sc. Moreover, the real deception of this demanding clinical case was that the thrombophilia state was unknown at the time. According to the British Committee for standards in Haematology, screening the general population for thrombophilia is not recommended due to the low incidence rate of this pathological condition and cost-effectiveness concerns [10].

Conclusion

Our report describes how a major complication such as pulmonary embolism can occur in a young patient with unknown risk factors. In our case, the thrombophilic status of the patient was not anticipated, so the patient was presumed low risk and the prophylactic regimen consisted solely in anti-embolism stockings in accordance with NICE guidelines. Based upon this experience it is important to emphasize that more restrictive risk assessment scores such as the Caprini score should be used, bearing in mind a possible higher risk of complications secondary to anticoagulant treatment such as bleeding and haematoma.

Our case serves as a warning about the risk of VTE in breast implant surgery, making it paramount to evaluate each patient more closely, employing more restrictive risk assessment tools.

Declaration of interest

The authors report no conflicts of interest. The authors alone are responsible for the content and writing of this article.

References

- [1] Seruya M, Baker SB. MOC-PS(SM) CME article: venous thromboembolism prophylaxis in plastic surgery patients. *Plast Reconstr Surg* 2008;122(Suppl 3):1–9.
- [2] National Institute for Health and Care Excellence. Venous thromboembolism: reducing the risk—reducing the risk of venous thromboembolism (deep vein thrombosis and pulmonary embolism) in patients admitted to hospital. Clinical Guideline 92. London: NICE; 2010.
- [3] Miszkiewicz K, Perreault I, Landes G, Harris PG, Sampalis JS, Dionyssopoulos A, et al. Venous thromboembolism in plastic surgery: incidence, current practice and recommendations. *J Plast Reconstr Aesthet Surg* 2009;62:580–8.
- [4] Alderman AK, Collins ED, Streu R, Grotting JC, Sulkin AL, Neligan P, et al. Benchmarking outcomes in plastic surgery: national complication rates for abdominoplasty and breast augmentation. *Plast Reconstr Surg* 2009; 124:2127–33.
- [5] Spiezia L, Simioni P. Upper extremity deep vein thrombosis. *Intern Emerg Med* 2010;5:103–9.
- [6] Caprini JA. Risk assessment as a guide for the prevention of the many faces of venous thromboembolism. *Am J Surg* 2010;199(Suppl 1):S3–10.
- [7] Murphy RX, Alderman A, Gutowski K, Kerrigan C, Rosolowski K, Schechter L, et al. Evidence-based practices for thromboembolism prevention: summary of the ASPS Venous Thromboembolism Task Force Report. *Plast Reconstr Surg* 2012;130:168e–75e.
- [8] Pannucci CJ, Bailey SH, Dreszer G, Fisher Wachtman C, Zumsteg JW, Jaber RM, et al. Validation of the Caprini risk assessment model in plastic and reconstructive surgery patients. *J Am Coll Surg* 2011;212:105–12.
- [9] Thromboembolism Risk. Diepflap.it Medical Software Version (Version 1.2) [Mobile application software]. 2014. Available from: <http://itunes.apple.com/it/app/thromboembolism-risk/id889719436?l=en&mt=8>.
- [10] The British Committee for Standards in Haematology. Clinical guidelines for testing for heritable thrombophilia. *Br J Haematol* 2010;149:209–20.