


Deep sternal wound infection following cardiac surgery: A comparison of the monolateral with the bilateral pectoralis major flaps

Federico Lo Torto¹ | Gianmarco Turriziani¹  | Casella Donato² | Marco Marcasciano¹ | Ugo Redi¹ | Manfredi Greco³ | Fabio Miraldi⁴ | Diego Ribuffo¹

¹Department of Plastic Reconstructive and Aesthetic Surgery, Sapienza Università di Roma, Rome, Italy

²Department of Breast Cancer Surgery, Azienda Ospedaliero-Universitaria Senese, Siena, Italy

³Università degli studi "Magna Graecia" di Catanzaro, Catanzaro, Italy

⁴Department of Cardiovascular, Respiratory, Nephrological, Anesthesiological and Geriatric Sciences, Sapienza Università di Roma, Rome, Italy

Correspondence

Gianmarco Turriziani, MD, Via Piede la Valle 13 Broccostella 03030, Italy.
Email: gianmarco.turriziani@gmail.com

Abstract

Deep sternal wound infections are a serious complication following sternotomy for cardiothoracic surgery. "Conventional" treatment provides debridement and secondary closure or closed catheter irrigation. The combination of the Negative Pressure Therapy with flap coverages is an accepted technique and one or both Pectoralis Major muscles could be chosen. A multistep protocol was adopted. One hundred and sixty seven patients were treated with the combination of Negative Pressure Therapy with the Pectoralis Major muscle flap: 86 monolateral flap and 81 bilateral flap reconstruction. The main complications (hematoma, seroma, dehiscence, and re-infection), the need for re-intervention, mortality rates, Intensive Care Unit, and hospitalisation time were assessed. The mono-pectoralis group had fewer complications and need for revision, with a shorter hospital stay. A statistically significant difference emerged for the hematoma rate ($P = .0079$). Monolateral flap should to be preferred because with the same coverage effectiveness, it guarantees the saving of controlateral muscle with its functionality and the possibility of its use in case of failure. Furthermore, as the technique is less invasive, it can be reserved for more fragile patients.

KEYWORDS

negative pressure therapy, pectoralis major muscle flap, sternal wound infection

1 | INTRODUCTION

Open-heart surgery can be followed by different complications, as the Sternal Wound Dehiscence (SWD) that usually occurs after infection.

The first classification of these wounds was described by Pairolero & Arnold in 1984.¹ Nowadays, according to the Center for Disease Control and Prevention (CDC), the Sternal Wound Infection (SWI) in surgical wounds

after sternotomy should be classified into three types: superficial (SSWI), when it involves skin, and subcutaneous tissue until muscle fascia; deep (DSWI), when the dehiscence reaches the sternal surface without affecting it but there may be sternal instability, osteomyelitis, and/or mediastinitis,² which are the most serious cases.

SSWI occur in 1.1% to 6.7% of cases, whereas the incidence of DSWI ranges from 0.1% to 3.7%,³⁻⁶ although it would reach up to 10%, according to other studies.⁷⁻⁹ The

SSWI morbidity and mortality rate ranges from 0.5% to 8% and in DSWI it increases more than twice, up to 47%.^{10,11} In addition to high morbidity and mortality rates, SWIs are associated with prolonged periods of hospitalisation and high healthcare costs.¹²⁻¹⁶

The most commonly reported risk factors for DSWI include surgical technique, obesity, diabetes mellitus, prolonged stay in intensive care, emergent or urgent surgery, use of BIMA (bilateral internal mammary artery), reoperation, substernal seroma or haematoma, female gender.¹⁷⁻²¹

The most common pathogens detected in DSWI are *Staphylococcus aureus*, especially methicillin-resistant species, followed by Gram-negative as *Pseudomonas aeruginosa*, *Klesbiella Pneumoniae*, or *Enterobacter* spp. with increasing incidence and multidrug resistance.²²

There are several methods for the treatment of SWIs and the most commonly used procedures are closed suction antibiotic catheter irrigation systems, Negative Pressure Therapy (NPT), and various flap coverages.¹⁰

“Conventional” treatment provides debridement and secondary closure or closed catheter irrigation. This choice is associated with mortality rate between 5% and 80%.^{23,24} In the last years, radical debridement with the use of vascularized flaps reduced the mortality rate to 4.8% to 10.5%²⁵⁻²⁹: in the most cases Pectoralis Major, Rectus Abdominis, and Latissimus Dorsi muscle flaps represent the main choices for SWIs surgical coverage and infection control. Nowadays, NPT is an accepted method for the treatment of open contaminated/infected-acute/chronic wounds. It reduces the wound bacterial colonisation rate, swelling and exudation, stimulates growth of granulation tissue, improves perfusion and antibiotic circulation in the wound, and creates favourable microenvironment for wound healing.³⁰⁻³⁶ The growing experience with the NPT pointed out how it can be used as a bridge to allow cleaning and preparation of the wound bed for further reconstructions.³⁶⁻³⁸ Traditionally, the timing for the surgical closure procedure is guided by the patient's general condition, the clinical appearance of the wound, the cultures performed on the wound bed, and laboratory tests, such as the CRP.³⁹

The whole treatment of DSWI often involves prolonged hospitalisation/time in the Intensive Care Unit (ICU), prolonged antibiotic therapy, and high costs.¹²⁻¹⁶

In this study, we want to report the results we obtained from the comparison of two groups of patients with DSWI, following a multistep protocol: the first group was treated with preoperative NPT (VAC[®] therapy) and subsequent reconstruction with a Monolateral Pectoralis Major muscle Flap (MPMF), whereas the second one was managed with preoperative VAC-therapy and a Bilateral Pectoralis Major muscle Flap (BPMF).

Key Messages

- Deep sternal infections are a possible complication of open-heart surgery. One hundred and sixty seven cases were treated with VAC-therapy and with Pectoralis Major muscle flap (86 unilateral and 81 bilateral). Complications, length of stay, and need for revision were assessed. The mono-Pectoralis muscle flap is less invasive and associated with better results than the bi-Pectoralis muscle flap.

2 | MATERIALS AND METHODS

2.1 | Patients

From January 2014 to April 2018, a single-centre retrospective study was performed and 167 patients with post-sternotomy DSWI following cardiac surgery.

All patients were treated with a multistep protocol. The first step was the preoperative VAC-therapy, performed in all 167 patients. The second step was surgery and two study groups were created: patients in Group A were treated with MPMF, whereas patients in Group B were treated with BPMF.

Both demographical data and surgical data were assessed routinely from all patients.

2.2 | Surgical technique

Preoperative management of DSWI was the debridement time and NPT (V.A.C. ATS Therapy System, KCI Concepts, Inc, San Antonio, TX) in all 167 patients (Figures 1–3). Before aseptic procedures, wound cultures were performed for microbiological exam and antibiogram. Debridement involved the review of the wound margins and the removal of necrotic and infected tissue, with a copious irrigation of the wound bed through a hydrogen peroxide plus normal saline solution. Staples and non-viable bone were removed with possible sequestrectomy, sternectomy, and a partial costectomy. At the beginning, all patients received empirical antibiotic treatment, then the therapy was based on the cultures and antibiograms.

At the end of this time, the polyurethane-customized foam was placed in the wound with a “two-layer” technique, in order to completely cover the upper layers of

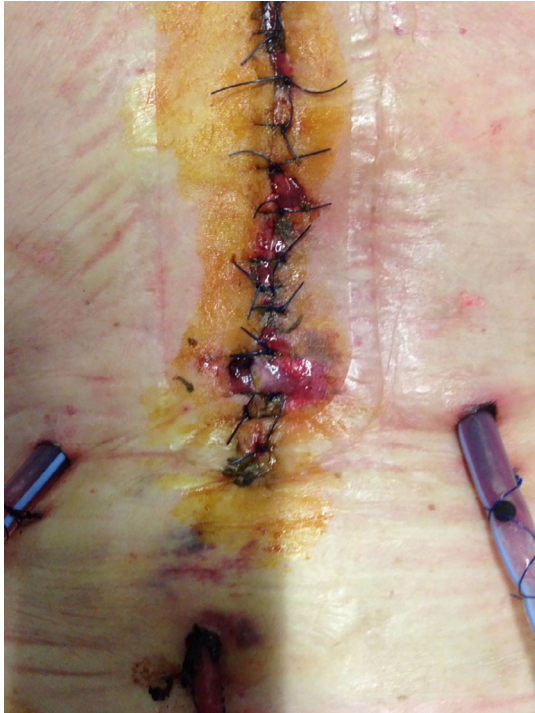

FIGURE 1 Preoperative time: sternal wound infection with closed drainage

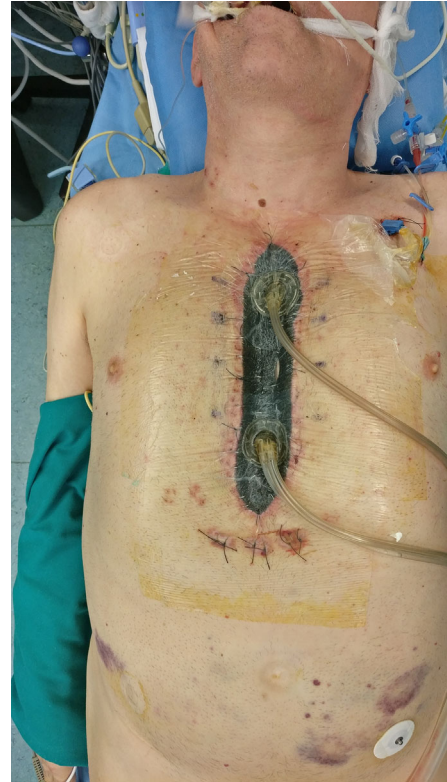

FIGURE 3 VAC-therapy placement

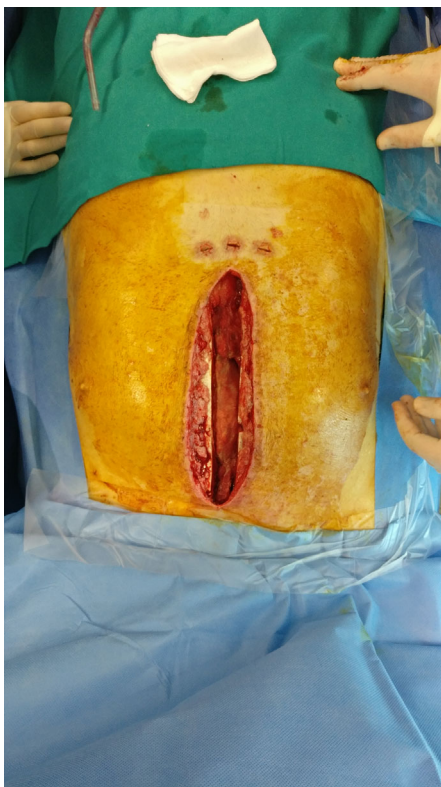

FIGURE 2 First step: surgical debridement

the wound. The two foams were covered with sterile drape and the layers were connected to the tube through a central and superficial hole. The effective negative pressure set was at -125 mmHg. VAC-therapy was replaced at least twice a-week and at each change, microbiological cultures were performed.

At the subsequent surgical time, the MPMF (Group A) was raised as the standard procedure (Figure 4). The muscle monolateral flap was placed upon the sternal defect and fixated without tension. Closure was performed in a multilayer technique using 2-0 and 3-0 absorbable single stitches sutures (Vicryl[®], Ethicon, Norderstedt, Germany) for the subcutaneous tissue and same calibres non-absorbable (Ethilon[®], Ethicon, Norderstedt, Germany) single vertical mattress sutures for the skin (Figure 5). In Group B, both Pectoralis muscles were sharply elevated from their costal and sternal insertions, continuing the dissection in a subpectoral plane to allow bilateral advancement to the midline without tension. The humeral attachments of the Pectoralis muscles were left intact and the thoracoacromial arteries were carefully preserved. The insertion of the Pectoralis muscles was released with preservation of the long thoracic artery to aid in a tension-free closure. The Pectoralis muscles were imbricated medially. Closure was performed in a multi-layer technique.

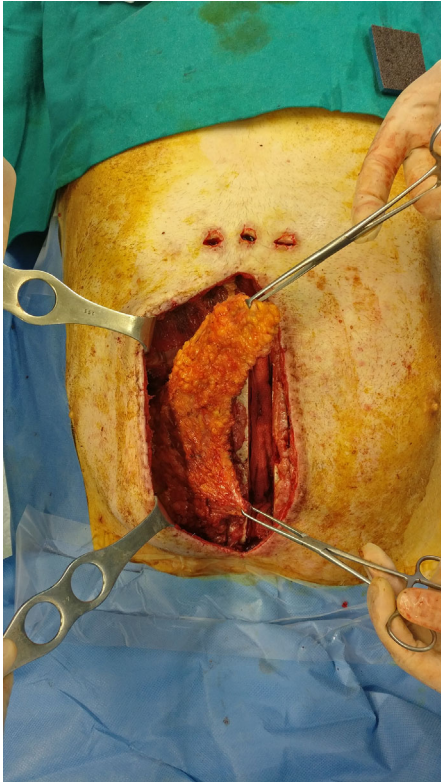


FIGURE 4 Second step: unilateral Pectoralis Major muscle flap coverage

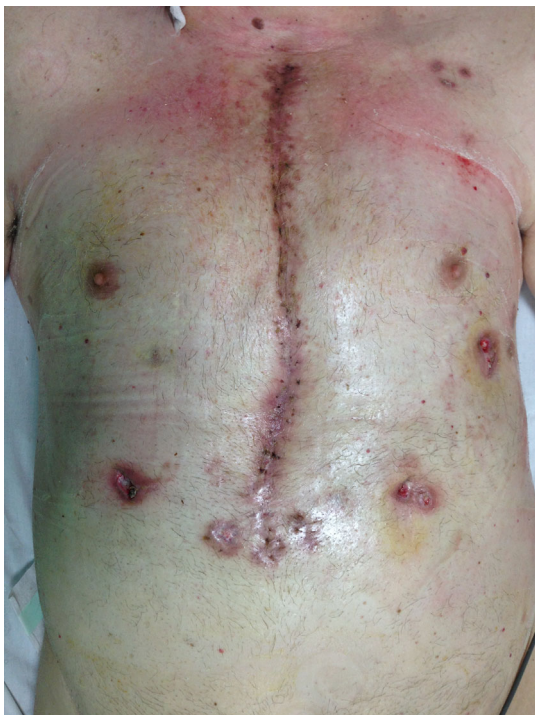

FIGURE 5 Postoperative picture at 30 days after surgery

Two or three drains were used and the wounds were taped with sterile non-woven tape.

2.3 | Statistical analysis

Statistical analysis was performed using the SPSS software. Fisher's exact two-tailed test was used to compare postoperative complications (seroma, haematoma, dehiscence, surgical revision). A P-value of 0.05 was considered statistically significant.

3 | RESULTS

3.1 | Patient characteristics

From January 2014 to April 2018, 167 patients had a DSWI following cardiac surgery with sternotomy. CABG (Coronary Artery Bypass Grafting) was performed in 109 patients (65.2%), valve replacement procedure in 26 patients (15.5%), both these procedures in 31 patients (18.5%); 1 patient (<1%) was treated for an ascending aorta rupture with intramural hematoma and hemopericardium. Bilateral Internal Mammary Artery technique for revascularization was used in 51 cases (30.5%) and other 51 patients underwent emergent/urgent surgery. Sex distribution, mean age, BMI, and comorbidities are described in Table 1.

Wound cultures were performed before VAC placing. In most patients a positivity for Gram + cocci was found: *Staphylococcus epidermidis* in 58 patients (34.7%); *Staphylococcus aureus* in 95 patients (56.8%), including 34 positive for *Pseudomonas*, KPC, *Candida albicans* too; 12 cultures were positive for *Enterobacter* (7.18%); in two

TABLE 1 Patient's characteristics and comorbidities

Sex (M:F)	(97:70)
Age (mean)	67.1
BMI > 30	73 (43.7%)
Diabetes mellitus	61 (36.5%)
Heart failure	41 (24.5%)
COPD	20 (11.9%)
CRI	21 (12.5%)
Hypertension	89 (53.2%)
Hyperlipidaemia	81 (48.5%)
Smoke	100 (59.8%)

Abbreviations: BMI, body mass index; COPD, chronic obstructive pulmonary disease; CRI, chronic renal insufficiency.

TABLE 2 Complication and revision rate

	Group A	Group B
Haematoma, <i>n</i> (%)	1 (1.2%)	9 (11.1%)
Seroma, <i>n</i> (%)	6 (7%)	13 (16%)
Deishences, <i>n</i> (%)	7 (8.1%)	8 (9.9%)
Revision needed, <i>n</i> (%)	8 (9.3%)	14 (17.3%)

cases, the presence of other pathogens was found. VAC-therapy lasted 16 ± 6 days.

Two homogeneous groups were created before the reconstructive time. Group A included 86 patients (51.5%) that underwent MPMF. Group B included the remaining 81 patients (48.5%) that underwent BPMF.

In Group A 14 adverse events (16.27%) occurred, whereas 30 complications (37.03%) occurred in Group B; wound revision was needed in eight cases and in 14 cases, for Groups A and B, respectively (Table 2). In each group, one patient had mediastinitis and died for sepsis (Group A) and for Heart Failure (Group B). Other two mediastinitis occurred and the one of Group B had sepsis.

When needed, the mean time spent in ICU was 3.2 ± 1.6 days in Group A and 18 ± 13 in Group B. The mean hospitalisation time was 18.1 ± 14.5 days for MP patients and 32 ± 24.2 for BP patients.

4 | DISCUSSION

Deep sternal wound infections (DSWI) are a serious complication occurring in about 0.1% to 3.7% of patients after sternotomy for cardiothoracic surgery.³⁻⁶

The first classification of these wounds was described by Pairolero & Arnold in 1984.¹ They classified these infections according to the postoperative onset timing. In 1996, Oakley et al used the same criteria but added to their classification the presence of clinical risk factors.⁴⁰ One year later, Jones et al proposed the first classification based on the affected anatomical site in addition to the ever presence of infection as the main parameter.⁴¹ Finally, in 2007 Greig et al defined the only affected anatomical site classification.⁴² In 2015, Anger et al suggested a new classification based on anatomical changes, considering the depth and location of the surgical wound.⁴³

There are various risk factors, like surgical technique and the use of accurate asepsis procedures, female gender, high BMI, diabetes mellitus and hyperglycemia status, prolonged stay in intensive care, emergent or urgent surgery, use of BIMA (bilateral internal mammary artery), and others, like age > 70, reoperation, heart failure, renal failure, peripheral vascular disease, need for

transfusion or prolonged inotropic support, smoking, chronic obstructive pulmonary disease, substernal seroma, or haematoma.¹⁷⁻²¹

The most common pathogens detected in DSWI are *Staphylococcus aureus*, *Pseudomonas aeruginosa*, *Klesbiella Pneumoniae*, or *Enterobacter* spp. The incidence of MRSA and multidrug resistance Gram-negative species is increasing in the last years.²²

In the past the treatment only consisted in intravenous antibiotics and different surgical techniques, but it was associated with a high short- and long-term mortality.⁴⁴

The introduction of negative pressure therapy in the treatment of difficult wounds dates back to 1997 by Argenta and Morykwas,³⁷ but Obdeijn suggested its application in post-sternotomy wound dehiscences in 1999.⁴⁵ In these cases VAC-therapy leads to a faster wound healing,⁴⁶⁻⁴⁸ lower length of hospital stay and the subsequent lower in-hospital cost.³⁸ Moreover, early studies and meta-analysis showed that VAC-therapy is associated with lower mortality than other surgical techniques in DSWI^{38,49,50} and that it is a good choice of treatment for these complications when it is used with other concomitant surgical reconstructive procedures.⁵¹ There are no contraindications in using VAC-therapy in SWI, but all free particles in the sternum have to be removed completely before its placing, in order to avoid severe bleeding caused by the displacement of the fragments in the vessels.⁵²

Primary or delayed flap closure is generally obtained by myocutaneous flaps (myoplasty), such as the Pectoralis Major flap,⁵³⁻⁵⁷ the Rectus Abdominis flap,^{58,59} the LD flap (Latissimus Dorsi muscle),⁶⁰ or the omental flap.^{61,62}

Pectoralis Major and Rectus Abdominis are the first-line flaps, with the preference of the first one.^{27,56,63}

Rectus Abdominis flap can be used especially in dehiscences of the lower III of the sternum, alone or in combination with the Pectoralis Major muscle flap. The flap is based on the peduncle of the superior epigastric artery, so the use of the internal mammary artery (IMA) for the previous cardiac revascularization is at least a relative contraindication,^{64,65} although cases of flap survival have been described despite the absence of one or both to IMA^{61,66-68}: this is explained by the presence of collateral circles based on the musculofrenic arteries and on the anterior intercostal arteries. A possible complication associated with this flap is the formation of herniations through the abdominal wall.⁶⁹

The LD flap can be used to cover dehiscence of the two upper thirds of the sternum. Vascularization is based on the thoraco-dorsal artery. The main advantage is related to the savings of the collateral blood supply to the

sternum and parasternal tissues; the disadvantages are the possible formation of seromas in the donor site and the need to change the position of the patient to lateral decubitus during surgery.⁷⁰

The greater Omentum flap is based on the gastroepiploic arteries and can cover large dehiscences, even of the entire sternum.^{63,71} Its harvesting requires a laparotomic incision or less invasive abdominal incisions, so it is contraindicated in complicated patients; furthermore, cases of accidental damage to abdominal viscera and formation of abdominal hernias have been described.¹ Laparoscopy can reduce all of these risks, but it is still a little used approach.⁵⁹ It would be advisable to exclude neoplastic pathologies at least of the colon because the omentum can be the site of metastatic repetition: in fact, Telfer et al⁷² described the case of a patient, who underwent the transposition of the Greater Omentum with the onset of an omental adenocarcinoma at the sternal region, starting from a colon cancer.

Pectoralis Major muscle flap is the technique of choice for several centres. One or both of the Pectoralis muscles can be harvested and the decision is based on the kind and extension of the area to be covered. Furthermore, in right-handed patients the left pectoral muscle is the first choice, so that the functionality of the dominant limb is completely preserved; equally, the right muscle is used in left-handed people.

The dominant peduncle is the thoracoacromial artery, therefore the use of the IMA for the revascularization procedure is an independent factor.^{59,73} The flap is an excellent option, especially for the covers of the two upper thirds of the sternum^{41,69,74} and guarantees a good thoracic stabilisation, a good aesthetic result and the maintenance of respiratory function.^{54,75-77}

MPMF is an alternative that spares the contralateral Pectoralis Major muscle. The technique is comparable to BPMF in terms of effectiveness of coverage and mortality, but it is associated with shorter surgical times and less invasiveness, morbidity, and complications, so as to have an indication even for patients with more risk factors.⁷⁸

In both procedures, the main limitation is the difficulty in covering the lower III of the sternum^{26,41,74}: in these cases, they can associate other flaps or reinforce the lower part of the flap with the suture of the only fascia of the Rectus Abdominis muscle.⁷⁹ The main complications are hematoma, seroma, infection, and dehiscence. In the literature, the incidence of these complications varies from study to study, especially based on the characteristics of the sample populations.^{41,73,80} The incidence of seromas and hematomas is around 6% to 7%; the re-infection rate is around 12%; the recurrence of sternal dehiscences is generally <10%, although it can even

reach 27%, especially for the partial dehiscences of the lower part of the sternum, where the tension after the coverage with the flap is high.^{1,41,68,70-72,81,82}

In our study, the overall complication rate is 16.2% in Group A and 37% in Group B. The rate of postoperative hematomas and seromas is lower after MPMF compared to BPMF: in Group A, the percentage of hematomas and seromas are 1.2% and 7%, respectively, instead in Group B they are 11.1% and 16%. Consequently, the need for surgical revision in patients treated with BPMF is higher compared to MPMF patients (17.3% versus 9.3%). Our results confirm the rate of dehiscence recurrence after PMF reported in the literature (<10% in both groups). A statistically significant difference emerged only for the hematoma rate ($P = .0079$). The mean time in ICU and the overall hospitalisation time are shorter in Group A (3.2 ± 1.6 , and 18.1 ± 14.5 days) than in Group B (18 ± 13 and 32 ± 24.2 days). Mortality rate was <1.2% after both procedures.

Our study shows that the coverage with unilateral or bilateral Pectoralis Major muscle flap is equally effective and without significant differences on the infectious outcome. On the other hand, the unilateral technique is less invasive because it saves the contralateral muscle with its functionality, so it can be reserved for more fragile patients. The contralateral Pectoralis muscle is always available in cases of recurrences. Furthermore, MPMF is associated with a more rapid postoperative course, with fewer days of hospitalisation, lower complication rate, and lower healthcare costs. In conclusion, both techniques are the first choice and, when conditions allow, unilateral flap is preferred.

ACKNOWLEDGMENTS

No contributions, technical help, financial and material support were provided by "V.A.C. ATS Therapy System, KCI Concepts, Inc, San Antonio, TX" or by others.

CONFLICT OF INTEREST

The authors declare no conflicts of interest.

AUTHOR CONTRIBUTIONS

All the authors and no one else contributed to the writing of the work.

ORCID

Gianmarco Turriziani  <https://orcid.org/0000-0003-3172-5568>

REFERENCES

1. Pairolero PC, Arnold PG. Management of recalcitrant median sternotomy wounds. *J Thorac Cardiovasc Surg.* 1984;88(3): 357-364.

2. Garner JS, Jarvis WR, Emori TG, Horan TC, Hughes JM. CDC definitions for nosocomial infections, 1988. *Am J Infect Control*. 1988;16(3):128-140.
3. Ridderstolpe L, Gill H, Granfeldt H, Ahlfeldt H, Rutberg H. Superficial and deep sternal wound complications: incidence, risk factors and mortality. *Eur J Cardiothorac Surg*. 2001;20:1168-1175.
4. Schimmer C, Reents W, Berneder S, et al. Prevention of sternal dehiscence and infection in high-risk patients: a prospective randomized multicenter trial. *Ann Thorac Surg*. 2008;86:1897-1904.
5. Baillot R, Cloutier D, Montalin L, et al. Impact of deep sternal wound infection management with vacuum-assisted closure therapy followed by sternal osteosynthesis: a 15-year review of 23,499 sternotomies. *Eur J Cardiothorac Surg*. 2010;37:880-887.
6. Farsky PS, Graner H, Duccini P, et al. Risk factors for sternal wound infections and application of the STS score in coronary artery bypass graft surgery. *Rev Bras Cir Cardiovasc*. 2011;26(4):624-629.
7. Landes G, Harris PG, Sampalis JS, et al. Outcomes in the management of sternal dehiscence by plastic surgery: a ten-year review in one university center. *Ann Plast Surg*. 2007;59(6):659-666.
8. Finkelstein R, Rabino G, Mashiah T, et al. Surgical site infection rates following cardiac surgery: the impact of a 6-year infection control program. *Am J Infect Control*. 2005;33(8):450-454.
9. Cove ME, Spelman DW, MacLaren G. Infectious complications of cardiac surgery: a clinical review. *J Cardiothorac Vasc Anesth*. 2012;26(6):1094-1100.
10. Kimberly S, Anderson E, Harper JG. Overview and management of sternal wound infection. *Semin Plast Surg*. 2011;25(1):25-33.
11. Braxton M, Marrin CA, McGrath PD, et al. 10-year follow-up of patients with and without mediastinitis. *Semin Thor Cardiovasc Surg*. 2004;16(1):70-76.
12. Mokhtari A, Sjogren J, Nilsson J, Gustafsson R, Malmsjo M, Ingemansson R. The cost of vacuum assisted closure therapy in treatment of deep sternal wound infections. *Scand Cardiovasc J*. 2008;42:85-89.
13. Lucet JC, Batisse D, Brucker G. Mediastinitis after sternotomy. Mortality and hospital length of stay. Groupe parisien detude des sternotomies. *Arch Mal Coeur Vaiss*. 1997;90:471-475.
14. Loop FD, Lytle BW, Cosgrove DM, et al. J. Maxwell Chamberlain memorial paper. Sternal wound complications after isolated coronary artery bypass grafting: early and late mortality, morbidity, and cost of care. *Ann Thorac Surg*. 1990;49:179-186. discussion 186-7.
15. Taylor AH, Mitchell AE, Mitchell IM. A 15-year study of the changing demographics and infection risk in a new UKcardiac surgery unit. *Interact Cardiovasc Thorac Surg*. 2012;15:390-394.
16. Graf K, Ott E, Vonberg RP, Kuehn C, Haverich A, Chaberny IF. Economic aspects of deep sternal wound infections. *Eur J Cardiothorac Surg*. 2010;37:893-896.
17. Omran AS, Karimi A, Ahmadi SH, et al. Superficial and deep sternal wound infection after more than 9000 coronary artery bypass graft (CABG): incidence, risk factors and mortality. *BMC Infect Dis*. 2007;7(1):1.
18. Parisian Mediastinitis Study Group. Risk factors for deep sternal wound infection after sternotomy: a prospective, multicenter study. *J Thor Cardiovasc Surg*. 1996;111(6):1200-1207.
19. Cotogni P, Barbero C, Rinaldi M. Deep sternal wound infection after cardiac surgery: evidences and controversies. *World J Crit Care Med*. 2015;4(4):265-273.
20. Borger MA, Rao V, Weisel RD, et al. Deep sternal wound infection: risk factors and outcomes. *Ann Thorac Surg*. 1998;65(4):1050-1056.
21. Heilmann C, Stahl R, Schneider C, et al. Wound complications after median sternotomy: a single-Centre study. *Interact Cardiovasc Thorac Surg*. 2013;16(5):643-648.
22. Morgante A, Romeo F. Deep sternal wound infections: a severe complication after cardiac surgery. *G Chir*. 2017;38(1):33-36.
23. Sarr MG, Gott VL, Townsend TR. Mediastinal infection after cardiac surgery. *Ann Thorac Surg*. 1984;38:415-423.
24. Bryant LR, Spencer FC, Trinkle JK. Treatment of median sternotomy infection by mediastinal irrigation with an antibiotic solution. *Ann Surg*. 1969;169:914-920.
25. Carlesimo B, Lo Torto F, Rossi A, Marcasciano M, Ruggiero M. Long-term result of bilateral pectoralis major muscle advancement flap in median sternotomy wound infections. *Eur Rev Med Pharmacol Sci*. 2014;18:3767-3772.
26. Jurkiewicz MJ, Bostwick J III, Hester TR, Bishop JB, Craver J. Infected median sternotomy wound. Successful treatment by muscle flaps. *Ann Surg*. 1980;191:738-744.
27. Pairolero PC, Arnold PG, Harris JB. Long-term results of pectoralis major muscle transposition for infected sternotomy wounds. *Ann Surg*. 1991;213:583-589. discussion 589-590.
28. Parisi P, Lo Torto F, Carlesimo B, Ribuffo D, Scuderi N. The split pectoralis flap: combining the benefits of pectoralis major advancement and turnover techniques in one flap. *Plast Reconstr Surg*. 2018;141(1):191e-192e.
29. Fioramonti P, Sorvillo V, Maruccia M, et al. New application of purse string suture in skin cancer surgery. *Int Wound J*. 2018;15(6):893-899.
30. Lo Torto F, Ruggiero M, Parisi P, Borab Z, Sergi M, Carlesimo B. The effectiveness of negative pressure therapy on infected wounds: preliminary results. *Int Wound J*. 2017;14(6):909-914.
31. Lo Torto F, Turriziani G, Miraldi F, Carlesimo B, Ribuffo D. Vacuum-assisted closure therapy for the treatment of post-sternotomy wound dehiscence in neonates and infants. *Thorac Cardiovasc Surg*. 2019. <https://doi.org/10.1055/s-0039-1688958>. [Epub ahead of print].
32. Marcasciano M, Cavalieri E, Kaciulyte J, et al. Temporary, customized negative pressure wound therapy to assist wound closure in selected patients: a practical solution or a bridge to advanced care. *Wound Repair Regen*. 2019;27(6):720-721.
33. Lo Torto F, Monfrecola A, Kaciulyte J, et al. Preliminary result with incisional negative pressure wound therapy and pectoralis major muscle flap for median sternotomy wound infection in a high-risk patient population. *Int Wound J*. 2017;14(6):1335-1339.
34. Yoshimoto A, Inoue T, Fujisaki M, Morizumi S, Suematsu Y. Efficacy of vacuum-assisted closure therapy on rehabilitation during the treatment for surgical site infection after cardiovascular surgery. *Gen Thorac Cardiovasc Surg*. 2016;64(8):464-9.
35. Simek M, Nemecek P, Zalesak B, et al. Vacuum-assisted closure in the treatment of sternal wound infection after cardiac surgery. *Biomed Pap*. 2007;151(2):295-299.
36. Fleck TM, Fleck M, Moidl R, et al. The vacuum-assisted closure system for the treatment of deep sternal wound infections after cardiac surgery. *Ann Thorac Surg*. 2002;74(5):1596-1600.

37. Argenta LC, Morykvas MJ, Marks MW, et al. Vacuum-assisted closure: state of art. *Plast Reconstruct Surg*. 2006;117:127-42S.
38. Sjoegren J, Gustafsson R, Nilsson J, Malmsjoe M, Ingemansson R. Clinical outcome after poststernotomy mediastinitis: vacuum-assisted closure versus conventional treatment. *Ann Thorac Surg*. 2005;79:2049-2055.
39. Gustafsson RI, Johnsson P, Algotsson L, Blomquist S, Ingemansson R. Vacuum-assisted closure therapy guided by C-reactive protein level in patients with deep sternal wound infection. *J Thorac Cardiovasc Surg*. 2002;123:895-900.
40. El Oakley RM, Wright JE. Postoperative mediastinitis: classification and management. *Ann Thorac Surg*. 1996;61(3):1030-1036.
41. Jones G, Jurkiewicz MJ, Bostwick J, et al. Management of the infected median sternotomy wound with muscle flaps. The Emory 20-year experience. *Ann Surg*. 1997;225(6):766-776.
42. Greig AV, Geh JL, Khanduja V, Shibu M. Choice of flap for the management of deep sternal wound infection—an anatomical classification. *J Plast Reconstr Aesthet Surg*. 2007;60(4):372-378.
43. Anger J, Dantas DC, Arnoni RT, Farsky PS. A new classification of post-sternotomy dehiscence. *Rev Bras Cir Cardiovasc*. 2015;30(1):114-118.
44. Toumpoulis IK, Anagnostopoulos CE, Derose JJ Jr, Swistel DG. The impact of deep sternal wound infection on long-term survival after coronary artery bypass grafting. *Chest*. 2005;127:464-471.
45. Obdeijn MC, de Lange MY, Lichtendahl DH, de Boer WJ. Vacuum-assisted closure in the treatment of poststernotomy mediastinitis. *Ann Thorac Surg*. 1999;68(6):2358-2360.
46. Joseph E, Hamori CA, Bergman S, Roaf E, Swann NF, et al. A prospective randomized trial of vacuum-assisted closure versus standard therapy of chronic non-healing wounds. *Wounds*. 2000;12:60-67.
47. Vuerstaek JD, Vainas T, Wuite J, Nelemans P, Neumann MH, et al. State-of-the-art treatment of chronic leg ulcers: a randomized controlled trial comparing vacuum-assisted closure (V.A.C.) with modern wound dressings. *J Vasc Surg*. 2006;44:1029-1037. discussion 1038.7.
48. Catarino PA, Chamberlain MH, Wright NC, et al. High-pressure suction drainage via a polyurethane foam in the management of poststernotomy mediastinitis. *Ann Thorac Surg*. 2000;70:1891-1895.
49. Sjoegren J, Nilsson J, Gustafsson R, Malmsjo M, Ingemansson R. The impact of vacuum-assisted closure on long-term survival after post-sternotomy mediastinitis. *Ann Thorac Surg*. 2005;80:1270-1275.
50. Falagas ME, Tansarli GS, Kapaskelis A, Vardakas KZ. Impact of vacuum-assisted closure (VAC) therapy on clinical outcomes of patients with sternal wound infections: a meta-analysis of non-randomized studies. *PLoS One*. 2013;8(5):e64741.
51. Listewnik MJ, Sielicki P, Mokrzycki K, Biskupski A, Brykczynski M. The use of vacuum-assisted closure in purulent complications and difficult-to-heal wounds in cardiac surgery. *Adv Clin Exp Med*. 2015;24(4):643-650.
52. Kiessling AH, Lehmann A, Isgro F, Moritz A. Tremendous bleeding complication after vacuum-assisted sternal closure. *J Cardiothorac Surg*. 2011;6:16.
53. Daya M, Barnes N. Use of VAC therapy and sternal plating in the treatment of sternotomy wound dehiscence. *Eur J Plast Surg*. 2009;32:287-291.
54. Klesius AA, Dzemali O, Simon A, et al. Successful treatment of deep sternal infections following open heart surgery by bilateral pectoralis major flaps. *Eur J Cardiothorac Surg*. 2004;25:218-223.
55. Netscher DT, Eladoumikhachi F, Mchugh PM, Thornby J, Soltero E. Sternal wound debridement and muscle flap reconstruction: functional implications. *Ann Plast Surg*. 2003;51:115-122.
56. Ringelman PR, Vander Kolk CA, Cameron D, Baumgartner WA, Manson PN. Long-term results of flap reconstruction in median sternotomy wound infections. *Plast Reconstr Surg*. 1994;93:1208-1214.
57. Wong CH, Senewiratne S, Garlick B, Mullany D. Two-stage management of sternal wound infection using bilateral pectoralis major advancement flap. *Eur J Cardiothorac Surg*. 2006;30:148-152.
58. Yuen JC, Zhou AT, Serafin D, Georgiade GS. Longterm sequelae following median sternotomy wound infection and flap reconstruction. *Ann Plast Surg*. 1995;35:585-589.
59. Davison SP, Clemens MW, Armstrong D, Newton ED, Swartz W. Sternotomy wounds: rectus flap versus modified pectoral reconstruction. *Plast Reconstr Surg*. 2007;120(4):929-934.
60. Erdmann D, Küntscher M, Petravic A, et al. Plastic surgery coverage of osteocutaneous defects of the sternum area with the vertical and transversal rectus abdominis muscle (VRAM/TRAM) flap. *Chirurg*. 2000;71:1156-1160.
61. Nahai F, Rand RP, Hester TR, Bostwick J III, Jurkiewicz MJ. Primary treatment of the infected sternotomy wound with muscle flaps: a review of 211 consecutive cases. *Plast Reconstr Surg*. 1989;84:434-441.
62. Lee ABJR, Schimert G, Shaktin S, Seigel JH. Total excision of the sternum and thoracic pedicle transposition of the greater omentum; useful strategems in managing severe mediastinal infection following open heart surgery. *Surgery*. 1976;80:433-436.
63. Hultman CS, Culbertson JH, Jones GE, et al. Thoracic reconstruction with the omentum: indications, complications, and results. *Ann Plast Surg*. 2001;46:242-249.
64. Arnold PG, Pairolo PC. Use of pectoralis major muscle flaps to repair defects of the anterior chest wall. *Plast Reconstr Surg*. 1979;63(2):205-213.
65. Solomon MP, Granick MS. New reconstruction method for sternotomy wounds. *Perspect Plast Surg*. 1994;8(1):61-65.
66. Fernando B, Muszynski C, Mustoe T. Closure of a sternal deficit with the rectus abdominis muscle after sacrifice of both internal mammary arteries. *Ann Plast Surg*. 1988;21:468-471.
67. Arnold PG, Pairolo PC. Chest-wall reconstruction: an account of 500 consecutive patients. *Plast Reconstr Surg*. 1996;98:804-810.
68. Netscher DT, Eladoumikhachi F, Goodman CM. Rectus abdominis muscle flaps used successfully for median sternotomy wounds after ipsilateral internal mammary artery ligation. *Ann Plast Surg*. 2001;47:223-228.

69. Lee C-H, Hsien J-H, Tang Y-B, Chen H-C. Reconstruction for sternal osteomyelitis at the lower third of sternum. *J Plast Reconstr Aesthet Surg*. 2010;63(4):633-641.
70. Dejesus RA, Paletta JD, Dabb RW. Reconstruction of the median sternotomy wound dehiscence using the latissimus dorsi myocutaneous flap. *J Cardiovasc Surg (Torino)*. 2001;42(3):359-364.
71. López-Monjardin H, de-la-Peña-Salcedo A, Mendoza-Muñoz M, López-Yáñez-de-la-Peña A, Palacio-López E, López-García A. Omentum flap versus pectoralis major flap in the treatment of mediastinitis. *Plast Reconstr Surg*. 1998;101(6):1481-1485.
72. Telfer JR, Chapple DC, Powell BW. Metastatic colonic adenocarcinoma in a pedicled omental flap used for sternal reconstruction: a case report. *Br J Plast Surg*. 1996;49:67-69.
73. Ascherman JA, Patel SM, Malhotra SM, Smith CR. Management of Sternal Wounds with bilateral Pectoralis major Myocutaneous advancement flaps in 114 consecutively treated patients: refinements in technique and outcomes analysis. *Plast Reconstr Surg*. 2004;114(3):676-683.
74. Nahai F, Morales L, Bone DK, Bostwick J. Pectoralis major muscle turnover flaps for closure of the infected sternotomy wound with preservation of form and function. *Plast Reconstr Surg*. 1982;70(4):471-474.
75. Bagheri R, Tashnizi MA, Haghzi SZ, et al. Therapeutic outcomes of pectoralis major muscle turnover flap in mediastinitis. *Korean J Thorac Cardiovasc Surg*. 2015;48(4):258-264.
76. Zeitani J, Pompeo E, Nardi P, et al. Early and long-term results of pectoralis muscle flap reconstruction versus sternal rewiring following failed sternal closure. *Eur J Cardiothorac Surg*. 2013;43(6):e144-e150.
77. Jang YJ, Park MC, Park DH, Lim H, Kim JH, Lee IJ. Immediate debridement and reconstruction with a pectoralis major muscle flap for poststernotomy mediastinitis. *Arch Plast Surg*. 2012;39(1):36-41.
78. Fernández-Palacios J, Abad C, García-Duque O, Baeta PJ. Post-operative mediastinitis in open heart surgery patients. Treatment with unilateral or bilateral pectoralis major muscle flap? *J Cardiovasc Surg (Torino)*. 2010;51(5):765-771.
79. Sauvageau J, Gagnon AR, Nikolis A, Harris PG, Brutus JP, Cordoba C. The pedicled rectus abdominis muscle transposition flap, as an adjunct to the unilateral pectoralis major Island flap, to reconstruct a full length sternal defect after postoperative mediastinal wound infection. *J Plast Reconstr Aesthet Surg*. 2008;61(2):230-231.
80. Zahiri HR, Lumpkins K, Kelishadi SS, et al. Significant predictors of complications after sternal wound reconstruction. *Ann Plast Surg*. 2012;69(4):439-441.
81. Solomon MP, Granick MS. Bipedicule muscle flaps in sternal wound repair. *Plast Reconstr Surg*. 1998;101:356-360.
82. Mathes SJ. The principles of muscle and musculocutaneous flaps. In: McCarthy JG, ed. *Plastic Surgery*. Vol 1. Philadelphia, PA: Saunders; 1990.

How to cite this article: Lo Torto F, Turriziani G, Donato C, et al. Deep sternal wound infection following cardiac surgery: A comparison of the monolateral with the bilateral pectoralis major flaps. *Int Wound J*. 2020;1-9. <https://doi.org/10.1111/iwj.13324>