

Concomitant Dehiscences of the Temporal Bone: A Case-Based Study



Maurizio Barbara, MD, PhD¹ , Valerio Margani, MD¹, Anna Voltattorni, MD¹, Simonetta Monini, MD¹, and Edoardo Covelli, MD, PhD¹

Abstract

Otic capsule dehiscences create a pathological third window in the inner ear that results in a dissipation of the acoustic energy consequent to the lowered impedance. Superior semicircular canal dehiscence (SSCD) was identified by Minor et al in 1998 as a syndrome leading to vertigo and inner ear conductive hearing loss. The authors also reported the relation between the dehiscence and pressure- or sound-induced vertigo (Tullio's phenomenon). Prevalence rates of SSCD in anatomical studies range from 0.4% to 0.7% with a majority of patients being asymptomatic. The observed association with other temporal bone dehiscences, as well as the propensity toward a bilateral or contralateral “near dehiscence,” raises the question of whether a specific local bone demineralization or systemic mechanisms could be considered. The present report regard a case of a patient with a previous episode of meningitis, with a concomitant bilateral SSCD and tegmen tympani dehiscence from the side of meningitis. The patient was affected by dizziness, left moderate conductive hearing loss, and pressure/sound-induced vertigo. Because of disabling vestibular symptoms, the patient underwent surgical treatment. A middle cranial fossa approach allowed to reach both dehiscences on the symptomatic side, where bone wax and fascia were used for repair. At 6 months from the procedure, hearing was preserved, and the vestibular symptoms disappeared.

Keywords

temporal bone, otic capsule, dehiscence, semicircular canal, tegmen

Introduction

The membranous labyrinth is located inside a hard-bony structure called the otic capsule (OC) that communicates with the middle ear cavity via 2 membranes (the round and oval windows) allowing fluid-mediated sound transduction, that is, the beginning of the hearing mechanism. The oval and round windows represent the 2 main physiological weak and compressible areas of the OC that alternate in depressing and bulging for this purpose. Other channels, including the cochlear and vestibular aqueducts and the foramina for vessels and nerves, represent additional windows that play scarce or no roles in auditory function. Abnormal communications of the OC may be also due to spontaneous and congenital dehiscences that related to defects during the embryological development. Among them, in the enlarged vestibular aqueduct syndrome part of the acoustic energy is lost since it is dumped due to shifting to the intracranial space.¹ Genetic conditions such as X-linked stapes gusher due to DFN3 locus mutations and Paget's syndrome may also generate a third window effect. Moreover, defects during embryological development may

result either in a complete dehiscence of the bone overlying the tegmen and/or the superior semicircular canal (SSC), or just in its thinning that becomes symptomatic in concomitance with additional factors (trauma, osteopenia, osteoporosis, sudden increase in intracranial pressure, and obesity).^{2–7} Chronic otitis media, cholesteatoma, temporal bone fractures or previous middle ear or skull base surgery are also involved for dehiscence occurrence.⁸

Superior semicircular canal dehiscence (SSCD) was identified by Minor et al in 1998⁹ as a syndrome of vertigo and oscillopsia. The prevalence rates in cadaveric temporal bone

¹ NESMOS Department, ENT Clinic, Sant'Andrea University Hospital, Sapienza University, Rome, Italy

Received: September 14, 2020; revised: October 19, 2020; accepted: October 26, 2020

Corresponding Author:

Maurizio Barbara, MD, PhD, Department of Otolaryngology, Sant'Andrea Hospital, via di Grottarossa 1035-1039, Roma 00189, Italy.

Email: maurizio.barbara@uniroma1.it



studies range from 0.4% to 0.7%^{10,11} and from 2% to 13% in computed tomography (CT) studies^{12,13} with the majority of patients being asymptomatic. Symptomatic patients will usually present with only cochlear, only vestibular or vestibulo-cochlear signs and symptoms. Patients mainly complain of noise or pressure-induced vertigo, hearing loss, dizziness, autophony, and tinnitus. When there is clinical suspicion, a confirmed diagnosis can only be achieved with high-resolution computed tomography (HRCT). According to Belden et al, the CT positive predictive value for detecting SSCD, using ultra-high resolution and reconstruction in the SC plan, is 93% with a collimation of 0.5 mm.¹⁴ The diagnosis of SSCD is therefore made by combining clinical and radiological findings. Dehiscences of the posterior or lateral semicircular canals are less common.¹⁵ Stimmer et al found dehiscence rates of 12% and 4.6% for the posterior and lateral semicircular canals, respectively, among 125 SSCD.¹⁶ According to Ahren and Thoulin and Lang, isolated tegmen defects occur in approximately 20% of temporal bones.^{17,18}

The association between SSCD and other temporal bone defects has been widely described in the literature. The most common association is the one involving the dehiscence of SSC and tegmen tympani. Minor was the first author to have noticed such an association.¹⁹ In 2016, Rodrigo et al described the common embryological origin of both structures that might explain the high rate of associated dehiscence.²⁰ Suryanarayanan and Lesser reported 3 cases of multiple tegmen defects forming a characteristic “honeycomb” pattern in association with SSCD.²¹ Manzari presented the case of a 38-year-old male with bilateral posterior semicircular canal dehiscence associated with SSCD and typical right-sided vestibular and cochlear symptoms.²² In 2018, Whyte et al studied possible associations between dehiscence in the superior and posterior semicircular canals, and the association of both dehiscences with other alterations in the temporal bone. They reported 28 cases of associations between SSC and tegmen tympani dehiscence and 3 cases that showed multiple temporal bone dehiscences associated with SSCD.²³ Multiple associated dehiscences without radiological evidence have also been recently described as otic capsule dehiscence syndrome.²⁴ In the present report, a case of a man suffering from bilateral SSCD and a unilateral tegmen tympani defect is presented, providing insights into the clinical course and surgical resolution.

Case Presentation

A 43-year-old man was referred to our hospital with an 8-months history of objective, sound/pressure elicited recurring vertigo, left tinnitus, and hearing loss. One year before he suffered from *Streptococcus pneumoniae* meningitis and was successfully treated with vancomycin for 20 days. Under otomicroscopy, a normal right tympanic membrane was found while in the left ear an attic retraction pocket was observed, with a pulsatile mass behind it. Pure tone audiometry showed normal hearing levels in the right ear and moderate conductive hearing loss in the left ear. Stapedial reflexes were present and

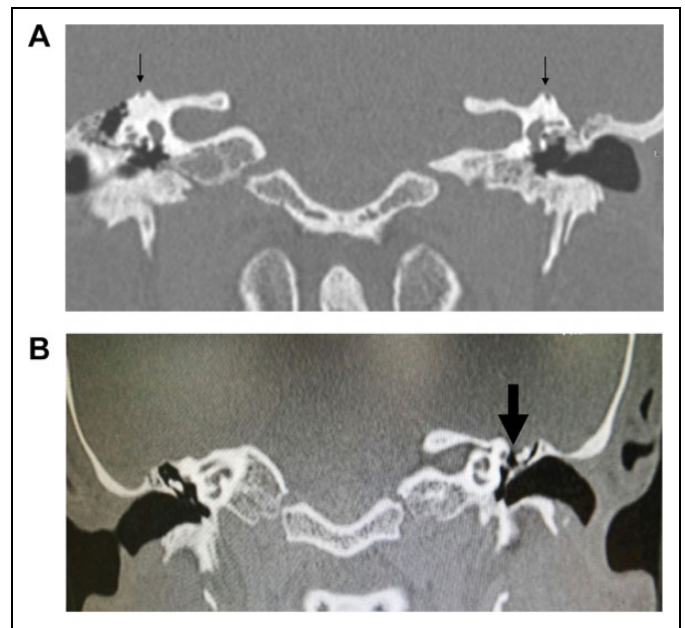


Figure 1. A, Temporal bone high resolution computed tomography (CT). Coronal view showing bilateral superior semicircular canal dehiscence (black arrows). B, Temporal bones high resolution CT. Coronal view showing dehiscence of tegmen tympani on left side (dotted arrow) and thinning on right side; left side meningocele; no aspects of ossicles erosion.

were in the normal range, while tympanometry was type “A” bilaterally, with peak compliance value of 1 mL on the right side and 0.7 mL on the left side. Tullio’s phenomenon was found to be positive on the left side.

A HRCT of the temporal bone revealed bilateral SSC dehiscence, wider on left side; dehiscence of the tegmen tympani and mastoid tegmen on the left side and thinning on the right side; a meningocele imprinting the malleus head and the body of the incus on the left side, without signs of ossicle erosion (Figure 1).

A surgical approach was planned through middle cranial fossa to repair both bony dehiscences (Figure 2). The hair around the area of the planned incision was shaved and the area infiltrated with 2% carbocaine with 1:100000 adrenaline. A piece of temporalis fascia was harvested for later use. Then the area of the craniotomy was exposed, and craniotomy was performed using a 3 mm cutting burr. The bone flap was carefully elevated away from the dura and preserved in saline for later use. A hemostatic microfibrillar absorbable sponge (Equitamp®, Ergon Sutramed s.r.l., Magliano dei Marsi [Aq], Italy) was applied under the bony edges of the craniotomy. A small temporal lobe meningocele was then identified and gently elevated allowing visualization of the eroded area. After detection of the exit of the greater superficial petrosal nerve, the dehiscence of the SSC was identified posteriorly. Both dehiscences were then repaired with bone wax and autologous fascia and stabilized with fibrin glue (Tisseel®, Baxter, Wien, Austria). Owing to the selected approach, it was not possible to get evidence of the condition of the ossicular chain that was

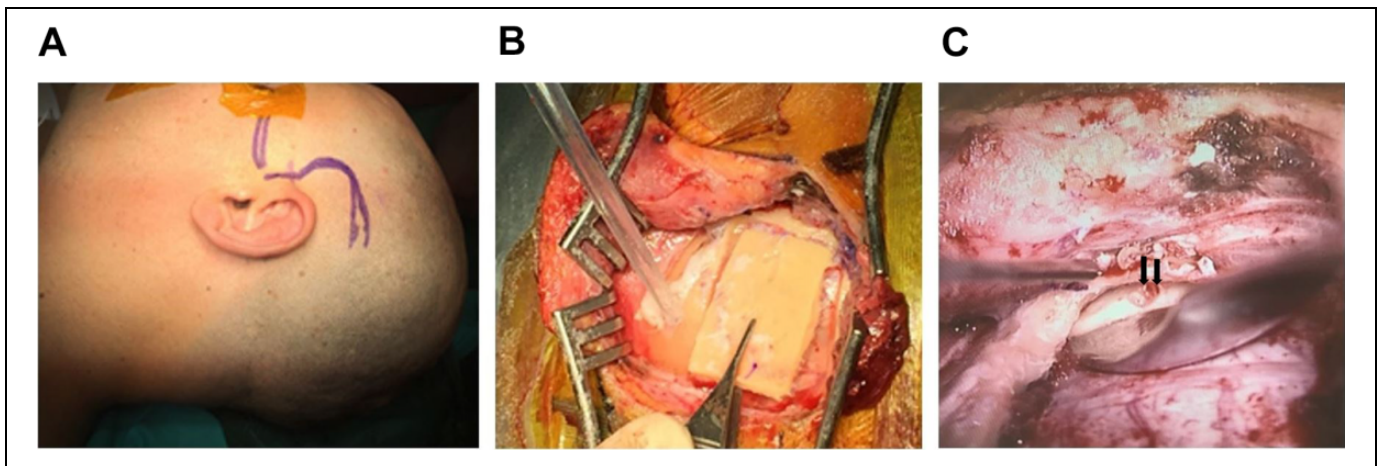


Figure 2. A, Planned incision for middle cranial fossa approach is drawn after hair being shaved. B, A 3 × 4 cm craniotomy is performed, and the bone flap is elevated. C, Bony dehiscences are individuated via a gentle depression of the temporal lobe (black arrows).

however freed from the brain contact. A non-absorbable, heterologous dura (Neuropatch®, BBraun, Milan, Italy) was then placed covering the repaired areas. Closure was achieved by anchoring the previously harvested bone flap in place using titanium plates. The temporal muscle was repositioned with absorbable sutures, and the skin closed with nylon sutures. A compressive dressing was applied. No postoperative complications were experienced by the patient. At otomicroscopy, pulsation at the level of the left attic eardrum had disappeared, as previously described.¹⁰ At the 2 years follow-up, the patient was still devoid of further episodes of imbalance, vertigo or meningitis, with no significant hearing changes.

Discussion

Spontaneous dehiscences affecting the tegmen tympani and superior semicircular canal are considered the most common association in temporal bone defects, with an incidence of 36.4%.¹¹ In 2012, El Hadi et al described that spontaneous tegmen defects had a 56.5% incidence of associated SSC dehiscence, suggesting that they may form a common disorder.²⁵ Nadaraja et al found a 76% association and reported a 10.2 times greater probability of tegmen dehiscence in patients affected by spontaneous SSC dehiscence.²⁶ Recently, Whyte et al reported a 39.4% association of both these defects.²³ Such a strong relationship has been explained by the common embryological origin of both structures.²⁰

From a clinical point of view, this association may be revealed by isolated vestibular or auditory symptoms, or by both or neither of them. According to an analysis by Wackym, the most common symptoms in patients are disequilibrium, headache, dizziness, tinnitus, vertigo, hearing loss, and autophony.²⁴ Signs such as Tullio's phenomenon (sound induced vertigo) and Hennebert's sign (pressure induced nystagmus) are also characteristic. Another clinical feature often found in SSCD is a conductive hearing loss on pure tone audiometry, usually involving the mid-low frequencies. The SSCD creates a

pathological third mobile window in the inner ear that results in a dissipation of the acoustic energy because of the consequent lowered impedance.²

Defects in the tegmen tympani create a communication between the middle ear and the middle cranial fossa exposing the subarachnoid space to potential aggression by pathological agents coming from the middle ear. Sanna et al. described a 27.3% incidence of meningitis as first manifestation in spontaneous tegmen defects,²⁷ while Bruschini et al found a 73.1% incidence of bone defects in otogenic meningitis.²⁸ Furthermore, a defective middle fossa floor can create a pathway through which meningeal and/or cerebral tissue may herniate, potentially resulting in worse complications.²⁸ Surgical treatment is mandatory when life-threatening complications are experienced and is also proposed to symptomatic patients with debilitating symptoms (vertigo, hearing loss, dizziness, etc). Wackym et al found a high rate of psycho-behavioral comorbidities that can mask the symptoms caused by the dehiscence itself especially in pediatric and head-trauma populations.²⁹

Two main surgical approaches may be applied under these circumstances: one through a middle fossa craniotomy approach and the other via a transmastoid route.³⁰ In the present case, the former approach was selected in view of the direct resurfacing of the bony areas where the defects were found.³¹ The reliability of this approach also lies in the more likely preservation of the SC function, against a 10% risk of pancanal loss of function reported with the transmastoid plugging procedure.¹² In fact, the patient in the present report showed no signs of canal function reduction and achieved complete regression of vestibular symptoms, with an overall high satisfaction rate. One major drawback of the selected surgical approach is the impossibility to control the conditions of the ossicular chain. In fact, the post-operative persistence of the conductive hearing loss would prompt planning an exploratory tympanotomy at a later stage.

Conclusions

Spontaneous temporal bone dehiscences represent a rare event, even more so in association with other temporal bone defects. Affected patients usually have debilitating symptoms and, especially in those with a previous history of meningitis, a surgical protocol is strongly recommended.

The definitive diagnosis always requires HRCT. The middle cranial fossa approach may be chosen for a wider and more accurate exposure with the repair of defects.

Declaration of Conflicting Interests

The author(s) declared no potential conflicts of interest with respect to the research, authorship, and/or publication of this article.

Funding

The author(s) received no financial support for the research, authorship, and/or publication of this article.

ORCID iD

Maurizio Barbara  <https://orcid.org/0000-0003-0740-0384>

References

- Sun W, Liang Q, Kuang S, Zhou S, Wang W. 3D-real IR MRI detects serendipity of inner ear in enlarged vestibular aqueduct syndrome. *Acta Otolaryngol*. 2019;139(3):233-237.
- Merchant SN, Rosowski JJ. Conductive hearing loss caused by third-window lesions of the inner ear. *Otol Neurotol*. 2008;29(3):282-289. doi:10.1097/mao.0b013e318161ab24
- Stevens SM, Lambert PR, Rizk H, McIlwain WR, Nguyen SA, Meyer TA. Novel radiographic measurement algorithm demonstrating a link between obesity and lateral skull base attenuation. *Otolaryngol Head Neck Surg*. 2015;152(1):172-179. doi:0.1177/0194599814557470
- Crovetto MA, Whyte J, Rodriguez OM, et al. Influence of aging and menopause in the origin of the superior semicircular canal dehiscence. *Otol Neurotol*. 2012;33(4):681-684. doi:10.1097/MAO.0b013e31824f9969
- Yu A, Teich DL, Moonis G, Wong ET. Superior semicircular canal dehiscence in East Asian women with osteoporosis. *BMC Ear Nose Throat Disord*. 2012;12:8. doi:10.1186/1472-6815-12-8
- Carey JP, Minor LB, Nager GT. Dehiscence or thinning of bone overlying the superior semicircular canal in a temporal bone survey. *Arch Otolaryngol Head Neck Surg*. 2000;126(2):137-147. doi:10.1001/archotol.126.2.137
- Stevens Shawn M, Hock K, Samy Ravi N, Pensak ML. Are patients with spontaneous CSF otorrhea and superior canal dehiscence congenitally predisposed to their disorders. *Otolaryngol Head Neck Surg*. 2018;159:543-552.
- Gacek RR. Arachnoid granulation cerebrospinal fluid otorrhea. *Ann Otol Rhinol Laryngol*. 1990;99(11):854-862. doi:10.1177/000348949009901102
- Minor LB, Solomon D, Zinreich JS, Zee DS. Sound-and/or pressure-induced vertigo due to bone dehiscence of the superior semicircular canal. *Arch Otolaryngol Head Neck Surg*. 1998;124(3):249-258. doi:10.1001/archotol.124.3.249
- Castellucci A, Brandolini C, Piras G, et al. Superior canal dehiscence with tegmen defect revealed by otoscopy: video clip demonstration of pulsatile tympanic membrane. *Auris Nasus Larynx*. 2018;45(1):165-169.
- Crovetto M., Whyte J, Rodriguez OM, Lecumberri I, Martinez C, Eléxpuru J. Anatomic-radiological study of the superior semicircular canal dehiscence: radiological considerations of superior and posterior semicircular canals. *Eur J Radiol*. 2010;76(2):167-172. doi:10.1016/j.ejrad.2009.05.038
- Carey JP, Migliaccio AA, Minor LB. Semicircular canal function before and after surgery for superior canal dehiscence. *Otol Neurotol*. 2007;28(3):356-364. doi:10.1097/01.mao.0000253284.40995.d8
- Berning AW, Arani K, Branstetter BF. Prevalence of superior semicircular canal dehiscence on high-resolution CT imaging in patients without vestibular or auditory abnormalities. *AJNR Am J Neuroradiol*. 2019;40(4):709-712. doi:10.3174/ajnr.A5999
- Belden CJ, Weg N, Minor LB, Zinreich SJ. CT evaluation of bone dehiscence of the superior semicircular canal as a cause of sound-and/or pressure-induced vertigo. *Radiology*. 2003;226(2):337-343. doi:10.1148/radiol.2262010897
- Lee JA, Liu YF, Nguyen SA, McRackan TR, Meyer TA, Rizk HG. Posterior semicircular canal dehiscence: case series and systematic review. *Otol Neurotol*. 2020;41(4):511-521. doi:10.1097/MAO.0000000000002576
- Stimmer H., Hamman KF, Zeiter S, Naumann A, Rummeny EJ. Semicircular canal dehiscence in HR multislice computed tomography: distribution, frequency, and clinical relevance. *Eur Arch Otorhinolaryngol*. 2012;269(2):475-480. doi:10.1007/s00405-011-1688-6
- Åhrén C, Thulin CA. Lethal intracranial complications following inflation in the external auditory canal in treatment of serous otitis media and due to defects in the petrous bone. *Acta Oto-Laryngologica*. 1965;60(1-6):407-421. doi.org/10.3109/00016486509127025
- Lang DV. Macroscopic bony deficiency of the tegmen tympani in adult temporal bones. *J Laryngol Otol*. 1983;97(8):685-688. doi:10.1017/s0022215100094834
- Minor LB. Superior canal dehiscence syndrome. *Am J Otol*. 2000;21:9-19. doi:10.1016/S0196-0709(00)80105-2
- Rodrigo JJF, Cisneros AI, Obon J, et al. Ontogenetic explanation for tegmen tympani dehiscence and superior semicircular canal dehiscence association. *Acta Otorrinolaringologica*. 2016;67:226-232. doi:10.1016/j.otorri.2015.09.006
- Suryanarayanan R, Lesser TH. Honeycomb' tegmen: multiple tegmen defects associated with superior semicircular canal dehiscence. *J Laryngol Otol*. 2010;124(5):560-563. doi:10.1017/S0022215109991411
- Manzari L. Multiple dehiscences of bony labyrinthine capsule. A rare case report and review of the literature. *Acta Otorhinolaryngol Ital*. 2010;30(6):317-320.
- Whyte J, Cisneros AI, Garcia-Barrios A, et al. Association between superior semicircular canal dehiscence and other

- dehiscences in temporal bone [published online December 30, 2019]. *Folia Morphol (Warsz)*. 2019. doi:10.5603/FM.a2019.0138
24. Wackym PA, Wood SJ, Siker DA, Carter DM. Otic capsule dehiscence syndrome: superior semicircular canal dehiscence syndrome with no radiographically visible dehiscence. *Ear Nose Throat J*. 2015;94(8):E8-E9. doi:10.1177/014556131509400802
 25. El Hadi T, Sorrentino T, Calmels MN, Fraysse B, Dequine O, Marx M. Spontaneous tegmen defect and semicircular canal dehiscence: same etiopathogenic entity? *Otol Neurotol*. 2012;33:591-595. doi:10.1097/MAO.0b013e31824bae10
 26. Nadaraja GS, Gurgel RK, Fischbein NJ, et al. Radiographic evaluation of the tegmen in patients with superior semicircular canal dehiscence. *Otol Neurotol*. 2012;33(7):1245-1250. doi:10.1097/MAO.0b013e3182634e27
 27. Sanna M, Fois P, Russo A, Falcioni M. Management of meningoencephalic herniation of the temporal bone: personal experience and literature review. *Laryngoscope*. 2009;119(8):1579-1585. doi:10.1002/lary.20510
 28. Bruschini L, Fortunato S, Tascini C, et al. Otogenic meningitis: a comparison of diagnostic performance of surgery and radiology. *Open Forum Infect Dis*. 2017;4(2). doi:10.1093/ofid/ofx069. Oxford University Press.
 29. Wackym PA, Mackay-Promitas HT, Demirel S, et al. Comorbidities confounding the outcomes of surgery for third window syndrome: outlier analysis. *Laryngoscope Investig Otolaryngol*. 2017;2(5):225-253. doi:10.1002/lio2.89
 30. Schwartz SR, Almosnino G, Noonan KY, Banakis Hartl RM, Zeitler DM, Saunders JE, Cass SP. Comparison of transmastoid and middle fossa approaches for superior canal dehiscence repair: a multi-institutional study. *Otolaryngol Head Neck Surg*. 2019;161(1):130-136.
 31. Ward BK, Carey JP, Minor LB. Superior canal dehiscence syndrome: lessons from the first 20 years. *Front Neurol*. 2017;28(8):177. doi:10.3389/fneur.2017.00177