

Unusual Symptomatology in Eagle Syndrome

Annalisa Pace, Valeria Rossetti , Giannicola Iannella and Giuseppe Magliulo 

Organi di Senso Department University, Sapienza University of Rome, Viale del Policlinico, 151, 00161 Rome, Italy.

Clinical Medicine Insights: Case Reports
Volume 13: 1–2
© The Author(s) 2020
Article reuse guidelines:
sagepub.com/journals-permissions
DOI: 10.1177/1179547620948728



ABSTRACT: A 20-year-old female presented a history of isolate left external ear pain. ENT valuation showed no alteration of the district, but an aberrant styloid process was tender to palpation in the left tonsillar fossa. Computer tomography was performed and confirmed it. Thereafter, the diagnosis of Eagle syndrome was made. The auricular branch of the vagal nerve (ABVN) was pressed by the styloid process causing the pain. This case pointed out the importance to consider anatomical alteration as elongated styloid process as a possible cause of external ear pain.

KEY WORDS: Eagle syndrome, external ear pain, elongated styloid process

RECEIVED: April 24, 2020. **ACCEPTED:** May 22, 2020.

TYPE: Case Report

FUNDING: The author(s) received no financial support for the research, authorship, and/or publication of this article.

DECLARATION OF CONFLICTING INTERESTS: The author(s) declared no potential conflicts of interest with respect to the research, authorship, and/or publication of this article.

CORRESPONDING AUTHOR: Giuseppe Magliulo, Organi di Senso Department University, Sapienza University of Rome, Viale del Policlinico, 151, 00161 Rome, Italy. Email: giuseppemagliuloorl@yahoo.com

Introduction

Eagle syndrome is a rare condition characterized by an elongated styloid process and/or calcification of the styloid ligament, thus affecting the function of cranial nerves.¹

Patients usually present with dysphagia and foreign body sensation and, occasionally, transient ischemic attacks, cerebrovascular insults, and carotid artery dissection.^{2,3} In this case report, the syndrome was present with a single unusual symptom: pain in a portion of the left external ear.

Case Report

A 20-year-old female presented with a history of left external ear pain. She described tenderness and pain on the whole left side of the concha, antitragus, part of the tragus, and part of antihelix. She did not describe odynophagia, foreign body sensation, hemifacial pain, or tenderness. Otoscopic examination showed a normal tympanic membrane, semi-transparent and pearly gray-colored, without swelling of the skin above the external canal. Anterior rhinoscopy and oropharyngoscopy were unremarkable, but palpation of the left tonsillar fossa showed an aberrant styloid process. Computed tomography and 3-dimensional reconstruction confirmed the presence of an elongated left styloid process that pressed on the vagus nerve. (Figures 1–2) A diagnosis of Eagle syndrome was established. The patient underwent surgical treatment with a styloidectomy by a traditional transoral approach. Styloid ligament appeared calcified. At 5-year follow-up examination, she was symptom free.

Patients wrote an informed consent form for publication of data.

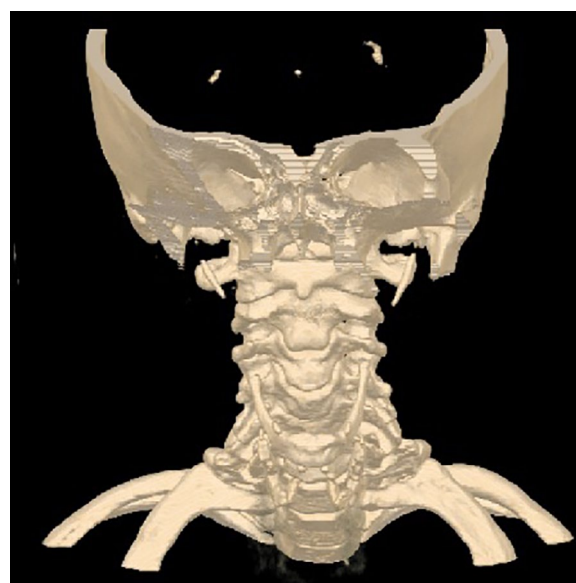

Figure 1. Three-dimensional reconstruction of computed tomography images. A transverse view showed the elongated left styloid process.

Discussion

Eagle syndrome is a rare condition that may manifest with a constant, dull pharyngeal pain or with pain and symptoms of carotid compression.

The patient described here presented only 1 unusual symptom: pain in a portion of the left external ear. It is known that external ear innervation is supplied by 3 nerves: glossopharyngeal, facial, and vagus nerves.⁴



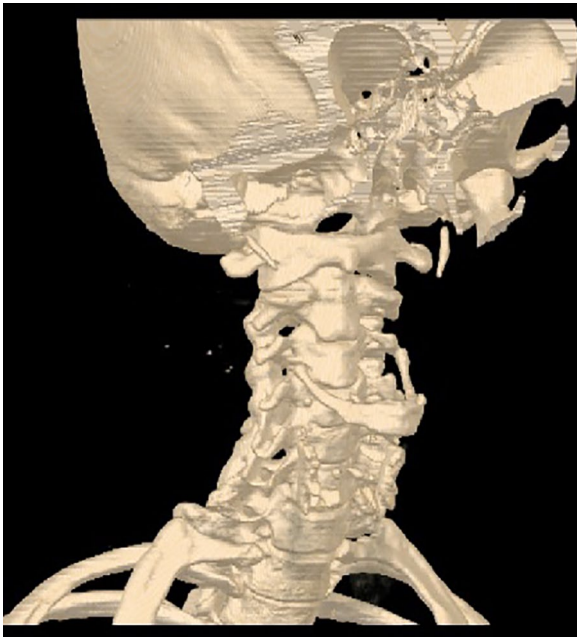


Figure 2. Three-dimensional reconstruction of computed tomography images. A coronal view showed the elongated left styloid process.

According to the localization of the pain, vagus neuralgia was identified. The auricular branch of the vagus nerve (ABVN), also known as the Arnold nerve, is a somatic afferent nerve which, in the mastoid, crosses the Fallopian canal about 3 to 4 mm above the stylomastoid foramen, before its division into 2 branches. Its fibers convey from the concha of the auricle and adjacent external auditory canal.⁵ Furthermore, the ABVN and its function explained the patient's symptomatology. In

fact, the latter was the result of mechanical compression of the ABVN produced by the elongated styloid process. This was proved by the absence of symptomatology during follow-up.

Author Contributions

AP: Design of the study;

VR: Drafting the article;

GI: Revising it critically for important intellectual content;

GM: Concept and final approval of the version to be submitted.

Informed Consent

Patients wrote an informed consent form for publication of data. Medical research was conducted according to the World Medical Association Declaration of Helsinki.

ORCID iDs

Valeria Rossetti  <https://orcid.org/0000-0002-3956-2831>

Giuseppe Magliulo  <https://orcid.org/0000-0003-3052-1969>

REFERENCES

1. Badhey A1, Jategaonkar A, Anglin Kovacs AJ, et al. Eagle syndrome: a comprehensive review. *Clin Neurol Neurosurg.* 2017;159:34-38.
2. Bai C, Wang Z, Guan J, et al. Clinical characteristics and neuroimaging findings in eagle syndrome induced internal jugular vein stenosis. *Ann Transl Med.* 2020;8:97.
3. Cohn JE, Othman S, Sajadi-Ernazarova K. Eagle syndrome masquerading as a chicken bone. *Int J Emerg Med.* 2020;13:1.
4. Watanabe K, Tubbs RS, Satoh S, et al. Isolated deep ear canal pain: possible role of auricular branch of vagus nerve—case illustrations with cadaveric correlation. *World Neurosurg.* 2016;96:293-301.
5. Butt MF, Albusoda A, Farmer AD, Aziz Q. The anatomical basis for transcutaneous auricular vagus nerve stimulation. *J Anat.* 2020;236:588-611.