

Minimally invasive video-assisted thyroidectomy and transoral video-assisted thyroidectomy: A comparison of two systematic reviews

Francesco Tartaglia¹, Alessandro Giuliani², Salvatore Sorrenti¹, Salvatore Ulisse¹

¹Department of Surgical Sciences, 'Sapienza' University of Rome, Rome, Italy, ²Department of Environment and Health, Superior Institute of Health, Rome, Italy

Abstract

Background: We compared two systematic reviews, one focusing on transoral video-assisted thyroidectomy (TOVAT) and the other on minimally invasive video-assisted thyroidectomy (MIVAT), to highlight the pros and cons that can determine the choice of one or the other procedure.

Materials and Methods: PubMed, Scopus and ISI Web of Science databases were searched for relevant articles published from 2000 to June 2018. Both searches were performed using the same keywords. All articles describing human surgical case series of any size were included, while the following were excluded: articles published in languages other than English, case reports, reviews, early cadaver and animal studies and old reports of cases now included in more recent works. Application of the above selection criteria yielded 151 articles on TOVAT and 246 on MIVAT. Of these, 34 articles were selected for inclusion in the present study: 17 for the TOVAT group and 17 for the MIVAT group. The comparison was made considering the most common variables used in evaluating thyroid surgery procedures. The statistical methods used were Cohen's delta, Student's *t*-test and the non-parametric Mann–Whitney U-test.

Results: The variable 'operative time' was found to show a very large effect size, and 'hospital stay' also differed significantly between the MIVAT and TOVAT groups.

Conclusions: TOVAT and MIVAT should not be considered in competition with each other, but seen simply as alternative choices. Both appear to be safe methods, comparable in terms of post-operative complications, although the main reason for using TOVAT seems to be purely aesthetic.

Keywords: Minimally invasive video-assisted thyroidectomy, thyroid surgery, transoral video-assisted thyroidectomy

Address for correspondence: Prof. Francesco Tartaglia, Largo Pannonia, 48, Rome 00183, Italy.

E-mail: francesco.tartaglia@uniroma1.it

Submitted: 24-May-2019, **Accepted in Revised Form:** 04-Feb-2020, **Published:** 28-Mar-2020

INTRODUCTION

Minimal access to thyroid surgery (MATS) has increasingly gained popularity among surgeons over the past two decades, as it can greatly reduce or avoid surgical scarring

while maintaining ease of access to the neck region. MATS procedures can be broadly divided into three categories: completely endoscopic, partly endoscopic and non-endoscopic. Minimally invasive video-assisted

This is an open access journal, and articles are distributed under the terms of the Creative Commons Attribution-NonCommercial-ShareAlike 4.0 License, which allows others to remix, tweak, and build upon the work non-commercially, as long as appropriate credit is given and the new creations are licensed under the identical terms.

For reprints contact: reprints@medknow.com

How to cite this article: Tartaglia F, Giuliani A, Sorrenti S, Ulisse S. Minimally invasive video-assisted thyroidectomy and transoral video-assisted thyroidectomy: A comparison of two systematic reviews. *J Min Access Surg* 0;0:0.

Access this article online	
Quick Response Code:	Website: www.journalofmas.com
	DOI: 10.4103/jmas.JMAS_123_19

thyroidectomy (MIVAT), a partly endoscopic procedure, is currently the most widely used MATS method.^[1]

In recent times, several unconventional thyroid surgery approaches have been developed with the aim of eliminating the problem of neck scarring, especially in young women. These include single/bilateral axillary and retroauricular approaches, mammary areola access and transoral video-assisted thyroidectomy (TOVAT), the latter a technique first proposed by Witzel *et al.* in 2008^[2] and subsequently modified by numerous authors, especially from Asia. TOVAT is an example of natural orifice transluminal endoscopic surgery (NOTES), the use of natural cavities as access points for videoscopic and robotic instruments. TOVAT falls into the ‘completely endoscopic’ category of MATS procedures.

We recently performed a systematic review of the TOVAT case series to evaluate the feasibility and safety of the method.^[3] The present study was instead conducted to compare TOVAT with MIVAT, given that the two methods share an almost identical set of indications and contraindications. MIVAT is considered a direct access procedure with a favourable cosmetic outcome, whereas TOVAT is a remote access procedure that aims to spare patients post-surgical neck scarring. The present comparison of these procedures is not intended to set them in competition with each other, simply to highlight the pros and cons that can determine the choice of one or the other.

MATERIALS AND METHODS

We conducted two systematic reviews of the English language literature dealing with MIVAT and TOVAT, respectively. PubMed, Scopus and ISI Web of Science databases were searched for relevant articles published from 2000 to June 2018. Both searches were performed using the same keywords: endoscopic thyroidectomy, mini-invasive video-assisted thyroidectomy (MIVAT), robotic thyroidectomy, thyroidectomy, thyroid surgery, transoral endoscopic thyroidectomy vestibular approach (TOETVA), and TOVAT. All articles describing human surgical case series of any size were included, while the following were excluded: articles published in languages other than English, case reports, reviews, early Cadaver and animal studies and old reports of cases now included in more recent works. The application of the above selection criteria yielded 151 articles on TOVAT and 246 on MIVAT. Of these, 34 articles were selected for inclusion in the present study: 17 for the TOVAT group^[4-20] and 17 for the MIVAT group.^[21-37] Figure 1 describes the above selection process in more detail.

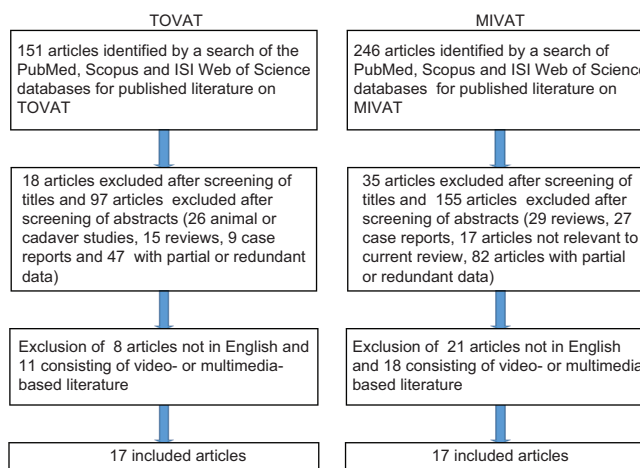


Figure 1: The flowcharts of the two reviews. TOVAT: Transoral video-assisted thyroidectomy. MIVAT: Minimally invasive video-assisted thyroidectomy

Our review of the literature on TOVAT included 17 different studies published by 17 different groups of authors between 2011 and 2018 [Summarised in Tables 1 and 2]. This review has already been reported in a previous article published in the Journal of Surgery.^[3] The review of MIVAT literature also included 17 studies, again by different authors, but in this case, they spanned a longer period (from 2001 to 2018), given that MIVAT was introduced into clinical practice earlier than TOVAT, at the beginning of the 2000s [Tables 3 and 4]. Nevertheless, we do not believe that there are any biases in our study due to the technical evolutions in the field of thyroid surgery.

The two reviews were compared by three of the authors of the present study, working independently but each focusing on the same variables, namely: first author’s country of origin, publication year, number of cases included, length of hospital stay, surgical conversion rate, type of approach, total number of thyroidectomies and lobeisthmectomies, operative time, intra-operative blood loss, and number and rate of complications: inferior laryngeal nerve palsy (transient and permanent), hypoparathyroidism (transient and permanent), post-operative haematoma, post-operative seroma, surgical wound infections and mental nerve injury (the latter considered only in TOVAT). Any discrepancies in the three authors’ findings were resolved by consensus after discussion between them.

The variable ‘operative time’ was analysed by calculating its effect size based on differences between means (Cohen’s delta). In this case, the between-studies homogeneity, and the fact that both mean values and standard deviations were reported for each study, allowed us to consider single patients as statistical units and collate these data into the

Table 1: Studies included in the systematic review on transoral video-assisted thyroidectomy

Author (year)	Nationality (country)	Number of cases	TT	HT	Approach	Conversion (%)	Operative time (min), mean or mean±SD	Blood loss (ml)	Hospital stay (days)
Anuwong (2018)	Thailand	422	177	245	Tri-vestibular	3 (0.71)	100.8±39.7	153	2.5
Chai (2017)	South Korea	7	0	7	Tri-vestibular	0	121.1±30.7	-	3.6
Chen (2018)	Taiwan	20	8	12	Tri-vestibular	0	145.5±50.34	-	-
Dionigi (2018)	Italy	15	5	10	Tri-vestibular	0	107.6	47	2.5
Fu (2018)	China	79	10	69	Combined (oral-vestibular)	2 (2.53)	89.0±38.6	30	4.77
Jitpratoom (2016)	Thailand	45	45	0	Tri-vestibular	1 (2.22)	134.11±31.48	63	-
Kim (2016)	South Korea	24	0	24	Tri-vestibular/robotic	0	232±41	-	3.5
Nakaio (2012)	Japan	8	3	5	Tri-vestibular	0	208	97	4.5
Park (2016)	South Korea	18	2	16	Tri-vestibular	0	170.55	-	5
Russell (2017)	USA	12	0	12	Tri-vestibular/robotic	1 (8.33)	288.5	-	1
Udelsman (2016)	USA	5	2	3	Tri-vestibular	0	222±77	20	1.5
Wang C (2013)	China	12	4	8	Tri-vestibular	0	60.4±17.4	11	4.9
Wang Y (2016)	China	10	1	9	Tri-vestibular	0	203.5	-	4.5
Wilhelm (2011)	Germany	8	4	4	Combined (oral-vestibular)	3 (37.5)	239±54	57	3
Yang J. (2015)	China	41	19	22	Tri-vestibular	0	72.1±19.5	11	5
Yang K. (2016)	China	6	0	6	Tri-vestibular	0	122	25	9
Zeng (2016)	China	4	0	4	Tri-vestibular	0	189.00±39.14	8	5
Total		736	280	456					

TT: Total thyroidectomy, HT: Hemithyroidectomy, SD: Standard deviation

Table 2: Complications reported in the different transoral video-assisted thyroidectomy series

Author (year)	Number of cases	Haematoma (%)	TILNP (%)	PILNP (%)	THP (%)	PHP (%)	MNI (%)	Infections (%)	Seroma (%)
Anuwong (2018)	422	1 (0.23)	25 (5.9)	0	46 (10.9)	0	3 (0.7)	0	20 (4.7)
Chai (2017)	7	0	2 (28.57)	0	-	-	0	0	0
Chen (2018)	20	0	0	0	3 (15)	0	1 (5)	0	0
Dionigi (2018)	15	0	0	0	1 (6.66)	0	0	0	0
Fu (2018)	79	0	0	0	0	0	-	6 (7.06)	0
Jitpratoom (2016)	45	0	4 (8.9)	0	10 (22.2)	0	0	0	0
Kim (2016)	24	0	0	0	0	0	9 (37.5)	0	0
Nakaio (2012)	8	0	0	1 (12.5)	0	0	0	0	0
Park (2016)	18	0	0	0	1 (5.55)	0	0	0	2 (11.1)
Russell (2017)	12	0	1 (8.33)	0	0	0	1 (8.33)	0	0
Udelsman (2016)	5	0	0	0	0	0	0	0	0
Wang C (2013)	12	0	0	0	0	0	0	0	0
Wang Y (2016)	10	0	0	0	1 (10)	0	0	0	0
Wilhelm (2011)	8	0	1 (12.5)	1 (12.5)	0	0	6 (75)	1 (12.5)	0
Yang J. (2015)	41	0	1 (2.43)	0	0	0	-	0	0
Yang K. (2016)	6	0	0	0	0	0	0	1 (16.66)	0
Zeng (2016)	4	0	0	0	0	0	0	0	0
Total	736	1 (0.13)	34 (4.61)	2 (0.26)	62 (8.42)	0 (0)	20 (2.71)	8 (1.08)	22 (2.99)

TILNP: Transient inferior laryngeal nerve palsy, PILNP: Permanent inferior laryngeal nerve palsy, THP: Transient hypoparathyroidism, PHP: Permanent hypoparathyroidism, MNI: Mandibular nerve injuries

TOVAT and MIVAT samples; the fact that we were able to use such a large number of data meant that we were able to obtain very high statistical power. This is why Cohen's delta is a more reliable measure of effect than the probabilistic kind (the reaching of statistical significance being assured even with a very small effect by the disproportionately high number of patients). Instead, to analyse the 'blood loss' and 'hospital stay' variables, the two reviews had to be compared using Student's *t*-test, given that, in this case, all we had at our disposal were the average values yielded by the single studies, without any data on their internal variability. Accordingly, we had to take, as statistical units, not the single patients but rather the single studies included in each of the two samples. Finally, since all the other variables showed a strongly non-Gaussian data distribution due to the disproportionate frequency of null values, in

these cases, we used the non-parametric Mann-Whitney U-test to compare the two study populations (TOVAT and MIVAT). The variable 'mental nerve injury' was excluded from the comparison, being present only in the TOVAT group. Results were considered statistically significant at $P < 0.05$.

RESULTS

Thirteen of the 17 articles included in the review on TOVAT were by Asian authors, specifically from China ($n = 7$), Thailand ($n = 2$), South Korea ($n = 2$), Taiwan ($n = 1$) and Japan ($n = 1$); two were by US authors, and the other two by Europeans (1 Italian and 1 German). Together, these papers reported a total of 736 procedures: 289 total thyroidectomies and 447 loboisthmectomies.

Table 3: Studies included in the systematic review on minimally invasive video-assisted thyroidectomy

Author (year)	Nationality (country)	Number of cases	TT	HT	Approach	Conversion rate	Operative duration (min), median±SD or range	Blood loss (ml)	Hospital stay (days)
Alesina (2010)	Italy	75	38	37	MIVAT	0	63±24	-	2
Barczyński (2012)	Poland	240	30	210	MIVAT	0	38.6±15.1	-	-
Bellotti (2018)	Italy	110	110	0	MIVAT	0	74±7.2	-	-
Chao (2004)	Taiwan	52	0	52	MIVAT	0	62.2±13.0	33	2
Del Rio (2015)	Italy	497	497	0	MIVAT	0	48±8.4	-	-
Dobrinja (2009)	Italy	68	23	45	MIVAT	0	35-175	-	1.75
Duke (2015)	USA	260	91	169	MIVAT	0	-	-	-
El-Labban (2009)	Egypt	38	0	38	MIVAT	0	62±21	39	1.2
Fan (2010)	China	300	118	182	MIVAT	20 (6.66)	20-90	-	2.5
Frank (2016)	USA	583	234	349	MIVAT	0	86.5±39.3	24	-
Gal (2008)	Hungary	15	4	11	MIVAT	0	65.5±18	-	-
Haitao (2014)	China	200	84	116	MIVAT	6 (3%)	20-110	-	1.89
Hegazy (2007)	Egypt	33	29	4	MIVAT	0	90-190	31	-
Miccoli (2015)	Italy	2412	1848	564	MIVAT	41 (1.7)	41±14	-	1.5
Park (2001)	South Korea	466	217	249	MIVAT	0	57.6±11.7	18	1.6
Ruggieri (2005)	Italy	11	8	3	MIVAT	1 (9.1)	170	-	-
Sami (2010)	UK	64	51	13	MIVAT	4 (6.3)	60-140	-	1
Total		5424	3382	2042					

MIVAT: Minimally invasive video-assisted thyroidectomy, TT: Total thyroidectomy, HT: Hemithyroidectomy, SD: Standard deviation

Table 4: Complications reported in the different minimally invasive video-assisted thyroidectomy series

Author (year)	Number of cases	Haematoma (%)	TILNP (%)	PILNP (%)	THP (%)	PHP (%)	Infections (%)	Seroma (%)
Alesina (2010)	75	0	0	0	2 (2.66)	0	0	0
Barczyński (2012)	240	0	8 (3.0)	2 (0.7)	13 (5.4)	0	2 (0.4)	0
Bellotti (2018)	110	0	2 (1.81)	1 (0.9)	11 (10)	1 (1.05)	1 (0.9)	0
Chao (2004)	52	0	3 (5.8)	0	-	0	0	0
Del Rio (2015)	497	1 (0.2)	12 (2.4)	4 (0.8)	36 (7.2)	1 (0.2)	0	0
Dobrinja (2009)	68	2 (2.9)	2 (2.9)	0	3 (4.41)	0	0	0
Duke (2015)	260	0	10 (3.84)	0	6 (2.3)	0	1 (0.38)	0
El-Labban (2009)	38	0	2 (5.3)	1 (2.6)	0	2 (5.3)	0	0
Fan (2010)	300	0	7 (2.3)	5 (1.7)*	9 (3)	0	0	0
Frank (2016)	583	0	56 (9.6)	1 (0.17)	59 (10.1)	3 (0.51)	0	0
Gal (2008)	15	0	0	0	0	0	0	0
Haitao (2014)	200	0	6 (3.0)	1 (0.5)	7 (3.5)	0	0	0
Hegazy (2007)	33	0	1 (3.03)	0	1 (3.03)	0	0	0
Miccoli (2015)	2412	3 (0.12)	-	30 (1.24)	120 (4.97)	10 (0.41)	3 (0.12)	-
Park (2001)	466	1	3 (0.64)	0	11 (2.36)	0	0	5 (1.07)
Ruggieri (2005)	11	-	2 (18.18)	-	-	-	-	-
Sami (2010)	64	0	7 (11)	2 (3.00)	2 (3.00)	0	-	0
Total	5424	6 (0.11)	121 (2.23)	47 (0.86)	280 (5.16)	17 (0.31)	7 (0.12)	5 (0.09)

TRLNP: Transient inferior laryngeal nerve palsy, PRLNP: Permanent inferior laryngeal nerve palsy, THP: Transient hypoparathyroidism, PHP: Permanent hypoparathyroidism

In the vast majority of studies ($n = 15$), the surgical approach was trivestibular (performed using videoscopic instruments in 13 and surgical robots in two). In the other two studies, a combined surgical approach (oro-vestibular) was used. Anuwong *et al.*^[4] published the largest case series, numbering 422 cases (177 total thyroidectomies and 245 loboisthmectomies). Only 40 surgeries (11 total thyroidectomies and 29 loboisthmectomies) were performed outside Asia.

Conversely, the review of literature on MIVAT included only four works by Asian authors (2 Chinese, 1 South Korean and 1 Taiwanese), whereas nine of the studies were by authors from European countries (6 from Italy, and 1 each from Hungary, Poland and the UK). It also included two from the US and two by Egyptian authors. This

review included a total of 5424 procedures: 3382 total thyroidectomies and 2042 loboisthmectomies. Miccoli's *et al.* was the largest series with 2412 cases (1848 total thyroidectomies and 564 loboisthmectomies).^[34]

The TOVAT and MIVAT groups were compared for the following variables: operative time, blood loss, length of hospital stay, transient and permanent inferior laryngeal nerve palsy, transient and permanent hypoparathyroidism, post-operative haematoma, post-operative seroma and surgical wound infections. As mentioned, for the first of these comparisons, the single patients were taken as the statistical units, since most of the articles reported the standard deviations. In this case, the first step was to calculate the weighted means and standard deviations of all the studies, eliminating all patients included in

studies where standard deviations were not given. On this basis, we eliminated 69 patients from the TOVAT group (which was thus reduced to 667 patients) and 936 from the MIVAT group (reducing it to 4488 patients). The resulting mean \pm SD for ‘operative time’ (in minutes) was 108.47 ± 68.72 for the TOVAT patients and 50.92 ± 16.51 for the MIVAT ones. We then calculated Cohen’s delta which, in the case of such a large population of patients (5155 in total), better describes any between-group difference found. In statistics, an effect size is a quantitative measure of the magnitude of a phenomenon, and in our case, Cohen’s delta was defined as the difference between two means divided by a standard deviation for the data. Therefore, Cohen’s delta = (TOVAT mean–MIVAT mean)/([TOVAT SD \pm MIVAT SD]/2)), and the result was 1.35 which corresponds to a ‘very large’ effect, as defined in Table 5.^[38,39] The corresponding *t*-test ($P < 0.00001$) was highly significant but, as we stressed in the Methods section, the huge number of patients made it more appropriate to use effect size statistics as opposed to an inferential approach.

For the variables ‘blood loss’ and ‘hospital stay’, the statistical units were the single scientific works, not the patients, since the individual papers reported only mean values without standard deviations. We used Student’s *t*-test to compare the two groups and found them to differ significantly for ‘hospital stay’ ($P < 0.001$) and non-significantly for ‘blood loss’ ($P < 0.33$).

Finally, due to the presence of a non-Gaussian data distribution, we used the non-parametric Mann–Whitney U-test to compare the two groups for complications. No statistically significant differences emerged in this regard [Table 6].

DISCUSSION

In the field of thyroid surgery, minimally invasive techniques are indicated solely for the small lesions (<30 ml volume) encountered, in our experience, in no more than 5%–10% of treated patients. It should, therefore, be borne in mind that thyroid surgery as a whole continues to be based largely on open techniques.

When indicated, however, MIVAT, now supported by 20 years of experience, appears to be a very valid technique. When performed in centres of excellence, it has practically the same incidence of specific complications as traditional surgery.

Recent years have brought a growing awareness of the possibility of using natural orifices as the access route

Table 5: Descriptors for different magnitudes of d, as initially suggested by Cohen and expanded by Sawilowsky

Magnitude of d	Effect size	Reference
0.01	Very small	Sawilowsky, 2009
0.20	Small	Cohen, 1988
0.50	Medium	Cohen, 1988
0.80	Large	Cohen, 1988
1.20	Very large	Sawilowsky, 2009
2.0	Huge	Sawilowsky, 2009

Table 6: Results of the comparison of complications between the two samples, performed using the Mann–Whitney U-test

Variable	U	Critical value of U at P<0.05	Z-score	P
Conversion rate	11	2	-0.20889	0.83366
Haematoma	111	81	-0.88254	0.37886
Seroma	120	75	0.26434	0.79486
Infections	122	75	-0.18881	0.84930
TILNP	87	81	-1.74706	0.08012
PILNP	84.5	81	-1.83712	0.06576
THP	93	70	-1.0475	0.29372
PHP	93.5	81	-1.51292	0.13104

No result reached the level of significance ($P < 0.05$). TILNP: Transient inferior laryngeal nerve palsy, PILNP: Permanent inferior laryngeal nerve palsy, THP: Transient hypoparathyroidism, PHP: Permanent hypoparathyroidism

for many surgical procedures. In endocrine surgery, too, alternative approaches have been proposed with the aim of performing partial or total thyroidectomies without causing neck scarring, which is an important advantage, especially in young female patients. The latest of these techniques is TOVAT, in which laparoscopic trocars were initially introduced through the floor of the mouth; however, the technique has since been modified to exploit the vestibular approach. An advantage of TOVAT is that scars remain concealed in the oral mucosa. Furthermore, its proponents argue that it allows the application of broader selection criteria in terms of thyroid volume and nodule size, and can facilitate the post-operative course, especially compared with other minimally invasive approaches.

Both of our reviews focussed on the variables most frequently used in the literature to evaluate the effectiveness of thyroid surgery. Unfortunately, since there are no scientific studies in which the two methods were used and compared by the same authors, we could not perform a meta-analysis of the data. Instead, we used other statistical methods to compare the results of the two reviews, as reported in the Methods section.

The fact MIVAT has been in use considerably longer than TOVAT, with the result that its results are no longer affected by the learning curve, could have created a bias in our study. Nevertheless, the TOVAT studies we considered included a number of large series, in which the effect of the learning curve can certainly be said to have been

overcome. Therefore, we consider this difference unlikely to have influenced our findings.

The geographical origins of the authors were found to differ considerably between the two groups. The vast majority of the first authors in the TOVAT group (13 out of 17) are Asian, whereas in the MIVAT group, only four authors are Asian and most are European. Furthermore, no one author contributed to both reviews, which suggests that most proponents of TOVAT do not have previous experience with MIVAT.

No difference in the rate of surgical conversion emerged between the two methods. However, it is important to underline that whereas conversion from MIVAT to open surgery simply means increasing the size of the neck incision, converting from TOVAT means creating new access and thus leaving the patient with both an endoral and a neck scar. This eventuality should be carefully explained to patients before surgery and should be specifically mentioned in the written informed consent form.

Already realising that the variable ‘operative time’ was going to differ markedly between the two methods, to better analyse it, we calculated its ‘effect size’ based on differences between means. As mentioned, this is an approach that, in a large population like this (5155 patients), is better able to describe differences between two groups. The effect size was found to be very large, this result reflecting the fact that TOVAT, even when performed in centres of excellence, is a much more time-consuming procedure than MIVAT. Obviously, this large effect size impacts greatly on operating room costs and the duration of anaesthetic procedures. It is well established in the literature that remote access procedures have longer operative times and are associated with longer hospital stays compared with direct access procedures. This is attributed to the distance between the access point and the thyroid compartment and thus, the more extensive dissection required. Although we were not surprised by the outcome of this comparison, and recognise that TOVAT is necessarily time consuming, we do not think these excessively long surgeries can be justified solely by aesthetic considerations or patient preferences.

The two groups did not differ significantly with regard to ‘blood loss’, a finding that prompts us to suggest that this variable could perhaps be omitted. After all, blood loss during a perfectly executed total thyroidectomy is generally insignificant and certainly does not determine haemodynamically significant effects, even though in minimally invasive surgery, it can be a cause of conversion. Post-operative bleeding, of course, is another thing

altogether; referred to among our variables as haematoma, it often necessitates reoperation.

‘Hospital stay’ showed a statistically significant difference between the groups. Like ‘operative time’, this variable affects the overall costs of the procedure, although this is due not so much to the method used as to the possible onset of postoperative hypocalcaemia, which can arise even as long as 48–72 h after the surgery, especially in hyperfunctioning goitres. In addition, the length of hospital stay varies according to local practices: the US authors, generally accustomed to short stays, habitually discharged their patients 24 h after TOETVA or MIVAT, whereas in the Asian and European studies hospital stays were prolonged beyond the 2nd day, probably to monitor the levels of post-operative calcaemia;^[40-52] this is indeed in line with our practice.

To evaluate the main complications associated with the two methods, we examined transient and definitive inferior laryngeal nerve palsy, transient and definitive hypoparathyroidism, post-operative haematomas necessitating reoperation, seromas and surgical wound infections. No statistically significant differences were found, although it should be noted that not all the authors in the TOVAT group reported definitive hypoparathyroidism, and only two of the 17 studies reported definitive inferior laryngeal nerve palsy.

Paralysis of the terminal branches of the inferior alveolar nerve (i.e. the variable ‘mental nerve injury’) deserves a special mention, being associated only with TOVAT. The frequency of this complication has actually decreased since the technique was modified, moving the point of lateral trocar insertion closer to the back of oral vestibule. However, other types of complications have been reported with TOVAT, such as flap perforation, subcutaneous emphysema, and an almost constant ‘pulling sensation along the surgical track that resulted in a poor outcome in some scales of the 36-Item Short Form Survey (SF-36)’.^[53] In our view, the pursuit of a better aesthetic result is not, on its own, a justifiable reason for adding to the list of possible complications associated with thyroid surgery. Moreover, aesthetic problems linked to the cervical surgical wound are certainly not the rule in open surgery and do not appear to be related to the type of skin suture. They can occur in a completely random manner from patient to patient, and can also depend on the body regions involved, irrespective of the type of suture used.^[54,55] Often the causes are genetic. Familial inheritance with a predominantly autosomal dominant mechanism is known.^[56] However, there is no clinical evidence that the surgical method influences

the aesthetic result.^[57] Some studies show that surgical wounds should be evaluated over a period of time, even as long as 18 months, and that the aesthetic result generally improves over time.^[58] Of course, in young patients with a history of post-operative hypertrophic scars, it is worth seriously considering TOVAT, but were young age and a positive history to be taken as the sole criteria for its use, the method would probably end up being applied in an absolute minority of cases.

Patient satisfaction with the surgical approach does not seem to differ between MIVAT and TOVAT patients, and even though, in the studies here considered, this parameter was not always evaluated with appropriate questionnaires like the Short Form SF-36. From this perspective, the impact of longer surgeries and hospital stays, and the potential for unconventional morbidities acquire real relevance.

CONCLUSIONS

TOVAT and MIVAT are two procedures belonging to different MATS categories. They should not be considered to be in competition with each other but regarded simply as alternative choices. MIVAT and TOVAT both appear to be safe methods, comparable in terms of postoperative complications, although TOVAT carries the risk of an additional complication: lesions of the terminal branches of the inferior alveolar nerve. At the moment, the average operative time with TOVAT is disproportionately long compared with MIVAT. Both are therapeutic options that meet different patient needs and desires, but in our opinion, the main reason, usually aesthetic, for choosing TOVAT is not sufficient to warrant its use in more than a very small number of selected cases.

Financial support and sponsorship

Nil.

Conflicts of interest

There are no conflicts of interest.

REFERENCES

- Bakkar S, Miccoli P. Minimally invasive video-assisted thyroidectomy (MIVAT) in the era of minimal access thyroid surgery. *J Minim Invasive Surg Sci* 2017;6:e42470.
- Witzel K, von Rahden BH, Kaminski C, Stein HJ. Transoral access for endoscopic thyroid resection. *Surg Endosc* 2008;22:1871-5.
- Tartaglia F, Maturo A, Di Matteo FM, De Anna L, Karpathiotakis M, Pelle F, *et al.* Transoral video assisted thyroidectomy: A systematic review. *G Chir* 2018;39:276-83.
- Anuwong A, Ketwong K, Jitpratoom P, Sasanakietkul T, Duh QY. Safety and outcomes of the transoral endoscopic thyroidectomy vestibular approach. *JAMA Surg* 2018;153:21-7.

- Chai YJ, Chung JK, Anuwong A, Dionigi G, Kim HY, Hwang KT, *et al.* Transoral endoscopic thyroidectomy for papillary thyroid microcarcinoma: Initial experience of a single surgeon. *Ann Surg Treat Res* 2017;93:70-5.
- Chen CM, Hung IY, Liu WC, Wang LK, Lan KM, Lin YT, *et al.* A great variation in the reported incidence of postoperative subcutaneous emphysema in trans-oral vestibular endoscopic thyroidectomy. *World J Surg* 2017;41:2647-8.
- Dionigi G, Bacuzzi A, Lavazza M, Inversini D, Boni L, Rausei S, *et al.* Transoral endoscopic thyroidectomy: Preliminary experience in Italy. *Updates Surg* 2017;69:225-34.
- Fu J, Luo Y, Chen Q, Lin F, Hong X, Kuang P, *et al.* Transoral endoscopic thyroidectomy: Review of 81 cases in a single institute. *J Laparoendosc Adv Surg Tech A* 2018;28:286-91.
- Jitpratoom P, Ketwong K, Sasanakietkul T, Anuwong A. Transoral endoscopic thyroidectomy vestibular approach (TOETVA) for Graves' disease: A comparison of surgical results with open thyroidectomy. *Gland Surg* 2016;5:546-52.
- Kim HY, Chai YJ, Dionigi G, Anuwong A, Richmon JD. Transoral robotic thyroidectomy: Lessons learned from an initial consecutive series of 24 patients. *Surg Endosc* 2018;32:688-94.
- Nakajo A, Arima H, Hirata M, Mizoguchi T, Kijima Y, Mori S, *et al.* Trans-Oral Video-Assisted Neck Surgery (TOVANS). A new transoral technique of endoscopic thyroidectomy with gasless premandible approach. *Surg Endosc* 2013;27:1105-10.
- Park JO, Sun DI. Transoral endoscopic thyroidectomy: Our initial experience using a new endoscopic technique. *Surg Endosc* 2017;31:5436-43.
- Russell JO, Clark J, Noureldine SI, Anuwong A, Al Khadem MG, Yub Kim H, *et al.* Transoral thyroidectomy and parathyroidectomy – A North American series of robotic and endoscopic transoral approaches to the central neck. *Oral Oncol* 2017;71:75-80.
- Udelsman R, Anuwong A, Oprea AD, Rhodes A, Prasad M, Sansone M, *et al.* Trans-oral vestibular endocrine surgery: A new technique in the United States. *Ann Surg* 2016;264:e13-e16.
- Wang C, Zhai H, Liu W, Li J, Yang J, Hu Y, *et al.* Thyroidectomy: A novel endoscopic oral vestibular approach. *Surgery* 2014;155:33-8.
- Wang Y, Yu X, Wang P, Miao C, Xie Q, Yan H, *et al.* Implementation of intraoperative neuromonitoring for transoral endoscopic thyroid surgery: A preliminary report. *J Laparoendosc Adv Surg Tech A* 2016;26:965-71.
- Wilhelm T, Metzger A. Endoscopic minimally invasive thyroidectomy (eMIT): A prospective proof-of-concept study in humans. *World J Surg* 2011;35:543-51.
- Yang J, Wang C, Li J, Yang W, Cao G, Wong HM, *et al.* Complete endoscopic thyroidectomy via oral vestibular approach versus areola approach for treatment of thyroid diseases. *J Laparoendosc Adv Surg Tech A* 2015;25:470-6.
- Yang K, Ding B, Lin C, Li W, Li X. The novel transvestibule approach for endoscopic thyroidectomy: A case series. *Surg Laparosc Endosc Percutan Tech* 2016;26:e25-8.
- Zeng YK, Li ZY, Xuan WL, He JX. Trans-oral glasses-free three-dimensional endoscopic thyroidectomy-preliminary single center experiences. *Gland Surg* 2016;5:628-32.
- Alesina PF, Rolfs T, Rühlend K, Brunkhorst V, Groeben H, Walz MK. Evaluation of postoperative pain after minimally invasive video-assisted and conventional thyroidectomy: Results of a prospective study. *ESES Vienna presentation. Langenbecks Arch Surg* 2010;395:845-9.
- Barczyński M, Konturek A, Stopa M, Papier A, Nowak W. Minimally invasive video-assisted thyroidectomy: Seven-year experience with 240 cases. *Wideochir Inne Tech Maloinwazyjne* 2012;7:175-80.
- Bellotti C, Capponi MG, Cinquepalmi M, Castagnola G, Marchetta S, Mallozzi F, *et al.* MIVAT: The last 2 years experience, tips and techniques after more than 10 years. *Surg Endosc* 2018;32:2340-4.
- Chao TC, Lin JD, Chen MF. Video-assisted open thyroid lobectomy

Tartaglia, *et al.*: MIVAT and TOVAT – A comparison of two systematic reviews

- through a small incision. *Surg Laparosc Endosc Percutan Tech* 2004;14:15-9.
25. Del Rio P, Viani L, Montana CM, Cozzani F, Sianesi M. Minimally invasive thyroidectomy: A ten years experience. *Gland Surg* 2016;5:295-9.
 26. Dobrinja C, Trevisan G, Makovac P, Liguori G. Minimally invasive video-assisted thyroidectomy compared with conventional thyroidectomy in a general surgery department. *Surg Endosc* 2009;23:2263-7.
 27. Duke WS, White JR, Waller JL, Terris DJ. Six-year experience with endoscopic thyroidectomy: Outcomes and safety profile. *Ann Otol Rhinol Laryngol* 2015;124:915-20.
 28. El-Labban GM. Minimally invasive video-assisted thyroidectomy versus conventional thyroidectomy: A single-blinded, randomized controlled clinical trial. *J Minim Access Surg* 2009;5:97-102.
 29. Fan Y, Guo B, Guo S, Kang J, Wu B, Zhang P, *et al.* Minimally invasive video-assisted thyroidectomy: Experience of 300 cases. *Surg Endosc* 2010;24:2393-400.
 30. Frank E, Park J, Simental A Jr., Vuong C, Liu Y, Kwon D, *et al.* Minimally invasive video-assisted thyroidectomy: Almost a decade of experience at an academic center. *Am Surg* 2016;82:949-52.
 31. Gal I, Solymosi T, Szabo Z, Balint A, Bolgar G. Minimally invasive video-assisted thyroidectomy and conventional thyroidectomy: A prospective randomized study. *Surg Endosc* 2008;22:2445-9.
 32. Haitao Z, Jie X, Lixin J. Minimally invasive video-assisted thyroidectomy: Experience of 200 cases in a single center. *Wideochir Inne Tech Maloinwazyjne* 2014;9:337-43.
 33. Hegazy MA, Khater AA, Setit AE, Amin MA, Kotb SZ, El Shafci MA, *et al.* Minimally invasive video-assisted thyroidectomy for small follicular thyroid nodules. *World J Surg* 2007;31:1743-50.
 34. Miccoli P, Biricotti M, Matteucci V, Ambrosini CE, Wu J, Materazzi G. Minimally invasive video-assisted thyroidectomy: Reflections after more than 2400 cases performed. *Surg Endosc* 2016;30:2489-95.
 35. Park CS, Chung WY, Chang HS. Minimally invasive open thyroidectomy. *Surg Today* 2001;31:665-9.
 36. Ruggieri M, Straniero A, Mascaro A, Genderini M, D'Armiento M, Gargiulo P, *et al.* The minimally invasive open video-assisted approach in surgical thyroid diseases. *BMC Surg* 2005;5:9.
 37. Samy AK, Ridgway D, Orabi A, Suppiah A. Minimally invasive, video-assisted thyroidectomy: First experience from the United Kingdom. *Ann R Coll Surg Engl* 2010;92:379-84.
 38. Cohen J. *Statistical Power Analysis for the Behavioral Sciences*. 2nd ed. Lawrence Erlbaum Associates; 1988. ISBN 0-8058-0283-5.
 39. Sawilowsky S. New effect size rules of thumb. *J Mod Appl Stat Methods* 2009;8:597-9.
 40. Tartaglia F, Giuliani A, Sgueglia M, Biancari F, Juvonen T, Campana FP. Randomized study on oral administration of calcitriol to prevent symptomatic hypocalcemia after total thyroidectomy. *Am J Surg* 2005;190:424-9.
 41. Sanabria A, Kowalski LP, Tartaglia F. Inferior thyroid artery ligation increases hypocalcemia after thyroidectomy: A meta-analysis. *Laryngoscope* 2018;128:534-41.
 42. Tartaglia F, Giuliani A, Sorrenti S, Tromba L, Carbotta S, Maturo A, *et al.* Early discharge after total thyroidectomy: A retrospective feasibility study. *G Chir* 2016;37:250-6.
 43. Tartaglia F, Blasi S, Giuliani A, Merola R, Livadoti G, Krizzuk D, *et al.* Parathyroid autotransplantation during total thyroidectomy. Results of a retrospective study. *Int J Surg* 2016;28 Suppl 1:S79-83.
 44. Tartaglia F, Giuliani A, Sgueglia M, Patrizi G, Di Rocco G, Blasi S, *et al.* Is ionized calcium a reliable predictor of hypocalcemia after total thyroidectomy? A before and after study. *G Chir* 2014;35:27-35.
 45. Baldini E, Tuccilli C, Prinzi N, Sorrenti S, Falvo L, De Vito C, *et al.* Deregulated expression of Aurora kinases is not a prognostic biomarker in papillary thyroid cancer patients. *PLoS One* 2015;10:e0121514.
 46. Tromba L, Blasi S, Vestri A, Kiltzanidi D, Tartaglia F, Redler A. Prevalence of chronic cerebrospinal venous insufficiency in multiple sclerosis: A blinded sonographic evaluation. *Phlebology* 2015;30:52-60.
 47. Tartaglia F, Blasi S, Tromba L, Sgueglia M, Russo G, Di Matteo FM, *et al.* Duplex ultrasound and magnetic resonance imaging of the supra-aortic arches in patients with non recurrent inferior laryngeal nerve: A comparative study. *G Chir* 2011;32:245-50.
 48. Campana FP, Marchesi M, Tartaglia F, Biffoni M, Pugliese FR, Nobili-Benedetti R, *et al.* Total thyroidectomy for goiter. *Chirurgia* 1992;5:102-105.
 49. Minisola S, Cipriani C, Diacinti D, Tartaglia F, Scillitani A, Pepe J, *et al.* Imaging of the parathyroid glands in primary hyperparathyroidism. *Eur J Endocrinol* 2016;174:D1-8.
 50. Tartaglia F, Salvatori FM, Pichelli D, Sgueglia M, Blasi S, Custureri F. Preoperative embolization of thyroid arteries in a patient with a large cervicomedial hyperfunctioning goiter. *Thyroid* 2007;17:787-92.
 51. Tartaglia F, Salvatori FM, Russo G, Blasi S, Sgueglia M, Tromba L, *et al.* Selective embolization of thyroid arteries for preresection or palliative treatment of large cervicomedial goiters. *Surg Innov* 2011;18:70-8.
 52. Ulisse S, Bosco D, Nardi F, Nesca A, D'Armiento E, Guglielmino V, *et al.* Thyroid imaging reporting and data system score combined with the new Italian classification for thyroid cytology improves the clinical management of indeterminate nodules. *Int J Endocrinol*. 2017;2017:9692304. doi: 10.1155/2017/9692304. [Epub 2017 Mar 01].
 53. Bakkar S, Al Hyari M, Naghawi M, Corsini C, Miccoli P. Transoral thyroidectomy: A viable surgical option with unprecedented complications-a case series. *J Endocrinol Invest* 2018;41:809-13.
 54. Lombardi CP, Bracaglia R, Revelli L, Insalaco C, Pennestrì F, Bellantone R, *et al.* Aesthetic result of thyroidectomy: Evaluation of different kinds of skin suture. *Ann Ital Chir* 2011;82:449-55.
 55. Consorti F, Mancuso R, Piccolo A, Pretore E, Antonaci A. Quality of scar after total thyroidectomy: A single blinded randomized trial comparing octyl-cyanoacrylate and subcuticular absorbable suture. *ISRN Surg* 2013;2013:270953. doi: 10.1155/2013/270953. eCollection 2013.
 56. Shih B, Bayat A. Genetics of keloid scarring. *Arch Dermatol Res* 2010;302:319-39.
 57. Dordea M, Aspinnall SR. Short and long-term cosmesis of cervical thyroidectomy scars. *Ann R Coll Surg Engl* 2016;98:11-7.
 58. Robinson JK, Hanke CW, Sengelmann RD, Siegel DM. *Surgery of the Skin*. Philadelphia: Elsevier; 2005. p. 23-78.