

World Journal of *Gastroenterology*

World J Gastroenterol 2020 October 21; 26(39): 5911-6110



OPINION REVIEW

- 5911 Use of artificial intelligence in improving adenoma detection rate during colonoscopy: Might both endoscopists and pathologists be further helped

Sinagra E, Badalamenti M, Maida M, Spadaccini M, Maselli R, Rossi F, Conoscenti G, Raimondo D, Pallio S, Repici A, Anderloni A

REVIEW

- 5919 Clinical assessment and management of liver fibrosis in non-alcoholic fatty liver disease

Campos-Murguía A, Ruiz-Margáin A, González-Regueiro JA, Macías-Rodríguez RU

MINIREVIEWS

- 5944 Enteroscopy in children and adults with inflammatory bowel disease

Di Nardo G, Esposito G, Ziparo C, Micheli F, Masoni L, Villa MP, Parisi P, Manca MB, Baccini F, Corleto VD

- 5959 Artificial intelligence technique in detection of early esophageal cancer

Huang LM, Yang WJ, Huang ZY, Tang CW, Li J

ORIGINAL ARTICLE**Basic Study**

- 5970 Polyethylene glycol 35 ameliorates pancreatic inflammatory response in cerulein-induced acute pancreatitis in rats

Ferrero-Andrés A, Panisello-Roselló A, Roselló-Catafau J, Folch-Puy E

- 5983 Identification of differentially expressed genes in ulcerative colitis and verification in a colitis mouse model by bioinformatics analyses

Shi L, Han X, Li JX, Liao YT, Kou FS, Wang ZB, Shi R, Zhao XJ, Sun ZM, Hao Y

- 5997 Herbal cake-partitioned moxibustion inhibits colonic autophagy in Crohn's disease *via* signaling involving distinct classes of phosphatidylinositol 3-kinases

Wang SY, Zhao JM, Zhou CL, Zheng HD, Huang Y, Zhao M, Zhang ZY, Wu LY, Wu HG, Liu HR

Case Control Study

- 6015 Single access laparoscopic total colectomy for severe refractory ulcerative colitis

Burke J, Toomey D, Reilly F, Cahill R

Retrospective Study

- 6027 Real-world treatment attrition rates in advanced esophagogastric cancer

Tsang ES, Lim HJ, Renouf DJ, Davies JM, Loree JM, Gill S

6037 Metastatic pattern in esophageal and gastric cancer: Influenced by site and histology
Verstegen MHP, Harker M, van de Water C, van Dieren J, Hugten N, Nagtegaal ID, Rosman C, van der Post RS

6047 Relationships of early esophageal cancer with human papillomavirus and alcohol metabolism
Inoue M, Shimizu Y, Ishikawa M, Abiko S, Shimoda Y, Tanaka I, Kinowaki S, Ono M, Yamamoto K, Ono S, Sakamoto N

6057 Dynamic contrast-enhanced magnetic resonance imaging and diffusion-weighted imaging in the activity staging of terminal ileum Crohn's disease
Wu YC, Xiao ZB, Lin XH, Zheng XY, Cao DR, Zhang ZS

Observational Study

6074 Relationship of meteorological factors and air pollutants with medical care utilization for gastroesophageal reflux disease in urban area
Seo HS, Hong J, Jung J

6087 Acute gastrointestinal injury in critically ill patients with COVID-19 in Wuhan, China
Sun JK, Liu Y, Zou L, Zhang WH, Li JJ, Wang Y, Kan XH, Chen JD, Shi QK, Yuan ST

Randomized Controlled Trial

6098 Impact of cap-assisted colonoscopy during transendoscopic enteral tubing: A randomized controlled trial
Wen Q, Liu KJ, Cui BT, Li P, Wu X, Zhong M, Wei L, Tu H, Yuan Y, Lin D, Hsu WH, Wu DC, Yin H, Zhang FM

ABOUT COVER

Editorial Board Member of *World Journal of Gastroenterology*, Dr. Sung-Chul Lim is a Distinguished Professor at the Chosun University School of Medicine. Having received his Bachelor's degree from Chosun University College of Medicine in 1987, Dr. Lim undertook his postgraduate training, first at the Graduate School of Chosun University, receiving his Master's degree in 1990, and then at the Graduate School of Chungnam National University, receiving his PhD in 1995. He became Professor and Pathologist in the Department of Pathology of Chosun University School of Medicine and Chosun University Hospital in 1996, rising to Head of the Department of Pathology in 2019. His ongoing research interests involve chemoresistance and apoptotic cell death of gastric cancer cells and inhibition of hepatic fibrogenesis. Currently, he serves as Chairperson of the Certification Committee of the Korean Society of Pathologists and Director of the Biobank of Chosun University Hospital. (L-Editor: Filipodia)

AIMS AND SCOPE

The primary aim of *World Journal of Gastroenterology (WJG, World J Gastroenterol)* is to provide scholars and readers from various fields of gastroenterology and hepatology with a platform to publish high-quality basic and clinical research articles and communicate their research findings online. *WJG* mainly publishes articles reporting research results and findings obtained in the field of gastroenterology and hepatology and covering a wide range of topics including gastroenterology, hepatology, gastrointestinal endoscopy, gastrointestinal surgery, gastrointestinal oncology, and pediatric gastroenterology.

INDEXING/ABSTRACTING

The *WJG* is now indexed in Current Contents®/Clinical Medicine, Science Citation Index Expanded (also known as SciSearch®), Journal Citation Reports®, Index Medicus, MEDLINE, PubMed, PubMed Central, and Scopus. The 2020 edition of Journal Citation Report® cites the 2019 impact factor (IF) for *WJG* as 3.665; IF without journal self cites: 3.534; 5-year IF: 4.048; Ranking: 35 among 88 journals in gastroenterology and hepatology; and Quartile category: Q2.

RESPONSIBLE EDITORS FOR THIS ISSUE

Production Editor: *Yu-Jie Ma*; Production Department Director: *Xiang Li*; Editorial Office Director: *Ze-Mao Gong*.

NAME OF JOURNAL

World Journal of Gastroenterology

ISSN

ISSN 1007-9327 (print) ISSN 2219-2840 (online)

LAUNCH DATE

October 1, 1995

FREQUENCY

Weekly

EDITORS-IN-CHIEF

Andrzej S Tarnawski, Subrata Ghosh

EDITORIAL BOARD MEMBERS

<http://www.wjgnet.com/1007-9327/editorialboard.htm>

PUBLICATION DATE

October 21, 2020

COPYRIGHT

© 2020 Baishideng Publishing Group Inc

INSTRUCTIONS TO AUTHORS

<https://www.wjgnet.com/bpg/gerinfo/204>

GUIDELINES FOR ETHICS DOCUMENTS

<https://www.wjgnet.com/bpg/GerInfo/287>

GUIDELINES FOR NON-NATIVE SPEAKERS OF ENGLISH

<https://www.wjgnet.com/bpg/gerinfo/240>

PUBLICATION ETHICS

<https://www.wjgnet.com/bpg/GerInfo/288>

PUBLICATION MISCONDUCT

<https://www.wjgnet.com/bpg/gerinfo/208>

ARTICLE PROCESSING CHARGE

<https://www.wjgnet.com/bpg/gerinfo/242>

STEPS FOR SUBMITTING MANUSCRIPTS

<https://www.wjgnet.com/bpg/GerInfo/239>

ONLINE SUBMISSION

<https://www.f6publishing.com>

Enteroscopy in children and adults with inflammatory bowel disease

Giovanni Di Nardo, Gianluca Esposito, Chiara Ziparo, Federica Micheli, Luigi Masoni, Maria Pia Villa, Pasquale Parisi, Maria Beatrice Manca, Flavia Baccini, Vito Domenico Corleto

ORCID number: Giovanni Di Nardo 0000-0002-9026-7758; Gianluca Esposito 0000-0002-2242-5048; Chiara Ziparo 0000-0002-4209-6958; Federica Micheli 0000-0001-5420-7005; Luigi Masoni 0000-0001-9866-4224; Maria Pia Villa 0000-0002-5859-0723; Pasquale Parisi 0000-0001-9042-8120; Maria Beatrice Manca 0000-0001-8993-5467; Flavia Baccini 0000-0002-3245-8329; Vito Domenico Corleto 0000-0001-6383-9581.

Author contributions: Di Nardo G, Villa MP and Parisi P wrote the pediatric section of the paper; Ziparo C and Manca MB collected and analyzed pediatric literature; Esposito G, Masoni L and Corleto VD wrote the adult section of the paper; Micheli F and Baccini F collected and analyzed adult literature.

Conflict-of-interest statement:

Authors declare no conflict of interests for this article.

Open-Access: This article is an open-access article that was selected by an in-house editor and fully peer-reviewed by external reviewers. It is distributed in accordance with the Creative Commons Attribution NonCommercial (CC BY-NC 4.0) license, which permits others to distribute, remix, adapt, build upon this work non-commercially, and license their derivative works

Giovanni Di Nardo, Chiara Ziparo, Maria Pia Villa, Pasquale Parisi, Chair of Pediatrics, Pediatric Gastroenterology and Endoscopy Unit, NESMOS Department, Faculty of Medicine and Psychology, Sapienza University of Rome, Sant' Andrea University Hospital, Rome 00189, Lazio, Italy

Gianluca Esposito, Department of Medical-Surgical Sciences and Translational Medicine, Sant' Andrea Hospital, Sapienza University of Rome, Rome 00189, Lazio, Italy

Federica Micheli, Flavia Baccini, Vito Domenico Corleto, Department of Medical-Surgical Sciences and Translational Medicine, Sant' Andrea University Hospital, Sapienza University of Rome, Rome 00189, Lazio, Italy

Luigi Masoni, Department of Surgery, Sapienza University of Rome, Sant' Andrea University Hospital, Rome 00189, Lazio, Italy

Maria Beatrice Manca, Department of Clinical and Surgical Translational Medicine, Anesthesia and Intensive Care Medicine, Sant'Andrea University Hospital, Sapienza University of Rome 00189, Lazio, Italy

Corresponding author: Giovanni Di Nardo, MD, PhD, Assistant Professor, Chair of Pediatrics, Pediatric Gastroenterology and Endoscopy Unit, NESMOS Department, Faculty of Medicine and Psychology, Sapienza University of Rome, Sant' Andrea University Hospital, Via di Grottarossa 1035-1039, Rome 00189, Lazio, Italy. giovanni.dinardo@uniroma1.it

Abstract

Inflammatory bowel disease (IBD) includes Crohn's disease (CD), ulcerative colitis and unclassified entities. CD commonly involves the terminal ileum and colon but at the time of diagnosis it can be confined to the small bowel (SB) in about 30% of the patients, especially in the young ones. Management of isolated SB-CD can be challenging and objective evaluation of the SB mucosa is essential in differentiating CD from other enteropathies to achieve therapeutic decisions and to plan the follow-up. The introduction of cross-sectional imaging techniques and capsule endoscopy (CE) have significantly expanded the ability to diagnose SB diseases providing a non-invasive test for the visualization of the entire SB mucosa. The main CE limitations are the low specificity, the lack of therapeutic capabilities and the impossibility to take biopsies. Device assisted enteroscopy (DAE) enables histological confirmation when traditional endoscopy, capsule endoscopy and cross-sectional imaging are inconclusive and also allows therapeutic interventions such as balloon stricture dilation, intralesional steroid injection, capsule retrieval and more recently stent insertion. In the current review

on different terms, provided the original work is properly cited and the use is non-commercial. See: <http://creativecommons.org/licenses/by-nc/4.0/>

Manuscript source: Invited manuscript

Received: June 28, 2020

Peer-review started: June 28, 2020

First decision: July 28, 2020

Revised: August 8, 2020

Accepted: September 25, 2020

Article in press: September 25, 2020

Published online: October 21, 2020

P-Reviewer: Hijaz NM

S-Editor: Huang P

L-Editor: A

P-Editor: Ma YJ



we will discuss technical aspect, indications and safety profile of DAE in children and adults with IBD.

Key Words: Enteroscopy; Device assisted enteroscopy; Inflammatory bowel disease; Crohn's disease; Small bowel disease; Endoscopic balloon dilation

©The Author(s) 2020. Published by Baishideng Publishing Group Inc. All rights reserved.

Core Tip: Evaluation of the small bowel (SB) mucosa is essential in differentiating Crohn's disease (CD) from other enteropathies to achieve therapeutic decisions and to plan follow-up. The introduction of cross-sectional imaging techniques and capsule endoscopy have significantly improved the diagnostic approach to SB disease providing a non-invasive diagnostic method for the visualization of the entire SB mucosa. However, Device assisted enteroscopy (DAE) has further revolutionized management of SB-CD enabling histological confirmation and allowing therapeutic interventions. In the current review we will discuss technical aspect, indications and safety profile of DAE in children and adults with inflammatory bowel disease.

Citation: Di Nardo G, Esposito G, Ziparo C, Micheli F, Masoni L, Villa MP, Parisi P, Manca MB, Baccini F, Corleto VD. Enteroscopy in children and adults with inflammatory bowel disease. *World J Gastroenterol* 2020; 26(39): 5944-5958

URL: <https://www.wjgnet.com/1007-9327/full/v26/i39/5944.htm>

DOI: <https://dx.doi.org/10.3748/wjg.v26.i39.5944>

INTRODUCTION

Inflammatory bowel disease (IBD) represents a group of chronic inflammatory disorders that involve the colon, small bowel (SB) and the entire gastrointestinal tract and include Crohn's disease (CD), ulcerative colitis (UC) and unclassified entities^[1,2]. CD is a chronic immuno-mediated inflammation that most commonly involves the terminal ileum and colon, but at the time of diagnosis, it can be confined to the SB, as seen in approximately 30% of CD patients, especially young patients^[2-8]. Isolated SB-CD can be challenging to diagnose and manage for several reasons. First, the SB is less easily accessible by endoscopy, making it easy to miss a SB-CD diagnosis with conventional endoscopy contributing to a delay in diagnosis as observed in many patients with CD^[9]. Second, SB ulcerations induced by infection (such as tuberculosis) or drugs can sometimes be difficult to differentiate from CD^[4,8]. Third, compared with the other phenotypes, SB-CD is associated with an increased risk of relapse and stricture development^[1,3,6,7]. Fourth, SB cancer associated with CD is a rare but difficult problem because only a minority of these cases are diagnosed preoperatively and at an early stage^[9]. Finally, in the paediatric population, SB-CD has particular clinical relevance for its negative impact on growth and pubertal development^[2,7]. Thus, objective evaluation of the SB mucosa is essential in differentiating CD from other enteropathies to make therapeutic decisions and to plan follow-up.

For many years, investigation of the SB has been a challenge because of its anatomy, location, and relative tortuosity. The introduction of cross-sectional imaging techniques such as computed tomography (CT) and magnetic resonance imaging (MRI), enterography/enteroclysis and SB ultrasound, have enhanced SB assessment with great accuracy in evaluating transmural and extraluminal disease, but subtle mucosal changes can still be missed^[8,10,11].

Capsule endoscopy (CE) and device-assisted enteroscopy (DAE) have significantly expanded the ability to diagnose SB diseases. CE provides a non-invasive test for the visualization of the entire SB mucosa, which can aid in the diagnosis of SB-CD and monitoring the therapeutic response. The main CE limitations in IBD patients are a low specificity, a lack of therapeutic capabilities and the inability to perform biopsies^[12,13].

DAE enables histological confirmation when other modalities, such as traditional endoscopy, CE and cross-sectional imaging, are inconclusive and allows therapeutic interventions, such as balloon stricture dilation, intralesional steroid injection, capsule

retrieval and, more recently, stent insertion^[12-14].

In the current review, we will discuss the technical aspects, indications and safety profiles of DAE in children and adults with IBD.

TECHNICAL ASPECTS

DAE is a generic term for any endoscopic technique that includes assisted progression (*i.e.*, balloons, overtubes or other devices) and includes double-balloon enteroscopy (DBE), single-balloon enteroscopy (SBE), balloon-guided endoscopy (BGE) and spiral enteroscopy (SE). **Table 1** shows the main characteristics of the currently available DAE systems.

The DBE system was presented for the first time in Japan in 2001, and the first paediatric report was described in 2003. The DBE system is constituted of a high-resolution enteroscope with a latex balloon attached to the end of the enteroscope and a second balloon attached to the tip of a polyurethane overtube. Both balloons are inflated and deflated using an external pressure-controlled pump system. Currently, three DBE systems are available. The P type is the thinnest; however, the small diameter of its working channel (2.2 mm) limits the possibility of performing advanced therapeutic procedures. The T type has an outer diameter of 9.4 mm and a working channel diameter of 3.2 mm. The main advantage of the short type (working length of 152 cm) is the compatibility with all conventional devices; it can also be used for endoscopic retrograde cholangiopancreatography in patients with altered anatomy and difficult or failed colonoscopy^[14-18].

SBE was introduced in 2007, and in contrast to DBE, there is no balloon at the tip of the enteroscope; therefore, handling of the balloon control unit is simplified. The enteroscope is a high-resolution video endoscope, the overtube and balloon are made of silicon, and a control unit with a safety pressure setting that controls the balloon inflation and deflation^[14-18].

DBE and SBE use the push-and-pull method, however, the number of balloons makes a slight difference in the insertion technique between the two balloon assisted enteroscopy (BAE) systems.

Two operators are generally needed to perform DBE. For the antegrade approach, the endoscope and overtube are advanced to the duodenum beyond the major papilla, at which point the balloon located on the overtube is inflated to hold the small bowel tightly. The enteroscope is then advanced to the distal side of the SB, and its balloon is inflated to prevent slippage of the scope backward. The balloon on the overtube is then deflated, and the overtube is advanced towards the tip of the enteroscope. The balloon on the overtube is then reinflated. The enteroscope-overtube is then withdrawn to fold the SB along the overtube. This process can be repeated until the maximal insertion point or the target lesion is reached^[16].

SBE is usually performed by two operators, but it may be easier than DBE to perform with a single-operator. The enteroscope and overtube are advanced similar to the DBE insertion technique. However, the enteroscope tip must be angled during advancement of the overtube and only after the angulation of the tip, the overtube is advanced towards the tip of the enteroscope, and the overtube balloon is then inflated. The enteroscope-overtube is then withdrawn to fold the SB along the overtube. The overtube balloon is left inflated and the enteroscope is advanced from the overtube tip. This cycle of forward advancement and withdrawal is repeated until the maximal insertion point or target lesion is reached^[16].

Retrograde insertion is more difficult than antegrade insertion, even in experienced hands. For both techniques (DBE and SBE), the enteroscope and overtube are advanced to the caecum. After inflation of the overtube balloon, the enteroscope-overtube is withdrawn to decrease the ileo-colic angle. With the overtube balloon inflated, the enteroscope is then passed through the ileocecal valve, and endoscopy balloon is inflated within the ileum to hold the position. The overtube is then advanced into the ileum with the balloon deflated. For SBE, although the insertion technique is the same, backward slippage of the tip of the enteroscope to the caecum during insertion of the overtube is frequent because of the lack of a balloon at the enteroscope tip, which would enable holding the position^[16].

DBE and SBE have the same procedural technique in children and adults. BAE is suitable and safe for children aged > 3 years and weight > 14 kg. However, due to a smaller abdominal cavity, thinner intestinal walls and a narrower intestinal lumen, BAE requires a greater level of skill in younger children^[18].

BGE is performed by using an on-demand through-the-scope (TTS) balloon inserted

Table 1 Technical characteristics of the currently available device-assisted endoscopes

Company	DAE system type	Endoscope model	Optical field of view	Optical depth of field	Endoscope distal outer diameter	Endoscope channel inner diameter	Endoscope working length	Overtube outer diameter	Image enhancement
Fujifilm Corporation (Tokyo, Japan)	DBE	EN-580T	140	2-100 mm	9, 4 mm	3, 2 mm	200 cm	13, 2 mm	FICE
	DBE	EN-580XP	140	2-100 mm	7, 5 mm	2, 2 mm	200 cm	11, 6 mm	FICE
	DBE	EI-580BT	140	2-100 mm	9, 4 mm	3, 2 mm	156 cm	13, 2 mm	FICE
Pentax Medical (Tokyo, Japan)	DBE on demand using BGE	G-EYE34-i10L/F	140	2-100 mm	11, 5 mm	3, 8 mm	170 cm	NA	i-scan OE
	DBE on demand using BGE	G-EYE38-i10L/F	140	2-100 mm	13, 2 mm	3, 8 mm	170 cm	NA	i-scan OE
	DBE on demand using BGE	G-EYE38-i10F2	140	2-100 mm	13, 2 mm	3, 8 mm	150 cm	NA	i-scan OE
Olympus (Tokyo, Japan)	SBE	SIF-Q180	140	3-100 mm	9, 2 mm	2, 8 mm	200 cm	13, 2 mm	NBI
	SBE	SIFH290S	140	3-100 mm	9, 2 mm	3, 2 mm	152 cm	13, 2 mm	NBI
	SE	SIF-Y0019 Motorized spiral overtube	140	2-100 mm	11, 3 mm	3, 2 mm	168 cm	31, 1 mm max ¹ ; 18, 1 mm distal ²	NBI
NaviAid, Smart Medical Systems, (Ra'anana, Israel)	BGE	No specific scope required	NA	NA	NA	NA	NA	NA	NA
Spirus Medical (Stoughton, United States)	SE	No specific scope required	NA	NA	NA	NA	NA	14, 5 mm	NA

¹Maximum outer diameter.

²Distal outer diameter. DAE: Device assisted enteroscopy; DBE: Double balloon enteroscopy; SBE: Single balloon enteroscopy; BGE: Balloon guided enteroscopy; SE: Spiral enteroscopy; NA: Not applicable; NBI: Narrow band imaging; FICE: Flexible spectral imaging color enhancement; OE: Optical enhancement.

in the working channel of any endoscope. The balloon is then inflated, allowing anchoring in the SB, and progression is obtained with repeated push-and-pull manoeuvres by sliding the endoscope over the catheter. The balloon catheter can be removed to perform therapeutic interventions. The main limitation of this technique is the low stability of the endoscope during the therapeutic procedure due to the lack of an anchoring balloon^[14,15]. To overcome this drawback, a colonoscope with an integrated latex-free balloon at the bending section has recently been developed (see Table 1). These colonoscopes, combined with a disposable advancing balloon (AB) applied through the instrument channel, provide the assembly to perform deep SB double-balloon enteroscopy. The balloon endoscopes as well as the AB devices are controlled simultaneously by the inflation system. The feasibility and safety of BGE using the NaviAid AB device has recently been evaluated in children with IBD^[19].

SE involves the use of an overtube with a raised spiral ridge. The SB is pulled and pleated onto the overtube by continuous rotation of the spiral, and advancement into the SB is allowed by clockwise rotation of the overtube during insertion and anticlockwise rotation during withdrawal. SE overtubes have been replaced by a new motorized spiral enteroscopy (NMSE) system. NMSE system is composed of a reusable endoscope with an integrated motor permitting the rotation of a short spiral overtube placed on the insertion tube portion of the endoscope and a motor control

unit with a foot pedal and visual force gauge. The foot pedal activates the drive motor located in the endoscope handle, which controls the rotational direction and speed of a coupler located in the middle of the insertion tube of the endoscope. The bowel is pleated or unpleated on the insertion tube of the endoscope with clockwise or anticlockwise rotation, respectively. After reaching the required depth of insertion, the endoscope will be withdrawn using motorized anticlockwise spiral rotation^[14,20]. Preliminary data shows that NMSE offers advantages over traditional methods, in particular concerning the duration of the procedure and the relative ease of use; otherwise, it has similar diagnostic and therapeutic yields as both SBE and DBE^[20,21]. Nevertheless, data on SE in IBD patients are not yet available, and the large diameter of the SE overtube makes this technique unsuitable for children.

The approach (oral, anal or both) is determined on clinical judgement, cross-sectional imaging (CT/MRI - enterography) and CE. Usually, the oral approach is the first choice due to its lower technical difficulty^[16,17,22]. Both oral and anal approaches are used if inspection of the whole intestine is clinically needed. An ink tattoo or clip is left at the deepest point of insertion achieved during the first approach.

Overnight fasting of 12 h for solid food and 4 h for clear liquids before starting the procedure is enough for the oral approach, the same bowel cleansing suggested for colonoscopy required for retrograde enteroscopy. General anaesthesia is recommended for long procedures or for patients in whom sedation is not appropriate (*i.e.*, paediatric and high-risk patients). Fluoroscopy is not always needed, except when adhesions or massive SB-CD involvement is expected and when enteroscopy is aimed to perform stricture dilation^[16,17,22]. Insufflation of CO₂ is recommended due to its capability to allow deeper SB intubation of the scope and minimize postprocedural discomfort^[22,23].

ENTEROSCOPY IN ADULT PATIENTS WITH SUSPECTED IBD

Five studies evaluated the impact of DAE on adults with suspected IBD (Table 2)^[24-28].

In a retrospective German study, 16 adult patients with clinical suspicion of isolated SB-CD underwent DBE after negative gastroscopy and colonoscopy. Abnormal SB findings were detected in 7 patients (44%) but pathognomonic histological findings of CD were found in only one case (6%). However, a diagnosis of CD was confirmed in 11 out of 16 (69%) patients taking into account clinical, endoscopic and radiological features^[24].

Navaneethan *et al*^[25] retrospectively reviewed a BAE registry, which included DBE and SBE procedures performed on adult patients, to assess the diagnostic yield and clinical impact of BAE in suspected SB-CD. They identified 22 patients with suspected SB-CD and inconclusive results from conventional upper and lower gastrointestinal endoscopy, radiological cross-sectional imaging studies, and CE. These patients underwent BAE, which provided a histological diagnosis of CD in 6 patients (27.3%) and non-steroidal anti-inflammatory drug-induced enteropathy in 3 patients (13.6%), whereas no lesions were found in 13 patients (59.1%). One newly diagnosed CD patient underwent successful balloon dilation of a jejunal stricture without complications. The authors also evaluated the agreement rate between CT or MRI enterography and BAE findings which was quite low (36.4%).

In a multicenter retrospective study, 43 adult patients with suspected CD based on abnormal cross-sectional imaging or CE were evaluated by DBE. The diagnostic yield reached 79%. SB-CD diagnosis was confirmed in 17 patients, and DBE examination was normal in 12 cases. The remaining 5 patients received alternative diagnoses, such as NSAID ulceration, stricture/solitary ulcer, anastomotic ulcer, or Meckel's diverticulum. Another main outcome measure of this study was a comparison of DBE and CE findings. Overall, only 46% of lesions were confirmed on DBE. In 33 (77%) patients, BAE modified clinical management by the exclusion of CD in 11 patients, confirming CD in 17, diagnosing stenosis in 2, nonspecific ulcer in 2 and stopping the NSAID treatment in 1^[26].

Tun *et al*^[27] retrospectively evaluated the impact of DBE and histology on the diagnosis and management of 100 adult patients with suspected SB-CD for whom, based on clinical and laboratory data and after colonoscopy and radiological imaging studies or CE, a diagnosis of CD was not achieved. Abnormal macroscopic DBE findings were detected in 60 patients (ulcers, $n = 47$; stricture, $n = 11$; abnormal mucosa, $n = 2$), and biopsy samples was obtained. Twenty-three showed no histological abnormalities despite positive macroscopic appearances on DBE, whilst among the remaining 37 patients, according to histological examination, the diagnosis

Table 2 Available studies on diagnostic yield and impact on patient management of device assisted enteroscopy in adult Crohn's disease patients

Ref.	DAE system type	Study design	CD patients (n)		Diagnostic yield (%)		Impact on patient management (%)	
			Suspected	Known	Suspected	Known	Suspected	Known
Mensink et al ^[36] , <i>J Gastroenterol</i> 2009	DBE	Retrospective	0	40	60		75	
Kondo et al ^[33] , <i>J Gastroenterol</i> 2010	DBE	Retrospective	25	50	47		53	
Möschler et al ^[34] , <i>Endoscopy</i> 2011	DBE	Prospective	193		47		NA	
Schulz et al ^[24] , <i>Dig Endosc</i> 2014	DBE	Retrospective	16	0	69		NA	
Navaneethan et al ^[25] , <i>Endosc Int Open</i> 2014	SBE or DBE	Retrospective	22	43	27	53	NA	53
Christian et al ^[35] , <i>World J Gastrointest Endosc</i> 2016	Retrograde SBE	Retrospective	29		41.4		17	
Rahman et al ^[26] , <i>Gastrointest Endosc</i> 2015	DBE	Retrospective	43	38	79	87	77	82
Tun et al ^[27] , <i>Eur J Gastroenterol Hepatol</i> 2016	DBE	Retrospective	100	0	NA		45	
Holleran et al ^[28] , <i>Scand J Gastroenterol</i> 2018	SBE	Retrospective	13	39	39	77	69	

DAE: Device-assisted enteroscopy; DBE: Double balloon enteroscopy; SBE: Single balloon enteroscopy; CD: Crohn's disease; NA: Not applicable.

of CD was confirmed in 8 patients (22%), and 15 (41%) had histology suggestive of CD.

Nevertheless, combining clinical, biochemical, endoscopic, and histological findings, 45% of all patients received treatment for CD. After a median follow-up period of 27 mo, the diagnosis of CD was confirmed in 38% of DBE-positive patients^[27].

The diagnostic yield and the impact on clinical outcome of the use of SBE for suspected SB-CD were evaluated in an Italian retrospective study, which included 13 adult patients. The diagnostic yield was 39%, detecting four patients with active ileitis and one with ileal stricture. For the remaining eight patients, a new diagnosis of CD was reached in 4 patients (8%) and excluded in the other 4 patients (8%)^[28].

ENTEROSCOPY IN CHILDREN WITH SUSPECTED IBD

Five studies, two on SBE, two on DBE and one on BGE, evaluated the impact of DAE on children with suspected IBD^[19,29-32] (Table 3).

In a study previously published by our group, 16 paediatric patients with suspected CD and unspecific findings after extensive assessment with upper and lower GI endoscopy, MRE and CE were assessed by SBE. SBE provided a histological diagnosis of CD in 12 patients and eosinophilic enteropathy in 2 patients, no lesions were found in the remaining 2 patients. Moreover, SBE allowed dilation of SB strictures identified on MRI in 2 suspected CD patients^[29].

de Ridder et al^[30] evaluated the diagnostic yield of SBE for paediatric CD. In this study, patients were evaluated directly by two-route SBE, not preceded by conventional endoscopy or CE, and in 8 out of 14 patients with suspected CD, the diagnosis was confirmed after SBE.

Urs et al^[31] performed DBE in 3 patients with suspected CD after CE examination indicating mucosal abnormalities. DBE led to a CD diagnosis in 2 out of 3 patients, and CD was excluded in the other child due to the lack of mucosal lesions and a normal histology.

The study from Uchida et al^[32], evaluated the efficacy and safety of DBE in 8 children with suspected CD after inconclusive gastroscopy, colonoscopy and an SB-contrast study. DBE confirmed a CD diagnosis in 2 out of 8 patients, led to an alternative diagnosis in four patients and did not find mucosal lesions or histological abnormalities in the remaining 2 patients.

Recently, Broide et al^[19] evaluated the feasibility and safety of BAE using a NaviAid AB device in children with suspected IBD. Technical success was achieved in 95.23%

Table 3 Available study on device assisted enteroscopy in pediatric inflammatory bowel disease

Ref.	DAE system type	Study design	Patients (n)	Previous diagnostic work-up	Impact on patient management (%)	Therapeutic procedure	Complications
Di Nardo <i>et al</i> ^[29] , <i>Gastrointest Endosc</i> 2012	SBE	Prospective	Suspected CD = 16, known CD = 14	MRI and CE	Suspected CD = 87%, known CD = 64%	Balloon dilation = 5 pts	Not reported
de Ridder <i>et al</i> ^[30] , <i>Gastrointest Endosc</i> 2012	SBE	Prospective	Suspected CD = 14, known CD = 6	MRI and US	Suspected CD = 57%, known CD = 83%	NA	Not reported
Uchida <i>et al</i> ^[32] , <i>Pediatr Int</i> 2012	DBE	Prospective	Suspected CD = 8, known CD = 4	Upper GI endoscopy, colonoscopy and SB-contrast study	Suspected CD = 75%, known CD = 75%	Balloon dilation = 1 pt	Not reported
Urs <i>et al</i> ^[31] , <i>J Pediatr Gastroenterol Nutr</i> 2014	DBE	Prospective	Suspected CD = 3, known CD = 5	CE	Suspected CD = 66%, known CD = 100%	NA	Not reported
Broide <i>et al</i> ^[19] , <i>J Pediatr Gastroenterol Nutr</i> 2020	BGE	Prospective	Suspected IBD = 15, known IBD = 16	NA	NA	NA	Not reported

DAE: Device-assisted enteroscopy; DBE: Double balloon enteroscopy; SBE: Single balloon enteroscopy; BGE: Balloon guided enteroscopy; CE: Capsule endoscopy; IBD: Inflammatory bowel disease; CD: Crohn's disease; NA: Not applicable; MRI: Magnetic resonance imaging; US: Ultrasonography; GI: Gastrointestinal; SB: Small bowel; CE: Capsule endoscopy.

and 85.7% of the anterograde and retrograde approaches, respectively. Moreover, the total procedure time was significantly shorter and the learning curve was faster than with BAE, as its operation is intuitive and simple. Unfortunately, the diagnostic yield of this technique was not assessed. In the 15 patients with suspected IBD, 3 patients were diagnosed with UC and 3 patients with CD; the remaining 9 patients showed no intestinal abnormalities.

According to the previously described literature and our previously published algorithm (Figure 1), in children with suspected IBD, we suggest the following approach. DAE is recommended when conventional endoscopy, imaging of the SB and CE are inconclusive and tissue sampling and/or therapeutic procedures would alter disease management. DAE should be the preferred primary endoscopic procedure only if a stricture or an easy-to-reach lesion (*i.e.*, proximal SB wall thickness) is suspected at imaging. This is reasonable due to DAE diagnostic and therapeutic possibilities and to the high capsule retention risk^[6,18].

ENTEROSCOPY IN SUSPECTED AND ALREADY KNOWN IBD ADULT PATIENTS

Three studies evaluated the impact of DAE on both suspected and already known IBD adult patients (Table 2)^[33-35].

Kondo *et al*^[33] analyzed a total of 1444 cases of DBE performed for various indications collected in a multicenter database to investigate the efficacy of DBE for the diagnosis and treatment of CD on adult patient. A total of 50 known and 25 newly diagnosed patients with CD were included. Active inflammatory lesions (ulcer and erosion/redness) were found in 51.2% of the symptomatic patients, but they were also detected in 33.3% of the asymptomatic CD patients. Overall, the treatment was altered for 53.3% of the patients, resulting in introduction of anti-TNF antibody (20.4%) or other medication (17.5%), dose reduction (1.9%), endoscopic balloon dilation (EBD, 7.8%), and surgical treatment (5.8%).

In 2011, Möschler *et al*^[34] published the results derived from a large prospective German database that reported data from 2245 DBE examinations carried out on 1765 adult patients over a 2-year period. Overall, 193 patients (11%) with known or suspected CD underwent endoscopic examination of the SB, showing pathological findings in 91 of them, with a diagnostic yield of 47%.

In a retrospective study, Christian *et al*^[35] evaluated the diagnostic and therapeutic yields of SBE using solely a retrograde approach. Overall, 136 retrograde SBE procedures were considered. Twenty-nine (21.3%) were performed on adult patients

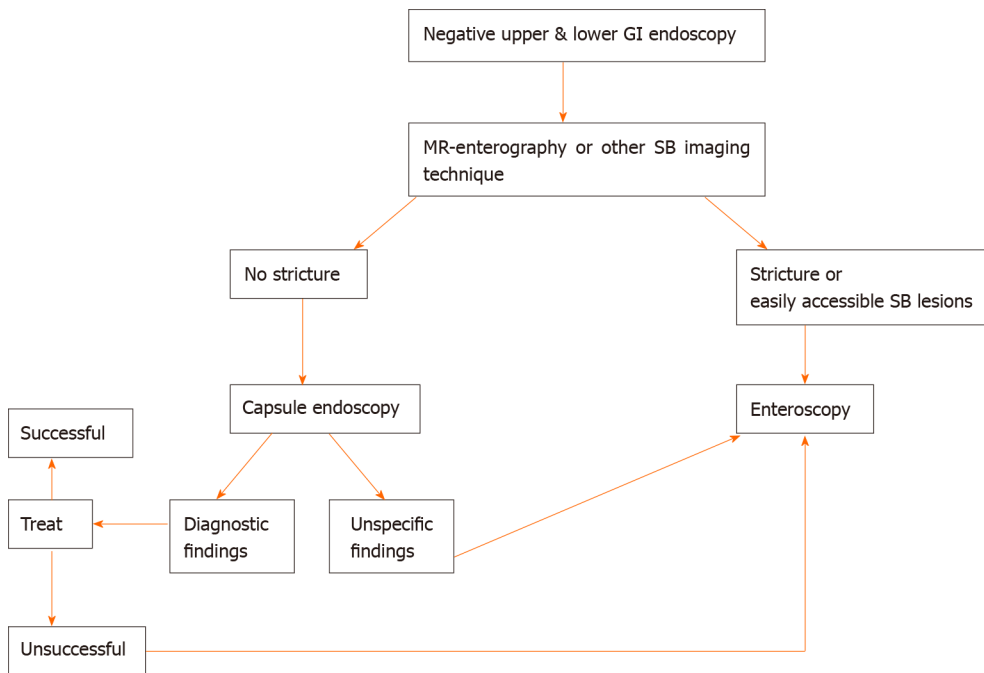


Figure 1 Suggested algorithm in children with suspected inflammatory bowel disease (adapted by reference 6). GI: Gastrointestinal; MR: Magnetic resonance; SB: Small bowel.

with suspected or known CD. Twelve new diagnoses of CD were established, with a diagnostic yield of 41.4%, and the therapeutic yield was 17.2%.

ENTEROSCOPY IN ADULT PATIENTS WITH KNOWN IBD

Four studies evaluated the impact of BAE on adults with known IBD (Table 2)^[25,26,28,36].

Mensink *et al.*^[36] assessed the clinical impact of endoscopic evaluation of the SB by DBE for patients with known CD and clinical suspicion of SB activity. They retrospectively analyzed 52 DBE procedures performed in 40 adult patients. Twenty-four patients (60%) showed macroscopically active inflammation of the SB, and 18 of them (75%) had to switch therapy with persistent clinical improvement in 83% of patients after a mean follow-up of 13 mo. In particular, amongst the 18 patients, 11 introduced anti-TNF therapy, 2 switched from infliximab to adalimumab, 1 introduced steroid therapy, 2 underwent surgical resection, and 2 underwent balloon dilation.

In the study from Navaneethan *et al.*^[25], BAE was performed in 43 adult patients with an established diagnosis of CD whose main indications were disease activity and extent assessment in uninvestigated CD, anaemia or obscure gastrointestinal bleeding, confirmation and treatment of SB strictures diagnosed on radiological examination, and evaluation of activity and extent of CD in postoperative patients. BAE had impact on clinical management of 23 patients (53.4%): 18 patients (41.8%) had active inflammation with ulcers or strictures, which led to a switch of medical therapy or surgery, 5 (11.6%) with documented stenosis in the absence of active ulcers underwent EBD to treat obstructive symptoms. Overall, thirteen patients (30%) required surgery: Two due to lack of other therapeutic strategies, five as a result of medical treatment escalation failure, five based on patient's choice, and one due to bowel perforation after BAE. Finally, the authors found that the agreement rate between CT or MRI enterography and BAE findings were higher (75.6%) in already diagnosed CD patients.

In the study by Rahman *et al.*^[26], the authors analyzed the diagnostic yield and the clinical impact of DBE on the management of 38 adult patients with known CD and clinical suspicion of SB disease activity. In this setting, the diagnostic yield was 87% (33/38 patients), revealing an active disease in 11 patients (29%), 5 with CD stricture (13%), 3 (8%) with functional obstruction due to fixed/angulated bowel, 3 (8%) with anastomotic ulcers, and 2 (5%) with nonspecific ulceration. DBE examination was normal in 9 cases (23.6%). Therefore, DBE resulted in a clinical management change for 82% of patients with known CD. Thirteen patients (34%) needed an increase or a

switch of therapy or surgery, and three patients (8%) underwent endoscopic dilation without any related complications. One patient (1.2%) underwent surgery due to perforation consequent to diagnostic DBE and directly related to an ulcer at an anastomosis site.

Holleran *et al*^[28] evaluated the diagnostic yield and the impact on clinical outcome of the use of SBE for 39 patients with established SB-CD. In this setting, the diagnostic yield was significantly higher than for adult patients with suspected CD (77% *vs* 39%, $P < 0.01$). The most frequent findings were ileal or anastomotic strictures in 38% and 26%, respectively, and active ileitis in 21% of patients. SBE had an immediate clinical impact on 69% ($n = 33$) of patients, including stricture dilation in 27%, adjustment of medications in 48%, and referral for surgical resection in 6%. Long-term follow-up (mean duration of 11 mo, range of 3-22 mo), performed in 34 patients (65%) of the 52 patients, showed a significant change in the mean Harvey-Bradshaw index score from 6.6 to 4.2 after the procedure ($P < 0.0001$).

Regarding the therapeutic role of enteroscopy in adult patients with IBD complications, several studies evaluated the clinical impact of EBD using BAE for SB stricture in CD (Table 4)^[25,28,33,37-45]. Among them, Hirai *et al*^[45] conducted, to our knowledge, the largest multicenter study currently available, which prospectively enrolled 112 patients with symptomatic SB strictures related to CD to clarify the efficacy and safety of EBD. Ninety-five patients (85%) were included, and balloon dilation was successful in 89 (94%) of them. The primary endpoint related to short-term outcomes was an improvement of symptoms, which was achieved in 66 patients (70%). The dilation diameter was significantly larger (15.20 ± 1.70 mm *vs* 13.65 ± 2.59 mm, $P = 0.03$) in the short-term symptomatic improvement group than in the no improvement group. There were no other significant differences in the groups' baseline characteristics or stricture features.

The long-term outcomes of EBD for SB stricture in CD adult patients were extensively evaluated by two retrospective Japanese studies^[43,44].

Hirai *et al*^[43] evaluated 65 CD patients with obstructive symptoms caused by endoscopically manageable SB strictures (stricture length ≤ 5 cm, not associated with fistulae, abscesses or deep ulcers, and without severe curvature of the stricture) with clinical success in 80.0% of patients (52/65). During the observation period after the initial EBD (mean 41.8 ± 24.9 mo), seventeen patients (26.2%) underwent surgery. The cumulative surgery-free rate was 79% and 73% at 2 and 3 years, respectively, and it was significantly higher among successful EBD cases ($P < 0.0001$). Moreover, the cumulative re-dilation-free rate was 64% at 2 years and 47% at 3 years. No significant differences in terms of concomitant treatment or initial dilation method were detected between patients with and without the need for re-dilation.

More recently, Sunada *et al*^[44] analyzed data regarding 85 patients who underwent DBE-assisted EBD for SB-CD strictures and were then followed-up for a mean period of 41.9 mo (range, 0-141). The surgery-free rate after the initial EBD was 87.3% at 1 year, 78.1% at 3 years, and 74.2% at 5 years. Univariate analysis showed that the presence of an internal fistula beside the refractory stricture was significantly associated with the need for surgical intervention (hazard ratio: 5.50; 95% CI: 2.16-14.0; $P = 0.01$).

ENTEROSCOPY IN CHILDREN WITH KNOWN IBD

Five studies, two on SBE, two on DBE and one on BGE evaluated the impact of BAE in children with established IBD (Table 3)^[19,29-32].

In our study, the SBE findings of 14 patients with longstanding CD and symptoms unexplained by conventional endoscopy led to the introduction of or to a change in therapeutic approach in 11 patients. Moreover, SBE allowed successful and safe dilation of SB strictures identified on MRE in 3 patients^[29].

In the study of de Ridder *et al*^[30] SBE findings led to a change in therapy in five out of six patients with established CD.

In the paper from Urs *et al*^[31], in the established CD group, 2 patients had adverse reactions to infliximab with poor response to adalimumab and 3 patients underwent DBE for disease evaluation and consideration of escalation of treatment. DBE led to a change of treatment in all 5 patients.

Uchida *et al*^[32] evaluated the efficacy and safety of DBE in 4 children with established CD. After DBE, one patient underwent balloon dilatation and a change in medical therapy, and in two patients, surgical resection was planned. In one patient, DBE was performed for assessment of intestinal lesions due to persistent abdominal

Table 4 Available studies on endoscopic balloon dilation using balloon-assisted enteroscopy for small bowel stricture in adult Crohn's disease patients

Ref.	DAE system type	Study design	CD patients (n)	Dilation diameter (mm), mean (range)	Technical success (%)	Clinical efficacy (%)	Dilatations (n), mean per patient (range)	Perforation (%)	Observation period (mo), mean (range)	Symptom recurrence (%)
Fukumoto <i>et al</i> ^[37] , <i>Gastrointest Endosc</i> 2007	DBE	Retrospective	23	NA	NA	74	35, (1.52; 1-6)	0	12, (1-40)	26
Pohl <i>et al</i> ^[38] , <i>Eur J Gastroenterol Hepatol</i> 2007	Push enteroscopy	NA	10	17, (12-20)	80	60	15, (1.5; 1-3)	0	10, (4-16)	40
Ohmiya <i>et al</i> ^[39] , <i>Gastrointest Endosc</i> 2009	DBE	Retrospective	16	NA, (8-20)	96	69	NA	0	16, (2-43)	31
Despott <i>et al</i> ^[40] , <i>Gastrointest Endosc</i> 2009	DBE	Prospective	11	15.4, (12-20)	73	73	18, (2; 1-3)	9	20.5, (2-41)	25
Hirai <i>et al</i> ^[41] , <i>Dig Endosc</i> 2010	DBE	Retrospective	25	NA, (12-18)	72	72	55, (2.2; 1-4)	0	11, (6-29)	22
Kondo <i>et al</i> ^[33] , <i>J Gastroenterol</i> 2010	DBE	Retrospective	8	NA	100	87.5	18, 1.5 (1-2)	0	NA	NA
Gill <i>et al</i> ^[42] , <i>Ther Adv Gastroenterol</i> 2014	DBE	Retrospective	10	13.5, (10-16.5)	80	70	17, (1.8; 1-4)	20	NA	14
Hirai <i>et al</i> ^[43] , <i>Dig Endosc</i> 2014	DBE	Retrospective	65	NA, (12-18)	80	80	NA	1.5	NA	48
Navaneethan <i>et al</i> ^[25] , <i>Endosc Int Open</i> 2014	BAE (SBE/DBE)	Retrospective	6	NA	100	100	7, (1.16; 1-2)	16	NA	NA
Sunada <i>et al</i> ^[44] , <i>Inflamm Bowel Dis</i> 2016	DBE	Retrospective	85	12.4, (8-20)	NA	87	321, (3.8; 1-14)	5	41.9, (0-141)	78.5
Holleran <i>et al</i> ^[28] , <i>Scand J Gastroenterol</i> 2018	SBE	Retrospective	13	13, (12-15)	100	80	14, (1; 1-2)	0	8, (2-16)	23
Hirai <i>et al</i> ^[45] , <i>Journal of Crohn's and Colitis</i> 2018	SBE and DBE	Prospective	95	15, (8-20)	94	70	90, (1; 1-2)	0	24, (NA)	NA

BAE: Balloon-assisted enteroscopy; DBE: Double balloon enteroscopy; SBE: Single balloon enteroscopy; SB: Small bowel; CD: Crohn's disease; NA: Not available or not applicable; DAE: Device assisted enteroscopy.

pain, and only small erosion near the ileal stoma orifice was found; thus, therapy after DBE was not changed.

Recently, Broide *et al*^[19] evaluated the feasibility and safety of BAE using a NaviAid AB device in 16 children with known IBD (undetermined colitis = 7; CD = 9). In this group, 6 patients with undetermined colitis at baseline were confirmed to have active UC, and 1 patient exhibited mucosal healing. Eight of the 9 patients with known CD were confirmed to have active CD, and 1 patient exhibited mucosal healing.

According to the previously described literature and our previously published

algorithm (Figure 2), we suggest the following approach for children with known IBD. DAE is recommended when endoscopic visualization and biopsies of the small intestine are needed to exclude an alternative diagnosis (lymphoma, tuberculosis or carcinoma) or to perform a therapeutic procedure including SB stricture dilation and removal of retained capsule. Endoscopists should keep in mind that in established CD adhesions may limit examination and that active stricturing CD significantly increases the perforation risk^[6,18].

COMPLICATIONS

The most common complications related to DAE are perforation, bleeding, and pancreatitis, with an overall rate on adult patients of approximately 1%^[34,46].

A large retrospective Japanese study identified 29068 patients who underwent diagnostic BAE, reporting 32 cases of perforation (0.11%). Nine hundred forty-two patients underwent a subsequent therapeutic BAE, but no perforations occurred in this group. Univariate logistic regression analysis showed that patients with IBD, irrespective of steroid therapy, had a significantly higher risk of perforation than patients without (8.6-fold and 2.5-fold, respectively)^[47]. In most published studies, the perforation rate among CD patients who underwent EBD varied from 0% to 10% of subjects^[25,28,33,37-41,44,45], although one small cohort reported a perforation rate of 20%^[42] (Table 4). Bleeding after balloon dilation of CD strictures occurs in approximately 2.5% of patients, and it only often requires conservative management^[25]. Finally, pancreatitis has been reported to occur in 0.3% of patients, especially after procedures with an antegrade approach^[34,48,49]. Adverse event rates for the different types of DAE have been shown to be similar^[50].

In paediatric literature, major complications have been reported only for therapeutic procedures. A large retrospective study on 257 DBE procedures in children reported an overall complication rate of 5.4% (10.4% in patients under 10 years)^[51]. No major complications related to either diagnostic or therapeutic procedures have been reported in the paediatric IBD setting.

CONCLUSION

This review analyzed the use of enteroscopy in children and adults with IBD.

Regarding the use of DAE for diagnostic purposes in adult patients, recent ECCO-ESGAR guidelines recommend its use for: (1) Patients with negative endoscopy and suspicion of CD on MRI or CE, if endoscopic and histological diagnostic confirmation is needed; and (2) Patients who need endoscopic intervention in the SB^[52].

According to the studies considered in this review, as shown in Table 2, the diagnostic yields of DAE in adult patients with suspected CD and with known CD is 27%-79% and 53%-87%, respectively, and are higher if the indication for DAE is based on previous SB investigations that may identify suspected lesions and guide the choice of insertion route^[25,26,28]. Meanwhile, the diagnostic yield of DAE drops drastically when the indication is placed exclusively based on non-specific abdominal symptoms^[34]. Similarly the agreement rate between imaging and DAE findings appears to be higher in already diagnosed CD patients than in suspected CD patients (75.6% *vs* 36.4% respectively)^[25]. In published studies a significant impact of DAE on patient management, ranges from 17% to 82%, has been reported with a persistent clinical improvement reaching 83% after a mean follow-up of 13 mo in the study by Mensink *et al*^[36] (Table 2)^[25-28,33,35].

Endoscopic balloon dilation overall has a technical success rate from 72% to 100%, and a clinical success rate greater than 60%^[25,28,33,37-45], although no standardized definitions of both these short-term outcomes has been clearly stated yet. The majority of studies evaluated clinical success basing on the obstructive symptoms reported by the patients often comparing the clinical improvement before and after dilation^[40,45]. The most commonly used definition of technical success was a chance to get the successful inflation of a balloon catheter within the stenotic bowel segment and the subsequently endoscope passage through the dilated segment. Studies considered in this review showed that the mean stricture dilation diameter varied from 12.4 to 17 mm, up to a maximum of 20 mm, and the achievement of a larger dilation diameter seems to be related to a better short-term clinical improvement^[45]. The recurrence of obstructive symptoms after EBD has been variously reported (14% to 78.5% of adult subjects) according to the time considered that in most cases was very short (less than

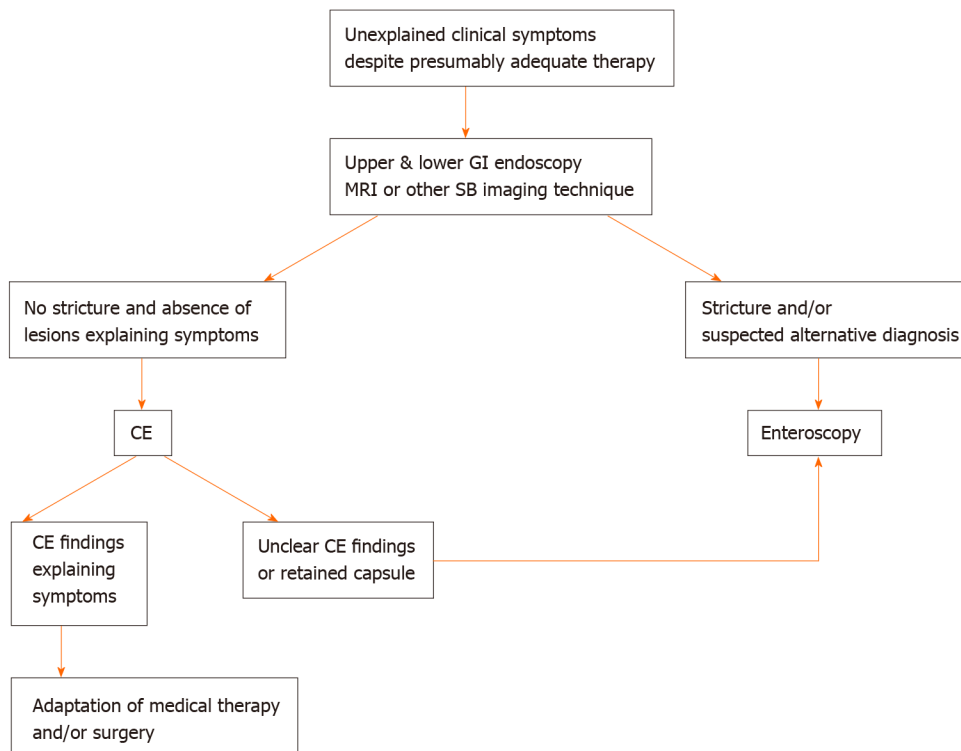


Figure 2 Suggested algorithm in children with known inflammatory bowel disease (adapted by reference 6). GI: Gastrointestinal; MRI: Magnetic resonance imaging; SB: Small bowel; CE: Capsule endoscopy.

fifteen months). However, in two studies the average duration of the observation period after initial EBD was greater than three years^[43,44]. They showed the highest recurrence rates of obstructive symptoms (48% and 78.5%, respectively) but most patients underwent successful re-dilation with a high cumulative surgery-free rate (over 78% at three years). Although balloon dilation of CD strictures appears effective in the short term, it needs to take into consideration the high recurrence rate with the possibility of repeated endoscopic procedures and/or surgery. To our best knowledge, no RCT comparing surgery *vs* balloon dilation has been conducted. As suggested by the ECCO guidelines^[53], EBD or surgery are both suitable treatment options for patients with short (< 5 cm) strictures of the terminal ileum in CD, and the choice of treatment depends on local expertise and patient choice (very low level of evidence). Overall, DAE is a relatively safe procedure if it is performed in expert hands. However, needs deep sedation with the presence of anesthesiologist, may require a bi-directional approach, and has a high complication rate, making this technique not very widespread. Moreover, in children with CD EBD it could delay or avoid invasive surgery to dilate the stenosis and potentially positively affect the natural history of chronic disease all the more important the more it is in childhood.

The present review underlines several limitations related to the studies currently available in the literature. First, most of them are retrospective and include a small number of patients. Second, the studies are often extremely heterogeneous in terms of patient selection, including IBD and non-IBD patients. Third, there are no standardized definitions of the principal outcome measures, such as technical success and clinical efficacy. Fourth, observational period after therapeutic endoscopic procedures, such as EBD, are often too short, not allowing a long-term evaluation. Fifth, into the manuscripts some results are not always clearly stated but have been calculated on the basis of results by the authors of the review.

In conclusion, enteroscopy seems a promising technique especially in patients with suspected isolated SB-CD and inconclusive results from conventional studies (including ileocolonoscopy and radiological cross-sectional imaging) in whom histological diagnosis would alter patient management. Moreover, DAE could have many roles in patients with known CD, in terms of adjustment of medical therapy to obtain more lasting and deep clinical improvement, concomitant diagnosis and treatment of stenosing complications and accurate localization of lesions to allow targeted surgical intervention. Because mucosal healing is increasingly becoming a

goal of therapy in CD, DBE may have a role in assessment response to therapy in the future in select cases. More standardized and wider studies are needed to confirm these evidences.

ACKNOWLEDGEMENTS

We thank Altobello Leo and Di Maio Adele for their tireless work to improve the care of pediatric patients.

REFERENCES

- 1 **Fong SC**, Irving PM. Distinct management issues with Crohn's disease of the small intestine. *Curr Opin Gastroenterol* 2015; **31**: 92-97 [PMID: 25594888 DOI: 10.1097/MOG.0000000000000149]
- 2 **Sauer CG**, Kugathasan S. Pediatric inflammatory bowel disease: highlighting pediatric differences in IBD. *Med Clin North Am* 2010; **94**: 35-52 [PMID: 19944797 DOI: 10.1016/j.mcna.2009.10.002]
- 3 **Hall B**, Holleran G, McNamara D. Small bowel Crohn's disease: an emerging disease phenotype? *Dig Dis* 2015; **33**: 42-51 [PMID: 25531496 DOI: 10.1159/000366047]
- 4 **Peyrin-Biroulet L**, Loftus EV Jr, Colombel JF, Sandborn WJ. The natural history of adult Crohn's disease in population-based cohorts. *Am J Gastroenterol* 2010; **105**: 289-297 [PMID: 19861953 DOI: 10.1038/ajg.2009.579]
- 5 **Pimentel M**, Chang M, Chow EJ, Tabibzadeh S, Kirit-Kiriak V, Targan SR, Lin HC. Identification of a prodromal period in Crohn's disease but not ulcerative colitis. *Am J Gastroenterol* 2000; **95**: 3458-3462 [PMID: 11151877 DOI: 10.1111/j.1572-0241.2000.03361.x]
- 6 **Di Nardo G**, de Ridder L, Oliva S, Casciani E, Escher JC, Cucchiara S. Enteroscopy in paediatric Crohn's disease. *Dig Liver Dis* 2013; **45**: 351-355 [PMID: 22947488 DOI: 10.1016/j.dld.2012.07.020]
- 7 **Chouraki V**, Savoye G, Dauchet L, Vernier-Massouille G, Dupas JL, Merle V, Laberrenne JE, Salomez JL, Lerebours E, Turck D, Cortot A, Gower-Rousseau C, Colombel JF. The changing pattern of Crohn's disease incidence in northern France: a continuing increase in the 10- to 19-year-old age bracket (1988-2007). *Aliment Pharmacol Ther* 2011; **33**: 1133-1142 [PMID: 21488915 DOI: 10.1111/j.1365-2036.2011.04628.x]
- 8 **Leighton JA**, Pasha SF. Inflammatory Disorders of the Small Bowel. *Gastrointest Endosc Clin N Am* 2017; **27**: 63-77 [PMID: 27908519 DOI: 10.1016/j.giec.2016.08.004]
- 9 **Cuffari C**, Dubinsky M, Darbari A, Sena L, Baldassano R. Crohn's jejunoileitis: the pediatrician's perspective on diagnosis and management. *Inflamm Bowel Dis* 2005; **11**: 696-704 [PMID: 15973125 DOI: 10.1097/01.mib.0000166933.74477.69]
- 10 **Cullen G**, Donnellan F, Doherty GA, Smith M, Cheifetz AS. Evaluation of the small bowel in inflammatory bowel disease. *Expert Rev Gastroenterol Hepatol* 2013; **7**: 239-251 [PMID: 23445233 DOI: 10.1586/egh.13.11]
- 11 **Ou G**, Enns R. Capsule Endoscopy and Small Bowel Enteroscopy: Have They Rendered the Radiologist Obsolete? *Gastrointest Endosc Clin N Am* 2019; **29**: 471-485 [PMID: 31078248 DOI: 10.1016/j.giec.2019.02.007]
- 12 **Pennazio M**, Spada C, Eliakim R, Keuchel M, May A, Mulder CJ, Rondonotti E, Adler SN, Albert J, Baltes P, Barbaro F, Cellier C, Charton JP, Delvaux M, Despott EJ, Domagk D, Klein A, McAlindon M, Rosa B, Rowse G, Sanders DS, Saurin JC, Sidhu R, Dumonceau JM, Hassan C, Gralnek IM. Small-bowel capsule endoscopy and device-assisted enteroscopy for diagnosis and treatment of small-bowel disorders: European Society of Gastrointestinal Endoscopy (ESGE) Clinical Guideline. *Endoscopy* 2015; **47**: 352-376 [PMID: 25826168 DOI: 10.1055/s-0034-1391855]
- 13 **Di Nardo G**, Aloï M, Oliva S, Civitelli F, Casciani E, Cucchiara S. Investigation of small bowel in pediatric Crohn's disease. *Inflamm Bowel Dis* 2012; **18**: 1760-1776 [PMID: 22275336 DOI: 10.1002/ibd.22885]
- 14 **Pennazio M**, Venezia L, Cortegoso Valdivia P, Rondonotti E. Device-assisted enteroscopy: An update on techniques, clinical indications and safety. *Dig Liver Dis* 2019; **51**: 934-943 [PMID: 31138509 DOI: 10.1016/j.dld.2019.04.015]
- 15 **Schneider M**, Höllerich J, Beyna T. Device-assisted enteroscopy: A review of available techniques and upcoming new technologies. *World J Gastroenterol* 2019; **25**: 3538-3545 [PMID: 31367155 DOI: 10.3748/wjg.v25.i27.3538]
- 16 **Kim J**. Training in Endoscopy: Enteroscopy. *Clin Endosc* 2017; **50**: 328-333 [PMID: 28783921 DOI: 10.5946/ce.2017.089]
- 17 **ASGE Technology Committee**, Chauhan SS, Manfredi MA, Abu Dayyeh BK, Enestvedt BK, Fujii-Lau LL, Komanduri S, Konda V, Maple JT, Murad FM, Pannala R, Thosani NC, Banerjee S. Enteroscopy. *Gastrointest Endosc* 2015; **82**: 975-990 [PMID: 26388546 DOI: 10.1016/j.gie.2015.06.012]
- 18 **Di Nardo G**, Calabrese C, Conti Nibali R, De Matteis A, Casciani E, Martemucci L, Pagliaro G, Pagano N. Enteroscopy in children. *United European Gastroenterol J* 2018; **6**: 961-969 [PMID: 30228882 DOI: 10.1177/2050640618789853]
- 19 **Broide E**, Shalem T, Richter V, Matalon S, Shirin H. The Safety and Feasibility of a New Through-the-scope Balloon-assisted Enteroscopy in Children. *J Pediatr Gastroenterol Nutr* 2020; **71**: e6-e11 [PMID: 32187142 DOI: 10.1097/MPG.0000000000002706]
- 20 **Mans L**, Arvanitakis M, Neuhaus H, Devière J. Motorized Spiral Enteroscopy for Occult Bleeding. *Dig Dis* 2018; **36**: 325-327 [PMID: 29698967 DOI: 10.1159/000488479]
- 21 **Rahmi G**, Samaha E, Vahedi K, Ponchon T, Fumex F, Filoche B, Gay G, Delvaux M, Lorenceau-Savale C, Malamut G, Canard JM, Chatellier G, Cellier C. Multicenter comparison of double-balloon enteroscopy and

- spiral enteroscopy. *J Gastroenterol Hepatol* 2013; **28**: 992-998 [PMID: 23488827 DOI: 10.1111/jgh.12188]
- 22 **Yamamoto H**, Ogata H, Matsumoto T, Ohmiya N, Ohtsuka K, Watanabe K, Yano T, Matsui T, Higuchi K, Nakamura T, Fujimoto K. Clinical Practice Guideline for Enteroscopy. *Dig Endosc* 2017; **29**: 519-546 [PMID: 28370422 DOI: 10.1111/den.12883]
 - 23 **Li X**, Zhao YJ, Dai J, Li XB, Xue HB, Zhang Y, Xiong GS, Ohtsuka K, Gao YJ, Liu Q, Song Y, Fang JY, Ge ZZ. Carbon dioxide insufflation improves the intubation depth and total enteroscopy rate in single-balloon enteroscopy: a randomised, controlled, double-blind trial. *Gut* 2014; **63**: 1560-1565 [PMID: 24626435 DOI: 10.1136/gutjnl-2013-306069]
 - 24 **Schulz C**, Mönkemüller K, Salheiser M, Bellutti M, Schütte K, Malfertheiner P. Double-balloon enteroscopy in the diagnosis of suspected isolated Crohn's disease of the small bowel. *Dig Endosc* 2014; **26**: 236-242 [PMID: 23855454 DOI: 10.1111/den.12142]
 - 25 **Navaneethan U**, Vargo JJ, Menon KV, Sanaka MR, Tsai CJ. Impact of balloon-assisted enteroscopy on the diagnosis and management of suspected and established small-bowel Crohn's disease. *Endosc Int Open* 2014; **2**: E201-E206 [PMID: 26135093 DOI: 10.1055/s-0034-1377522]
 - 26 **Rahman A**, Ross A, Leighton JA, Schembre D, Gerson L, Lo SK, Waxman I, Dye C, Semrad C. Double-balloon enteroscopy in Crohn's disease: findings and impact on management in a multicenter retrospective study. *Gastrointest Endosc* 2015; **82**: 102-107 [PMID: 25840927 DOI: 10.1016/j.gie.2014.12.039]
 - 27 **Tun GS**, Rattehalli D, Sanders DS, McAlindon ME, Drew K, Sidhu R. Clinical utility of double-balloon enteroscopy in suspected Crohn's disease: a single-centre experience. *Eur J Gastroenterol Hepatol* 2016; **28**: 820-825 [PMID: 27010557 DOI: 10.1097/MEG.0000000000000629]
 - 28 **Holleran G**, Valerii G, Tortora A, Scaldaferrri F, Conti S, Amato A, Gasbarrini A, Costamagna G, Riccioni ME. The use of single balloon enteroscopy in Crohn's disease and its impact on clinical outcome. *Scand J Gastroenterol* 2018; **53**: 925-929 [PMID: 29966446 DOI: 10.1080/00365521.2018.1476914]
 - 29 **Di Nardo G**, Oliva S, Aloï M, Rossi P, Casciani E, Masselli G, Ferrari F, Mallardo S, Stronati L, Cucchiara S. Usefulness of single-balloon enteroscopy in pediatric Crohn's disease. *Gastrointest Endosc* 2012; **75**: 80-86 [PMID: 21855873 DOI: 10.1016/j.gie.2011.06.021]
 - 30 **de Ridder L**, Mensink PB, Lequin MH, Aktas H, de Krijger RR, van der Woude CJ, Escher JC. Single-balloon enteroscopy, magnetic resonance enterography, and abdominal US useful for evaluation of small-bowel disease in children with (suspected) Crohn's disease. *Gastrointest Endosc* 2012; **75**: 87-94 [PMID: 21963066 DOI: 10.1016/j.gie.2011.07.036]
 - 31 **Urs AN**, Martinelli M, Rao P, Thomson MA. Diagnostic and therapeutic utility of double-balloon enteroscopy in children. *J Pediatr Gastroenterol Nutr* 2014; **58**: 204-212 [PMID: 24126830 DOI: 10.1097/MPG.0000000000000192]
 - 32 **Uchida K**, Yoshiyama S, Inoue M, Koike Y, Yasuda H, Fujikawa H, Okita Y, Araki T, Tanaka K, Kusunoki M. Double balloon enteroscopy for pediatric inflammatory bowel disease. *Pediatr Int* 2012; **54**: 806-809 [PMID: 22564182 DOI: 10.1111/j.1442-200X.2012.03661.x]
 - 33 **Kondo J**, Iijima H, Abe T, Komori M, Hiyama S, Ito T, Nakama A, Tominaga K, Kubo M, Suzuki K, Iwanaga Y, Ebara R, Takeda A, Tsuji S, Nishida T, Tsutsui S, Tsujii M, Hayashi N. Roles of double-balloon endoscopy in the diagnosis and treatment of Crohn's disease: a multicenter experience. *J Gastroenterol* 2010; **45**: 713-720 [PMID: 20174832 DOI: 10.1007/s00535-010-0216-6]
 - 34 **Möschler O**, May A, Müller MK, Ell C; German DBE Study Group. Complications in and performance of double-balloon enteroscopy (DBE): results from a large prospective DBE database in Germany. *Endoscopy* 2011; **43**: 484-489 [PMID: 21370220 DOI: 10.1055/s-0030-1256249]
 - 35 **Christian KE**, Kapoor K, Goldberg EM. Performance characteristics of retrograde single-balloon endoscopy: A single center experience. *World J Gastrointest Endosc* 2016; **8**: 501-507 [PMID: 27606042 DOI: 10.4253/wjge.v8.i15.501]
 - 36 **Mensink PB**, Groenen MJ, van Buuren HR, Kuipers EJ, van der Woude CJ. Double-balloon enteroscopy in Crohn's disease patients suspected of small bowel activity: findings and clinical impact. *J Gastroenterol* 2009; **44**: 271-276 [PMID: 19271117 DOI: 10.1007/s00535-009-0011-4]
 - 37 **Fukumoto A**, Tanaka S, Yamamoto H, Yao T, Matsui T, Iida M, Goto H, Sakamoto C, Chiba T, Sugano K. Diagnosis and treatment of small-bowel stricture by double balloon endoscopy. *Gastrointest Endosc* 2007; **66** Suppl 3: S108-S112 [PMID: 17709019 DOI: 10.1016/j.gie.2007.02.027]
 - 38 **Pohl J**, May A, Nachbar L, Ell C. Diagnostic and therapeutic yield of push-and-pull enteroscopy for symptomatic small bowel Crohn's disease strictures. *Eur J Gastroenterol Hepatol* 2007; **19**: 529-534 [PMID: 17556897 DOI: 10.1097/MEG.0b013e328012b0d0]
 - 39 **Ohmiya N**, Arakawa D, Nakamura M, Honda W, Shirai O, Taguchi A, Itoh A, Hirooka Y, Niwa Y, Maeda O, Ando T, Goto H. Small-bowel obstruction: diagnostic comparison between double-balloon endoscopy and fluoroscopic enteroclysis, and the outcome of enteroscopic treatment. *Gastrointest Endosc* 2009; **69**: 84-93 [PMID: 19111689 DOI: 10.1016/j.gie.2008.04.067]
 - 40 **Despott EJ**, Gupta A, Burling D, Tripoli E, Konieczko K, Hart A, Fraser C. Effective dilation of small-bowel strictures by double-balloon enteroscopy in patients with symptomatic Crohn's disease (with video). *Gastrointest Endosc* 2009; **70**: 1030-1036 [PMID: 19640518 DOI: 10.1016/j.gie.2009.05.005]
 - 41 **Hirai F**, Beppu T, Sou S, Seki T, Yao K, Matsui T. Endoscopic balloon dilatation using double-balloon endoscopy is a useful and safe treatment for small intestinal strictures in Crohn's disease. *Dig Endosc* 2010; **22**: 200-204 [PMID: 20642609 DOI: 10.1111/j.1443-1661.2010.00984.x]
 - 42 **Gill RS**, Kaffes AJ. Small bowel stricture characterization and outcomes of dilatation by double-balloon enteroscopy: a single-centre experience. *Therap Adv Gastroenterol* 2014; **7**: 108-114 [PMID: 24790641 DOI: 10.1177/1756283X13513995]
 - 43 **Hirai F**, Beppu T, Takatsu N, Yano Y, Ninomiya K, Ono Y, Hisabe T, Matsui T. Long-term outcome of endoscopic balloon dilatation for small bowel strictures in patients with Crohn's disease. *Dig Endosc* 2014; **26**: 545-551 [PMID: 24528293 DOI: 10.1111/den.12236]
 - 44 **Sunada K**, Shinozaki S, Nagayama M, Yano T, Takezawa T, Ino Y, Sakamoto H, Miura Y, Hayashi Y, Sato H, Lefor AK, Yamamoto H. Long-term Outcomes in Patients with Small Intestinal Strictures Secondary to

- Crohn's Disease After Double-balloon Endoscopy-assisted Balloon Dilation. *Inflamm Bowel Dis* 2016; **22**: 380-386 [PMID: 26535767 DOI: 10.1097/MIB.0000000000000627]
- 45 **Hirai F**, Andoh A, Ueno F, Watanabe K, Ohmiya N, Nakase H, Kato S, Esaki M, Endo Y, Yamamoto H, Matsui T, Iida M, Hibi T, Watanabe M, Suzuki Y, Matsumoto T. Efficacy of Endoscopic Balloon Dilation for Small Bowel Strictures in Patients With Crohn's Disease: A Nationwide, Multi-centre, Open-label, Prospective Cohort Study. *J Crohns Colitis* 2018; **12**: 394-401 [PMID: 29194463 DOI: 10.1093/ecco-jcc/jjx159]
- 46 **Rondonotti E**, Sunada K, Yano T, Paggi S, Yamamoto H. Double-balloon endoscopy in clinical practice: where are we now? *Dig Endosc* 2012; **24**: 209-219 [PMID: 22725104 DOI: 10.1111/j.1443-1661.2012.01240.x]
- 47 **Odagiri H**, Matsui H, Fushimi K, Kaise M, Yasunaga H. Factors associated with perforation related to diagnostic balloon-assisted enteroscopy: analysis of a national inpatient database in Japan. *Endoscopy* 2015; **47**: 143-146 [PMID: 25412096 DOI: 10.1055/s-0034-1390891]
- 48 **Mensink PB**, Haringsma J, Kucharzik T, Cellier C, Pérez-Cuadrado E, Mönkemüller K, Gasbarrini A, Kaffes AJ, Nakamura K, Yen HH, Yamamoto H. Complications of double balloon enteroscopy: a multicenter survey. *Endoscopy* 2007; **39**: 613-615 [PMID: 17516287 DOI: 10.1055/s-2007-966444]
- 49 **Gerson LB**, Tokar J, Chiorean M, Lo S, Decker GA, Cave D, Bouhaidar D, Mishkin D, Dye C, Haluszka O, Leighton JA, Zfass A, Semrad C. Complications associated with double balloon enteroscopy at nine US centers. *Clin Gastroenterol Hepatol* 2009; **7**: 1177-1182, 1182.e1-1182. e3 [PMID: 19602453 DOI: 10.1016/j.cgh.2009.07.005]
- 50 **Rondonotti E**, Spada C, Adler S, May A, Despott EJ, Koulaouzidis A, Panter S, Domagk D, Fernandez-Urien I, Rahmi G, Riccioni ME, van Hooft JE, Hassan C, Pennazio M. Small-bowel capsule endoscopy and device-assisted enteroscopy for diagnosis and treatment of small-bowel disorders: European Society of Gastrointestinal Endoscopy (ESGE) Technical Review. *Endoscopy* 2018; **50**: 423-446 [PMID: 29539652 DOI: 10.1055/a-0576-0566]
- 51 **Yokoyama K**, Yano T, Kumagai H, Mizuta K, Ono S, Imagawa T, Yamamoto H, Yamagata T. Double-balloon Enteroscopy for Pediatric Patients: Evaluation of Safety and Efficacy in 257 Cases. *J Pediatr Gastroenterol Nutr* 2016; **63**: 34-40 [PMID: 26628449 DOI: 10.1097/MPG.0000000000001048]
- 52 **Maaser C**, Sturm A, Vavricka SR, Kucharzik T, Fiorino G, Annese V, Calabrese E, Baumgart DC, Bettenworth D, Borralho Nunes P, Burisch J, Castiglione F, Eliakim R, Ellul P, González-Lama Y, Gordon H, Halligan S, Katsanos K, Kopylov U, Kotze PG, Krustinš E, Laghi A, Limdi JK, Rieder F, Rimola J, Taylor SA, Tolan D, van Rheenen P, Verstockt B, Stoker J; European Crohn's and Colitis Organisation [ECCO] and the European Society of Gastrointestinal and Abdominal Radiology [ESGAR]. ECCO-ESGAR Guideline for Diagnostic Assessment in IBD Part 1: Initial diagnosis, monitoring of known IBD, detection of complications. *J Crohns Colitis* 2019; **13**: 144-164 [PMID: 30137275 DOI: 10.1093/ecco-jcc/jjy113]
- 53 **Adamina M**, Bonovas S, Raine T, Spinelli A, Warusavitarne J, Armuzzi A, Bachmann O, Bager P, Biancone L, Bokemeyer B, Bossuyt P, Burisch J, Collins P, Doherty G, El-Hussuna A, Ellul P, Fiorino G, Frei-Lanter C, Furfaro F, Gingert C, Gionchetti P, Gisbert JP, Gomollon F, González Lorenzo M, Gordon H, Hlavaty T, Juillerat P, Katsanos K, Kopylov U, Krustins E, Kucharzik T, Lytras T, Maaser C, Magro F, Marshall JK, Myrelid P, Pellino G, Rosa I, Sabino J, Savarino E, Stassen L, Torres J, Uzzan M, Vavricka S, Verstockt B, Zmora O. ECCO Guidelines on Therapeutics in Crohn's Disease: Surgical Treatment. *J Crohns Colitis* 2020; **14**: 155-168 [PMID: 31742338 DOI: 10.1093/ecco-jcc/jjz187]



Published by **Baishideng Publishing Group Inc**
7041 Koll Center Parkway, Suite 160, Pleasanton, CA 94566, USA

Telephone: +1-925-3991568

E-mail: bpgoffice@wjgnet.com

Help Desk: <https://www.f6publishing.com/helpdesk>

<https://www.wjgnet.com>

