



29th World Congress on Ultrasound in Obstetrics and Gynecology

12-16 October 2019, Berlin, Germany

Join us in Berlin at the leading event in
obstetric and gynecological ultrasound.

Register now

- 12 August** Early bird registration deadline
- 12 October** Pre-Congress courses
- 13 October** Congress opens

For full details visit isuog.org/worldcongress/2019

congress@isuog.org | +44 (0)20 7471 9955

* Discounts apply to ISUOG members, trainees and sonographers

Organised by the International Society of Ultrasound in Obstetrics and Gynecology.

#ISUOG2019    

 **isuog**.org



Role of magnetic resonance imaging in fetuses with mild or moderate ventriculomegaly in the era of fetal neurosonography: systematic review and meta-analysis

D. DI MASCIO¹, F. G. SILEO², A. KHALIL^{2,3}, G. RIZZO^{4,5}, N. PERSICO^{6,7}, R. BRUNELLI¹, A. GIANCOTTI¹, P. B. PANICI¹, G. ACHARYA^{8,9} and F. D'ANTONIO^{9,10}

¹Department of Gynecological-Obstetric and Urological Sciences, Sapienza University of Rome, Rome, Italy; ²Fetal Medicine Unit, St George's University Hospitals NHS Foundation Trust, University of London, London, UK; ³Vascular Biology Research Centre, Molecular and Clinical Sciences Research Institute, St George's University of London, London, UK; ⁴Division of Maternal and Fetal Medicine, Ospedale Cristo Re, University of Rome Tor Vergata, Rome, Italy; ⁵Department of Obstetrics and Gynecology, The First I.M. Sechenov Moscow State Medical University, Moscow, Russia; ⁶Department of Obstetrics and Gynecology 'L. Mangiagalli', Ospedale Maggiore Policlinico, Milan, Italy; ⁷Department of Clinical Science and Community Health, University of Milan, Milan, Italy; ⁸Department of Clinical Science, Intervention and Technology, Karolinska Institute, Stockholm, Sweden; ⁹Women's Health and Perinatology Research Group, Department of Clinical Medicine, Faculty of Health Sciences, UiT – The Arctic University of Norway, Tromsø, Norway; ¹⁰Department of Obstetrics and Gynecology, University Hospital of Northern Norway, Tromsø, Norway

KEYWORDS: central nervous system; fetal magnetic resonance imaging; fetal MRI; fetal ultrasound; neurosonography; prenatal diagnosis; ventriculomegaly

ABSTRACT

Objectives To report the rate of additional central nervous system (CNS) anomalies detected exclusively on prenatal magnetic resonance imaging (MRI) in fetuses diagnosed with isolated mild or moderate ventriculomegaly (VM) on ultrasound, according to the type of ultrasound protocol adopted (dedicated neurosonography vs standard assessment of the fetal brain), and to explore whether the diagnostic performance of fetal MRI in detecting such anomalies is affected by gestational age at examination and laterality and degree of ventricular dilatation.

Methods MEDLINE, EMBASE, CINAHL and Clinicaltrials.gov were searched for studies reporting on the prenatal MRI assessment of fetuses diagnosed with isolated mild or moderate VM (ventricular dilatation of 10–15 mm) on ultrasound. Additional anomalies detected only on MRI were classified as callosal, septal, posterior fossa, white matter, intraventricular hemorrhage, cortical, periventricular heterotopia, periventricular cysts or complex malformations. The rate of additional anomalies was compared between fetuses diagnosed on dedicated neurosonography, defined as a detailed assessment of the fetal brain, according to the International Society of Ultrasound in Obstetrics and Gynecology guidelines, and those diagnosed on standard fetal brain assessment. The rate of additional CNS anomalies missed on prenatal MRI and detected only at

birth was calculated and compared between fetuses that had early (at or before 24 weeks' gestation) and those that had late (after 24 weeks) MRI. Subanalysis was performed according to the laterality (uni- vs bilateral) and degree (mild vs moderate, defined as ventricular dilatation of 10–12 and 13–15 mm, respectively) of ventricular dilatation. Whether MRI assessment led to a significant change in prenatal management was explored. Random-effects meta-analysis of proportions was used.

Results Sixteen studies (1159 fetuses) were included in the systematic review. Overall, MRI detected an anomaly not identified on ultrasound in 10.0% (95% CI, 6.2–14.5%) of fetuses. However, when stratifying the analysis according to the type of ultrasound assessment, the rate of associated anomalies detected only on MRI was 5.0% (95% CI, 3.0–7.0%) when dedicated neurosonography was performed compared with 16.8% (95% CI, 8.3–27.6%) in cases that underwent a standard assessment of the fetal brain in the axial plane. The overall rate of an additional anomaly detected only at birth and missed on prenatal MRI was 0.9% (95% CI, 0.04–1.5%) (I^2 , 0%). There was no difference in the rate of an associated anomaly detected only after birth when fetal MRI was carried out before, compared with after, 24 weeks of gestation ($P = 0.265$). The risk of detecting an associated CNS abnormality on MRI was higher in fetuses with moderate than in those with mild VM (odds ratio, 8.1 (95% CI, 2.3–29.0); $P = 0.001$), while

Correspondence to: Dr F. D'Antonio, Department of Obstetrics and Gynecology, Department of Clinical Medicine, Faculty of Health Sciences, UiT – The Arctic University of Norway, Hansine Hansens veg 18, Tromsø, Norway (e-mail: dantoniofra@gmail.com)

Accepted: 7 December 2018

there was no difference in those presenting with bilateral, compared with unilateral, dilatation ($P = 0.333$). Finally, a significant change in perinatal management, mainly termination of pregnancy owing to parental request, following MRI detection of an associated anomaly, was observed in 2.9% (95% CI, 0.01–9.8%) of fetuses undergoing dedicated neurosonography compared with 5.1% (95% CI, 3.2–7.5%) of those having standard assessment.

Conclusions In fetuses undergoing dedicated neurosonography, the rate of a CNS anomaly detected exclusively on MRI is lower than that reported previously. Early MRI has an excellent diagnostic performance in identifying additional CNS anomalies, although the findings from this review suggest that MRI performed in the third trimester may be associated with a better detection rate for some types of anomaly, such as cortical, white matter and intracranial hemorrhagic anomalies. Copyright © 2018 ISUOG. Published by John Wiley & Sons Ltd.

INTRODUCTION

Ventriculomegaly (VM) encompasses a spectrum of conditions characterized by dilatation of the lateral ventricles of the brain, typically defined as > 10 mm at the level of the atria, with or without dilatation of the third or fourth ventricle^{1–4}. VM is the most common prenatally diagnosed fetal brain anomaly, with a reported prevalence ranging from 1:1600 to 1:50 newborns^{1–4}.

VM is commonly categorized, according to the degree of ventricular dilatation, as mild (10–12 mm), moderate (13–15 mm) or severe (> 15 mm); the rationale for such classification relies on the fact that the risk of associated anomalies and abnormal neurodevelopmental outcome is higher with increasing degree of dilatation⁵. VM is not a unique condition, but rather a sonographic sign that represents a common endpoint of various pathological processes with different outcomes and prognoses; it may also be a physiological finding representing extreme normal variation^{6–8}.

The main determinants of postnatal outcome in fetuses presenting with VM are the etiology, presence of associated anomalies and severity of ventricular dilatation. Thus, the main issues to be resolved during the diagnostic work-up of a fetus with VM are ruling out infection and chromosomal, central nervous system (CNS) and non-CNS anomalies⁷.

Fetal magnetic resonance imaging (MRI) has been shown to add additional information compared with ultrasound in fetuses affected by a CNS anomaly⁹. The overall prevalence of additional brain abnormalities detected prenatally by MRI has been reported to be as high as 19% in fetuses with VM, irrespective of the degree of ventricular dilatation¹⁰. However, the majority of these studies do not report the type of ultrasound assessment performed, and the MRI scans were performed at different gestational ages. The International Society of Ultrasound

in Obstetrics and Gynecology (ISUOG) recommends that fetuses presenting with a CNS anomaly should undergo multiplanar assessment of the brain in axial, coronal and sagittal views of the fetal head¹¹. Therefore, it is plausible that the rate of associated anomalies detected exclusively on MRI reported in the published literature may be affected by the type of ultrasound assessment performed.

The primary aim of this systematic review was to report the rate of additional anomalies detected exclusively on prenatal MRI in fetuses diagnosed with isolated VM on ultrasound, according to the type of ultrasound protocol adopted. The secondary aim was to explore whether the diagnostic performance of fetal MRI in detecting such anomalies is affected by gestational age at examination.

METHODS

Protocol, eligibility criteria, information sources and search

This review was performed according to an *a-priori* designed protocol recommended for systematic reviews and meta-analyses^{12–14}. MEDLINE, EMBASE, CINAHL and Clinicaltrials.gov databases were searched electronically in June 2018, utilizing combinations of the relevant medical subject heading (MeSH) terms, keywords and word variants for ‘magnetic resonance imaging’ and ‘ventriculomegaly’ (Table S1). The search and selection criteria were restricted to the English language. Reference lists of relevant articles and reviews were hand searched for additional reports; PRISMA and MOOSE guidelines were followed^{15–17}. The study was registered with the PROSPERO database (registration number: CRD42018104173).

Study selection, data collection and data items

The primary aim of this study was to report the rate of additional anomalies detected exclusively on prenatal MRI in fetuses affected by isolated mild or moderate VM, defined as ventricular dilatation of 10–15 mm, undergoing, compared with those not undergoing, dedicated neurosonography, defined as a detailed assessment of the fetal brain in axial, sagittal and coronal views, according to ISUOG guidelines¹¹.

Additional anomalies were classified as: callosal anomalies, including complete and partial agenesis, hypoplasia and dysgenesis of the corpus callosum; septal anomalies, including all abnormalities characterized by a primary defect involving the septum pellucidum with a normally present corpus callosum; posterior fossa anomalies, including all defects involving the cerebellar vermis and/or hemispheres; intraventricular hemorrhage; cortical anomalies, including all abnormalities associated with a primary defect in neuronal migration towards the cortical surface of the brain; periventricular heterotopia; other white-matter anomalies; periventricular cysts; complex brain anomalies, including all defects characterized by the presence of multiple intracranial anomalies; and other cerebral anomalies.

For the purpose of the analysis, we did not consider as associated anomalies biometric variation in brain structure, such as mega cisterna magna, or increased or reduced degree of ventricular dilatation or of cranial size. Furthermore, we aimed at performing a subgroup analysis according to the laterality (unilateral *vs* bilateral VM) and degree (mild (10–12 mm) *vs* moderate (13–15 mm)) of ventricular dilatation.

Our secondary aim was to elucidate whether the diagnostic performance of fetal MRI for the detection of additional CNS anomalies was affected by gestational age at scan. For the purpose of the analysis, we calculated the rate of additional CNS anomalies missed on prenatal MRI and detected only at birth in fetuses that had early (at or before 24 weeks' gestation) compared with those that had late (after 24 weeks) MRI. Finally, we explored whether MRI detection of associated anomalies led to a change in the prenatal management of the pregnancy, mainly defined as termination of pregnancy (TOP) at parental request owing to the higher risk of abnormal neurodevelopmental outcome in fetuses with an associated anomaly detected on MRI.

Only studies reporting the prevalence of brain anomalies diagnosed on MRI in fetuses affected by isolated VM confirmed on postnatal imaging, or postmortem examination in case of TOP or fetal demise, were considered eligible for inclusion in this systematic review. VM was defined as isolated when no other CNS or non-CNS anomalies were detected on ultrasound.

Studies including cases with a fetal anomaly, those including exclusively cases of severe VM (defined as ventricular dilatation > 15 mm) and those not reporting the degree of ventricular dilatation were excluded in view of the higher risk of associated brain anomalies in cases presenting with additional anomalies and/or severe VM. Case reports, conference abstracts and case series with fewer than three cases were excluded to avoid publication bias. Furthermore, studies published before the ISUOG guidelines recommending a detailed assessment of the fetal brain (2007)¹¹ were also excluded, as advances in prenatal imaging and difficulties in extrapolating the type of ultrasound protocol used make them less relevant.

Two authors (D.D.M., F.G.S.) independently reviewed all abstracts. Agreement regarding potential relevance was reached by consensus or resolved by discussion with a third reviewer (F.D.A.). Full-text copies of those papers deemed to be relevant were obtained, and the same reviewers independently extracted relevant data regarding study characteristics and pregnancy outcomes. Consensus on inconsistencies was reached by discussion by the two reviewers or with a third author. If more than one study had been published on the same cohort with identical endpoints, the report containing the most comprehensive information on the population was included to avoid overlapping populations. For those articles in which information was not reported but the methodology was such that this information would have been recorded initially, the authors were contacted.

Quality assessment of the included studies was performed using the Newcastle–Ottawa Scale (NOS) for cohort studies. According to the NOS, each study is judged on three broad perspectives: selection of the study groups, comparability of the groups and ascertainment of the outcome of interest¹⁸. Assessment of the selection of the groups in a study includes evaluation of the representativeness of the exposed cohort, selection of the non-exposed cohort, ascertainment of exposure and demonstration that the outcome of interest was not present at the start of the study. Assessment of comparability of the study groups includes evaluation of the comparability of cohorts based on the design or analysis. Finally, assessment of ascertainment of the outcome of interest includes evaluation of the type of assessment of the outcome of interest and length and adequacy of follow-up. According to the NOS, a study can be awarded a maximum of one star for each numbered item within the selection and outcome categories; a maximum of two stars can be given for comparability¹⁸.

Statistical analysis

First, random-effects meta-analysis of proportions was used to estimate the pooled rates of each brain anomaly in fetuses diagnosed with isolated VM undergoing MRI assessment. Second, random-effects head-to-head meta-analysis was used to compare directly the risk of detecting an associated anomaly in fetuses undergoing early (≤ 24 weeks) compared with those undergoing late (> 24 weeks) fetal MRI, expressing the results as a summary odds ratio (OR) and 95% CI, and evaluating statistical heterogeneity using the I^2 metric. Data from individual studies were also combined to estimate the weighted mean gestational age at diagnosis of brain anomalies among fetuses with VM detected using the multiplanar approach. Only sparse data on gestational age were available in the standard ultrasound group, as well as on the time interval between ultrasound and MRI examinations in both groups. In these cases, no meta-analyses were performed and the results were reported only narratively for descriptive purposes. All included studies reported single-group analyses, and no outcome comparison between groups was available, thus no head-to-head meta-analysis could be performed.

Publication bias was assessed graphically using funnel plots, and formally using Egger's regression asymmetry test; formal tests for funnel-plot asymmetry were not performed when the total number of publications included for each outcome was less than 10 because in such cases the power of the test would be too low to distinguish chance from real asymmetry.

Both proportion and single-group meta-analyses of continuous data were performed using a random-effects model to account for interstudy heterogeneity. All analyses were carried out using Stata version 13.1 (Stata Corp., College Station, TX, USA, 2013).

RESULTS

General characteristics

Six hundred and twenty articles were identified, of which 66 were assessed with respect to their eligibility for inclusion (Table S2) and 16 were included in the systematic review (Tables 1 and S3 and Figure 1)^{19–34}. These sixteen studies included 1159 fetuses diagnosed with isolated mild or moderate VM. The diagnosis of isolated VM was based on multiplanar neurosonography in eight studies (596 fetuses), while a standard axial assessment of the fetal brain was used in the remaining eight studies (563 fetuses). Mean gestational age at MRI was 27.2 weeks (95% CI, 26.8–27.6 weeks) in fetuses undergoing neurosonography compared with 27.1 weeks (95% CI, 26.9–27.3 weeks) in those having standard assessment. Associated anomalies confirmed at birth or on autopsy were found in 8.6% (95% CI, 7.1–10.4%) of cases with a prenatal diagnosis of isolated VM on ultrasound.

The results of the quality assessment of the included studies using the NOS are presented in Table 2. Most of the included studies showed an overall good score regarding the selection and comparability of the study groups and ascertainment of the outcome of interest. The main weaknesses of the studies were their retrospective design, small sample size, different gestational ages at examination and lack of stratification of the results according to laterality and degree of ventricular dilatation in most of the included studies. Furthermore, stratification of the analysis according to gestational age at MRI was possible only by adopting a single cut-off (of 24 weeks' gestation), and we could not perform

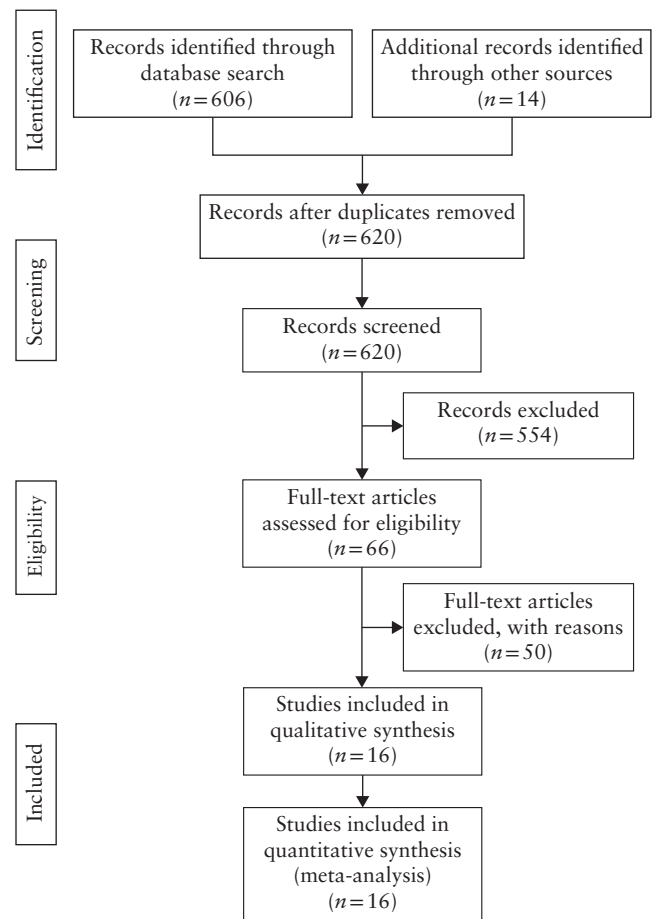


Figure 1 Flowchart summarizing inclusion of studies on prenatal magnetic resonance imaging assessment of fetuses diagnosed with isolated mild or moderate ventriculomegaly on ultrasound.

Table 1 Summary of characteristics of included studies reporting on prenatal magnetic resonance imaging (MRI) assessment of fetuses diagnosed with isolated mild or moderate ventriculomegaly (VM) on ultrasound

Study	Country	Study design	Study period	Fetuses (n)	GA at MRI*	US to MRI interval†	US route	Multi-planar US assessment	MRI field strength	Definition of VM (dilatation in mm)	Postnatal imaging
Griffiths (2017) ¹⁹	UK	Prosp	2011–2014	280	NS	Max 14 days	NS	No	1.5 T	10–15	US, MRI, CT
Lavongtheung (2018) ²⁰	France	Retro	2011–2015	14	31	Max 9 weeks	NS	No	1.5 T	10–12	US, MRI
Mehlhorn (2017) ²¹	USA	Retro	2009–2015	24	29.7	Max 5 weeks	TA	No	1.5 T	10–15	NS
Gezer (2016) ²²	Turkey	Retro	2007–2009	14	NS	NS	NS	No	1.5 T	10–15	US, MRI, CT
Tonni (2016) ²³	Italy	Prosp	2007–2010	54	26.6	Mean 1 week	NS	Yes	1.5 T	10–15	US, MRI
Baffero (2015) ²⁴	Italy	Retro	2001–2012	118	26.4	Median 1.0 (range, 0.0–12.6) weeks	TA	Yes	1.5 T	10–15	US, MRI
Kandula (2015) ²⁵	Australia	Prosp	2006–2013	52	28	Median 2 weeks	NS	No	1.5 T	10–15	NS
Paladini (2014) ²⁶	Italy	Retro	2005–2012	30	27	Max 1 week	TA and TV	Yes	1.5 T	10–15	US, MRI, CT
Pasquini (2014) ²⁷	Italy	Retro	2007–2012	132	30.16	Mean 3.7 weeks	TA and TV	Yes	1.5 T	10–15	US, MRI
Parazzini (2012) ²⁸	Italy	Retro	2003–2010	179	26 ± 4.2	Mean 7.6 days	TA and TV	Yes	1.5 T	10–12	US, MRI, CT
Miguelote (2012) ²⁹	Portugal	Prosp	2010–2011	18	NS	NS	NS	Yes	1.5 T	10–15	US, MRI
Han Huang (2013) ³⁰	Taiwan	Retro	2003–2010	42	NS	NS	NS	NS	1.5 T	10–15	NS
Griffiths (2010) ³¹	UK	Prosp	2005–2009	119	NS	Max 4 days	NS	NS	1.5 T	10–12	NS
Yin (2010) ³²	China	Prosp	2006–2008	51	31–38	NS	TA	Yes	1.5 T	10–12	NS
Benacerraf (2007) ³³	USA	Prosp	NS	14	24.14 ± 5.02	NS	TA and TV	Yes	1.5 T	10–12	NS
Morris (2007) ³⁴	UK	Retro	1999–2003	18	22.8	Max 4 days	NS	No	1.5 T	10–15	NS

Only first author of each study is given. *Data are mean, mean (range), median [interquartile range], mean ± SD or range. †Maximum (Max), mean or median interval. CT, computed tomography; GA, gestational age; NS, not stated; Prosp, prospective; Retro, retrospective; TA, transabdominal; TV, transvaginal; US, ultrasound.

Table 2 Quality assessment on Newcastle–Ottawa Scale of included studies reporting on prenatal magnetic resonance imaging assessment of fetuses diagnosed with isolated mild or moderate ventriculomegaly on ultrasound

Study	Selection	Comparability	Outcome
Griffiths (2017) ¹⁹	★★	★	★★
Lavongtheung (2018) ²⁰	★★	★	★★
Mehlhorn (2017) ²¹	★★	★	★★
Gezer (2016) ²²	★★	★	★★
Tonni (2016) ²³	★★	★	★★
Baffero (2015) ²⁴	★★	★	★★
Kandula (2015) ²⁵	★★	★	★
Paladini (2014) ²⁶	★★	★★	★★
Pasquini (2014) ²⁷	★★	★	★★
Parazzini (2012) ²⁸	★★	★	★★
Miguelote (2012) ²⁹	★★	★	★
Han Huang (2013) ³⁰	★★	★	★
Griffiths (2010) ³¹	★★	★	★★
Yin (2010) ³²	★★	★	★★
Benacerraf (2007) ³³	★★	★	★★
Morris (2007) ³⁴	★★	★	★★

Only first author of each study is given. A study can be awarded a maximum of one star for each numbered item within the selection and outcome categories. A maximum of two stars can be given for comparability.

any meaningful subanalysis according to time interval between ultrasound and MRI assessments.

Synthesis of results

Sixteen studies^{19–34} (1159 fetuses) explored the role of fetal MRI in detecting associated anomalies in fetuses with a prenatal diagnosis of isolated VM on ultrasound. Overall, MRI detected 10.0% (95% CI, 6.2–14.5%); (I^2 , 78.7%; 92/1159 fetuses) of fetal anomalies not detected on ultrasound. However, when stratifying the analysis according to the type of ultrasound assessment, the rate of associated anomalies detected only on MRI was 5.0% (95% CI, 3.0–7.0%) (I^2 , 5.9%; 28/596 fetuses) when dedicated neurosonography was performed, compared with 16.8% (95% CI, 8.3–27.6%) (I^2 , 86.1%; 64/563 fetuses) in cases diagnosed on standard assessment of the fetal brain in the axial plane (Figure 2).

When stratifying the analysis according to the type of anomaly detected on MRI, the incidence of a callosal anomaly undetected on ultrasound was 0.7% (95% CI, 0.2–1.5%) in fetuses that underwent neurosonography and 2.9% (95% CI, 1.1–5.7%) in those that had standard assessment of the fetal brain, while the corresponding figures for a posterior fossa anomaly were 0.4% (95% CI, 0.1–1.1%) and 0.9% (95% CI, 0.2–2.1%) (Table 3). Cortical anomalies missed on ultrasound were detected on MRI in 1.6% (95% CI, 0.9–2.3%) of fetuses with a prenatal diagnosis of isolated VM, with no difference between cases that underwent neurosonography and those that had standard assessment of the fetal brain (pooled proportions (PP), 1.6% (95% CI, 0.7–2.7%) vs 1.5% (95% CI, 0.7–2.7%)). Hemorrhagic lesions were missed on ultrasound and detected exclusively on MRI in 1.1% (95% CI, 0.3–2.4%) of cases that underwent

detailed neurosonography and 2.0% (95% CI, 0.6–4.1%) of those that received standard assessment. Finally, white-matter anomalies were missed on ultrasound and detected on MRI in 1.4% (95% CI, 0.6–2.5%) of cases with an ultrasound diagnosis of isolated VM overall, in 1.6% (95% CI, 0.7–2.7%) of those that had detailed neurosonography and in 1.8% (95% CI, 0.3–4.4%) of those that had a standard ultrasound assessment.

The overall rate of an additional anomaly detected only at birth and missed on prenatal MRI was 0.9% (95% CI, 0.04–1.5%) (I^2 , 0%). The rate of an associated CNS anomaly missed on prenatal MRI and diagnosed only at birth was 1.3% (95% CI, 0.5–2.4%) when MRI was performed before 24 weeks' gestation and 0.8% (95% CI, 0.3–1.7%) when carried out after 24 weeks, with no significant difference between the two groups (OR, 2.3 (95% CI, 0.5–9.9) (I^2 , 0%; P = 0.265)).

Subanalyses including only fetuses undergoing multiplanar assessment of the brain were performed according to degree of ventricular dilatation and laterality (Tables S4 and S5). The risk of detecting an associated CNS anomaly on MRI was higher in fetuses with moderate VM (PP, 22.6% (95% CI, 11.1–36.7%)) than in those with mild VM (PP, 3.5% (95% CI, 1.7–6.1%)) (OR, 8.1 (95% CI, 2.3–29.0) (I^2 , 18.1%; P = 0.001)), while there was no difference in those presenting with bilateral VM (PP, 7.2% (95% CI, 3.3–12.3%) (I^2 , 46.7%)) compared to those with unilateral VM (PP, 3.0% (95% CI, 0.8–6.3%) (I^2 , 0%)) (OR, 1.8 (95% CI, 0.6–5.4) (I^2 , 8.1%; P = 0.333)).

Finally, the rate of the change in perinatal management after prenatal MRI was explored. Overall, 4.6% (95% CI, 2.1–8.0%) (I^2 , 61%) of fetuses with a prenatal diagnosis of isolated VM on ultrasound had a significant change in perinatal management, mainly TOP at parental request, following detection of an associated anomaly on MRI. When stratifying the analysis according to the type of ultrasound assessment performed, a significant change in perinatal management involved 2.9% (95% CI, 0.01–9.8%) (I^2 , 65.3%) of fetuses that underwent neurosonography compared with 5.1% (95% CI, 3.2–7.5%) (I^2 , 7.8%) of those that had a standard assessment.

DISCUSSION

Main findings

The findings from this systematic review show that, in fetuses affected by VM undergoing dedicated neurosonography, the rate of a CNS anomaly detected exclusively on MRI is lower than has been reported previously. Fetal MRI has a high diagnostic accuracy in identifying associated anomalies regardless of gestational age at MRI. Furthermore, the risk of detecting associated anomalies is higher in fetuses with moderate, compared to those with mild, VM, while there was no difference between cases with unilateral, compared to those with bilateral, VM.

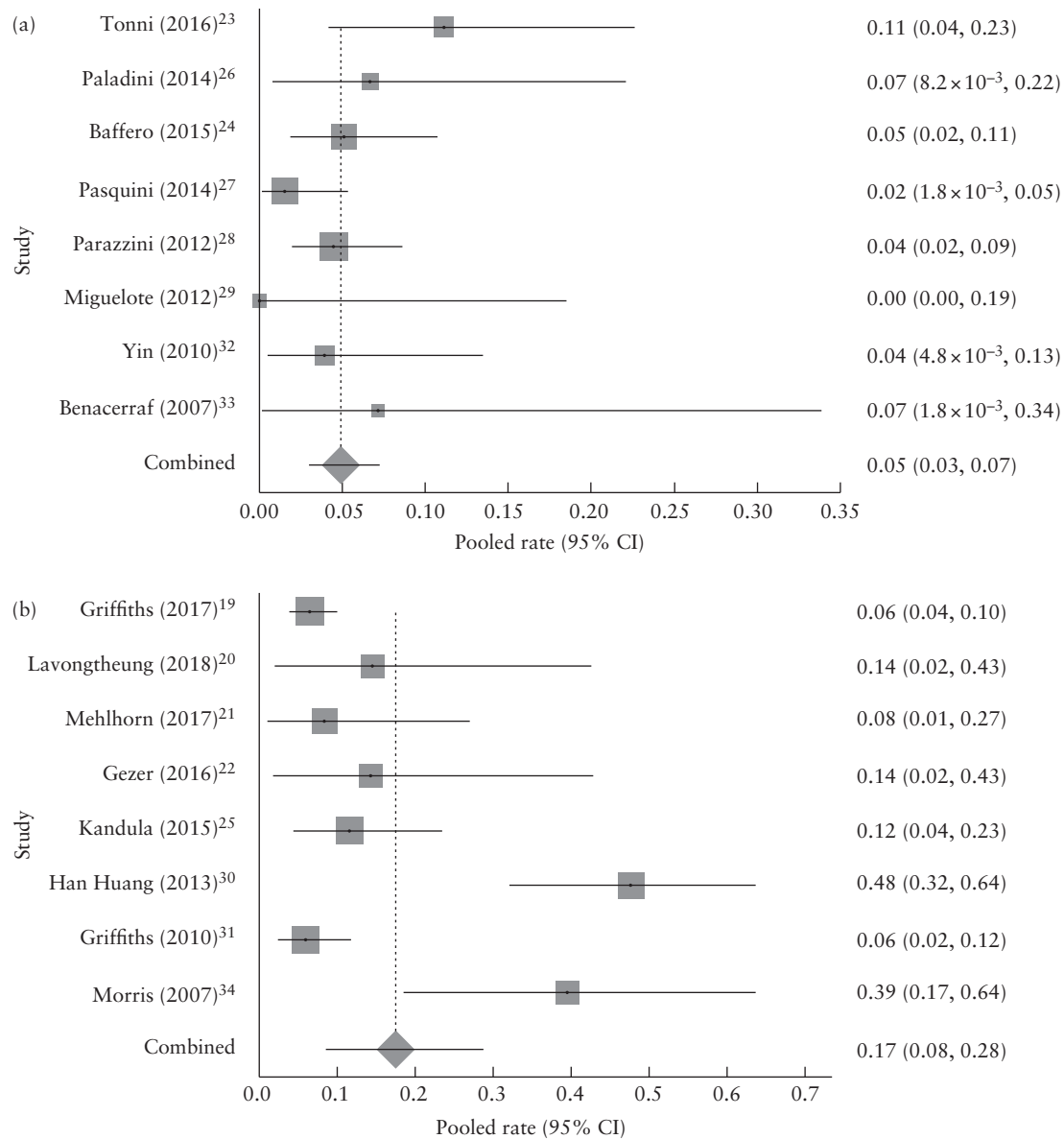


Figure 2 Pooled rates of additional brain anomalies detected on magnetic resonance imaging in fetuses diagnosed with isolated mild or moderate ventriculomegaly on multiplanar neurosonography (a) and standard ultrasound assessment of brain (b).

Table 3 Pooled proportions of rate of additional central nervous system (CNS) anomalies detected on magnetic resonance imaging in fetuses with prenatal diagnosis of isolated mild or moderate ventriculomegaly on ultrasound, according to ultrasound assessment

CNS anomaly	All cases				Multiplanar neurosonography				Standard brain assessment			
	Studies (n)	Fetuses (n/N)	Pooled proportion (%)	I ² (%)	Studies (n)	Fetuses (n/N)	Pooled proportion (%)	I ² (%)	Studies (n)	Fetuses (n/N)	Pooled proportion (%)	I ² (%)
Callosal	16	15/1159	1.42 (0.7–2.4)	26.0	8	2/596	0.67 (0.2–1.5)	0	8	13/563	2.92 (1.1–5.7)	46.3
Septal	16	2/1159	0.45 (0.1–0.9)	0	8	0/596	0 (0–0.9)	0	8	2/563	0.66 (0.2–1.5)	0
Posterior fossa	16	5/1159	0.56 (0.2–1.1)	5.8	8	2/596	0.44 (0.1–1.1)	0.8	8	3/563	0.85 (0.2–2.1)	19.7
Hemorrhage	16	14/1159	1.43 (0.6–2.5)	35.4	8	5/596	1.07 (0.3–2.4)	32.1	8	9/563	1.97 (0.6–4.1)	39.2
Cortical	16	15/1159	1.55 (0.9–2.3)	0	8	8/596	1.56 (0.7–2.7)	0	8	7/563	1.53 (0.7–2.7)	0
Periventricular heterotopia	16	0/1159	0 (0–0.7)	0	8	0/596	0 (0–0.9)	0	8	0/563	0 (0–0.9)	0
White matter	16	15/1159	1.39 (0.6–2.5)	32.8	8	8/596	1.57 (0.7–2.7)	0	8	7/563	1.75 (0.3–4.4)	57.9
Periventricular cyst	16	2/1159	0.41 (0.1–0.9)	0	8	1/596	0.45 (0.01–1.1)	0	8	1/563	0.36 (0.03–1.0)	0
Complex	16	8/1159	0.85 (0.4–1.5)	0	8	1/596	0.44 (0.01–1.1)	0	8	7/563	1.55 (0.7–2.7)	0
Other	16	16/1159	1.68 (0.5–3.5)	67.9	8	1/596	0.38 (0.001–1.0)	0	8	15/563	4.03 (0.7–9.9)	82.8

Data in parentheses are 95% CI.

Limitations of the study

Retrospective design, small sample size, different gestational ages at examination and lack of stratification of the results according to laterality and degree of ventricular dilatation in most of the included studies represent the main limitations of this systematic review. Furthermore, not all cases presenting an additional anomaly on MRI were screened for aneuploidy or infection. In this scenario, it might be possible that some cases affected by aneuploidy or infection diagnosed only later on after birth were included in the analysis, thus affecting the robustness of the results. Finally, it was not possible to rule out completely inclusion of cases complicated by maternal medical conditions potentially leading to an increased risk of associated CNS anomalies in the setting of VM, which may explain the relatively high incidence of acquired brain anomalies, such as hemorrhage, reported in this review.

Implications for clinical practice and research

Ruling out associated anomalies in fetuses with a prenatal diagnosis of VM is fundamental, as the neurodevelopmental outcome of these children is greatly affected by the presence of associated malformations.

ISUOG recommends that fetuses presenting with a CNS anomaly should undergo a multiplanar assessment of the fetal head in order to rule out associated anomalies that may be missed on a standard assessment. Likewise, the Society for Maternal–Fetal Medicine suggests that MRI should be considered in cases of mild or moderate fetal VM, although it may be of less value if the woman has had a detailed ultrasound examination performed by an individual with specific experience of, and expertise in, sonographic imaging of the fetal brain. These statements from two key maternal–fetal medicine societies highlight the need for a detailed assessment of the fetal brain when VM is detected on a scan. Despite this, it is common clinical practice to refer pregnancies with fetuses presenting with VM for MRI without a detailed assessment of the brain. This has led to a high reported incidence of associated anomalies detected only on MRI in fetuses presenting with isolated VM on ultrasound.

In the present review, the large majority of associated malformations undetected on ultrasound in cases undergoing standard assessment comprised a callosal anomaly. This emphasizes the need for detailed neurosonography in fetuses presenting with ventricular dilatation in axial views in order to reduce the number of cases classified incorrectly as isolated VM. This is also fundamental, as fetal MRI may not be available immediately and a late diagnosis of an associated anomaly may lead to increased parental stress and a lack of legal options in the prenatal management of the pregnancy. This is also highlighted by the different amounts of change in prenatal management after MRI in fetuses undergoing, compared with those not undergoing, neurosonography.

It has been suggested that fetal MRI has a high diagnostic accuracy in detecting cortical malformations,

such as polymicrogyria and schizencephaly^{10,35}. The true prevalence of congenital cortical anomalies in the general population is largely unknown and some of these cases are suspected on fetal ultrasound during the third trimester of pregnancy based on the subjective findings of immature sulcation, thin and smooth cortex or wide and thick gyri. In the present systematic review, the rate of cortical anomalies detected exclusively on MRI was about 1.6%, highlighting the need for a detailed MRI assessment of the fetal brain in order to rule out such anomalies.

The severity of ventricular dilatation is associated with an increasing risk of adverse neurodevelopmental outcome in fetuses presenting with isolated VM. In the present systematic review, the rate of an associated anomaly detected only on MRI was 3.5% and 22.6% in cases with mild and moderate VM, respectively, suggesting that increasing ventricular dilatation is associated with a higher risk of an associated anomaly. Conversely, there was no difference in the rate of associated anomalies detected only on MRI in fetuses with unilateral, compared to those with bilateral, VM, although the very small number of cases included in this subanalysis may have led to a lack of statistical power.

Gestational age at MRI is another important clinical factor when assessing fetuses with an ultrasound diagnosis of isolated VM. Early (second-trimester) MRI assessment is useful to confirm the diagnosis and rule out associated anomalies, especially in those countries in which TOP beyond the second trimester is not allowed, although it may overlook anomalies such as cortical malformations or hemorrhage, which become evident only later on in gestation. In this systematic review, the overall rate of additional anomalies detected only at birth and missed on prenatal MRI was 1.3% (95% CI, 0.5–2.4%) when MRI was performed before, and 0.8% (95% CI, 0.3–1.7%) when carried out after, 24 weeks' gestation. Although there was no statistical difference in the rates of undetected CNS anomalies between fetuses that had early, and those that had late, MRI, it would be reasonable to perform MRI in the third trimester of pregnancy, as most of the anomalies coexisting with VM, such as cortical, white matter or hemorrhage, become more evident after 24 weeks' gestation. However, parents should be reassured that, in cases in which VM is apparently isolated on fetal MRI, the probability of an undetected anomaly at birth is low.

Conclusions

Fetuses diagnosed with isolated VM on ultrasound screening examination should be referred for dedicated neurosonography in order to rule out associated anomalies that may affect the short- and long-term neurodevelopmental outcome of these children. MRI assessment of these fetuses is recommended to detect associated anomalies that may be missed on neurosonography in about 5% of cases. Although early MRI is reliable, a third-trimester ultrasound scan may detect conditions potentially missed on a second-trimester scan, such as hemorrhage. In the future, large prospective studies

sharing objective protocols for ultrasound imaging of the fetal brain are needed to elucidate better the actual role of fetal MRI when fetal neurosonography has been performed.

ACKNOWLEDGMENTS

We thank Prof. Edward Araujo, Prof. Beryl Benecerraf, Prof. Julien Chevreau, Prof. Mariarosaria Di Tommaso, Dr Sinem Gezer, Prof. Stacy Goergen, Prof. Lucia Mangano, Dr Giulia Masini, Dr Cecilia Parazzini, Prof. Pierpaolo Peruzzi, Dr Gabriele Tonni and Dr Pierre Tourneux for providing further information from their studies.

REFERENCES

- Achiron R, Schimmel M, Achiron A, Mashiah S. Fetal mild idiopathic lateral ventriculomegaly: is there a correlation with fetal trisomy? *Ultrasound Obstet Gynecol* 1993; 3: 89–92.
- Alagappan R, Browning PD, Laorr A, McGahan JP. Distal lateral ventricular atrium: reevaluation of normal range. *Radiology* 1994; 193: 405–408.
- Nomura ML, Barini R, De Andrade C, Milanez H, Simoni RZ, Peralta CF, Machado IN, Zambelli H, Maio KT. Congenital hydrocephalus: gestational age and neonatal outcomes. *Arch Gynecol Obstet* 2010; 282: 607–611.
- Garel C, Luton D, Oury JF, Gressens P. Ventricular dilatations. *Childs Nerv Syst* 2003; 19: 517–523.
- Society for Maternal–Fetal Medicine (SMFM); Fox NS, Monteagudo A, Kuller JA, Craigo S, Norton ME. Mild fetal ventriculomegaly: diagnosis, evaluation, and management. *Am J Obstet Gynecol* 2018; 219: B2–B9.
- Signorelli M, Tiberti A, Valsariati D, Molin E, Cerri V, Groli C, Bianchi UA. Width of fetal lateral ventricular atrium between 10 and 12 mm: a simple variation of the norm? *Ultrasound Obstet Gynecol* 2004; 23: 14–18.
- Melchiorre K, Bhide A, Gika AD, Pilu G, Papageorghiu AT. Counseling in isolated mild fetal ventriculomegaly. *Ultrasound Obstet Gynecol* 2009; 34: 212–224.
- Shizuo OI. Controversies in definition and classification of hydrocephalus. *Neurol Med Chir* 2010; 50: 859–869.
- Rossi AC, Prefumo F. Additional value of fetal magnetic resonance imaging in the prenatal diagnosis of central nervous system anomalies: a systematic review of the literature. *Ultrasound Obstet Gynecol* 2014; 44: 388–393.
- Scala C, Familiari A, Pinas A, Papageorghiu AT, Bhide A, Thilaganathan B, Khalil A. Perinatal and long-term outcome in fetuses diagnosed with isolated unilateral ventriculomegaly: systematic review and meta-analysis. *Ultrasound Obstet Gynecol* 2017; 49: 450–459.
- International Society of Ultrasound in Obstetrics & Gynecology Education Committee. Sonographic examination of the fetal central nervous system: guidelines for performing the ‘basic examination’ and the ‘fetal neurosonogram’. *Ultrasound Obstet Gynecol* 2007; 29: 109–116.
- Henderson LK, Craig JC, Willis NS, Tovey D, Webster AC. How to write a Cochrane systematic review. *Nephrology (Carlton)* 2010; 15: 617–624.
- NHS Centre for Reviews and Dissemination. *Systematic reviews: CRD’s guidance for undertaking reviews in health care*. University of York, York, UK, 2009. Available at: https://www.york.ac.uk/media/crd/Systematic_Reviews.pdf.
- Welch V, Petticrew M, Petkovic J, Moher D, Waters E, White H, Tuqwell P. Extending the PRISMA statement to equity-focused systematic reviews (PRISMA-E 2012): explanation and elaboration. *J Clin Epidemiol* 2016; 70: 68–89.
- Moher D, Liberati A, Tetzlaff J, Altman DG; PRISMA Group. Preferred reporting items for systematic reviews and meta-analyses: the PRISMA statement. *Ann Intern Med* 2009; 151: 264–269.
- Zorzela L, Loke YK, Ioannidis JP, Golder S, Santaguida P, Altman DG, Moher D, Vohra S; PRISMAHarms Group. PRISMA harms checklist: improving harms reporting in systematic reviews. *BMJ* 2016; 352: i157.
- Stroup DF, Berlin JA, Morton SC, Olkin I, Williamson GD, Rennie D, Moher D, Becker BJ, Sipe TA, Thacker SB. Meta-analysis of observational studies in epidemiology: a proposal for reporting. Meta-analysis of Observational Studies in Epidemiology (MOOSE) group. *JAMA* 2000; 283: 2008–2012.
- Newcastle–Ottawa Scale for assessing the quality of nonrandomised studies in meta-analyses. Available at: http://www.ohri.ca/programs/clinical_epidemiology/oxford.asp
- Griffiths PD, Brackley K, Bradburn M, Connolly DJ, Gawne-Cain ML, Griffiths DI, Kilby MD, Mandfield L, Mooney C, Robson SC, Vollmer B, Mason G. Anatomical subgroup analysis of the MERIDIAN cohort: ventriculomegaly. *Ultrasound Obstet Gynecol* 2017; 50: 736–744.
- Lavongthueang A, Jedraszak G, Naepels P, Tourneux P, Gondry-Jouet C, Le Moing AG, Gondry J, Chevreau J. Should isolated fetal ventriculomegaly measured below 12 mm be viewed as a variant of the norm? Results of a 5-year experience in a prenatal referral center. *J Matern Fetal Neonatal Med* 2018; 31: 2325–2331.
- Mehlhorn, AJ, Morin CE, Wong-You-Cheong JJ, Contag SA. Mild fetal cerebral ventriculomegaly: prevalence, characteristics, and utility of ancillary testing in cases presenting to a tertiary referral center. *Prenat Diagn* 2017; 37: 647–657.
- Gezer NS, Gezer C, Ekin A, Yesilirmak DC, Solmaz U, Dogan A, Guleryuz H. Obstetric and neurodevelopmental outcome in fetal cerebral ventriculomegaly. *Clin Exp Obstet Gynecol* 2016; 43: 490–494.
- Tonni G, Vito I, Palmisano M, Martins WP, Araujo Júnior E. Neurological Outcome in Fetuses with Mild and Moderate Ventriculomegaly. *Rev Bras Ginecol Obstet* 2016; 38: 436–442.
- Baffero GM, Crovotto F, Fabietti I, Boito S, Fogliani R, Fumagalli M, Triulzi F, Mosca F, Fedele L, Persico N. Prenatal ultrasound predictors of postnatal major cerebral abnormalities in fetuses with apparently isolated mild ventriculomegaly. *Prenat Diagn* 2015; 35: 783–788.
- Kandula T, Fahey M, Chalmers R, Edwards A, Shekleton P, Teoh M, Clark J, Goergen SK. Isolated ventriculomegaly on prenatal ultrasound: what does fetal MRI add? *J Med Imaging Radiat Oncol* 2015; 59: 154–162.
- Paladini D, Quarantelli M, Sglavo G, Pastore G, Cavallaro A, D’Armiento MR, Salvatore M, Nappi C. Accuracy of neurosonography and MRI in clinical management of fetuses referred with central nervous system abnormalities. *Ultrasound Obstet Gynecol* 2014; 44: 188–196.
- Pasquini L, Masini G, Gaini C, Franchi C, Trotta M, Dani C, Di Tommaso M. The utility of infection screening in isolated mild ventriculomegaly: an observational retrospective study on 141 fetuses. *Prenat Diagn* 2014; 34: 1295–1300.
- Parazzini C, Righini A, Doneda C, Arrigoni F, Rustico M, Lanna M, Triulzi F. Is fetal magnetic resonance imaging indicated when ultrasound isolated mild ventriculomegaly is present in pregnancies with no risk factors? *Prenat Diagn* 2012; 32: 752–757.
- Miguelote RF, Vides B, Santos RF, Palha JA, Matias A, Sousa N. Cortical maturation in fetuses referred for ‘isolated’ mild ventriculomegaly: a longitudinal ultrasound assessment. *Prenat Diagn* 2012; 32: 1273–1281.
- Han Huang Y, Hang Ng S, Hong Toh C, Ming Wu Y, Fai Wong H, Ching Wong AM. Fetal Ventriculomegaly: Investigating Additional Brain Abnormalities by using MR Imaging. *J Radiol Sci* 2013; 38: 35–41.
- Griffiths P, Reeves MJ, Morris JE, Mason G, Russell SA, Paley MN, Whitby EH. A prospective study of fetuses with isolated ventriculomegaly investigated by antenatal sonography and in utero MR imaging. *AJNR Am J Neuroradiol* 2010; 31: 106–111.
- Yin S, Na Q, Chen J, Li-Ling J, Liu C. Contribution of MRI to detect further anomalies in fetal ventriculomegaly. *Fetal Diagn Ther* 2010; 27: 20–24.
- Benacerraf BR, Shipp TD, Bromley B, Levine D. What does magnetic resonance imaging add to the prenatal sonographic diagnosis of ventriculomegaly? *J Ultrasound Med* 2007; 26: 1513–1522.
- Morris JE, Rickard S, Paley MNJ, Griffiths PD, Rigby A, Whitby EH. The value of in-utero magnetic resonance imaging in ultrasound diagnosed foetal isolated cerebral ventriculomegaly. *Clin Radiol* 2007; 62: 140–144.
- Glenn OA, Cuneo AA, Barkovich AJ, Hashemi Z, Bartha AI, Xu D. Malformations of cortical development: diagnostic accuracy of fetal MR imaging. *Radiology* 2012; 263: 843–855.

SUPPORTING INFORMATION ON THE INTERNET

The following supporting information may be found in the online version of this article:



Table S1 Search strategy for studies reporting on prenatal MRI assessment of fetuses diagnosed with isolated mild or moderate ventriculomegaly on ultrasound

Table S2 Excluded studies and reason for exclusion

Table S3 Detailed characteristics of included studies reporting on prenatal MRI assessment of fetuses diagnosed with isolated mild or moderate ventriculomegaly on ultrasound

Table S4 Pooled proportions (95% CI) for rate of additional anomalies detected only on MRI in fetuses diagnosed with isolated VM on dedicated neurosonography, according to severity

Table S5 Pooled proportions (95% CI) for rate of additional anomalies detected only on MRI in fetuses diagnosed with isolated VM on dedicated neurosonography, according to laterality of VM