

Clinical procedure in sealing pit and fissure using technological aids: VistaCam iX Proof and Combi

Fabrizio Guerra*, Marta Mazur, Francesca Rinaldo, Denise Corridore, Debora Pasqualotto, Gianna Maria Nardi, Livia Ottolenghi.

Affiliations: Department of Oral and Maxillo-facial Sciences, Oral Diagnosis Unit, "Sapienza" University of Rome, Via Caserta, 6-00161 Rome, Italy.

*Corresponding author: Fabrizio Guerra, e-mail: fabrizio.guerra@uniroma1.it; Tel.: +390649918151

Article history

Received: March 15, 2016

Accepted: March 29, 2016

Published: March 31, 2016

Abstract

The effectiveness of sealants in preventing pits and fissures decay is currently assessed by retention as principal clinical evaluation criteria. Among the determinants for sealant retention, an incomplete removal of plaque debris can cause lack of adhesion at the sealant-enamel interface. Therefore, in order to optimize the caries prevention outcome, clinical procedures of biofilm detection and cleansing are crucial. Technological aids can help clinicians in these critical phases. A clinical procedure is described of sealant application using VistaCam iX Proof fluorescence camera for quantitative assessment of surface demineralization and Combi air polishing unit for plaque removal. Pre and post air polishing intraoral VistaCam iX Proof images show the effectiveness of glycine air-polish technology in plaque removal. The results encourage technological aided clinical procedures in enhancing sealant application for pit and fissures caries prevention. Further clinical research is needed to validate our preliminary outcomes.

Keywords: sealants; fluorescence; air-polish.

Introduction

Dental sealants were introduced in the 1960s as part of the preventive dental programs. Sealing is a method widely described in literature as a simple, safe and effective clinical procedure in terms of cost / benefit and, therefore, it is highly recommended [1] [2] [3] [4] [5]. The longevity of sealant coverage [i.e. clinical retention] defines the effectiveness of sealants [6]. Among the determinants for sealant retention, an incomplete removal of plaque debris can cause lack of adhesion at the sealant-enamel interface [7]. Therefore, in order to optimize the caries prevention outcome, clinical procedures of biofilm detection is crucial and ensures complete cleansing of pit and fissures is mandatory.

Technological aids can help clinicians in these critical phases. Quantitative assessment of surface demineralization is detectable through currently marketed fluorescence based intraoral camera and tooth polishing is a procedure carried out as a part of oral prophylaxis in most dental practices. [8]. We here propose a technological aided clinical procedure for pit and fissure sealing, also reporting a clinical case to show the technological aiding tool usage in the pre-conditioning operative phase of sealing procedures.

We used a fluorescence-based camera (Vistacam iX Proof, Durr Dental) for the quantitative assessment of demineralization in pit and fissures [9] and an air-polishing unit (Combi, Mectron S.p.a.) for pre-sealing surface cleansing.

Materials and Methods

Eligible teeth for pit and fissure sealing are permanent molars totally erupted, with deep pit and fissure morphology, ICDAS-II codes 0,1 or 2.

Technologically aided pit and fissures sealing procedure: (The illustrative case of A. Z., male, 12 years old, with no obvious pit and fissure caries, on first left lower molar, is described).

Field isolation - eligible tooth was isolated with a rubber dam [OpraDam® Plus, Ivoclar Vivadent] (Fig 1).

Surface demineralization evaluation [pre] - VistaCam iX Proof measurements were taken after tooth drying with air pressure. The measured value was null (Fig.2).

Biofilm removal - To completely remove plaque from pit and fissures surface, air-polish cleaning with glycine powder was performed (Fig 3). We used an air polishing device (COMBI air polishing, standard handpiece, particle size of glycine powder is < 63 µm, Mectron S.p.a.) installed in an automated apparatus under defined and standardized conditions.

Powder and water settings were standardized to 50 % of the maximum level. The nozzle was placed 5–6 mm away from the tooth surface with the spray directed toward the occlusal surface and the middle third of the crown, cleansed with a constant circular motion. Since the air polishing device generates aerosol, a mask and protective eyewear were used [10].

Surface rinsing - The tooth was rinsed with water spray for 20 seconds.

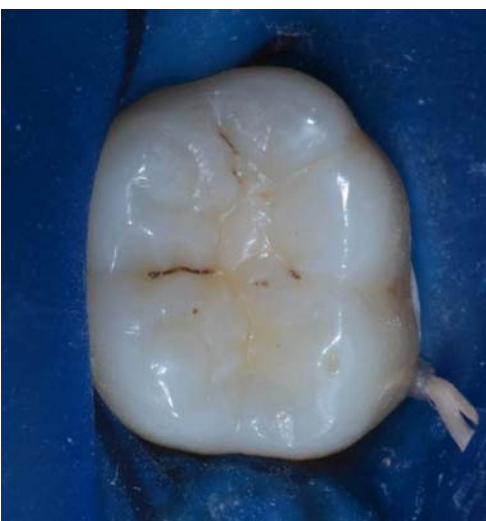

Figure 1: Rubber dam isolation

Surface drying - and air dried for 5 seconds with an air-water spray.

Surface demineralization evaluation (post) - A second evaluation of the surface with the fluorescence camera was performed, to provide quantitative measure of biofilm removal. Figure 4 shows the complete biofilm removal and VistaCam value 1.3 (incipient enamel demineralization).

Enamel conditioning - Enamel was conditioned for 20-30 seconds with 37% phosphoric acid, directly using the gel dispenser with special applicator tip, ensuring that the gel was only worked down into the fissures; (Fig 5)

Surface rinsing - The tooth was rinsed with water spray for 60 seconds (Fig 6)

Surface drying - and air dried for 20 seconds. From the rubber dam to the tooth surface until obtaining a white chalky surface on the entire design of pit and fissure (Fig 7).

Sealant application - Resin sealant (Grandio Seal, VOCO GmbH) was applied with the applicator tip provided by the manufacturer. The correct amount of sealant was applied in order to cover the entire prepared area and left 20 seconds to allow the resin to flow into the etched surface (Fig 6).

Light curing - The tooth was light cured for 60 seconds. The light-curing time should vary from 20 to 60 seconds depending on the curing lamp used. The tip of the light should be kept as close as possible to the sealant and perpendicularly to the tooth surface (Fig 8).

Occlusion control - Rubber dam was removed and occlusion was checked with articulating paper (Fig 9-10).

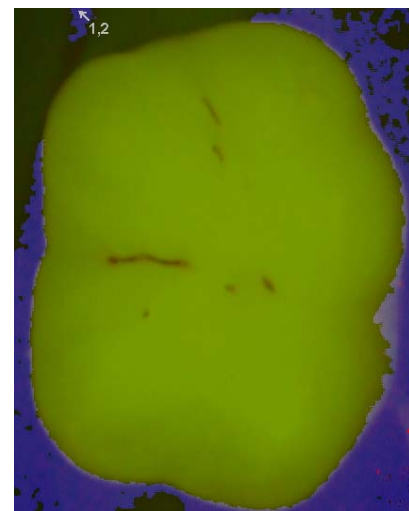

Figure 2: VistaCam iX Proof value on first left lower molar pre polishing procedure

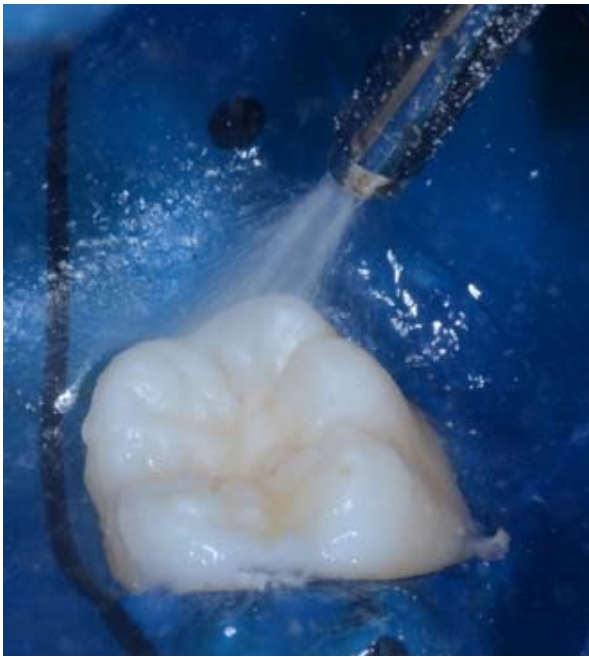


Figure 3: Air polishing using Combi [Mectron S.p.a.]

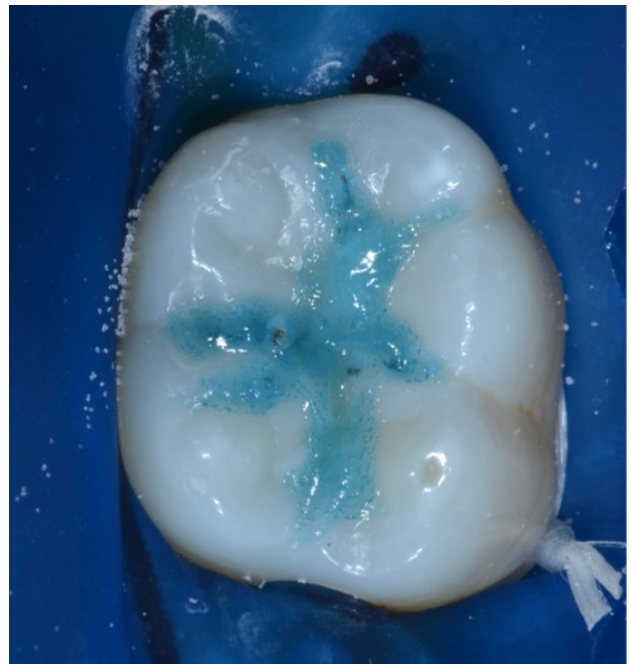


Figure 5: Enamel conditioning

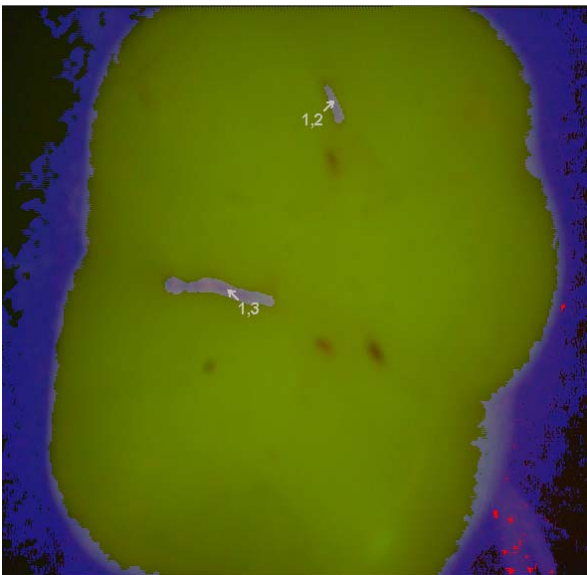


Figure 4: VistaCam iX Proof value on first left lower molar post polishing procedure.

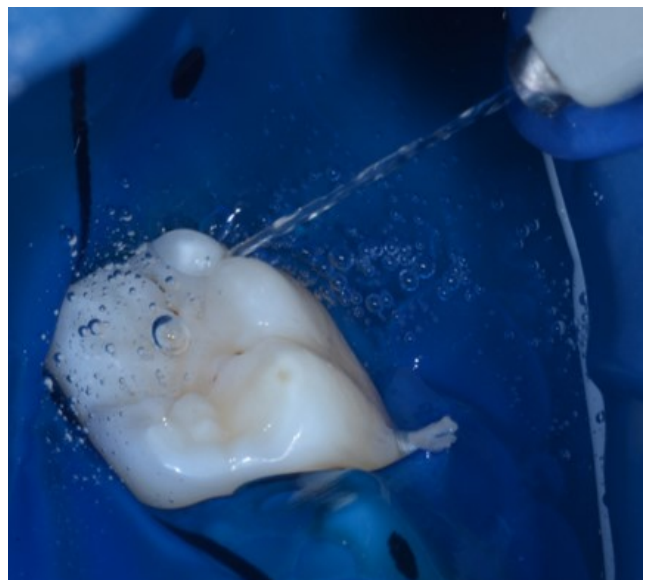


Figure 6: Surface rinsing

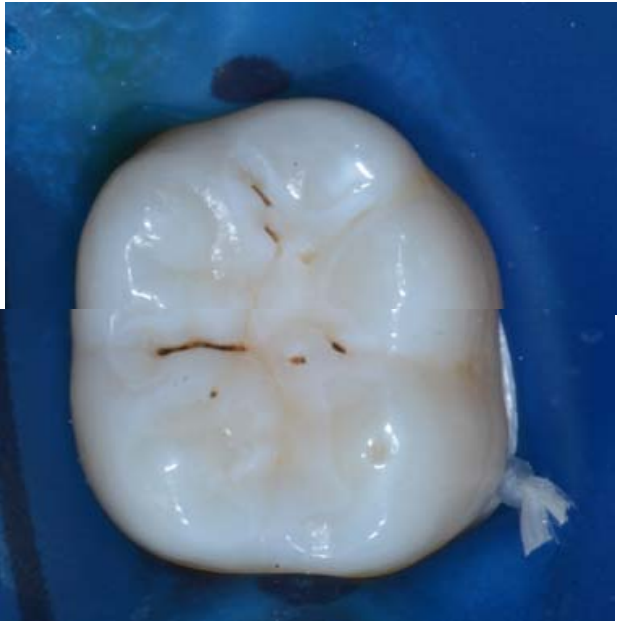

Figure 7: Surface drying

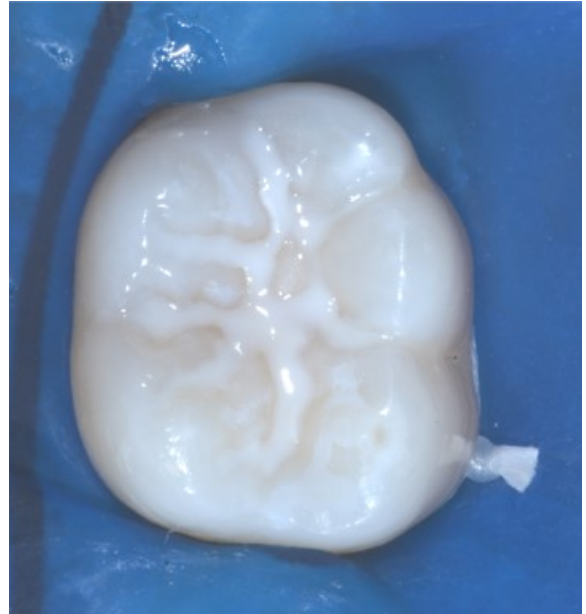


Figure 9: Clinical image after treatment

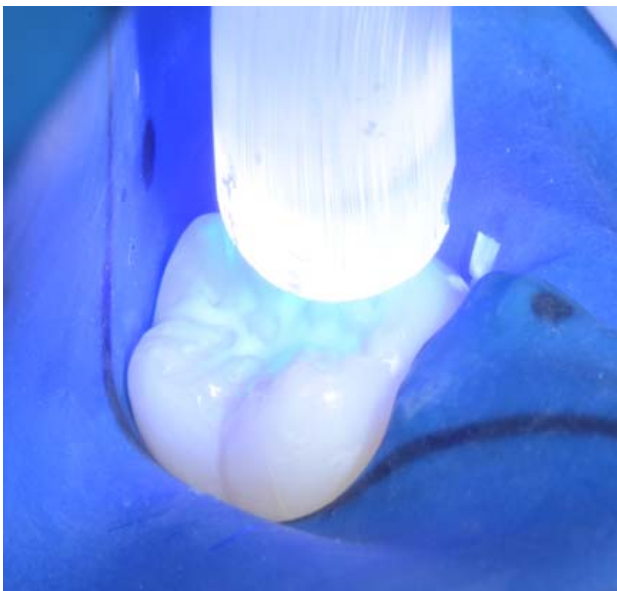


Figure 8: Light curing

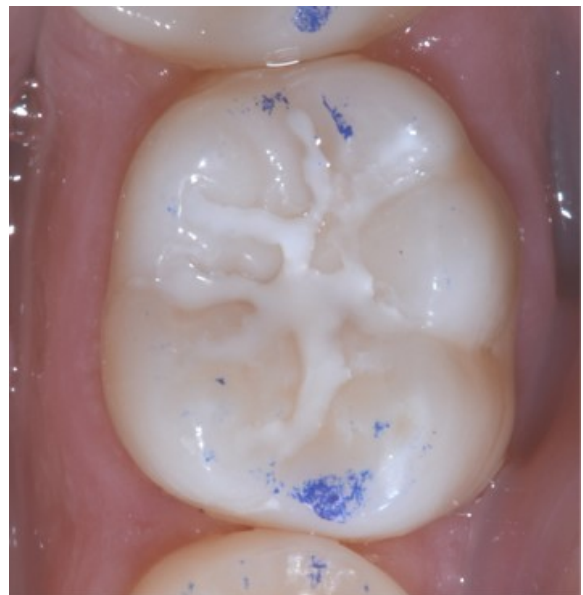


Figure 10: Occlusal control

Discussion

An air polisher provides an alternative method of removing supra-gingival extrinsic stains and deposits from the teeth [11]. Air polishing, has been shown to remove plaque more efficiently than hand instruments and to clean pits and fissures better and easier than synthetic brushes, ensuring thorough plaque biofilm and debris removal, prior to placement of sealants [7] [11] [12]. The air polisher uses an hand piece to generate a slurry of pressurized air, abrasive powder and water to remove plaque biofilm and stains [11]. Previously, sodium bicarbonate based powders (NaHCO₃) were utilized [11]; recently developed powders contain calcium sodium phosphosilicate, calcium carbonate, aluminum trihydroxide and glycine. These powders are less abrasive than traditional sodium bicarbonate based powders.

Furthermore, glycine is a water-soluble naturally occurring aminoacid, with non-salty taste [13]. Glycine powder produces significantly less surface damage on restorative materials than NaHCO₃ powder [14]. Moreover, surface cleaning with an air-polishing unit creates an increase in sealant resin depth penetration [15].

The Vista Cam iX Proof intraoral self-calibrating fluorescence camera (Durr Dental, Bietigheim-Bissingen, Germany) is a novel dental optical instrument and diagnostic tool for quantitative assessment of demineralization allowing early detection of carious lesions [9].

VistaCam iX Proof pre and post cleaning surface images provide a comprehensive dental plaque assessment with better objectivity. Quantitative surface fluorescence measurement before the cleansing phase can be biased by biofilm, providing altered values ascribed to initial caries.

The measurement after cleansing has effectively substantiated the capability to measure the actual demineralization on the tooth surface after air-polishing. Indeed, in the reported case the post-polishing measured value is 1.3, which is just the threshold value beyond which the preventive [not operative] sealing is not recommended in literature.

The glycine powder air-polishing avoids false-negative VistaCam iX Proof diagnostic outcome in pit and fissures demineralization assessment. Air-polishing prevents possible misunderstanding of the VistaCam iX Proof numerical data when plaque on pit and fissures is present.

Whereas VistaCam iX Proof, reporting and substantiating biofilm removal from the surface, allowed optimizing the following procedures of diagnosis, conditioning and sealant application.

Conclusions

Traditionally, sealants effectiveness was evaluated by retention on tooth surface. Intact sealants protect pits and fissures from caries lesions. The use of an air-polishing unit as a standard cleansing method before sealing, should be recommended. Air-polishing rapidly removes tooth stains and plaque and conditions better tooth surface, causing less invoked hypersensitivity, and less operator fatigue, improving sealant resin penetration depth. Since sealant success depends on meticulous operator technique, glycine air-polishing unit (COMBI air polishing, Mectron S.p.a.) and fluorescence camera (VistaCam iX, Durr Dental) usage should standardize the assessment of the fissure cleaning for better caries diagnosis. The results encourage technological aided clinical procedures in enhancing sealant efficacy for pit and fissures primary and secondary caries prevention. Further clinical research is needed to validate our preliminary outcomes.

References

1. Ministero della salute. Linee guida nazionali per la promozione della salute orale e la prevenzione delle patologie orali in età evolutiva. AGGIORNAMENTO NOVEMBRE 2013.
2. Tellez M, Gray S, Gray S, Lim S, Ismail A. Sealants and dental caries: dentists' perspectives on evidence-based recommendations.. *J Am Dent Assoc.* 2011; 142(9):1033- 40.
3. Hiiri A, Ahovuo-Saloranta A, Nordblad A, Mäkelä M. Pit and fissure sealants versus fluoride varnishes for preventing dental decay in children and adolescents.. *Cochrane Database Syst Rv.* 2010 Mar 17; (3):CD003067. Pub 3.
4. Gooch B, Griffin S, Gray S, Khon W, Rozier R, Siegal M, et al. Preventing dental caries through school-based sealant programs updated recommendations and reviews of evidence.. *J Am Dent Assoc.* 2009; 140(11): 1356-65.
5. Evans R, Dennison P. The Caries Management System: an evidence-based preventive strategy for dental practitioners. Application for children and adolescents. *Aust Dent J.* 2009; 54(4):381-9.
6. Locker D, Jokovic A, Kay E. Prevention. Part 8. The use of pit and fissure sealants in preventing caries in the permanent dentition of children.. *Br Dent J.* 2003; 195:375–8.
7. Botti R, Bossù M, Zallocco N, Vestri A, Polimeni A. Effectiveness of plaque indicators and air polishing for the sealing of pits and fissures.

- Eur J Paediatr Dent. 2010; 11[1]:15–18.
8. Sawai M, Bhardwaj A, Jafri Z, Sultan N, Daing A. Tooth polishing: The current status. *Journal of Indian Society of Periodontology*. 2015 Jul-Aug ; 19(4): 375–380.
 9. Guerra F, Mazur M, Rinaldo F, Corridore D, Salvi D, Pasqualotto D, et al. New diagnostic technology and hidden pits and fissures caries. *Senses Sci*. 2015; 2 (1):20–23.
 10. Patil S, Rakhewar PS, Limaye PS, Chaud NP. A comparative evaluation of plaque-removing efficacy of air polishing and rubbercup, bristle brush with paste polishing on oral hygiene status: A clinical study. *J Int Soc Prev Community Dent*. 2015 NovDec; 5(6): 457–462.
 11. Graumann S, Sensat M, Stoltenberg J. Air polishing: a review of current literature. *J Dent Hyg*. 2013 Aug; 87(4):173-80.
 12. Petersilka G, Steinmann D, Häberlein I, Heinecke A, Flemmig T. Subgingival plaque removal in buccal and lingual sites using a novel low abrasive air-polishing powder. *J Clin Periodontol*.. 2003 ; 30(4):328–333.
 13. Petersilka G. Subgingival air-polishing in the treatment of periodontal biofilm infections.. *Periodontol* 2000. 2011; 55(1):124–142.
 14. Pelka M, Trautmann S, Petschelt A, Lohbauer U. Influence of air-polishing devices and abrasives on root dentin—An in vitro confocal laser scanning microscope study.. *Quintessence Int*. 2010; 41(7):141–148.
 15. Simonsen RJ. Pit and fissure sealant: review of the literature. *Pediatric dentistry*. 2002; 24.5: 393–414.
 16. Batchelor P, Sheiham A. Grouping of tooth surfaces by susceptibility to caries: a study in 5-16 year-old children.. *BMC Oral Health*. 2004; 4(1):2.
 17. Brown L, Selwitz R. The impact of recent changes in the epidemiology of dental caries on guidelines for the use of dental sealants.. *Journal of Public Health Dentistry*. 1995; 55 (5 Spec No):274–91.
 18. McDonald S, Sheiham A. The distribution of caries on different tooth surfaces at varying levels of caries - a compilation of data from 18 previous studies.. *Community Dental Health*. 1992; 9(1):39–48.
 19. Beauchamp J, Caufield P, Crall J, Donly K, Feigal R, Gooch B, et al. Evidence-based clinical recommendations for the use of pit-and-fissure sealants: a report of the American Dental Association Council on Scientific Affairs.. *J Am Dent Assoc*. 2008; 139(3):257- 68.
 20. Muller-Bolla M, Lupi-Pégurier L, Tardieu C, Velly A, Antomarchi C. Retention of resin-based pit and fissure sealants: A systematic review.. *Community Dent Oral Epidemiol*.. 2006 Oct; 34(5):321-36.
 21. Mejare I LPPLHATSKCea. Caries-preventive effect of fissure sealants: a systematic review. *Acta Odontol Scand*. 2003; 61:321–30.
 22. Ahovuo-Saloranta A, Hiiri A, Nordblad A, Worthington H, Makela M. Pit and fissure sealants for preventing dental decay in the permanent teeth of children and adolescents [Cochrane review]. In John Wiley & Sons L. *The Cochrane Library*. Issue 3. Chichester, UK.; 2004.