


# Poland Syndrome with Atypical Malformations Associated to a *de novo* 1.5 Mb Xp22.31 Duplication

Carmela R. Massimino<sup>1</sup> Pierluigi Smilari<sup>1</sup> Filippo Greco<sup>1</sup> Silvia Marino<sup>2</sup> Davide Vecchio<sup>3</sup>  
 Andrea Bartuli<sup>3</sup> Pasquale Parisi<sup>4</sup> Sung Y. Cho<sup>5</sup> Piero Pavone<sup>1,5</sup> 

<sup>1</sup> Department of Clinical and Experimental Medicine, Section of Pediatrics and Child Neuropsychiatry, University of Catania, Catania, CT, Italy

<sup>2</sup> University-Hospital "Policlinico-Vittorio Emanuele," University of Catania, Catania, CT, Italy

<sup>3</sup> Rare Disease and Medical Genetics, Academic Department of Pediatrics, Bambino Gesù Children's Hospital, Rome, Italy

<sup>4</sup> Child Neurology, Chair of Pediatrics, NESMOS Department, Faculty of Medicine & Psychology, Sapienza University, c/o Sant' Andrea Hospital, Rome, Italy

<sup>5</sup> Department of Pediatrics, Samsung Medical Center, Sungkyunkwan University School of Medicine, Seoul, Republic of Korea

**Address for correspondence** Piero Pavone, MD, PhD, Department of Pediatrics, AOU Policlinico-Vittorio Emanuele, University of Catania, Via S. Sofia 78, 95123 Catania, CT, Italy (e-mail: ppavone@unict.it).

Neuropediatrics

## Abstract

Poland's syndrome (PS; OMIM 173800) is a rare congenital syndrome which consists of absence or hypoplasia of the pectoralis muscle. Other features can be variably associated, including rib defects. On the affected side other features (such as of breast and nipple anomalies, lack of subcutaneous tissue and skin annexes, hand anomalies, visceral, and vertebral malformation) have been variably documented. To date, association of PS with central nervous system malformation has been rarely reported remaining poorly understood and characterized. We report a left-sided PS patient carrying a *de novo* 1.5 Mb Xp22.31 duplication diagnosed in addition to strabismus, optic nerves and chiasm hypoplasia, corpus callosum abnormalities, ectopic neurohypophysis, pyelic ectasia, and neurodevelopmental delay. Since, to our knowledge, this features' association has not been previously reported, we argue that this case may contribute to further widening of the variability of PS phenotype.

## Keywords

- ▶ Poland's syndrome
- ▶ hypoplastic optic nerve
- ▶ CNS involvement

## Introduction

The incidence of PS has been evaluated in approximately 1:32,000 by Frère-Maia et al<sup>1</sup> and by McGillivray and Lowry.<sup>2</sup> The condition is usually sporadic but a familial recurrence with different inheritance patterns has been also observed.<sup>3</sup> PS affects mostly males than females, occurs on right side around 55 to 61% of cases,<sup>4,5</sup> and has been variably reported with several associated anomalies and comorbidities.<sup>3</sup> The PS etio-pathogenesis is still unknown. The prevailing theory is an interruption of the embryonic blood supply of the subclavian arteries during a critical period of the embryonic development at about the 5 to 6 weeks of gestation<sup>6</sup>. Hence, it is thought that its range of features can be determined due to the blood supply

level disruption. However, genes which regulate the embryonic development of pectoral girdle may also be involved in this disorder<sup>7</sup>. PS has been also described in association to several other features and conditions, such as dextrocardia,<sup>8</sup> Möebius's syndrome, vertebral abnormalities, and undescended testes. Extracorporeal intercostal liver herniation and thoracic myelomeningocele, renal agenesis, and megacalycosis of the ipsilateral kidney has been reported.<sup>9-12</sup> Conditions, such as malignancies<sup>11,12</sup> and other rare disorders, may be found to be associated to PS but these events are usually considered as not directly correlated.

We describe a left-sided PS patient carrying a *de novo* 1.5 Mb Xp22.31 duplication retrieved in addition to a complex

received

May 11, 2019

accepted after revision

August 18, 2019

© Georg Thieme Verlag KG  
 Stuttgart · New York

DOI <https://doi.org/10.1055/s-0039-3402009>  
 ISSN 0174-304X.

central nervous system (CNS) malformation, neurodevelopmental delay, and several other first reported features. Since this atypical clinical picture has not been previously described, we defined the presented clinical frame as a further contribution in widening variability of the PS phenotype.

## Case Report

The proband is a 10-year-old male, second by birth order, born by a Caesarean section from nonconsanguineous healthy parents after an uneventful pregnancy in which a positive serology for *Toxoplasma gondii* was detected in the last trimester. Birth weight was 3,300 g. On the physical examination he showed double hair whorl, poliosis circumscripta/segmented heterochromia of scalp hair in the right parietooccipital region, convergent squint of the right eye, an hypoplastic left pectoral region, mild scoliosis, syndactyly of the II and III toes on the left foot, and bilateral flat foot (►Fig. 1). Growth parameters were normal; weight, 28.200 kg (25–50° pc); height, 135 cm (25–50° pc); occipitofrontal circumference (OFC) 51.3 cm (10° pc). Over the time the child was also diagnosed with hyperopic astigmatism, language delay, and intellectual disability.

## Investigations

Ultrasound of the pectoral muscles showed a reduction in the thickness of the muscles. The eye examination showed convergent squint of the right eye; funduscopy revealed bilateral temporal pallor of the optic disc. He was subjected to a phoniatric counseling that prescribed speech therapy and to an audiological evaluation which was normal. Blood tests revealed an Ig (immunoglobulin) A deficiency, metabolic tests (ammonium, lactate, phenylalanine, and congenital disorders of glycosylation [CDG]) resulted within the normal range. His magnetic resonance imaging (MRI) brain

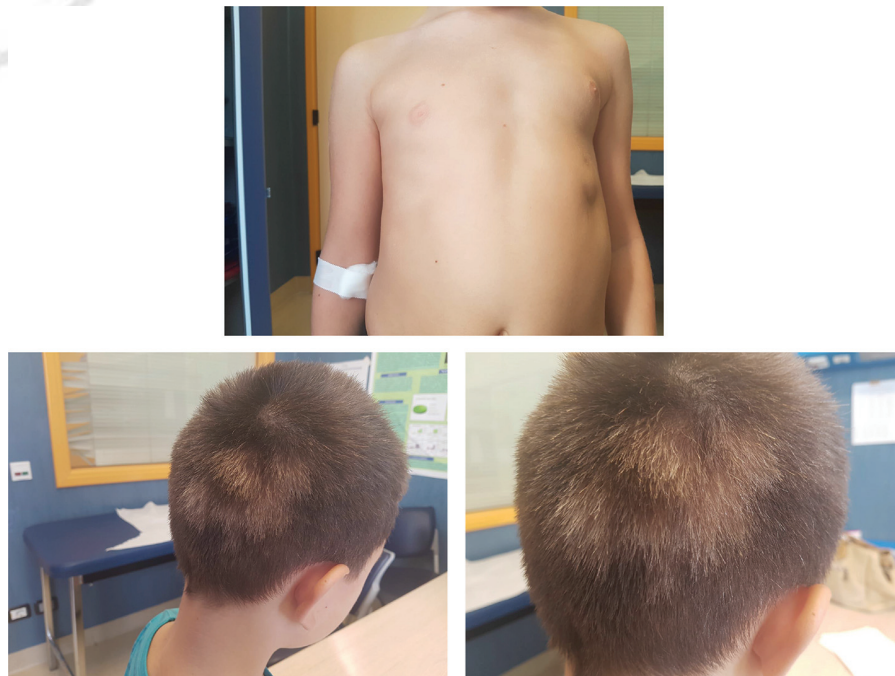scan showed a reduced caliber of the optic nerves and chiasm associated to palpebral and periorbital edematous tissues on the right; uniformly thinned corpus callosum with dysplasia of the splenium, and ectopia of the posterior lobe of the pituitary gland was also detected. Abdominal ultrasound revealed ectasia of the left renal pelvis (10 mm) plus an ipsilateral accessory inferior pole renal artery. Dynamic renal scintigraphy highlighted a low-grade hydronephrosis with decreased excretory function in the dilated left kidney and increasing pelvic dilatation. By quantitative PCR assay of toxoplasma and cytomegalovirus (CMV) on Guthrie's card of his neonatal screening, it was possible to exclude a related infectious disease caused by the two pathogens.

## Genetic Testing

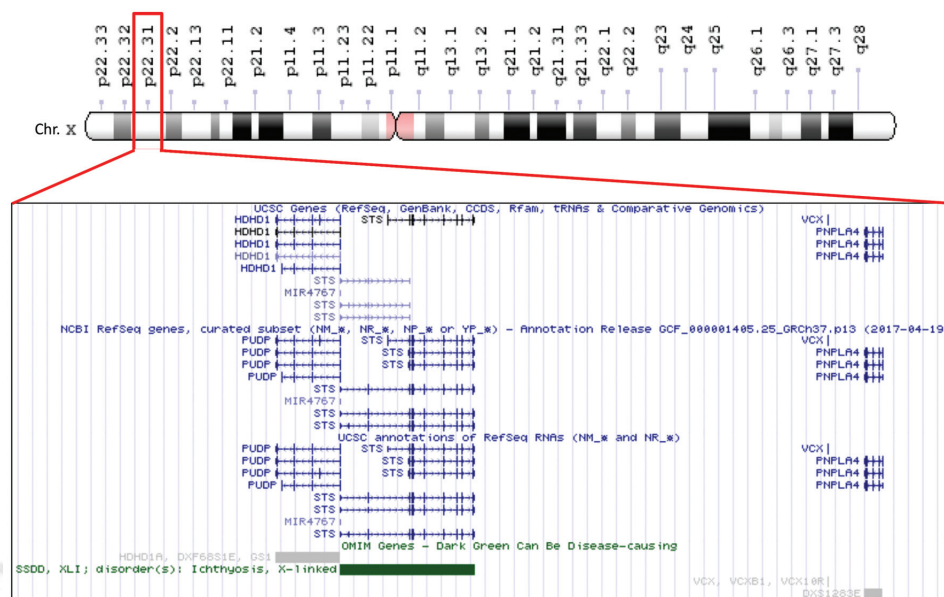
DNAs of the proband and parents were extracted with Puregene DNA Isolation Kit (Gentra System, Minneapolis, Minnesota, United States) according to the manufacturer's instruction. CGH-array analysis was performed by using CytoSure ISCA 8 × 60K v.2 (OGT) with a resolution of 50 to 100 Kb according to the manufacturer's instructions. Array slides were analyzed through the CytoSure Analysis Software; the quality score (DLRS) was <0.25. Results show genome-wide array analysis of the proband and parents showed a patient's de novo 1.5 Mb duplication at the Xp22.31 subband, ranging from 6.552.712 to 8.097.511 (GRCh37, May 2009) which harbors the following The University of California Santa Cruz (UCSC) genes: *HDHD1A*, *STS*, *PUDP*, *PNPLA4*, *VCX*, and the microRNA *MIR4767* (►Fig. 2).

## Discussion

The child here reported exhibited in association with some typical features of PS, a complex set of scalp hair, ocular,



**Fig. 1** Our proband's main features of double hair whorl, poliosis circumscripta/segmented heterochromia of hair, convergent squint of the right eye, and hypoplastic left pectoral region.



**Fig. 2** ideogrammatic representation of the human Xp22.31 region and those loci harbored within (*HDHD1A*, *STS*, *PUDP*, *PNPLA4*, and *VCX*).

cerebral, and renal anomalies. Renal anomalies consisted of low-grade hydronephrosis, with decreased excretory function in the dilated left kidney and accessory renal arteries in the inferior pole of the left kidney. A rare association of PS, hand and genitourinary anomalies (renal agenesis, duplex collecting system, ureteropelvic junction obstruction, hypospadias, and undescended testicles) was previously described as acropectorrenal field defect.<sup>13</sup> Moreover, Briner and Thiel described a patient with a right-sided PS and megacalycoses of the ipsilateral kidney,<sup>11</sup> and Assadi and Salem described a 7-month-old patient with PS and renal agenesis.<sup>10</sup> Anomalies of the renal system have been reported to occur in approximately 11% of cases with PS and upper limb involvement.<sup>5</sup> Thus, in patients with PS, it is recommended to perform diagnostic imaging procedures, such as ultrasonography, to exclude renal involvement.

Our patient shows a rearrangement in the Xp22.31 region that, to our knowledge, has never been associated to PS. Individuals carrying Xp22.31 rearrangements have been reported in the literature in approximately 0.4% of cases with developmental delay/intellectual disability (DD/ID) but also in approximately 0.15% of controls or proband's unaffected parents and in approximately 0.4% of cases.<sup>14</sup> Our research group published a case report of a child affected by microcephaly, autism spectrum disorder, and intellectual disability, in which a Xp22.31 duplication was also detected.<sup>15</sup> The most frequently reported neurological involvement in patients carrying Xp22.31 rearrangements consists of autism spectrum disorder (ASD) and DD/ID. In this view, three large cohorts of patients with Xp22.31 duplication have been reported in this decade. Li et al<sup>16</sup> described 35 individuals including 12 patients from the literature where DD/ID was reported in 24, ASD in 9, hypotonia in 7, and seizures in 4 patients, respectively. Liu et al<sup>17</sup> reported on 14 individuals with this segmental aneuploidy where eight manifested with DD/ID, seven with ASD, four with hypotonia, and two with epileptic seizures. Other

features from that study included five patients presenting with an abnormal head circumference (four with macrocephaly and one with microcephaly). Esplin et al<sup>14</sup> described nine patients, DD/ID and seizures were observed in all patients, talipes in three, and ASD and hypotonia were seen in two patients. Finally, a single report from Faletra et al<sup>18</sup> described a patient with dysmorphic features and neurological involvement including DD/ID, talipes, and hypotonia. The phenotype expression in affected duplication carriers is variable; the clinical and severe manifestations exhibited by affected individuals have been hypothesized to be linked to a second deleterious genetic mutation<sup>19</sup> or a concomitant presence of different genetic variants expression.

Moreover, although optic disc anomalies can be retrieved in PS (since they have been reported at least in a patient with coloboma of the optic disc/morning glory syndrome,<sup>20,21</sup> and in another case of optic dysplasia/papillorenal syndrome,<sup>22</sup> the proband brain MRI showed severe hypoplasia of optic nerves and chiasm. In patients with optic nerve hypoplasia (ONH), neuroimaging also shows abnormalities in ventricles or white- or gray-matter development, septooptic dysplasia, hydrocephalus, and corpus callosum abnormalities.<sup>23–25</sup> This last feature was also documented in our patient in addition to a posterior lobe of the pituitary gland ectopia. Indeed, it has been described that incidence of neurologic abnormalities is greater in patients with bilateral optic nerve hypoplasia (65%) than patients with unilateral ONH.<sup>23</sup> Moreover, ONH occurs in less than 10% of children with corpus callosum hypoplasia, while a pituitary dysfunction is uncommon in children with corpus callosum hypoplasia and no optic nerve hypoplasia.<sup>23</sup> In a patient who presents pectoral muscles hypoplasia, it is necessary to exclude the involvement of other organs with careful clinical examination and targeted diagnostic investigations. On the other hand, a patient with evidence of optic nerve hypoplasia should be assessed for presence of neurologic, radiologic, and endocrine associations.



In this view, it is worthy of mention that in 1990 Larizza and Maghnie reported a 9-year-old boy with Poland's syndrome and anatomical abnormalities of the pituitary gland (hypoplasia of both sella and anterior lobe of the pituitary gland with absence of the pituitary stalk and ectopia of the posterior lobe) associated with growth hormone deficiency.<sup>26</sup> In our case, MRI brain showed ectopia of the posterior lobe of the pituitary gland. The anterior lobe and the stalk of the pituitary gland appeared normal, and the child auxological parameters were retrieved within the normal range, without deficiency of growth hormone (GH).

PS abnormalities can be associated to another clinical entity, the Möbius syndrome, which is characterized by unilateral or bilateral congenital facial nerve paralysis with impairment of ocular abduction frequently associated with limb anomalies.<sup>27</sup> However, the cranial nerve examination in our patient did not find any facial nerve dysfunction.

The clinical manifestations presented by this boy share some phenotype features (i.e., DD/ID, hair anomalies, corpus callosum abnormalities, and others) with patients affected by FG syndrome in which a similar gene localization at Xp22.3 has been reported by Dessay et al.<sup>28</sup> The FG syndrome (OMIM 305450) is an X-linked disorder presenting with DD/ID, congenital hypotonia, constipation, or anal malformations, and a distinctive appearance with macrocephaly, tall and broad forehead, cowlicks, and telecanthus in which a gene localization at Xp22.3 (FGS3) has been reported.<sup>29</sup> In this syndrome, brain MRI may show corpus callosum abnormalities with dilatation of lateral ventricles and, less frequently, periventricular nodular heterotopias, mild cerebellar defects, and reduced periventricular white matter with the Chiari-1 malformation.<sup>29</sup> It is difficult to establish a clear correlation between the clinical expressions presented by the boy and those reported in FG syndromes, since both the disorders displayed a wide variable phenotype. Clinical and genetic relationship between PS and FG needs to be confirmed by further observations, as it may hypothesized that the two syndromes may share same genetic components or the region encompassed by the duplication have a partial role in both FG and PS phenotypes.

As reported by Vaccari et al<sup>30</sup> duplication/deletion of genomic regions can be rarely associated to PS. On the other hand, Tassano et al<sup>31</sup> report a clinical experience of a patient with PS and DD/ID in which a chromosome 6q21q22.1 deletion was found. In our case, the clinical presentation involving not only the hypoplasia of the pectoralis muscle but a complex set of manifestations lead us to hypothesize that various events aside the duplication may have played a relevant pathogenic role. The common, yet nonspecific, clinical modalities of presentation in individuals with Xp22.31 duplication might be explained by variable expressivity, decreased penetrance, and skewed X-inactivation in female.<sup>15,18</sup> All of these hypotheses need to be further confirmed. Additionally, the duplication might act not directly but rather predispose the patients to the action of other factors that cause the clinical features.<sup>15</sup> The region duplicated in our patient at the Xp22.31 subband encompasses the following loci: PUDP, PNPLA4, VCX, and the microRNA MIR4767 whose protein

biological functions are poorly understood, and have not yet been linked to the human nosology, plus the steroid sulfatase (STS) gene encoding for a STS which serves for a membrane-bound microsomal enzyme that hydrolyzes several 3- $\beta$ -hydroxysteroid sulfates serving as metabolic precursors for estrogens, androgens, and cholesterol. To date, only the last one was annotated in OMIM (308100) as responsible for an X-linked ichthyosis form.<sup>14,18</sup> Thus, the present report provides further knowledge on the potentially pathogenetic role of the Xp22.31 duplication and extends the clinical features previously described in PS cohort with an impressive coexistence of features (i.e., renal, optic, and neurological) which were almost formerly individually reported. Although the pathogenic role of this copy number variant rests unclear, its genomic modifier effect as a determining factor appears highly suggestive. In this view, it is therefore possible to hypothesize a multifactorial causative role in which a dosage-sensitive effect of one or more of those genes harbored within, could synergistically contribute to the composite phenotype retrieved, as well as to its variable clinical expressivity.

Since, to our knowledge, the features presented by the child in its complex has not been previously reported, we argue that this report may be worthy in extending the knowledge of the Poland syndrome and its variable clinical expression.

#### Funding

No funding was utilized for this study.

#### Conflicts of Interest

The authors declare no conflict of interest.

#### Acknowledgments

We wish to thank Dr. Rosemary Ready (University of Catania, Italy) for editing the final draft of the manuscript.

#### References

- Freire-Maia N, Chautard EA, Opitz JM, Freire-Maia A, Quelce-Salgado A. The Poland syndrome-clinical and genealogical data, dermatoglyphic analysis, and incidence. *Hum Hered* 1973;23(02):97-104
- McGillivray BC, Lowry RB. Poland syndrome in British Columbia: incidence and reproductive experience of affected persons. *Am J Med Genet* 1977;1(01):65-74
- Yiyit N, Işitmangil T, Öksüz S. Clinical analysis of 113 patients with Poland syndrome. *Ann Thorac Surg* 2015;99(03):999-1004
- Yiyit N. Definition of the inclusion criteria of Poland's syndrome. *Ann Thorac Surg* 2014;98(05):1886
- Romanini MV, Calevo MG, Puliti A, et al. Poland syndrome: a proposed classification system and perspectives on diagnosis and treatment. *Semin Pediatr Surg* 2018;27(03):189-199
- Poullin P, Toussirot E, Schiano A, Serratrice G. [Complete and dissociated forms of Poland's syndrome (5 cases)]. *Rev Rhum Mal Osteoartic* 1992;59(02):114-120
- Valasek P, Theis S, DeLaurier A, et al. Cellular and molecular investigations into the development of the pectoral girdle. *Dev Biol* 2011;357(01):108-116
- Torre M, Baban A, Buluggiu A, et al. Dextrocardia in patients with Poland syndrome: phenotypic characterization provides insight

- into the pathogenesis. *J Thorac Cardiovasc Surg* 2010;139(05):1177–1182
- 9 Prati R, Vandelli C, Prosdocimo M, Piacentini F. [Poland syndrome associated with Moebius syndrome]. *Pediatr Med Chir* 1985;7(06):901–903
  - 10 Assadi FK, Salem M. Poland syndrome associated with renal agenesis. *Pediatr Nephrol* 2002;17(04):269–271
  - 11 Briner V, Thiel G. [Hereditary Poland syndrome with megacalycosis of the right kidney]. *Schweiz Med Wochenschr* 1988;118(23):898–903
  - 12 Kurt Y, Demirbas S, Uluutku AH, Akin ML, Çelenk T. Poland's syndrome and gastric cancer: report of a case. *Eur J Cancer Prev* 2006;15(06):480–482
  - 13 Hegde HR, Leung AK, Robson WL. Acro-pectoro-renal field defect with contralateral ureteropelvic junction obstruction. *Clin Genet* 1995;47(04):210–213
  - 14 Esplin ED, Li B, Slavotinek A, et al. Nine patients with Xp22.31 microduplication, cognitive deficits, seizures, and talipes anomalies. *Am J Med Genet A* 2014;164A(08):2097–2103
  - 15 Pavone P, Corsello G, Marino S, Ruggieri M, Falsaperla R. Microcephaly/trigonocephaly, intellectual disability, autism spectrum disorder, and atypical dysmorphic features in a boy with Xp22.31 duplication. *Mol Syndromol* 2019;9(05):253–258
  - 16 Li F, Shen Y, Köhler U, et al. Interstitial microduplication of Xp22.31: Causative of intellectual disability or benign copy number variant? *Eur J Med Genet* 2010;53(02):93–99
  - 17 Liu P, Erez A, Nagamani SCS, et al. Copy number gain at Xp22.31 includes complex duplication rearrangements and recurrent triplications. *Hum Mol Genet* 2011;20(10):1975–1988
  - 18 Faletra F, D'Adamo AP, Santa Rocca M, et al. Does the 1.5 Mb microduplication in chromosome band Xp22.31 have a pathogenic role? New contribution and a review of the literature. *Am J Med Genet A* 2012;158A(02):461–464
  - 19 Qiao Y, Bagheri H, Tang F, et al. Exome sequencing identified a de novo mutation of PURA gene in a patient with familial Xp22.31 microduplication. *Eur J Med Genet* 2019;62(02):103–108
  - 20 Maxfield SD, Strominger MB. Optic disc dysplasia in Poland syndrome. *Ophthalmic Genet* 2014;35(02):117–118
  - 21 Pisteljić DT, Vranjesević D, Apostolski S, Pisteljić DD. Poland syndrome associated with 'morning glory' syndrome (coloboma of the optic disc). *J Med Genet* 1986;23(04):364–366
  - 22 Khan AO, Nowilaty SR. Early diagnosis of the papillorenal syndrome by optic disc morphology. *J Neuroophthalmol* 2005;25(03):209–211
  - 23 Garcia-Filion P, Borchert M. Optic nerve hypoplasia syndrome: a review of the epidemiology and clinical associations. *Curr Treat Options Neurol* 2013;15(01):78–89
  - 24 Chen CA, Yin J, Lewis RA, Schaaf CP. Genetic causes of optic nerve hypoplasia. *J Med Genet* 2017;54(07):441–449
  - 25 Hozjan I. Optic nerve hypoplasia: more than meets the eye. *J Pediatr Nurs* 2017;34:98–100
  - 26 Larizza D, Maghnie M. Poland's syndrome associated with growth hormone deficiency. *J Med Genet* 1990;27(01):53–55
  - 27 De Stefani E, Ardizzi M, Nicolini Y, et al. Children with facial paralysis due to Moebius syndrome exhibit reduced autonomic modulation during emotion processing. *J Neurodev Disord* 2019;11(01):12
  - 28 Dessay S, Moizard MP, Gilardi JL, et al. FG syndrome: linkage analysis in two families supporting a new gene localization at Xp22.3 [FGS3]. [FGS3] *Am J Med Genet* 2002;112(01):6–11
  - 29 Battaglia A, Chines C, Carey JC. The FG syndrome: report of a large Italian series. *Am J Med Genet A* 2006;140(19):2075–2079
  - 30 Vaccari CM, Tassano E, Torre M, et al. Assessment of copy number variations in 120 patients with Poland syndrome. *BMC Med Genet* 2016;17(01):89
  - 31 Tassano E, Mirabelli-Badenier M, Veneselli E, et al. Clinical and molecular characterization of a patient with interstitial 6q21q22.1 deletion. *Mol Cytogenet* 2015;8:31