

LETTER TO THE EDITOR

THE CASE OF AN OSTEOCHONDROMA IN A SKELETON FROM THE SEVENTEEN CENTURY
CRYPT OF NORTHERN LOMBARDY

LUCA NICOSIA¹, MARTA LICATA², GIUSEPPE ARMOCIDA², IGNAZIO VECCHIO³, SILVIA IORIO⁴, CHIARA ROSSETTI⁵

¹Milan University, Postgraduation School in Radiodiagnostics, Milano, Italy - ²Insubria University, Department of Biotechnology and Life Sciences, Varese, Italy - ³Department of Medical and Pediatric Sciences, University of Catania - ⁴Sapienza University of Rome, Department of Molecular Medicine, Unit of History of Medicine, Roma, Italy - ⁵Brescia University, Department of Medical and Surgical Specialities, Radiological sciences and Public Health, Spedali Civili, Brescia, Italy

Received April 30, 2016; Accepted July 02, 2016

Dear Editor,

In November 2013, the University of Insubria, in agreement with the Lombardy's Archaeological Heritage Department, investigated the burial crypt of the Convent Church in Azzio, which was built in 1608. The crypt holds sixteen tombs reserved exclusively to the members of the Franciscan order and includes a common ossuary with bones that belonged to the friars.

The skeleton was found in a correct anatomical position inside the common ossuary. It was examined in order to determine the age at the time of death, gender, and height. The age at the time of death was defined by the analysis of samples taken from variations to the pubic symphysis, the facies auricularis of the pelvic bones, the degree of the suture closure and external rib modification⁽¹⁾.

The gender analysis was carried out by using standard pelvic and cranial morphological indicators (following the methods given by Buikstra & Ubelaker). The intra vitam body stature was calculated as the mean of the different values obtained by several commonly used methods based on measurement of the femur length. The dating was carried out by extracting carbon from the raw sample through physical and chemical processing. The carbon was analyzed by mass spectrometry with accelerator in order to evaluate the relations of $^{14}\text{C}/^{12}\text{C}$ and $^{13}\text{C}/^{12}\text{C}$.

The identification analysis revealed that the skeleton belonged to a male who died when he was about 55 years old. The height of the subject was estimated to be 185 cm. The dating of the skeleton

can be placed between 1850 and 1950. Radiological investigation shows a formation (diameter of 20 mm thickness at the edge) of a clearly thickened and sclerotic osteolytic area of 10 mm, which raises the cortical bone without any erosion the left iliac (Fig. 3).

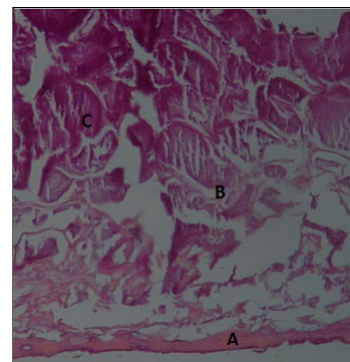


Fig. 3: Histological findings: A: compact bone; B: endochondral ossification; C: calcification. The poor quality of the image reveals the deterioration of the bone caused by the time. However, we can see the presence of the three different layers compatible with osteochondroma (EE x 200).

The osteolytic intracortical area concerns almost the entire section of the bone. More specifically, we analyzed the left iliac, which showed a loss of substance with a diameter of 0,7cm (Fig. 1).

To the CT examinations, the skeleton was analyzed with conventional medical radiological equipment (16-layer X-ray, Eclon 16, Hitachi Medical Systems). Imaging parameters were as follows: 120 kV, 175 mA. The slice thickness used was 1.25 mm.

The bone section in correspondence to the lesion (Fig. 2) was histologically examined. Macroscopically, the piece of bone showed a dense

and whitish area. The section was then decalcified and the slides were prepared with hematoxylin and eosin staining.



Fig. 1: Left hip bone: about 2 cm below the iliac crest on the left ilium, a wound/lesion with a diameter of 2 cm.

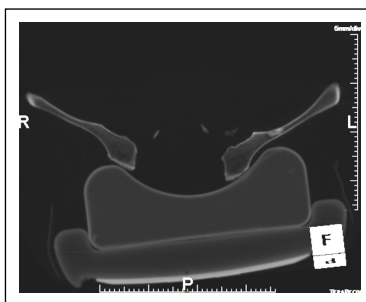


Fig. 2: CT image of the iliac bones that shows the irregularly hyperdense oval area with irregular margins, thick and thickened, of about 20mm, localized at the level of the proximal third of the left iliac wing, in the context of which, in the most medial part is appreciable initial lytic component.

The osteolysis has rounded and well-defined edges. It contains thin calcifications that appear of granular opacity and affect cortical diaphyseal without interruption. CT imaging highlights the lytic area in well-defined margins, bordered by a thin, sclerotic, centric and rounded relief. The relief proving that the lesion is an osteochondroma.

The histological analysis showed a poorly preserved image, due to bone degradation over the time. However, it is possible to distinguish a layer of compact bone. It is a layer of endochondral ossification in addition to a layer of calcification. In other older lesions, the cartilaginous tissue may disappear and could be substituted by noteworthy calcification.

The histological findings, albeit affected by the sample degradation, do not exclude the diagnosis of long-term osteochondroma. Therefore, the osteochondroma is compatible with a tumor in an older person.

Osteochondroma is a benign lesion, small and slow growing. It consists of growth hyaline cartilage.

This condition is defined as a developmental exostosis rather than a neoplasm. Osteochondroma represents about 10% of the primary bone tumors without gender predilection and generally it appears between the age of 10 and 50⁽²⁾.

In paleopathology, according to the data reported in the available literature, osteochondroma represent approximately 40-50% of all benign tumors, among the most common types of bone tumors⁽³⁾.

The most common bone affected by osteochondroma is the femur (30-40%) followed by the tibia with an incidence of 15 to 20%. Osteochondromas affect only 5% of the time in the pelvis and arise most frequently at the iliac crest⁽⁴⁾.

While studying tumors on ancient human remains, one must always consider that the majority of cancers are related to the age and are found in elderly.

In ancient time the average lifespan was shorter, therefore the prevalence of cancer was lower than in our day. Regarding osteochondroma, we can assume that the prevalence of cancer among ancient peoples and modern peoples overlaps, even if very few cases have been reported in literature⁽⁵⁾.

References

- 1) Licata M, Vecchio I, Armocida G. *Analysis of ante-mortem injuries in medieval skeletons from the necropolis of Caravate (Varese) Italy*. Acta Med Medit 2014; 30: 555-9.
- 2) Akansu B, Atik E, Altintas S, Kalaci A, Canda S. *Periosteal chondroma of the ischium; an unusual location*. Turkish J. Pathol 2012; 28: 172.
- 3) Buzon MR. *Two cases of pelvic osteochondroma in New Kingdom Nubia*. Int. J. Osteoarchaeol 2005; 15: 377-82.
- 4) Vyhnánek L, Strouhal E, Neřečková A. *"Kissing" osteochondroma: A case from Ancient Egypt*. Int. J. Osteoarchaeol 1999; 9:361-8.
- 5) Slaus M, Orlić D, Pečina M. *Osteochondroma in a skeleton from an 11th century Croatian cemetery*. Croat. Med. J 2000; 41: 336-40. PubMed PMID:11176078.

Acknowledgements

The authors wish to thank the Lombardy Archaeological Heritage Department for the archaeological investigations conducted inside the crypt. Thanks also go to Dr. Ugo Maspero and Luca Romano, radiologists at the Fondazione Borghi in Brebbia (VA), who performed the X-ray and CT analyses.

Corresponding author
marta.licata@uninsubria.it
(Italy)