

Use of miltefosine in a patient with mucosal leishmaniasis and HIV-coinfection: a challenge in long-term management

Giacomo Zanelli^{1,2}, Barbara Rossetti¹, Roberta Gagliardini^{1,3}, Lorenzo Paglicci^{1,2}, Giacinta Tordini^{1,2}, Clelia Miracco⁴, Sara Aversa⁴, Lorenzo Zammarchi⁵, Trentina Di Muccio⁶, Marina Gramiccia⁶, Francesca Montagnani^{1,2}

¹Hospital Department of Specialized and Internal Medicine, Infectious Diseases Unit, University Hospital of Siena, Siena, Italy;

²Department of Medical Biotechnologies, University of Siena, Italy;

³INMI L. Spallanzani IRCCS, Rome, Italy;

⁴Pathological Anatomy Division, Department of Medicine, Surgery and Neuroscience, University of Siena, Siena, Italy;

⁵Department of Experimental and Clinical Medicine, University of Florence, Florence, Italy; Infectious and Tropical Diseases Unit, Careggi University and Hospital, Florence, Italy; Referral Center for Tropical Diseases of Tuscany, Infectious and Tropical Diseases Unit, Careggi University Hospital, Florence, Italy;

⁶Department of Infectious Diseases, Unit of Vector-borne Diseases, Italian National Institute of Health, Rome, Italy

SUMMARY

The management of mucosal leishmaniasis in immunocompromised patients is not standardized and limited data are available on the use of miltefosine for treatment and secondary prophylaxis. We describe a case of mucosal leishmaniasis in an HIV-coinfected pa-

tient treated with miltefosine due to a severe allergic reaction to liposomal amphotericin B.

Keywords: mucosal leishmaniasis, HIV, miltefosine, liposomal B amphotericin, adverse reaction.

INTRODUCTION

In people infected with HIV, the clinical manifestations of leishmaniasis may be heterogeneous and not strictly species-specific [1]. The parasites can lose their typical tropism and mucosal involvement (mucosal leishmaniasis, ML) is not a rare event in the Old World, particularly in the immunocompromised patients [1]. Treatment of this co-infection is not standardized and may be complicated by a high risk of recurrence [2]. The use of liposomal amphotericin B (L-AmB) is

sometimes associated to adverse events, making alternative therapy necessary [2]. Data on the use of miltefosine for treatment and secondary prophylaxis in patients with ML and HIV-coinfection are extremely limited [2-4].

Here we describe a case of ML in a patient with HIV infection, treated with miltefosine after a severe allergic reaction to L-AmB.

CASE REPORT

A 59-year-old male Nigerian patient with mucosal leishmaniasis was referred to our hospital in June 2018. He reported uncontrolled arterial hypertension, recent thoracic herpes zoster and no other known major comorbidity. He had lived in Italy for more than 40 years and returned periodically

Corresponding author

Giacomo Zanelli

E-mail: giacomo.zanelli1971@gmail.com

to Nigeria (the last time had been two years earlier). Due to a months-long history of nasal obstruction, he underwent ENT (ear, nose and throat) assessment that revealed hyperplastic hemorrhagic vestibular mucosa with external swelling of the left nostril. The subsequent biopsy showed granulomatosis compatible with leishmaniasis (Figure 1, A and B), confirmed by the positivity to SSUrDNA nested-PCR [5]. The parasite was identified as belonging to the *Leishmania donovani* complex by ITS1-PCR-RFLP analysis performed at the Italian National Institute of Health (U.O. Vector-borne diseases, Rome, Italy) [6]. On admission the patient was in good clinical condition and physical examination only revealed an exudative and stenosing lesion in the left nasal vestibule without fibrolaryngoscopic evidence of pharyngeal or glottic lesions. Laboratory tests showed a white blood cells count (WBC) of 4,410 cells/mm³ (1,330 neutrophils), alanine aminotransferase (ALT) 80 IU/mL, and monoclonal hypergammaglobulinemia (31%). Serology was positive for HIV and HIV-1 RNA was 252,000 copies/mL (subtype G); the CD4 count was 140 cells/mm³. No major drug resistance mutation was detected. *Leishmania* real time PCR on peripheral whole blood (Stat Nat Leishmania spp, Sentinel Diagnostic, Italy) and serology (IFAT, Euroimmun, Lübeck, Germany)

were negative. No other co-infections were detected. Chest X-ray was normal; liver steatosis was detected by abdominal ultrasound. Left ventricular hypertrophy was documented by echocardiography. Magnetic resonance of the brain showed leukoaraiosis. The patient started antiretroviral therapy (ART) (tenofovir alafenamide/emtricitabine + dolutegravir) responding with a rapid decrease in HIV-1 RNA; cotrimoxazole was given for prophylaxis of opportunistic infections. To treat ML, L-AmB was administered with a scheduled dose of 4mg/Kg/day on days 1-5, 10, 17, 24, 31 and 38, associated with steroid treatment (intravenous methylprednisolone at dosage of 20 mg/day). On day 10, during the administration of the sixth dose of L-Amb (and 48 hours after starting the antiviral drugs), the patient developed anaphylactic shock with severe oedema of the glottis requiring intubation and admission to the intensive care unit. In the following days, tracheostomy was performed due to persistent inflammation of the glottis and the difficulty in extubation. PCR for *Leishmania* was negative in the arytenoid mucosa. Two weeks later, the tracheostomy tube was removed, and the patient was transferred to the Infectious Disease Unit. Oral miltefosine (50 mg x 3/day) was introduced and well tolerated. The patient was discharged on day 49 with a mac-

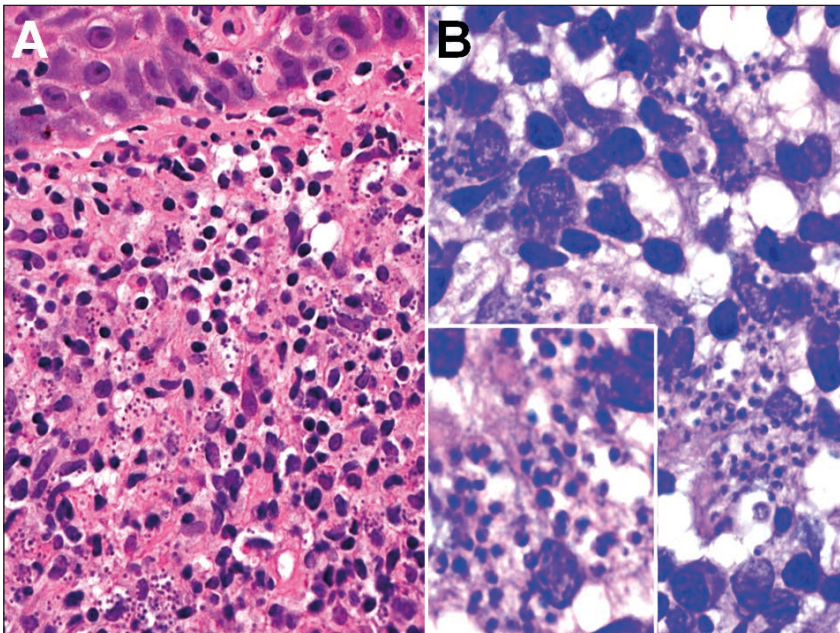


Figure 1 - (A) Granulomatous inflammation is observed within chorion in Hematoxylin/Eosin (magnification 400x); (B) Numerous *Leishmania* amastigotes highlighted by Giemsa stain (magnification 1000x).

roscopic regression of the nasal lesion. After completing 4 weeks of therapy, miltefosine was administered as secondary prophylaxis at a dosage of 50 mg × 2/day. At subsequent follow-up there were no signs of recurrence or macroscopic nasal mucosa lesions; after 10 months HIV-1 RNA was no longer detectable, CD4 count was 215 cells/mm³, and there was no significant alteration of liver or kidney function. The patient is continuing miltefosine until sustained immunological recovery and tolerates it well.

■ DISCUSSION

Leishmaniasis was a relatively frequent opportunistic disease during the HIV-related epidemic, especially in the Mediterranean area; for this reason the visceral form (visceral leishmaniasis, VL) was included as a stage 4, AIDS-defining condition in the World Health Organization (WHO) clinical staging system for HIV [1,2,7]. Although our patient probably contracted the parasite infection in Italy, where *L. infantum* is the only known endemic species, genotyping suggests that it is not possible to exclude reactivation of a prior latent infection due to immunosuppression [2]. In fact, very few autochthonous cases of VL are reported in Nigeria [8]. *L. infantum* is usually associated with VL, however atypical features including cutaneous and mucosal involvement, isolated or in combination with VL, have been described in immunocompromised patients [9,10]. In severely immunocompromised HIV-positive subjects (CD4 <50 mm³), atypical amastigotes localizations (digestive tract, lung, skin, tonsils) have been reported in up to 41% of HIV-positive subjects with VL in Southern France [11].

In our case, isolated ML was also the first unmasking HIV condition in a late-presenter patient [12]. In most cases, histological examination combined with molecular techniques can confirm suspected ML, whereas treatment and long-term suppression are more complex, especially for the high risk of recurrence [2, 13]. There is no first-choice treatment for ML, and therapy must be personalized [2]. Uncontrolled data from case report series have been published regarding therapy with L-AmB (not FDA-approved for ML) [2, 14]. Limited data from two non-randomized-controlled trials conducted in the region of Bolivia, where *L. braziliensis* is endemic, shows a 71% cure rate,

for ML patients treated with miltefosine [15,16]. Miltefosine is therefore only FDA-approved for ML caused only by *L. braziliensis* and is considered less effective for leishmaniasis caused by *L. infantum-chagasi*, the etiological agent of our case [2]. A recent study seems to confirm the natural resistance of *Leishmania infantum* to miltefosine contributing to the treatment failure of visceral leishmaniasis in Brazil [17]. Even less data is available for ML in immunocompromised patients, an unexplored context in which systemic therapy, like for VL, is suggested [2]. The FDA-approved total dose of L-AmB for VL in immunocompromised hosts is 40 mg/kg but there is little evidence to suggest that miltefosine is effective [2]. An interesting recent randomized trial showed that the sequential use of L-AmB (30 mg/kg) followed by miltefosine (100 mg/28 days) is more effective in patients with VL and HIV in Ethiopia [18]. A similar result was previously documented in India with a combined treatment [3]. These findings could modify or direct the current recommendations if confirmed in other areas and with other *Leishmania* species. In line with available evidence we treated the patient with L-AmB but soon had to suspend it due to life-threatening anaphylaxis, despite prophylactic administration of steroids, expected in the treatment of ML [2]. L-AmB is not only a high-cost drug but can also have serious side effects. Acute infusion reaction and complement-activation-related-pseudoallergy (CARPA) have been described and could bring to select an alternative treatment as in our case [2]. It is difficult to determine whether the simultaneous administration of antiretroviral therapy and the risk of a Jarisch-Herxheimer reaction during ML treatment have contributed to the adverse event [2]. The subsequent tolerability of antiretroviral therapy and the negativity of *Leishmania* DNA in the laryngeal specimen seem to confirm the hypothesis of an anaphylactoid reaction to L-AMB. In co-infected HIV patients with VL, post-treatment relapses are much more common and secondary prophylaxis is therefore recommended, usually with L-AmB, while experience using miltefosine in this setting is limited [2, 19]. Discontinuation can be considered in patients whose CD4 cell count on antiretroviral therapy has been >200-350 cells/mm³ for at least 6 months [2]. In HIV-infected patients with cutaneous or mucosal leishmaniasis, secondary prophylaxis is not rou-

tinely recommended under current guidelines but is only suggested for immunocompromised patients with cutaneous leishmaniasis who have multiple relapses after adequate treatment [2, 19]. However, in our case, considering the life-threatening course of the disease, the adverse reaction to L-AmB, and the patient's very good tolerance of the miltefosine, this drug was used for secondary prophylaxis. At 10-month follow up there were no signs of parasitic relapse or toxicity and the treatment is still ongoing until sustained immunological recovery is achieved.

In conclusion, the present case confirms that management of ML with HIV-coinfection is complex, and the treatment with miltefosine alone or in combination with L-AmB may be a valid therapeutic alternative.

Conflict of interest

None

REFERENCES

- [1] Pagliano P., Ascione T., Di Flumeri G., Boccia G., De Caro F. Visceral Leishmaniasis in immunocompromised: diagnostic and therapeutic approach and evaluation of the recently released IDSA guidelines. *Infez. Med.* 24, 265-271, 2016.
- [2] Aronson N., Herwaldt B.L., Libman M., et al. Diagnosis and treatment of leishmaniasis: Clinical practice guidelines by the Infectious Diseases Society of America (IDSA) and the American Society of Tropical medicine and hygiene (ASTMH). *Clin. Infect. Dis.* 63, e202-e264, 2016.
- [3] Mahajan R., Das P., Isaakidis P., et al. Combination treatment for visceral leishmaniasis patients coinfecting with human immunodeficiency virus in India. *Clin. Infect. Dis.* 61, 1255-1262, 2015.
- [4] Marques N., Sa R., Coelho F., Oliveira J., Saraiva Da Cunha J., Medico-Silvestre A. Miltefosine for visceral leishmaniasis relapse treatment and secondary prophylaxis in HIV-infected patients. *Scand. J. Infect. Dis.* 40, 523-526, 2008.
- [5] van Eys G.J.J.M., Schoone G.J., Kroon M.N.C., Ebeling S.B. Sequence analysis of small subunit ribosomal RNA genes and its use for detection and identification of *Leishmania* parasites. *Mol. Biochem. Parasitol.* 51, 133-142, 1992.
- [6] Schönian G., Nasserredin A., Dinse N., et al. PCR diagnosis and characterization of *Leishmania* in local and imported clinical samples. *Diagn. Microbiol. Infect. Dis.* 47, 349-358, 2003.
- [7] World Health Organization (2006) WHO Case definitions of HIV for surveillance and revised clinical staging and immunological classification of HIV-related disease in adults and children. Available at: <http://www.who.int/hiv/pub/guidelines/hivstaging/en/> [Accessed 24th May, 2019].
- [8] Alvar J., Vélez I.D., Bern C., et al. WHO Leishmaniasis Control Team. Leishmaniasis worldwide and global estimates of its incidence. *PLoS One* 7, e35671, 2012.
- [9] Rinaldi F., Giachè S., Spinicci M., et al. Focal spleen lesions in visceral leishmaniasis, a neglected manifestation of a neglected disease: report of three cases and systematic review of literature. *Infection* 47, 507-518, 2019.
- [10] Roshental E., Marty P., del Giudice P., et al. HIV and *Leishmania* coinfection: a review of 91 cases with focus on atypical locations of *Leishmania*. *Clin. Infect. Dis.* 31, 1093-1095, 2000.
- [11] Faucher B., Pomares C., Fourcade S., et al. Mucosal *Leishmania infantum* leishmaniasis: specific pattern in a multicentre survey and historical cases. *J. Infect.* 63, 76-82, 2011.
- [12] Madeddu G., Fiori M.L., Ena P., et al. Mucocutaneous leishmaniasis as presentation of HIV infection in Sardinia, insular Italy. *Parasitol. Int.* 63, 35-36, 2014.
- [13] Monge-Maillo B., Norman F.F., Cruz I., Alvar J., Lopez-Velez R. Visceral leishmaniasis and HIV coinfection in the Mediterranean Region. *PLoS Negl. Trop. Dis.* 8, e3021, 2014.
- [14] Mosimann V., Neumayr A., Paris D.H., Blum J. Liposomal amphotericin B treatment of Old World cutaneous and mucosal leishmaniasis: A literature review. *Acta Trop.* 182, 246-250, 2018.
- [15] Soto J., Toledo J., Valda L., et al. Treatment of Bolivian mucosal leishmaniasis with miltefosine. *Clin. Infect. Dis.* 44, 350-356, 2007.
- [16] Soto J., Rea J., Valderrama M., et al. Efficacy of extended (six weeks) treatment with miltefosine for mucosal leishmaniasis in Bolivia. *Am. J. Trop. Med. Hyg.* 81, 387-389, 2009.
- [17] Carnielli J.B.T., Monti-Rocha R., Costa D.L. et al. Natural resistance of *Leishmania infantum* to miltefosine contributes to the low efficacy in the treatment of visceral leishmaniasis in Brazil. *Am. J. Trop. Med. Hyg.* 101, 789-794, 2019.
- [18] Diro E., Blesson S., Edwards T., et al. A randomized trial of AmBisome monotherapy and AmBisome and miltefosine combination to treat visceral leishmaniasis in HIV co-infected patients in Ethiopia. *PLoS. Negl. Tro. Dis.* 13, e0006988, 2019.
- [19] Guidelines for the prevention and treatment of opportunistic infections in adults and adolescents with HIV. Department of Health and Human Services. Available at https://aidsinfo.nih.gov/contentfiles/lvguidelines/adult_oi.pdf [18th April, 2019].