




REVIEW

REVISED **Advances in the pathophysiology of adult-onset focal dystonias: recent neurophysiological and neuroimaging evidence [version 2; peer review: 2 approved]**

Antonella Conte^{1,2}, Giovanni Defazio³, Marcello Mascia³, Daniele Belvisi², Patrizia Pantano^{1,2}, Alfredo Berardelli ^{1,2}

¹Department of Human Neurosciences, Sapienza, University of Rome, Rome, Italy

²IRCCS Neuromed, Pozzilli (IS), Italy

³Department of Medical Sciences and Public Health, Neurology Unit, University of Cagliari and AOU Cagliari, Monserrato, Cagliari, Italy

v2 **First published:** 30 Jan 2020, 9(F1000 Faculty Rev):67 (<https://doi.org/10.12688/f1000research.21029.1>)
Latest published: 26 Mar 2020, 9(F1000 Faculty Rev):67 (<https://doi.org/10.12688/f1000research.21029.2>)

Abstract

Focal dystonia is a movement disorder characterized by involuntary muscle contractions that determine abnormal postures. The traditional hypothesis that the pathophysiology of focal dystonia entails a single structural dysfunction (i.e. basal ganglia) has recently come under scrutiny. The proposed network disorder model implies that focal dystonias arise from aberrant communication between various brain areas. Based on findings from animal studies, the role of the cerebellum has attracted increased interest in the last few years. Moreover, it has been increasingly reported that focal dystonias also include nonmotor disturbances, including sensory processing abnormalities, which have begun to attract attention. Current evidence from neurophysiological and neuroimaging investigations suggests that cerebellar involvement in the network and mechanisms underlying sensory abnormalities may have a role in determining the clinical heterogeneity of focal dystonias.

Keywords

dystonia, neurophysiology, neuroimaging, magnetic resonance; pathophysiology

Open Peer Review

Reviewer Status  

| | Invited Reviewers | |
|---|---|---|
| | 1 | 2 |
| version 2 (revision) 26 Mar 2020 | | |
| version 1 30 Jan 2020 |  |  |

F1000 Faculty Reviews are written by members of the prestigious F1000 Faculty. They are commissioned and are peer reviewed before publication to ensure that the final, published version is comprehensive and accessible. The reviewers who approved the final version are listed with their names and affiliations.

- 1 **Aasef G Shaikh**, Case Western University School of Medicine, Cleveland, USA
University Hospitals, Cleveland, USA
- 2 **Martin Bareš**, Masaryk University and St. Anne's University Hospital Brno, Brno, Czech Republic

University of Minnesota, Minneapolis, USA

Pavel Filip, Masaryk University and St. Anne's
University Hospital Brno, Brno, Czech Republic

Any comments on the article can be found at the
end of the article.

Corresponding author: Alfredo Berardelli (alfredo.berardelli@uniroma1.it)

Author roles: **Conte A:** Conceptualization, Formal Analysis, Visualization, Writing – Original Draft Preparation, Writing – Review & Editing; **Defazio G:** Writing – Original Draft Preparation, Writing – Review & Editing; **Mascia M:** Data Curation, Writing – Original Draft Preparation; **Belvisi D:** Writing – Review & Editing; **Pantano P:** Writing – Original Draft Preparation, Writing – Review & Editing; **Berardelli A:** Conceptualization, Supervision, Validation, Writing – Original Draft Preparation, Writing – Review & Editing

Competing interests: No competing interests were disclosed.

Grant information: The author(s) declared that no grants were involved in supporting this work.

Copyright: © 2020 Conte A *et al.* This is an open access article distributed under the terms of the [Creative Commons Attribution License](#), which permits unrestricted use, distribution, and reproduction in any medium, provided the original work is properly cited.

How to cite this article: Conte A, Defazio G, Mascia M *et al.* **Advances in the pathophysiology of adult-onset focal dystonias: recent neurophysiological and neuroimaging evidence [version 2; peer review: 2 approved]** F1000Research 2020, 9(F1000 Faculty Rev):67 (<https://doi.org/10.12688/f1000research.21029.2>)

First published: 30 Jan 2020, 9(F1000 Faculty Rev):67 (<https://doi.org/10.12688/f1000research.21029.1>)

REVISED Amendments from Version 1

The affiliation of Prof. Giovanni Defazio and Dr. Marcello Mascia has been changed to "Department of Medical Sciences and Public Health, Neurology Unit, University of Cagliari and AOU Cagliari, Monserrato, Cagliari, Italy", as the previous affiliation listed for them in the version 1 was incorrect.

Any further responses from the reviewers can be found at the end of the article

Introduction

Dystonia is a disorder characterized by excessive and sustained muscle contractions that cause abnormal postures and involuntary movements that can be twisting, repetitive, or tremulous. It is often initiated or worsened by voluntary action and is associated with an overflow of muscle activity^{1,2}.

Idiopathic adult-onset dystonia, the most common form of dystonia, has variable clinical expression, though it often has a focal onset such as blepharospasm (BSP), oromandibular dystonia, cervical dystonia (CD), laryngeal dystonia, or arm dystonia^{1,3-5}. In adulthood, the lower limb has rarely been observed as a site of dystonia⁶.

The demographic and clinical characteristics of adult-onset focal dystonias are now well established. Dystonias in the craniocervical area are more common in women, whereas occupational limb cramps are more common in men³. Adult-onset dystonia has a limited tendency to spread to adjacent body regions^{1,3-5}, which likely depends on the site and age of dystonia onset and on genetic factors^{7,8}. Focal dystonias may be associated with rest/postural tremor in the head or upper limbs^{9,10}.

In addition to motor signs, patients with adult-onset dystonia may also have a spectrum of nonmotor symptoms, including psychiatric manifestations (namely depression, anxiety, and obsessive compulsive traits)¹¹, mild disturbances in executive functions¹², and sensory symptoms¹³. In patients with BSP, sensory symptoms may include a burning, gritty sensation in the eye, dry eye, and photophobia, which may develop months or years before BSP onset. In patients with CD, dystonic movements are often associated with neck pain that contributes significantly to patient disability and a low quality of life. The overall burden of nonmotor symptoms may vary in different patients with focal dystonia¹⁴. All types of focal dystonia can be specifically relieved by sensory tricks, which are self-acquired maneuvers that transiently improve focal dystonia in a consistent proportion of patients^{15,16}.

In an early paper, Marsden *et al.*¹⁷ suggested that the basal ganglia play an important pathophysiological role in adult-onset focal dystonia. Indeed, early lesional studies showed that structural lesions in the basal ganglia determine dystonia (and not only focal forms) in contralateral body parts¹⁷⁻²⁰. Since basal ganglia determine motor command in goal-directed motor learning (i.e. facilitate the desired motor output and

concomitantly inhibit unnecessary motor output), basal ganglia dysfunction may conceivably determine abnormal motor command. Moreover, it was also observed that oscillatory activity of the globus pallidus internus (GPi) at a frequency of <12 Hz contributes to dystonic motor symptoms²¹⁻²³ and that deep brain stimulation (DBS) of the GPi improved dystonia²⁴⁻²⁶.

Earlier neurophysiological studies demonstrated reduced inhibition at the level of the primary motor cortex, brainstem, and spinal cord^{1,3,27-29}, abnormal plasticity mechanisms in the cortical motor areas, and abnormal sensory integration²⁹⁻³⁴. Likewise, magnetic resonance imaging (MRI) studies showed gray matter volume differences in several cortical/subcortical regions in patients with different focal dystonias. However, owing to the wide array of connections between the basal ganglia and several brain areas, these changes were generally interpreted as consequences of a primary basal ganglia dysfunction.

The assertion that focal dystonia is exclusively the result of basal ganglia dysfunction has recently been challenged by the remarkable clinical heterogeneity of the motor and nonmotor manifestations characterizing the different forms of adult-onset focal dystonias, as well as by lesion studies demonstrating that secondary focal dystonia is related to structural lesions in various sites in the nervous system, such as the basal ganglia, thalamus, and cerebellum³⁵⁻³⁷. It has therefore been proposed that dystonia may not be due to a lesion or an abnormal function of only one structure, namely the basal ganglia, but rather may be due to dysfunctional mechanisms in other brain areas, either concomitantly with or secondary to altered basal ganglia influence, that contribute to the pathophysiology of the condition. This may be particularly true for CD. Animal models of reversible dystonia induced by means of muscimol inactivation have suggested a dysfunction of a circuit including mesencephalic reticular formation neurons, cerebellum, tectum, and the basal ganglia, known to play a fundamental role in control of eye, head, and coordinated eye and head movements³⁸⁻⁴⁴. The dysfunction, however, may not be primary in these regions but rather reflect an abnormal activity originating in other structures providing feedback to the network such as the cerebellum. In this vein of thought, the role of the cerebellum in the pathophysiology of focal dystonias has attracted great interest in the last decade^{45,46}.

In this paper, we provide a comprehensive overview of the new findings from recent neurophysiological and neuroimaging investigations regarding the pathophysiology of adult-onset dystonia and highlight the remaining knowledge gaps in the understanding of this condition.

Recent evidence from neurophysiological investigations

In recent years, neurophysiological investigations have largely focused on the pathophysiological mechanisms linking the hypothesized basal ganglia dysfunction to the activity of distant sites and the mechanisms underlying sensory abnormalities in focal dystonias, specifically altered temporal discrimination of sensory stimuli and pain (Table 1).

Table 1. Recent neurophysiological abnormalities in focal dystonias.

| Neural structure | Function | Patients | Main findings |
|------------------|---|---|---|
| Cerebellum | Eye blink classical conditioning | CD with and without tremor | Altered only in patients with tremor |
| | Feedforward adaptation | CD with and without tremor | Altered only in patients with tremor |
| Sensory system | Somatosensory temporal discrimination threshold | CD | Increased values correlate with high-frequency oscillations and paired somatosensory evoked potentials inhibition |
| | Quantitative sensory testing | CD, upper limb dystonia, generalized dystonia | Reduced cold and hot detection threshold |
| | Laser evoked potentials | CD, BSP | Normal N2/P2 amplitude |
| | Conditioned pain modulation protocol | CD, BSP | Reduced conditioned pain modulation response as compared to patients with BSP and healthy subjects |

BSP, blepharospasm; CD, cervical dystonia

Using scalp EEG recordings in dystonia patients implanted with DBS electrodes in the GPI and subthalamic nucleus, Miocinovic *et al.*⁴⁷ demonstrated that chronic DBS reduces exaggerated alpha oscillations and alpha band interhemispheric coherence in the motor cortex, thus confirming that clinical improvement with GPI-DBS reflects DBS-induced direct suppression of abnormal oscillatory activity in the motor cortex^{24,48}.

Sedov *et al.* recently recorded single unit neural responses and local field potentials from the GPI in CD patients undergoing DBS surgery. Firing rate and discharge pattern of the GPI were asymmetric in patients with torticollis. Neuronal asymmetry correlated with the degree of involuntary head turning. Sedov *et al.* concluded that asymmetric pallidal activity results in asymmetric feedback to the mesencephalic neural integrator causing dysfunction in the network integrating eye and head coordinated movement^{49,50}.

Studies using animal models of dystonia, however, also showed that cerebellar output alters basal ganglia activity and determines dystonic postures^{51–53}. The observation that mutations in *THAP1* and *KMT2B* genes, highly expressed in the cerebellum, can induce generalized dystonia further supports the cerebellum's role in the pathophysiology of dystonia^{54,55}. In humans, cerebellar involvement in dystonia pathophysiology has recently been tested using eye blink classic conditioning (EBCC) and motor learning paradigms involving adaptation mechanisms. EBCC consists of a Pavlovian learning protocol integrated at the level of Purkinje cells and deep cerebellar nuclei. Some authors have shown that EBCC is impaired in patients with idiopathic focal hand dystonia and CD⁵⁶. Conversely, adaptation learning, which tests the predictive ability to adjust motor execution after a perturbation, has been found to be normal in patients with CD^{57,58}. The contrasting findings obtained by these two neurophysiological tests tentatively exclude a global cerebellar dysfunction in dystonic patients.

Since patients with dystonia, specifically those with CD, often have concomitant tremor, some authors have investigated whether the presence of tremor may be the clinical feature reflecting cerebellar involvement. Hence, in studying CD patients with and without tremor, Antelmi *et al.*⁵⁹ observed that patients with dystonic tremor showed a decreased number of conditioned responses in the EBCC paradigm as compared to healthy controls and dystonic patients without tremor. Similarly, when investigating anticipatory movement control during a bimanual task, Avanzino *et al.*⁵⁸ found that adaptation of anticipatory adjustment was altered in patients with CD and tremor but not in CD patients without tremor and healthy subjects. These observations therefore suggest that cerebellar dysfunction more likely determines tremor than dystonia. Nonetheless, since most neurophysiological investigations testing the cerebellar hypothesis were conducted in patients with CD, further investigations should also assess whether this conclusion also applies to other types of focal dystonia.

Earlier studies tested the sensory system in dystonic patients by assessing somatosensory-evoked potentials (SEPs), electrical potentials generated in sensory pathways at peripheral, spinal, subcortical, and cortical levels of the nervous system⁶⁰. In healthy subjects, the SEP amplitude obtained by stimulating two adjacent nerves simultaneously is smaller than that obtained by stimulating a single nerve due to inhibitory mechanisms^{61–65}. In dystonic patients with upper limb involvement, some authors have reported impaired suppression of SEPs at the spinal, brainstem, and cortical levels after mixed stimulation of the median and ulnar nerves^{66,67}, thus implying reduced inhibition at multiple levels of the sensory system. Supporting this hypothesis, several studies on patients with various forms of focal dystonia have reported increased temporal discrimination thresholds (STDts), the interval needed to discriminate two consecutively applied stimuli^{30,33,68,69}. Recently, Antelmi *et al.*⁷⁰ recorded the high-frequency potential

oscillations (HFOs) related to SEPs in order to understand the mechanisms responsible for altered STDT in dystonia and found that patients with CD had a reduced area of the early component of HFOs and reduced paired SEP inhibition that correlated with increased STDT values. Since HFOs are generated by the activity of a population of 3b cortical inhibitory interneurons that receive thalamo-cortical inputs⁷¹, the authors concluded that impaired temporal discrimination in dystonia arises from defective inhibitory mechanisms in the primary somatosensory cortex.

As regards pain, there is some evidence from quantitative sensory testing that the thermal detection threshold and pain sensitivity are abnormal in patients with dystonia^{72,73}. Though an earlier investigation⁷⁴ showed, and a recent study confirmed⁶⁵, that nociceptive pathways are normal, as tested by laser-evoked potentials in patients with CD, Tinazzi *et al.*⁷⁵ recently investigated whether pain arises from dysfunction of regulatory pathways of nociceptive transmission. To this aim, the authors applied a protocol, termed the conditioned pain modulation protocol, to test descending inhibitory control on nociceptive neurotransmission. This protocol consists of delivering a painful conditioning stimulus alongside another experimentally induced painful test stimulus. The ratio of the laser evoked N2/P2 potential amplitude during the application of the heterotopic noxious conditioning stimulation, as compared to baseline, reflects the physiological reduction of the perceived conditioned stimulus. The authors found that patients with CD have

a reduced conditioned pain modulation response as compared to patients with BSP and healthy subjects and concluded that the endogenous inhibitory pain system is primarily defective in CD. Although this abnormality was present regardless of the presence of pain in these patients, it is likely that this alteration makes patients with CD more susceptible to developing pain. In addition, the evidence that this response is normal in patients with BSP implies that the two types of focal dystonia may differ in their pathophysiological mechanisms⁷⁵.

Recent evidence from neuroimaging techniques

The introduction of functional neuroimaging investigations has allowed investigators to view changes in the functional activity of various brain areas in dystonia (Table 2). Changes in the blood oxygen level-dependent (BOLD) signal, measured while patients perform a task (task-based fMRI) or during resting conditions (resting state fMRI), allow the functional activity and connectivity of different brain areas to be evaluated⁷⁶⁻⁷⁹. Motor tasks such as hand movements, writing, playing instruments, and blinking are the most common tasks that have been used in dystonia. Sensory and motor task-related fMRI studies first showed an abnormal activation of the primary sensory and motor cortices, secondary motor cortex, basal ganglia, and the cerebellum that were consistent across different dystonia phenotypes⁸⁰⁻⁸⁸. Changes were detected while patients with dystonia performed tasks with and without dystonia induced by the movement itself and also when the tasks involved clinically unaffected body regions^{84,85}. Altered

Table 2. Recent neuroimaging abnormalities in focal dystonias.

| MRI technique | Function/analysis | Patients | Main findings |
|----------------------|--|-----------------|---|
| Task-related fMRI | Head rotation | CD | Increased activation of the ipsilateral anterior cerebellum and sensorimotor cortex depending on the direction of head rotation |
| | Hand force task | CD | Increased activity of the cerebellum and decreased functional activity of the somatosensory cortex |
| | Visuospatial task | CD | Reduced activation of the cerebellum associated with a reduced connectivity of the cerebellum with basal ganglia and the motor cortex, and a reduced activation of temporal, premotor, and parietal associative areas |
| | Transient finger pressure | WC | Decreased activation of the sensorimotor network |
| | Visual looming stimuli | CD | Reduced superior collicular activation |
| Resting state fMRI | Independent component analysis | BSP | Abnormalities in sensory-motor network, frontoparietal network, salience network, default-mode network |
| | Intraregional brain activities and interregional functional connectivities | BSP | Abnormalities in both intraregional and interregional functional connectivities, abnormal functional connectivity between the right caudate and left striatum and right supplementary motor area |
| | Graph theoretical analysis | BSP, CD, WC, LD | Large-scale alteration of network architecture |
| Diffusion tensor MRI | FA, MD | BSP, CD, LD | Structural alterations distinguish between focal dystonia phenotypes |

BSP, blepharospasm; CD, cervical dystonia; FA, fractional anisotropy; fMRI, functional magnetic resonance imaging; LD, laryngeal dystonia; MD, mean diffusivity; WC, writer's cramp.

sensory processing and abnormal somatotopic sensory organization in the basal ganglia and sensory cortex were also found, most consistently in the hand area of the primary somatosensory cortex^{80–82}. Dysfunction was also detected during motor preparation and motor imagery⁸³.

In the last three years, task-related fMRI studies have aimed to test the involvement of the cerebellum in focal dystonia and to identify functional correlates of altered sensory processing. In patients with CD, isometric head rotation in the direction of dystonic head rotation was associated with an increased activation of the ipsilateral anterior cerebellum, whereas isometric head rotation in the opposite direction was associated with increased sensorimotor cortex activity⁸⁹. In another study in CD patients performing a hand force task, symptom severity was associated with increased activity of the cerebellum and decreased functional activity of the somatosensory cortex⁹⁰. Using a visuospatial task, Filip *et al.*⁹¹ found a reduced activation of the cerebellum associated with a reduced connectivity of the cerebellum with basal ganglia and the motor cortex, and a reduced activation of temporal, premotor, and parietal associative areas.

As regards sensory processing, temporal discrimination deficits corresponded to disrupted superior collicular activity during looming stimuli in patients with CD⁹². In writer's cramp, the sensory processing of stimulation sequences (transient finger pressure) before the execution of a motor task revealed widespread decreased activation of the sensorimotor network, suggesting defective sensory processing during motor planning in these patients⁹³.

In conclusion, recent evidence with fMRI has shown that the cerebellum is involved in altered connectivity and has identified functional correlates of altered sensory processing. However, since dystonic symptoms often worsen or are triggered by motor task execution, a relevant issue with task-related fMRI findings is that they are unable to determine whether functional abnormalities are causes or consequences of dystonic motor disturbances. Similarly, the cerebellar involvement in the abnormal connectivity can be either primary or compensatory. Studies in unaffected carriers of dystonia-related mutations and unaffected relatives of dystonic patients may help clarify this important issue.

Using resting-state fMRI with independent component analysis (ICA)^{94–99} in patients with BSP, Huang *et al.*¹⁰⁰ observed alterations in multiple neural networks including the sensory–motor network (decreased connectivity involving the bilateral primary sensorimotor cortex, supplementary motor area, right premotor cortex, bilateral precuneus, and left superior parietal cortex), the right frontoparietal network (decreased connections in the middle frontal gyrus, dorsal lateral prefrontal cortex, and inferior frontal gyrus), and the salience network (increased connectivity in the left superior frontal gyrus and middle frontal gyrus). Abnormalities in regions of the default mode network and sensory integration network have been reported in patients with BSP¹⁰¹. Further confirmation of an abnormal functional connectivity between the right caudate

and left striatum and right supplementary motor area correlating with BSP severity comes from the study by Ni *et al.*¹⁰². In embouchure dystonia, changes in resting state connectivity were found in sensorimotor and auditory areas and in the cerebellum¹⁰³. Abnormalities in both intraregional brain activities and interregional functional connectivity were also described in patients with CD¹⁰⁴. Functional changes extensively involved both cortical and subcortical structures, and common alterations of the two measures were identified bilaterally in the postcentral gyrus as well as in the basal ganglia and thalamus. Overall, the above-cited findings with resting-state MRI have shown that in patients with focal dystonias altered connectivity in various brain networks is present independently from the execution of specific sensorimotor tasks, related or not to dystonia. Using both graph theoretical analysis^{79,94,105–108} and ICA, Battistella *et al.*¹⁰⁹ compared patients with task-specific (eight spasmodic dysphonia and seven writer's cramp patients) and non-task-specific dystonia (nine CD and nine BSP patients) and found that every patient exhibited unusually expanded or minimized neural communities. In addition, patients with task-specific dystonia had substantial connectivity alterations in the primary sensorimotor and inferior cortices and abnormally formed hubs in the insula and superior temporal cortex, as compared to patients without task-specific dystonia¹⁰⁹. Results from graph theory analysis, therefore, suggest a large-scale alteration of network architecture in focal dystonia, with distinguishing features between task-specific and non-task-specific dystonia.

Earlier diffusion tensor imaging (DTI)^{79,110–112} studies showed microstructural alterations in the fiber tracts connecting the brainstem nuclei, basal ganglia, thalamus, cerebellum, motor cortex, and sensory cortex, and in the white matter (WM) of limbic, occipital, and prefrontal cortices in different forms of focal dystonia^{79,113,114}. In recent years, Berman *et al.*¹¹⁵ used DTI in patients with BSP and CD to show that there are focal alterations in various brain structures that are specific to the two forms of focal dystonia (i.e. GPi, subthalamic, and red nuclei in BSP versus the caudate nucleus and cerebellum in CD). Consistent with the hypothesis that specific focal alterations may distinguish between focal dystonia phenotypes, Bianchi *et al.*¹¹⁶ observed that spasmodic dysphonia phenotypes may be distinguished on the basis of focal structural abnormalities in the areas of motor control of speech production and auditory–motor integration, whereas spasmodic dysphonia genotypes were associated with structural changes in higher-order extra-Sylvian regions and their connecting pathways. Similarly, differences in structural integrity have been reported by Kirke *et al.*¹¹⁷ in patients with spasmodic dysphonia, both with and without tremor. Compared to patients with spasmodic dysphonia without tremor, patients with spasmodic dysphonia and tremor exhibited a greater extent of WM changes in the right posterior limb of the internal capsule at the junction of the corticospinal/corticopontine tracts and superior thalamic radiation¹⁰³.

Finally, Corp *et al.*³⁷ used an MRI technique termed “lesion network mapping” from connectome data of a large cohort of healthy subjects to test whether lesions causing CD belong

to a common brain network. However, the authors found that patients with CD had heterogeneous lesion sites (basal ganglia, brainstem, and cerebellum) that all belonged to a single functionally connected brain network.

Conclusion

For a long time, the pathophysiology of adult-onset focal dystonia has been thought to involve, uniquely, a basal ganglia disturbance. However, accumulating evidence in recent years now points to the anatomical and functional involvement of several brain regions. Recent findings have demonstrated an association between acquired focal dystonia and lesions in various brain regions, including the cortex, the basal ganglia, thalamus, brainstem, and cerebellum. Convincing evidence from both neurophysiological and neuroimaging investigations supports the hypothesis that the cerebellum intervenes in the pathophysiology of dystonia. However, although it is widely accepted that abnormal cerebellar output may determine tremor in dystonia, it is still unclear whether the cerebellum is the primary node where aberrant communication arises. Moreover, it is also unclear whether the cerebellum plays a substantial role in all forms of focal dystonia or only in CD.

The neurophysiological reports of impaired sensory and motor inhibition at multiple levels of the central nervous system (contributing to altered tactile temporal discrimination as well as to motor manifestations) may well reflect not only a direct basal ganglia disturbance but also disturbances in the activity of basal ganglia-thalamo-cortical and cerebello-thalamo-cortical projections. Pain in CD patients, likely due to impaired descending regulatory mechanisms of nociceptive transmission, implies an additional dysfunctional network in this form of focal dystonia. In summary, recent neurophysiological and neuroimaging studies

demonstrate that focal dystonias involve disordered communication among several brain networks, in which basal ganglia and, possibly, the cerebellum act as entraining structures. Although different forms of focal dystonia all share alterations in neural structures belonging to the basal ganglia-thalamo-sensorimotor cortical network, specific clinical dystonic features may also emerge because of characteristic neural signatures in specific networks.

Finally, increased attention is now directed towards the remarkable clinical heterogeneity of motor manifestations and the variable occurrence of sensory, psychiatric, and executive function disturbances. The heterogeneous clinical features together with the neurophysiological and neuroimaging advances support the trend towards “splitting” focal dystonias, insofar as, taken to the extreme, each focal dystonia is unique to each patient.


Abbreviations

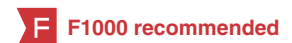BSP, blepharospasm; CD, cervical dystonia; DBS, deep brain stimulation; DTI, diffusion tensor imaging; EBCC, eye blink classic conditioning; GPi, globus pallidus internus; HFOs, high-frequency potential oscillations; ICA, independent component analysis; MRI, magnetic resonance imaging; SEPs, somatosensory-evoked potentials; STDT, increased temporal discrimination threshold; WM, white matter.

Acknowledgements

We thank Dr. Melissa Kerr from the Department of Human Neuroscience, Sapienza, University of Rome, for language editing.

References

- Albanese A, Bhatia K, Bressman SB, *et al.*: **Phenomenology and classification of dystonia: a consensus update.** *Mov Disord.* 2013; **28**(7): 863–73.
[PubMed Abstract](#) | [Publisher Full Text](#) | [Free Full Text](#)
- Jinnah HA, Berardelli A, Comella C, *et al.*: **The focal dystonias: current views and challenges for future research.** *Mov Disord.* 2013; **28**(7): 926–43.
[PubMed Abstract](#) | [Publisher Full Text](#) | [Free Full Text](#)
- Defazio G, Berardelli A, Hallett M: **Do primary adult-onset focal dystonias share aetiological factors?** *Brain.* 2007; **130**(Pt 5): 1183–93.
[PubMed Abstract](#) | [Publisher Full Text](#)
- Hallett M, Evinger C, Jankovic J, *et al.*: **Update on blepharospasm: report from the BEBRF International Workshop.** *Neurology.* 2008; **71**(16): 1275–82.
[PubMed Abstract](#) | [Publisher Full Text](#) | [Free Full Text](#)
- Defazio G, Jankovic J, Giel JL, *et al.*: **Descriptive epidemiology of cervical dystonia.** *Tremor Other Hyperkinet Mov (N Y).* 2013; **3**: pii: tre-03-193-4374-2.
[PubMed Abstract](#) | [Publisher Full Text](#) | [Free Full Text](#)
- Martino D, Macerollo A, Abbruzzese G, *et al.*: **Lower limb involvement in adult-onset primary dystonia: frequency and clinical features.** *Eur J Neurol.* 2010; **17**(2): 242–6.
[PubMed Abstract](#) | [Publisher Full Text](#)
- Abbruzzese G, Berardelli A, Girlanda P, *et al.*: **Long-term assessment of the risk of spread in primary late-onset focal dystonia.** *J Neurol Neurosurg Psychiatry.* 2008; **79**(4): 392–6.
[PubMed Abstract](#) | [Publisher Full Text](#)
-  Defazio G, Matarin M, Peckham EL, *et al.*: **The TOR1A polymorphism rs1182 and the risk of spread in primary blepharospasm.** *Mov Disord.* 2009; **24**(4): 613–6.
[PubMed Abstract](#) | [Publisher Full Text](#) | [Free Full Text](#) | **F1000 Recommendation**
- Defazio G, Conte A, Gigante AF, *et al.*: **Is tremor in dystonia a phenotypic feature of dystonia?** *Neurology.* 2015; **84**(10): 1053–9.
[PubMed Abstract](#) | [Publisher Full Text](#)
- Gigante AF, Berardelli A, Defazio G: **Rest tremor in idiopathic adult-onset dystonia.** *Eur J Neurol.* 2016; **23**(5): 935–9.
[PubMed Abstract](#) | [Publisher Full Text](#)
- Fabbrini G, Berardelli I, Moretti G, *et al.*: **Psychiatric disorders in adult-onset focal dystonia: a case-control study.** *Mov Disord.* 2010; **25**(4): 459–65.
[PubMed Abstract](#) | [Publisher Full Text](#)
- Romano R, Bertolino A, Gigante A, *et al.*: **Impaired cognitive functions in adult-onset primary cranial cervical dystonia.** *Parkinsonism Relat Disord.* 2014; **20**(2): 162–5.
[PubMed Abstract](#) | [Publisher Full Text](#)



13. Conte A, Defazio G, Hallett M, *et al.*: **The role of sensory information in the pathophysiology of focal dystonias.** *Nat Rev Neurol.* 2019; **15**(4): 224–33.
[PubMed Abstract](#) | [Publisher Full Text](#)
14. Ferrazzano G, Conte A, Gigante A, *et al.*: **Disease progression in blepharospasm: a 5-year longitudinal study.** *Eur J Neurol.* 2019; **26**(2): 268–73.
[PubMed Abstract](#) | [Publisher Full Text](#)
15. Hallett M: **The dystonias: a heterogeneous collection.** *Eur J Neurol.* 2015; **22**(5): 741–2.
[PubMed Abstract](#) | [Publisher Full Text](#)
16. Dagostino S, Ercoli T, Gigante AF, *et al.*: **Sensory trick in upper limb dystonia.** *Parkinsonism Relat Disord.* 2019; **63**: 221–3.
[PubMed Abstract](#) | [Publisher Full Text](#)
17. Marsden CD, Obeso JA, Zarranz JJ, *et al.*: **The anatomical basis of symptomatic hemidystonia.** *Brain.* 1985; **108**(Pt 2): 463–83.
[PubMed Abstract](#) | [Publisher Full Text](#)
18. Pettigrew LC, Jankovic J: **Hemidystonia: a report of 22 patients and a review of the literature.** *J Neuro Neurosurg Psychiatry.* 1985; **48**(7): 650–7.
[PubMed Abstract](#) | [Publisher Full Text](#) | [Free Full Text](#)
19. LeDoux MS, Brady KA: **Secondary cervical dystonia associated with structural lesions of the central nervous system.** *Mov Disord.* 2003; **18**(1): 60–9.
[PubMed Abstract](#) | [Publisher Full Text](#)
20. Neychev VK, Gross RE, Lehericy S, *et al.*: **The functional neuroanatomy of dystonia.** *Neurobiol Dis.* 2011; **42**(2): 185–201.
[PubMed Abstract](#) | [Publisher Full Text](#) | [Free Full Text](#)
21. Silberstein P, Kühn AA, Kupsch A, *et al.*: **Patterning of globus pallidus local field potentials differs between Parkinson's disease and dystonia.** *Brain.* 2003; **126**(Pt 12): 2597–608.
[PubMed Abstract](#) | [Publisher Full Text](#)
22. Chen CC, Kühn AA, Trottenberg T, *et al.*: **Neuronal activity in globus pallidus interna can be synchronized to local field potential activity over 3-12 Hz in patients with dystonia.** *Exp Neurol.* 2006; **202**(2): 480–6.
[PubMed Abstract](#) | [Publisher Full Text](#)
23. Liu X, Wang S, Yianni J, *et al.*: **The sensory and motor representation of synchronized oscillations in the globus pallidus in patients with primary dystonia.** *Brain.* 2008; **131**(Pt 6): 1562–73.
[PubMed Abstract](#) | [Publisher Full Text](#)
24. Barow E, Neumann WJ, Brücke C, *et al.*: **Deep brain stimulation suppresses pallidal low frequency activity in patients with phasic dystonic movements.** *Brain.* 2014; **137**(Pt 11): 3012–24.
[PubMed Abstract](#) | [Publisher Full Text](#) | [Free Full Text](#)
25. Volkmann J, Wolters A, Kupsch A, *et al.*: **Pallidal deep brain stimulation in patients with primary generalised or segmental dystonia: 5-year follow-up of a randomised trial.** *Lancet Neurol.* 2012; **11**(12): 1029–38.
[PubMed Abstract](#) | [Publisher Full Text](#) | [F1000 Recommendation](#)
26. Fox MD, Alterman RL: **Brain Stimulation for Torsion Dystonia.** *JAMA Neurol.* 2015; **72**(6): 713–9.
[PubMed Abstract](#) | [Publisher Full Text](#) | [Free Full Text](#)
27. Berardelli A: **New advances in the pathophysiology of focal dystonias.** *Brain.* 2006; **129**(Pt 1): 6–7.
[PubMed Abstract](#) | [Publisher Full Text](#)
28. Quartarone A, Hallett M: **Emerging concepts in the physiological basis of dystonia.** *Mov Disord.* 2013; **28**(7): 958–67.
[PubMed Abstract](#) | [Publisher Full Text](#) | [Free Full Text](#)
29. Conte A, Rocchi L, Latorre A, *et al.*: **Ten-Year Reflections on the Neurophysiological Abnormalities of Focal Dystonias in Humans.** *Mov Disord.* 2019; **34**(11): 1616–28.
[PubMed Abstract](#) | [Publisher Full Text](#)
30. Scontrini A, Conte A, Defazio G, *et al.*: **Somatosensory temporal discrimination in patients with primary focal dystonia.** *J Neuro Neurosurg Psychiatry.* 2009; **80**(12): 1315–9.
[PubMed Abstract](#) | [Publisher Full Text](#)
31. Quartarone A, Rizzo V, Terranova C, *et al.*: **Abnormal sensorimotor plasticity in organic but not in psychogenic dystonia.** *Brain.* 2009; **132**(Pt 10): 2871–7.
[PubMed Abstract](#) | [Publisher Full Text](#) | [Free Full Text](#) | [F1000 Recommendation](#)
32. Belvisi D, Suppa A, Marsili L, *et al.*: **Abnormal experimentally- and behaviorally-induced LTP-like plasticity in focal hand dystonia.** *Exp Neurol.* 2013; **240**: 64–74.
[PubMed Abstract](#) | [Publisher Full Text](#)
33. Hutchinson M, McGovern EM, Narasimham S, *et al.*: **The premotor syndrome of cervical dystonia: Disordered processing of salient environmental stimuli.** *Mov Disord.* 2018; **33**(2): 232–7.
[PubMed Abstract](#) | [Publisher Full Text](#) | [F1000 Recommendation](#)
34. Sadnicka A, Stevenson A, Bhatia KP, *et al.*: **High motor variability in DYT1 dystonia is associated with impaired visuomotor adaptation.** *Sci Rep.* 2018; **8**(1): 3653.
[PubMed Abstract](#) | [Publisher Full Text](#) | [Free Full Text](#) | [F1000 Recommendation](#)
35. Khooshnoodi MA, Factor SA, Jinnah HA: **Secondary blepharospasm associated with structural lesions of the brain.** *J Neurol Sci.* 2013; **331**(1–2): 98–101.
[PubMed Abstract](#) | [Publisher Full Text](#) | [Free Full Text](#)
36. Liuzzi D, Gigante AF, Leo A, *et al.*: **The anatomical basis of upper limb dystonia: lesson from secondary cases.** *Neurol Sci.* 2016; **37**(9): 1393–8.
[PubMed Abstract](#) | [Publisher Full Text](#)
37. Corp DT, Joutsa J, Darby RR, *et al.*: **Network localization of cervical dystonia based on causal brain lesions.** *Brain.* 2019; **142**(6): 1660–74.
[PubMed Abstract](#) | [Publisher Full Text](#) | [Free Full Text](#) | [F1000 Recommendation](#)
38. Farshadmanesh F, Klier EM, Chang P, *et al.*: **Three-dimensional eye-head coordination after injection of muscimol into the interstitial nucleus of Cajal (INC).** *J Neurophysiol.* 2007; **97**(3): 2322–38.
[PubMed Abstract](#) | [Publisher Full Text](#)
39. Klier EM, Wang H, Crawford JD: **Interstitial nucleus of cajal encodes three-dimensional head orientations in Fick-like coordinates.** *J Neurophysiol.* 2007; **97**(1): 604–17.
[PubMed Abstract](#) | [Publisher Full Text](#)
40. Klier EM, Crawford JD: **Neural control of three-dimensional eye and head posture.** *Ann N Y Acad Sci.* 2003; **1004**: 122–31.
[PubMed Abstract](#) | [Publisher Full Text](#)
41. Crawford JD, Martinez-Trujillo JC, Klier EM: **Neural control of three-dimensional eye and head movements.** *Curr Opin Neurobiol.* 2003; **13**(6): 655–62.
[PubMed Abstract](#) | [Publisher Full Text](#)
42. Klier EM, Wang H, Constantin AG, *et al.*: **Midbrain control of three-dimensional head orientation.** *Science.* 2002; **295**(5558): 1314–6.
[PubMed Abstract](#) | [Publisher Full Text](#)
43. Shaikh AG, Wong AL, Zee DS, *et al.*: **Keeping your head on target.** *J Neurosci.* 2013; **33**(27): 11281–95.
[PubMed Abstract](#) | [Publisher Full Text](#) | [Free Full Text](#)
44. Shaikh AG, Zee DS, Crawford JD, *et al.*: **Cervical dystonia: a neural integrator disorder.** *Brain.* 2016; **139**(Pt 10): 2590–9.
[PubMed Abstract](#) | [Publisher Full Text](#) | [Free Full Text](#)
45. Filip P, Lungu OV, Bareš M: **Dystonia and the cerebellum: a new field of interest in movement disorders?** *Clin Neurophysiol.* 2013; **124**(7): 1269–76.
[PubMed Abstract](#) | [Publisher Full Text](#)
46. Tewari A, Fremont R, Khodakhah K: **It's not just the basal ganglia: Cerebellum as a target for dystonia therapeutics.** *Mov Disord.* 2017; **32**(11): 1537–45.
[PubMed Abstract](#) | [Publisher Full Text](#) | [Free Full Text](#) | [F1000 Recommendation](#)
47. Miciocinovic S, Swann NC, de Hemptinne C, *et al.*: **Cortical gamma oscillations in isolated dystonia.** *Parkinsonism Relat Disord.* 2018; **49**: 104–5.
[PubMed Abstract](#) | [Publisher Full Text](#) | [F1000 Recommendation](#)
48. Ruge D, Tisch S, Hariz MI, *et al.*: **Deep brain stimulation effects in dystonia: time course of electrophysiological changes in early treatment.** *Mov Disord.* 2011; **26**(10): 1913–21.
[PubMed Abstract](#) | [Publisher Full Text](#) | [Free Full Text](#)
49. Sedov A, Popov V, Shabalov V, *et al.*: **Physiology of midbrain head movement neurons in cervical dystonia.** *Mov Disord.* 2017; **32**(6): 904–12.
[PubMed Abstract](#) | [Publisher Full Text](#) | [Free Full Text](#) | [F1000 Recommendation](#)
50. Sedov A, Usova S, Semenova U, *et al.*: **The role of pallidum in the neural integrator model of cervical dystonia.** *Neurobiol Dis.* 2019; **125**: 45–54.
[PubMed Abstract](#) | [Publisher Full Text](#) | [Free Full Text](#) | [F1000 Recommendation](#)
51. Calderon DP, Fremont R, Kraenzlin F, *et al.*: **The neural substrates of rapid-onset dystonia-Parkinsonism.** *Nat Neurosci.* 2011; **14**(3): 357–65.
[PubMed Abstract](#) | [Publisher Full Text](#) | [Free Full Text](#)
52. Chen CH, Fremont R, Arteaga-Bracho EE, *et al.*: **Short latency cerebellar modulation of the basal ganglia.** *Nat Neurosci.* 2014; **17**(12): 1767–75.
[PubMed Abstract](#) | [Publisher Full Text](#) | [Free Full Text](#)
53. Fremont R, Calderon DP, Maleki S, *et al.*: **Abnormal high-frequency burst firing of cerebellar neurons in rapid-onset dystonia-parkinsonism.** *J Neurosci.* 2014; **34**(35): 11723–32.
[PubMed Abstract](#) | [Publisher Full Text](#) | [Free Full Text](#)
54. Meyer E, Carss KJ, Rankin J, *et al.*: **Mutations in the histone methyltransferase gene *KMT2B* cause complex early-onset dystonia.** *Nat Genet.* 2017; **49**(2): 223–37.
[PubMed Abstract](#) | [Publisher Full Text](#) | [F1000 Recommendation](#)
55. Balint B, Mencacci NE, Valente EM, *et al.*: **Dystonia.** *Nat Rev Dis Primers.* 2018; **4**(1): 25.
[PubMed Abstract](#) | [Publisher Full Text](#) | [F1000 Recommendation](#)
56. Hoffland BS, Kassavetis P, Bologna M, *et al.*: **Cerebellum-dependent associative learning deficits in primary dystonia are normalized by rTMS and practice.** *Eur J Neurosci.* 2013; **38**(1): 2166–71.
[PubMed Abstract](#) | [Publisher Full Text](#)
57. Sadnicka A, Patani B, Saifee TA, *et al.*: **Normal motor adaptation in cervical dystonia: a fundamental cerebellar computation is intact.** *Cerebellum.* 2014; **13**(5): 558–67.
[PubMed Abstract](#) | [Publisher Full Text](#) | [Free Full Text](#)
58. Avanzino L, Ravaschio A, Lagravinese G, *et al.*: **Adaptation of feedforward movement control is abnormal in patients with cervical dystonia and tremor.** *Clin Neurophysiol.* 2018; **129**(1): 319–26.
[PubMed Abstract](#) | [Publisher Full Text](#) | [F1000 Recommendation](#)
59. Antelmi E, Di Stasio F, Rocchi L, *et al.*: **Impaired eye blink classical conditioning distinguishes dystonic patients with and without tremor.** *Parkinsonism Relat Disord.* 2016; **31**: 23–7.
[PubMed Abstract](#) | [Publisher Full Text](#)
60. Nuwer MR, Aminoff M, Desmedt J, *et al.*: **IFCN recommended standards for**

- short latency somatosensory evoked potentials. Report of an IFCN committee. International Federation of Clinical Neurophysiology. *Electroencephalogr Clin Neurophysiol*. 1994; **91**(1): 6–11.
[PubMed Abstract](#) | [Publisher Full Text](#)
61. Burke D, Gandevia SC, McKeon B, *et al.*: Interactions between cutaneous and muscle afferent projections to cerebral cortex in man. *Electroencephalogr Clin Neurophysiol*. 1982; **53**(4): 349–60.
[PubMed Abstract](#) | [Publisher Full Text](#)
62. Gandevia SC, Burke D, McKeon BB: Convergence in the somatosensory pathway between cutaneous afferents from the index and middle fingers in man. *Exp Brain Res*. 1983; **50**(2–3): 415–25.
[PubMed Abstract](#) | [Publisher Full Text](#)
63. Okajima Y, Chino N, Saitoh E, *et al.*: Interactions of somatosensory evoked potentials: simultaneous stimulation of two nerves. *Electroencephalogr Clin Neurophysiol*. 1991; **80**(1): 26–31.
[PubMed Abstract](#) | [Publisher Full Text](#)
64. Hsieh CL, Shima F, Tobimatsu S, *et al.*: The interaction of the somatosensory evoked potentials to simultaneous finger stimuli in the human central nervous system. A study using direct recordings. *Electroencephalogr Clin Neurophysiol*. 1995; **96**(2): 135–42.
[PubMed Abstract](#) | [Publisher Full Text](#)
65. Huttunen J, Ahlfors S, Hari R: Interaction of afferent impulses in the human primary sensorimotor cortex. *Electroencephalogr Clin Neurophysiol*. 1992; **82**(3): 176–81.
[PubMed Abstract](#) | [Publisher Full Text](#)
66. Tinazzi M, Priori A, Bertolasi L, *et al.*: Abnormal central integration of a dual somatosensory input in dystonia. Evidence for sensory overflow. *Brain*. 2000; **123**(Pt 1): 42–50.
[PubMed Abstract](#) | [Publisher Full Text](#)
67. Frasson E, Priori A, Bertolasi L, *et al.*: Somatosensory disinhibition in dystonia. *Mov Disord*. 2001; **16**(4): 674–82.
[PubMed Abstract](#) | [Publisher Full Text](#)
68. Bradley D, Whelan R, Kimmich O, *et al.*: Temporal discrimination thresholds in adult-onset primary torsion dystonia: an analysis by task type and by dystonia phenotype. *J Neurol*. 2012; **259**(1): 77–82.
[PubMed Abstract](#) | [Publisher Full Text](#)
69. Conte A, Ferrazzano G, Belvisi D, *et al.*: Does the Somatosensory Temporal Discrimination Threshold Change over Time in Focal Dystonia? *Neural Plast*. 2017; **2017**: 9848070.
[PubMed Abstract](#) | [Publisher Full Text](#) | [Free Full Text](#)
70. Antelmi E, Erro R, Rocchi L, *et al.*: Neurophysiological correlates of abnormal somatosensory temporal discrimination in dystonia. *Mov Disord*. 2017; **32**(1): 141–8.
[PubMed Abstract](#) | [Publisher Full Text](#) | [F1000 Recommendation](#)
71. Hashimoto I, Mashiko T, Imada T: Somatic evoked high-frequency magnetic oscillations reflect activity of inhibitory interneurons in the human somatosensory cortex. *Electroencephalogr Clin Neurophysiol*. 1996; **100**(3): 189–203.
[PubMed Abstract](#) | [Publisher Full Text](#)
72. Suttrup I, Oberdiek D, Suttrup J, *et al.*: Loss of sensory function in patients with idiopathic hand dystonia. *Mov Disord*. 2011; **26**(1): 107–13.
[PubMed Abstract](#) | [Publisher Full Text](#)
73. Paracka L, Wegner F, Blahak C, *et al.*: Sensory Alterations in Patients with Isolated Idiopathic Dystonia: An Exploratory Quantitative Sensory Testing Analysis. *Front Neurol*. 2017; **8**: 553.
[PubMed Abstract](#) | [Publisher Full Text](#) | [Free Full Text](#) | [F1000 Recommendation](#)
74. Tinazzi M, Valeriani M, Squintani G, *et al.*: Nociceptive pathway function is normal in cervical dystonia: a study using laser-evoked potentials. *J Neurol*. 2012; **259**(10): 2060–6.
[PubMed Abstract](#) | [Publisher Full Text](#)
75. Tinazzi M, Squintani GM, Bhatia KP, *et al.*: Pain in cervical dystonia: Evidence of abnormal inhibitory control. *Parkinsonism Relat Disord*. 2019; **65**: 252–5.
[PubMed Abstract](#) | [Publisher Full Text](#) | [F1000 Recommendation](#)
76. Holdsworth SJ, Bammer R: Magnetic resonance imaging techniques: fMRI, DWI, and PWI. *Semin Neurol*. 2008; **28**(4): 395–406.
[PubMed Abstract](#) | [Publisher Full Text](#) | [Free Full Text](#)
77. Fox MD, Greicius M: Clinical applications of resting state functional connectivity. *Front Syst Neurosci*. 2010; **4**: 19.
[PubMed Abstract](#) | [Publisher Full Text](#) | [Free Full Text](#)
78. Smitha KA, Akhil Raja K, Arun KM, *et al.*: Resting state fMRI: A review on methods in resting state connectivity analysis and resting state networks. *Neuroradiol J*. 2017; **30**(4): 305–17.
[PubMed Abstract](#) | [Publisher Full Text](#) | [Free Full Text](#) | [F1000 Recommendation](#)
79. Zoons E, Booij J, Nederveen AJ, *et al.*: Structural, functional and molecular imaging of the brain in primary focal dystonia—a review. *Neuroimage*. 2011; **56**(3): 1011–20.
[PubMed Abstract](#) | [Publisher Full Text](#)
80. Peller M, Zeuner KE, Munchau A, *et al.*: The basal ganglia are hyperactive during the discrimination of tactile stimuli in writer's cramp. *Brain*. 2006; **129**(Pt 10): 2697–708.
[PubMed Abstract](#) | [Publisher Full Text](#)
81. Butterworth S, Francis S, Kelly E, *et al.*: Abnormal cortical sensory activation in dystonia: an fMRI study. *Mov Disord*. 2003; **18**(6): 673–82.
[PubMed Abstract](#) | [Publisher Full Text](#)
82. Nelson AJ, Blake DT, Chen R: Digit-specific aberrations in the primary somatosensory cortex in Writer's cramp. *Ann Neurol*. 2009; **66**(2): 146–54.
[PubMed Abstract](#) | [Publisher Full Text](#)
83. Castrop F, Dresel C, Hennenlotter A, *et al.*: Basal ganglia-premotor dysfunction during movement imagination in writer's cramp. *Mov Disord*. 2012; **27**(11): 1432–9.
[PubMed Abstract](#) | [Publisher Full Text](#)
84. Kimberley TJ, Pickett KA: Differential activation in the primary motor cortex during individual digit movement in focal hand dystonia vs. healthy. *Restor Neurol Neurosci*. 2012; **30**(3): 247–54.
[PubMed Abstract](#) | [Publisher Full Text](#)
85. Moore RD, Gallea C, Horovitz SG, *et al.*: Individuated finger control in focal hand dystonia: an fMRI study. *Neuroimage*. 2012; **61**(4): 823–31.
[PubMed Abstract](#) | [Publisher Full Text](#) | [Free Full Text](#)
86. Gallea C, Horovitz SG, Najee-Ullah M, *et al.*: Impairment of a parieto-premotor network specialized for handwriting in writer's cramp. *Hum Brain Mapp*. 2016; **37**(12): 4363–75.
[PubMed Abstract](#) | [Publisher Full Text](#) | [Free Full Text](#)
87. Zeuner KE, Knutzen A, Granert O, *et al.*: Altered brain activation in a reversal learning task unmasks adaptive changes in cognitive control in writer's cramp. *Neuroimage Clin*. 2015; **10**: 63–70.
[PubMed Abstract](#) | [Publisher Full Text](#) | [Free Full Text](#)
88. Jankowski J, Paus S, Scheef L, *et al.*: Abnormal movement preparation in task-specific focal hand dystonia. *PLoS One*. 2013; **8**(10): e78234.
[PubMed Abstract](#) | [Publisher Full Text](#) | [Free Full Text](#)
89. Prudente CN, Stilla R, Singh S, *et al.*: A Functional Magnetic Resonance Imaging Study of Head Movements in Cervical Dystonia. *Front Neurol*. 2016; **7**: 201.
[PubMed Abstract](#) | [Publisher Full Text](#) | [Free Full Text](#)
90. Burciu RG, Hess CW, Coombes SA, *et al.*: Functional activity of the sensorimotor cortex and cerebellum relates to cervical dystonia symptoms. *Hum Brain Mapp*. 2017; **38**(9): 4563–73.
[PubMed Abstract](#) | [Publisher Full Text](#) | [Free Full Text](#) | [F1000 Recommendation](#)
91. Filip P, Gallea C, Lehericy S, *et al.*: Disruption in cerebellar and basal ganglia networks during a visuospacial task in cervical dystonia. *Mov Disord*. 2017; **32**(5): 757–68.
[PubMed Abstract](#) | [Publisher Full Text](#) | [F1000 Recommendation](#)
92. Mc Govern EM, Killian O, Narasimham S, *et al.*: Disrupted superior collicular activity may reveal cervical dystonia disease pathomechanisms. *Sci Rep*. 2017; **7**(1): 16753.
[PubMed Abstract](#) | [Publisher Full Text](#) | [Free Full Text](#) | [F1000 Recommendation](#)
93. Langbour N, Michel V, Dilharreguy B, *et al.*: The Cortical Processing of Sensorimotor Sequences is Disrupted in Writer's Cramp. *Cereb Cortex*. 2017; **27**(4): 2544–59.
[PubMed Abstract](#) | [Publisher Full Text](#) | [F1000 Recommendation](#)
94. Damoiseaux JS, Rombouts SA, Barkhof F, *et al.*: Consistent resting-state networks across healthy subjects. *Proc Natl Acad Sci U S A*. 2006; **103**(37): 13848–53.
[PubMed Abstract](#) | [Publisher Full Text](#) | [Free Full Text](#)
95. Fox MD, Marcus DM, Snyder AZ, *et al.*: "BrainSCAPE: an online spontaneous correlation analysis processing environment for fMRI BOLD data," in Organization for Human Brain Mapping Annual Meeting, Chicago, IL. 2007.
96. Biswal B, Yetkin FZ, Haughton VM, *et al.*: Functional connectivity in the motor cortex of resting human brain using echo-planar MRI. *Magn Reson Med*. 1995; **34**(4): 537–41.
[PubMed Abstract](#) | [Publisher Full Text](#) | [F1000 Recommendation](#)
97. Chen K, Azeez A, Chen DY, *et al.*: Resting-State Functional Connectivity: Signal Origins and Analytic Methods. *Neuroimaging Clin N Am*. 2020; **30**(1): 15–23.
[PubMed Abstract](#) | [Publisher Full Text](#)
98. de Figueiredo EH, Borgonovi AF, Doring TM: Basic concepts of MR imaging, diffusion MR imaging, and diffusion tensor imaging. *Magn Reson Imaging Clin N Am*. 2011; **19**(1): 1–22.
[PubMed Abstract](#) | [Publisher Full Text](#)
99. Viallon M, Cuvinciu V, Delattre B, *et al.*: State-of-the-art MRI techniques in neuroradiology: principles, pitfalls, and clinical applications. *Neuroradiology*. 2015; **57**(5): 441–67.
[PubMed Abstract](#) | [Publisher Full Text](#)
100. Huang XF, Zhu MR, Shan P, *et al.*: Multiple Neural Networks Malfunction in Primary Blepharospasm: An Independent Components Analysis. *Front Hum Neurosci*. 2017; **11**: 235.
[PubMed Abstract](#) | [Publisher Full Text](#) | [Free Full Text](#) | [F1000 Recommendation](#)
101. Wei J, Wei S, Yang R, *et al.*: Voxel-Mirrored Homotopic Connectivity of Resting-State Functional Magnetic Resonance Imaging in Blepharospasm. *Front Psychol*. 2018; **9**: 1620.
[PubMed Abstract](#) | [Publisher Full Text](#) | [Free Full Text](#) | [F1000 Recommendation](#)

102. **F** Ni MF, Huang XF, Miao YW, *et al.*: **Resting state fMRI observations of baseline brain functional activities and connectivities in primary blepharospasm.** *Neurosci Lett.* 2017; **660**: 22–8.
[PubMed Abstract](#) | [Publisher Full Text](#) | [F1000 Recommendation](#)
103. **F** Haslinger B, Noé J, Altenmüller E, *et al.*: **Changes in resting-state connectivity in musicians with embouchure dystonia.** *Mov Disord.* 2017; **32**(3): 450–8.
[PubMed Abstract](#) | [Publisher Full Text](#) | [F1000 Recommendation](#)
104. **F** Li Z, Prudente CN, Stilla R, *et al.*: **Alterations of resting-state fMRI measurements in individuals with cervical dystonia.** *Hum Brain Mapp.* 2017; **38**(8): 4098–108.
[PubMed Abstract](#) | [Publisher Full Text](#) | [Free Full Text](#) | [F1000 Recommendation](#)
105. Lee MH, Smyser CD, Shimony JS: **Resting-state fMRI: a review of methods and clinical applications.** *AJNR Am J Neuroradiol.* 2013; **34**(10): 1866–72.
[PubMed Abstract](#) | [Publisher Full Text](#) | [Free Full Text](#)
106. Moussa MN, Steen MR, Laurienti PJ, *et al.*: **Consistency of network modules in resting-state fMRI connectome data.** *PLoS One.* 2012; **7**(8): e44428.
[PubMed Abstract](#) | [Publisher Full Text](#) | [Free Full Text](#)
107. De Luca M, Beckmann CF, De Stefano N, *et al.*: **fMRI resting state networks define distinct modes of long-distance interactions in the human brain.** *NeuroImage.* 2006; **29**(4): 1359–67.
[PubMed Abstract](#) | [Publisher Full Text](#)
108. **F** Doucet G, Naveau M, Petit L, *et al.*: **Brain activity at rest: a multiscale hierarchical functional organization.** *J Neurophysiol.* 2011; **105**(6): 2753–63.
[PubMed Abstract](#) | [Publisher Full Text](#) | [F1000 Recommendation](#)
109. **F** Battistella G, Termsarasab P, Ramdhani RA, *et al.*: **Isolated Focal Dystonia as a Disorder of Large-Scale Functional Networks.** *Cereb Cortex.* 2017; **27**(2): 1203–15.
[PubMed Abstract](#) | [Publisher Full Text](#) | [Free Full Text](#) | [F1000 Recommendation](#)
110. Mori S, Zhang J: **Principles of diffusion tensor imaging and its applications to basic neuroscience research.** *Neuron.* 2006; **51**(5): 527–39.
[PubMed Abstract](#) | [Publisher Full Text](#)
111. Beaulieu C, Allen PS: **Determinants of anisotropic water diffusion in nerves.** *Magn Reson Med.* 1994; **31**(4): 394–400.
[PubMed Abstract](#) | [Publisher Full Text](#)
112. Alexander AL, Lee JE, Lazar M, *et al.*: **Diffusion tensor imaging of the brain.** *Neurotherapeutics.* 2007; **4**(3): 316–29.
[PubMed Abstract](#) | [Publisher Full Text](#) | [Free Full Text](#)
113. Colosimo C, Pantano P, Calistri V, *et al.*: **Diffusion tensor imaging in primary cervical dystonia.** *J Neurol Neurosurg Psychiatry.* 2005; **76**(11): 1591–3.
[PubMed Abstract](#) | [Publisher Full Text](#) | [Free Full Text](#)
114. Fabbrini G, Pantano P, Totaro P, *et al.*: **Diffusion tensor imaging in patients with primary cervical dystonia and in patients with blepharospasm.** *Eur J Neurol.* 2008; **15**(2): 185–9.
[PubMed Abstract](#) | [Publisher Full Text](#)
115. **F** Berman BD, Honce JM, Shelton E, *et al.*: **Isolated focal dystonia phenotypes are associated with distinct patterns of altered microstructure.** *Neuroimage Clin.* 2018; **19**: 805–12.
[PubMed Abstract](#) | [Publisher Full Text](#) | [Free Full Text](#) | [F1000 Recommendation](#)
116. **F** Bianchi S, Battistella G, Huddleston H, *et al.*: **Phenotype- and genotype-specific structural alterations in spasmodic dysphonia.** *Mov Disord.* 2017; **32**(4): 560–8.
[PubMed Abstract](#) | [Publisher Full Text](#) | [Free Full Text](#) | [F1000 Recommendation](#)
117. **F** Kirke DN, Battistella G, Kumar V, *et al.*: **Neural correlates of dystonic tremor: a multimodal study of voice tremor in spasmodic dysphonia.** *Brain Imaging Behav.* 2017; **11**(1): 166–75.
[PubMed Abstract](#) | [Publisher Full Text](#) | [Free Full Text](#) | [F1000 Recommendation](#)

Open Peer Review

Current Peer Review Status:  

Editorial Note on the Review Process

F1000 Faculty Reviews are written by members of the prestigious F1000 Faculty. They are commissioned and are peer reviewed before publication to ensure that the final, published version is comprehensive and accessible. The reviewers who approved the final version are listed with their names and affiliations.

The reviewers who approved this article are:

Version 1

1 **Martin Bareš**

¹ Department of Neurology, Faculty of Medicine, Masaryk University and St. Anne's University Hospital Brno, Brno, Czech Republic

² Department of Neurology, School of Medicine, University of Minnesota, Minneapolis, USA

Pavel Filip

Department of Neurology, Faculty of Medicine, Masaryk University and St. Anne's University Hospital Brno, Brno, Czech Republic

Competing Interests: No competing interests were disclosed.

2 **Aasef G Shaikh**

¹ Department of Neurology, Case Western University School of Medicine, Cleveland, OH, USA

² Neurological Institute, University Hospitals, Cleveland, OH, USA

Competing Interests: No competing interests were disclosed.

The benefits of publishing with F1000Research:

- Your article is published within days, with no editorial bias
- You can publish traditional articles, null/negative results, case reports, data notes and more
- The peer review process is transparent and collaborative
- Your article is indexed in PubMed after passing peer review
- Dedicated customer support at every stage

For pre-submission enquiries, contact research@f1000.com

F1000Research