

Plasma Cell Mastitis in Men: A Single-center Experience and Review of the Literature

ANDREA PALMIERI¹, VALERIO D'ORAZI², GIOVANNI MARTINO¹, FEDERICO FRUSONE¹, DANIELE CROCETTI³, MARIA IDA AMABILE¹ and MARCO MONTI⁴

¹Department of Surgical Sciences, ³Pietro Valdoni Department of Surgery, and

⁴Department of Gynecological, Obstetrics and Urologic Sciences, Sapienza University of Rome, Rome, Italy;

²Department of General Microsurgery and Hand Surgery, Fabia Mater Hospital, Rome, Italy

Abstract. *Plasma cell mastitis is an inflammatory disease of the breast parenchyma, rare in males. In the last 40 years, few cases have been described in literature. Our recent treatment of male patients affected by plasma cell mastitis raised a series of issues which led us to carry out a critical review of the literature. Plasma cell mastitis is often not well defined and is difficult to assess by clinical examination and radiological investigation alone. An understanding of the pathogenesis and the mechanisms behind plasma cell mastitis may help improve the diagnostic and therapeutic course of the disease, leading to a more targeted and less invasive treatment.*

Plasma cell mastitis is an inflammatory disease of the breast parenchyma, frequent in females, characterized by a periductal phlogistic reaction, accompanied by ductal ectasia. It was described for the first time by Burkitt in 1850 (1). In the literature, this disease is also known as granulomatous mastitis, obstructing mastitis, comedo mastitis (2), periductal mastitis (3, 4), and mammary duct ectasia (5-7). Plasma cell mastitis is more frequent in young women and in women who have not had pregnancy nor breastfed (8). It is characterized by occasional mastodynia with ductal ectasia and usually presents as a retroareolar lump with inverted nipple and secretions. The most common complication is the onset of a fistula (7). The first case of plasma cell mastitis

in men was documented in 1974 by Tedeschi and Mc Carthy (9). Our recent observation and treatment of male patients affected by plasma cell mastitis raised a series of diagnostic, etiological and therapeutic issues persuading us to carry out a critical review of the literature.

Our Single-center Experience

Out of a total of 411 breast surgeries performed between 2011 and 2015 at the Department of Surgical Sciences, Sapienza University of Rome, Italy, we recorded six cases of breast surgeries in men (1.46% of the total). In three cases out of these six (0.73% of the total), the final histological diagnosis was gynecomastia, in one case it was ductal carcinoma, and in two cases (0.48% of the total) the final histological diagnosis was plasma cell mastitis.

The first case of plasma cell mastitis concerned a 56-year-old man who complained of the appearance of a hard retroareolar lump, with smooth edges, which was quite painful, and without nipple secretions. A bilateral breast ultrasound examination was performed which showed a solid, non-homogeneous lesion, with irregular edges and diameter of 17 mm (Figure 1). An ultrasound-assisted core biopsy was performed due to suspicion of a neoplastic lesion, with the aim of characterizing the lesion. The histological examination revealed intense chronic inflammation, mostly plasmacellular, and focal steatonecrosis, without neoplastic cells. Therefore, the patient did not undergo surgery. An appropriate anti-inflammatory therapy was performed and the patient healed in about 3 weeks. At further follow-up evaluation, no signs of breast disease were observed, as previously described (10).

The second case concerned an otherwise healthy 76-year-old man who reported the presence of a hard retroareolar lump, which was quite painful, without nipple secretions. The breast ultrasound examination showed a hypochoic lesion with poorly defined edges and perilesional/ intralesional

This article is freely accessible online.

Correspondence to: Maria Ida Amabile, MD, Ph.D., Department of Surgical Sciences Sapienza University of Rome, Viale Regina Elena 324, 00161 Rome, Italy. Tel/Fax: +39 0649972449, e-mail: marida.amabile@gmail.com

Key Words: Plasma cell mastitis, male breast, periductal phlogistic reaction, review.

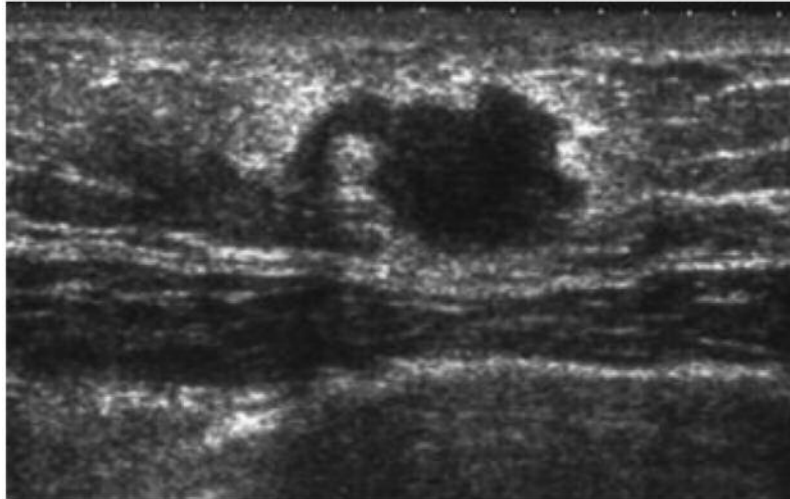


Figure 1. Ultrasound examination of the left breast revealing the presence of a retroareolar solid lump with a diameter of approximately 17 mm.

vascularization. Ultrasound-assisted fine-needle aspiration cytology obtained hematic material which was not useful in diagnosis. The patient refused any other invasive investigations and an excisional open biopsy was performed by periareolar access, without the need to position a metallic guide wire, as it is necessary instead in cases of female breast lesions with similar dimensions and characteristics (11). Entire excision of the lump was carried out. The postoperative definitive histological examination documented a diagnosis of plasma cell mastitis. No further therapies were necessary.

In both cases, further investigations were accomplished in order to exclude plasma cell mastitis as being an epiphenomenon of an unknown autoimmune disease. The immunological profile was within the normal range in both cases.

Review of the Literature

Plasma cell mastitis is a disease relatively common in women, but quite rare in men. This is probably why between 1974 and 2016, only 14 cases have been described in the literature, as can be seen in Table I.

The first case of plasma cell mastitis described in a man dates back to 1974, and referred to a 57-year-old man with a lump of the left breast, who underwent a simple mastectomy (9). In 1979, Mansel and Morgan documented three cases of plasma cell mastitis (12). In the first, a breast lump with inverted nipple and secretion was treated with an attempt at drainage and, subsequently, with a total ductectomy. In the second case, the patient had recurrent abscesses of the right breast that were treated initially with a ductectomy, and then with a simple mastectomy (12). In the third case, a breast lump was treated with subcutaneous mastectomy and excision

of the terminal ducts (12). In 1984, Chan and Lau described the case of a patient who had a breast lump treated with excision of the nodule (13), and in 1985 Ashworth *et al.* presented a similar case, but treated with excision of the major ducts (14). In 1996, Downs and Fisher described two cases of breast lumps in human immunodeficiency virus-positive patients, the first treated with excisional biopsy, while the second with antibiotic therapy (15). In 2001, Al-Masad documented two cases treated with excisional biopsy, one of which was concomitant with Behçet's disease, suggesting that some cases of plasma cell mastitis are a sign of an underlying autoimmune disease (16). In 2005, Reddy *et al.* described the case of a man with a retroareolar breast lump who underwent a fine-needle aspiration and, subsequently, an excisional biopsy (17). In 2011, Gupta *et al.* treated a man with a breast lump, which was initially thought to be a lobular carcinoma, after cytological examination by means of fine-needle aspiration, and therefore treated with a simple mastectomy (18). The definitive histological examination, however, showed the presence of plasma cell mastitis, as in all of the previous cases. In the case dating back to 2012, described by Kim *et al.*, a documented retroareolar breast lump in a 37-year-old man was hypothesized to be breast carcinoma (19). The patient underwent mammography, breast ultrasound, and subsequently an ultrasound-guided biopsy, the histological examination of which gave a diagnosis of plasma cell mastitis.

Discussion

It is difficult to differentiate between plasma cell mastitis, described for the first time during the last century (1) and later better defined by Bloodgood in 1921 (20) and by

Table I. Literature review and patient characteristics.

Author (Ref)	Cases	Patient	Diagnostic procedure	Histology	Therapy
Tedeschi and Mc Carthy (1 case) (9)	Case 1	57-Year-old man with left breast lump	Excisional biopsy	Chronic inflammatory infiltrate; lymphocytes and plasma cells with desquamation of the duct epithelium	Simple mastectomy
Mansel and Morgan (3 cases) (12)	Case 2	62-Year-old man with left breast nodule, inverted nipples and discontinuous secretion	Mammography, biopsy, microbial cultural examination of the secretion	Bilateral chronic inflammatory infiltrate with abscess evolution	Bilateral drainage of the breast abscess with total ductectomy
	Case 3	47-Year-old man with recurrent right breast abscesses	Cytological examination of nipple secretion, biopsy	Chronic inflammatory infiltrate with marked focal granulomatous reaction	Drainage of the abscess, total duct excision, repeated incisions and drainage, simple mastectomy
	Case 4	52-Year-old man with left breast lump	Cytological examination of nipple secretion, biopsy	Chronic inflammatory infiltrate	Subcutaneous mastectomy with terminal duct excision
Chan and Lau (1 case) (13)	Case 5	34-Year-old man with right breast lump	Biopsy	Inflammatory infiltrate with lymphocytes and plasma cells	Excision of the nodule
Ashworth <i>et al.</i> (1 case) (14)	Case 6	50-Year-old man with right breast lump	Mammography, biopsy	Inflammatory infiltrate with lymphocytes and plasma cells	Excision of the major ducts
Downs <i>et al.</i> (2 cases) (15)	Case 7	30-Year-old HIV-positive man with right breast lump and nipple secretion	Fine-needle aspiration cytology, cytological examination of nipple secretion, biopsy	Mostly plasmacellular chronic inflammatory infiltrate	Excisional biopsy
	Case 8	44-Year-old HIV-positive man with right breast lump and nipple secretion	Cytological examination of nipple secretion, biopsy	Dilated ducts with scattered granulomatous inflammation foci	Antibiotic treatment (amoxicillin and flucloxacillin)
Al-Masad (2 cases) (16)	Case 9	23-Year-old man suffering from Behçet's disease, with hematic secretions from the right nipple	Cytological examination of nipple secretion, mammography, core biopsy	Dilated ducts full of secretions and macrophages, surrounded by fibrosis and inflammatory infiltrate	Total duct excision
	Case 10	50-Year-old man with right breast lump	Fine-needle aspiration cytology, mammography, core biopsy	Abscess cavity; duct dilation; mononuclear inflammatory infiltrate	Pharmacological treatment, total duct excision
Reddy <i>et al.</i> (1 case) (17)	Case 11	47-Year-old man with subareolar lump of right breast	Mammography, fine-needle aspiration cytology	Chronic inflammation with granulocytes, giant cells and cellular debris	Excisional biopsy
Gupta <i>et al.</i> (1 case) (18)	Case 12	47-Year-old man with left breast lump	Fine-needle aspiration cytology, core biopsy	Chronic inflammation with ductal hyperplasia	Total mastectomy
Pasta <i>et al.</i> (1 case) (10)	Case 13	56-Year-old man with palpable retroareolar lump of left breast	Ultrasound, core biopsy	Plasmacellular chronic inflammation, together with focal steatonecrosis	Pharmacological treatment
Kim <i>et al.</i> (1 case) (19)	Case 14	37-Year-old man with subareolar lump of left breast	Mammography, ultrasound, core biopsy	Chronic inflammation with fibrosis and plasma cell infiltration	Excisional biopsy

Table II. Signs and symptoms of plasma cell mastitis as reported in the literature cited in Table I.

Case	Palpable mass	Pain	Erythema	Nipple secretion	Recurring abscess	Inverted nipple
1	X					
2	X			X		X
3					X	
4	X					
5	X	X				X
6	X	X	X			
7	X			X		
8	X			X		
9				X		
10	X	X				
11	X					
12	X					
13	X	X				
14	X	X				X

Haagensen in 1951 (5), and other forms of mastitis (21). It is usually unilateral, but can also affect the mammary gland bilaterally or supernumerary breasts (22, 23). The onset of plasma cell mastitis is aspecific, generally characterized by the appearance of a painful retroareolar lump, with inverted nipple, nipple secretion, and possible onset of fistulas (2, 3).

Despite evolution in diagnostic radiology, a protocol for diagnosis and treatment of plasma cell mastitis still has not been defined (21, 24). In addition, the rarity of plasma cell mastitis in men and in its clinical expression as a retroareolar lump is not widely acknowledged. Infrequently, it can be associated with skin erythema, mastodynia, and recurring abscesses. The presence of nipple serum-hematic secretions leads to the need for differential diagnosis from other benign breast diseases, such as aspecific or tuberculous mastitis (25), and from malignant breast diseases such as comedocarcinoma or retroareolar carcinoma (7, 12).

In our review of the literature (Table II), we consistently found a palpable mass to be a sign of plasma cell mastitis: 11 cases out of 14 (78.6%) presented with unilateral or bilateral palpable mass. Less common symptoms were: nipple secretion, pain (both found in four cases out of 14, therefore 28.6%), inverted nipple (in three cases out of 14, 21.4%), recurring abscesses and erythema. Ming *et al.* found that inverted nipple is very common in women suffering from plasma cell mastitis, whereas it is not very common in men (7). After physical examination, useful instrumental investigations are ultrasound examination, mammography and core biopsy.

In 1979 Mansel and Morgan asserted that in mammographic examination (which is difficult to perform in men), plasma cell mastitis exhibits a density indistinguishable from gynecomastia, and sometimes also from carcinoma (12).

Bilateral stick-like microcalcifications, usually symmetric and radially oriented to the nipple-areolar complex, can also be found (21). These microcalcifications can suggest differential diagnosis from breast carcinoma (26). Less common mammographic characteristics in mastitis are: denser symmetric areas, poorly defined masses and architectural disorders (21). Breast ultrasound examination is reportedly not very sensitive for the diagnosis of plasma cell mastitis, since it can reveal a hypoechogenic heterogeneous lesion or the appearance of a normal gland. Nevertheless, it is a necessary examination in the study of the male breast (21, 27). Between 1998 and 2003, Janes *et al.* found that breast core biopsy plays a predominant role in the diagnosis of unilateral breast lumps in men (28). They performed an average of two core biopsy samplings per male patient aged between 40 and 70 years old with unilateral breast lesion, and diagnosed 105 cases of true gynecomastia (93%), two of breast cancer, one of chronic mastitis and one of breast-metastatic head and neck lymphoma (28). Core biopsy, compared with fine-needle aspiration cytology, is more sensitive and specific in the evaluation of breast lesions in men (29). It allows a differential diagnosis between mastitis, gynecomastia and malignant neoplasia, and steers the clinician towards a correct therapeutic approach. In fact, as it can be seen from clinical case number 11 (Table II), fine-needle aspiration cytology does not allow differential diagnosis between plasma cell mastitis and lobular carcinoma, leading to overtreatment, consisting of radical surgery, compared to that to the correct disease (18).

In fact, in the majority of cases, plasma cell mastitis can be treated in a conservative manner (surgical drainage and antibiotic therapy) or with surgical duct excision (7). Rarely is a total mastectomy indicated, when the differential diagnosis between mastitis and carcinoma is uncertain (18).

In cases of recurring abscesses or fistulas, the treatment for plasma cell mastitis depends on the physiopathology of the abscess. If it comes from a duct, the treatment consists in the excision of the fistula as described by Atkins (30), whereas the treatment should be total excision of the ducts if the abscess arises from multiple ducts as described by Hadfield (31). From the microstructural point of view, plasma cell mastitis in men presents the same sequence of four lesions of periductal mastitis in females, described by Azzopardi in 1979 (24) and by Dixon *et al.* in 1989 (32), which are: ductal inflammation, resolution of inflammation, ductal fibrosis, and ductal dilatation.

During the active phase of the disease, the patient suffers from ductal dilatation (comprising lipids, cellular debris and foam cells), ductal obliteration with fibrous tissue, and the flattening and disappearance of ductal epithelium because of desquamation, with destruction of the sustaining elastic lamina (12). There is also a dense periductal inflammatory infiltrate produced by lymphocytes, neutrophils, foam cells and several plasma cells. Sometimes fistulas and initially sterile abscesses undergo bacterial super-infection after surgical incision (7). The histological pattern can help to differentiate plasma cell mastitis from other forms of mastitis, such as tuberculous mastitis characterized by caseous necrosis and acid-alcohol-resistant bacillus (25), and from neoplastic lesions. We recommend carrying out a microbiological culture examination before performing surgery, even if sometimes there is no bacterial contamination. It is clear that plasma cell mastitis is often not well defined and is difficult to assess by clinical diagnostics and radiological imaging alone (21). Therefore there is the risk of overtreatment, even though plasma cell mastitis can regress with a conservative approach.

An understanding of the pathogenesis and the mechanisms at the root of plasma cell mastitis may help to improve the diagnostic-therapeutic course of the disease, leading to a more targeted and less invasive diagnostic protocol. Many authors suggested different pathogenetic hypotheses. According to Bundred (33) and Furlong *et al.* (34), this disease is strictly associated with cigarette smoking (33, 34). Combustion products and other toxic metabolites produced by cigarette smoke (*e.g.* nicotine and cotinine) may damage ducts, liberate reactive oxygen intermediates and activate enzymes such as cyclo-oxygenase and peroxidase, leading to inflammatory mechanisms (33-35). It has been hypothesized that the pro-inflammatory mechanisms may originate from an inverted nipple in most cases, which leads to the occlusion and subsequent dilatation of the major breast ducts with obstacle to secretions, chronic inflammation and activation of an autoimmune response with massive plasma cell infiltration (7). More precisely, according to Liu *et al.*, the occlusion of the major breast ducts, secondary to inverted nipple, may lead to

increased expression of the pro-inflammatory cytokine interleukin-6, with subsequent activation of signal transducer and activator of transcription-3 protein, responsible for B-cell chemotaxis in the onset of the signal pathway for differentiation in plasma cells and inhibition of apoptosis, leading to chronic inflammation and to the typical histopathological picture of plasma cell mastitis (36). In support to this, Ming *et al.* postulated autoimmune mechanisms in inflammatory pathogenesis after observing how the injection of plasma cell mastitis cells into a healthy mouse led to development of the same disease in the animal (7).

Conclusion

Plasma cell mastitis is rare in men (8), but its true incidence is uncertain because few data are available in the literature on this topic. Issues concerning the disease's etiopathogenesis hypothesize the connection between plasma cell mastitis and immune system disorders such as Behçet's disease and Wegener's granulomatosis (8, 10). Moreover, the autoimmune hypothesis could explain the cases in which there is a relapse of the disease after treatment. Therefore, autoimmunity could be central to the pathogenesis of plasma cell mastitis in both genders, but in women the causes can be many (also because of anatomical and physiological reasons), whereas in men they are represented by chronic diseases with an autoimmune component, be it metabolic (*e.g.* diabetes mellitus) or primarily linked to autoimmune disorders such as Behçet's disease. Nevertheless, our patients did not suffer from any documented immune system disease. Therefore, a pre-surgical diagnosis based on breast ultrasound and echo-assisted core biopsy maintains an important role, and patients who need surgery are only those affected by dubious lesions, and those in which recurring infection necessitates an excision of the phlogystic tissue.

Disclosure

The Authors have stated that they have no conflicts of interest in regard to this article.

References

- 1 Birkett J: The Diseases of the Breast, and Their Treatment: Longman, Brown, Green, and Longmans (eds), London, pp. 64-92, 1850.
- 2 Tice GI, Dockerty MB and Harrington SW: Comedo mastitis. A clinical and pathological study of data in 172 cases. *Surg Gynecol Obstet* 87: 525-540, 1948.
- 3 Foote FW and Stewart FW: Comparative studies of cancerous *versus* noncancerous breasts. *Ann Surg* 121: 197-222, 1945.
- 4 Geschickter CF: Diseases of the Breast, Philadelphia, Lippincott, 1948.
- 5 Haagensen CD: Mammary duct ectasia: A disease that may simulate carcinoma. *Cancer* 4: 749-761, 1951.

- 6 Yu JJ, Bao SL, Yu SL, Zhang DQ, Loo WT, Chow LW, Su L, Cui Z, Chen K, Ma LQ, Zhang N, Yu H, Yang YZ, Dong Y, Yip AY and Ng EL: Mouse model of plasma cell mastitis. *J Transl Med* 10: S11, 2012.
- 7 Ming J, Meng G, Yuan Q, Zhong L, Tang P, Zhang K, Chen Q, Fan L and Jiang J: Clinical characteristics and surgical modality of plasma cell mastitis: analysis of 91 cases. *Am Surg* 79: 54-60, 2013.
- 8 Allende DS and Booth CN: Wegener's granulomatosis of the breast: a rare entity with daily clinical relevance. *Ann Diagn Pathol* 13: 351-357, 2009.
- 9 Tedeschi LG and Mc Carthy PE: Involutional mammary duct ectasia and periductal mastitis in a male. *Hum Pathol* 5: 232-236, 1974.
- 10 Pasta V, Urcioli P, D'Orazi V, Sottile D, Merola R, Vergine M, Malavenda MS and Monti M: Plasma cell mastitis in males: a review of the literature. *G Med Mil* 162: 205-212, 2012.
- 11 Tardioli S, Ballesio L, Gigli S, Di Pastena F, D'Orazi V, Giraldi G, Monti M, Amabile MI and Pasta V: Wire-guided localization in non-palpable breast cancer: results from monocentric experience. *Anticancer Res* 36: 2423-2427, 2016.
- 12 Mansel RE and Morgan WP: Duct ectasia in the male. *Br J Surg* 66: 605-606, 1979.
- 13 Chan KW and Lau WY: Duct ectasia in the male breast. *Aust N Z J Surg* 54: 173-176, 1984.
- 14 Ashworth MT, Corcoran GD and Haqqani MT: Periductal mastitis and mammary duct ectasia in a male. *Postgrad Med J* 61: 621-623, 1985
- 15 Downs AMR and Fisher M: Male duct ectasia associated with HIV infection. *Genitourin Med* 72: 65-66, 1996
- 16 Al-Masad JK: Mammary duct ectasia and periductal mastitis in males. *Saudi Med J* 22: 1030-1033, 2001.
- 17 Reddy KM, Meyer CE, Nakdjevani A and Shrotria S: Idiopathic granulomatous mastitis in the male breast. *Breast J* 11: 73, 2005.
- 18 Gupta N, Agrawal P, Saikia UN, Das A, Srinivasan R, Rajwanshi A and Singh G: Periductal mastitis in a male breast masquerading as lobular carcinoma on fine needle aspiration cytology. *Diagn Cytopathol* 40: 455-458, 2012.
- 19 Kim BS, Lee JH, Kim WJ, Kim DC, Shin S, Kwon HJ, Park JS and Park YM: Periductal mastitis mimicking breast cancer in a male breast. *Clin Imaging* 37: 574-576, 2013.
- 20 Bloodgood LE: The pathology of chronic cystic mastitis of the female breast with special consideration of the blue domed cyst. *Arch Surg* 3: 445, 1921.
- 21 Tan H, Li R, Peng W, Liu H, Gu Y and Shen X: Radiological and clinical features of adult non-puerperal mastitis. *Br J Radiol* 86: 20120657, 2013.
- 22 Pasta V, Urcioli P, Chiarini S, Vergine M, Favoriti N, Santucci E, Giofrè M and Monti M: Ectopic breast tissue and a carcinoma in atypical positions. *Ann Ital Chir* 80: 389-394, 2009.
- 23 Pasta V, Martino G, Vergine M, Scipioni P, Amabile MI, Cardarelli A, Palmieri A, Santucci E, Chiarini S and Monti M: Diagnostic and surgical problems of ectopic breast cancer. *G Chir* 30: 36-40, 2009.
- 24 Azzopardi JG: *Problems in Breast Pathology*. WB Saunders, London, pp. 72-87, 1979.
- 25 Rajagopala S and Agarwal R: Tubercular mastitis in men: case report and systematic review. *Am J Med* 121: 539-544, 2008.
- 26 Amabile MI, Mazouni C, Guimond C, Sarfati B, Leymarie N, Cloutier AS, Bentivegna E, Garbay JR, Kolb F and Rimareix F: Factors predictive of re-excision after oncoplastic breast-conserving surgery. *Anticancer Res* 35: 4229-4234, 2015.
- 27 Chau A, Jafarian N and Rosa M: Male breast: clinical and imaging evaluations of benign and malignant entities with histologic correlation. *Am J Med* 129: 776-791, 2016.
- 28 Janes SE, Lengyel JA, Singh S, Aluwihare N and Isgar B: Needle core biopsy for the assessment of unilateral breast masses in men. *Breast* 15: 273-275, 2006.
- 29 Pailoor K, Fernandes H, Cs J, Marla NJ and Keshava SM: Fine-needle aspiration cytology of male breast lesions – a retrospective study over a six-year period. *J Clin Diagn Res* 8: FC13-15, 2014.
- 30 Atkins HJ: Mammary fistula. *Br Med J* 2: 1473-1474, 1955.
- 31 Hadfield J: Excision of the major duct system for benign disease of the breast. *Br J Surg* 48: 472-477, 1960.
32. Dixon JM, Ravisekar O, Chetty U and Anderson TJ: Periductal mastitis and duct ectasia: different conditions with different aetiologies. *Br J Surg* 83: 820-822, 1996.
- 33 Bundred N: The cause and treatment of plasma cell mastitis. *Br J Surg* 81: 788-789, 1994.
- 34 Furlong AJ, al-Nakib L, Knox WF, Parry A and Bundred NJ: Periductal inflammation and cigarette smoke. *J Am Coll Surg* 179: 417-420, 1994.
- 35 Adair FR: Plasma cell mastitis, a lesion simulating mammary carcinoma. A clinical and pathological study with a report of ten cases. *Arch Surg* 29: 735, 1933.
- 36 Liu Y, Zhang J, Zhou YH, Jiang YN, Zhang W, Tang XJ, Ren Y, Han SP, Liu PJ, Xu J and He JJ: IL-6/STAT3 signaling pathway is activated in plasma cell mastitis. *Int J Clin Exp Pathol* 8: 12541-12548, 2015.
- 37 Hunfeld KP and Bassler R: Lymphocytic mastitis and fibrosis of the breast in long-standing insulindependent diabetics. A histopathologic study on diabetic mastopathy and report of ten cases. *Gen Diagn Pathol* 143: 49-58, 1997.

Received September 20, 2016

Revised October 11, 2016

Accepted October 14, 2016