

Contents lists available at [ScienceDirect](https://www.sciencedirect.com)

International Journal of Surgery Case Reports

journal homepage: www.casereports.com

Congenital diaphragmatic disease: An unusual presentation in adulthood. Case report

Angela Gurrado^{a,*}, Roberta Maria Isernia^a, Alessandro De Luca^a, Valentina Ferraro^a, Daniela Virgintino^b, Anna Napoli^c, Giuseppe Cavallaro^d, Eugenio Maiorano^c, Angela Pezzolla^e, Mario Testini^a

^a Department of Biomedical Sciences and Human Oncology, Unit of Endocrine, Digestive and Emergency Surgery, University Medical School “A. Moro”, Bari, Italy

^b Department of Basic Medical Sciences, Neurosciences, and Sensory Organs, Human Anatomy and Histology Unit, University Medical School “A. Moro”, Bari, Italy

^c Department of Pathology, University Medical School “A. Moro”, Bari, Italy

^d Department of Surgery “P. Valdoni”, Sapienza University, Rome, Italy

^e Department of Emergency and Organs Transplantation, University Medical School “A. Moro”, Bari, Italy

ARTICLE INFO

Article history:

Received 31 December 2017

Received in revised form 24 April 2018

Accepted 29 April 2018

Available online 7 May 2018

Keywords:

Case report

Congenital diaphragmatic disease

Diaphragmatic hernia

Toxic megacolon

ABSTRACT

INTRODUCTION: Congenital diaphragmatic disease is a quite common condition that usually occurs in the neonatal period, and the diagnosis of congenital diaphragmatic disease in adulthood is rare.

CASE PRESENTATION: A 64-years-old Caucasian woman was admitted in emergency at our Department, due to a bowel obstruction and dyspnea. A CT-scan showed a diaphragmatic herniation in the left area, with malposition of dilated transverse and descending colon in the chest. An emergency laparotomy was performed, showing a toxic megacolon, in the absence of a true diaphragmatic hernia, and a left diaphragm and left liver hypoplasia. An intraoperative bronchoscopy revealed concomitant hypoplasia of the left lung. A subtotal colectomy with ileo-rectal anastomosis was performed. The postoperative course was uneventful. Histological examination demonstrated hyperplasia of the *muscularis mucosae* of the colon and cytoplasmic vacuolization of the *Auerbach plexus ganglia*. The karyotype genetic analysis excluded concomitant microdeletion or duplication syndromes.

DISCUSSION: To our knowledge, this seems to be the first reported case of toxic megacolon in a patient with congenital hypoplasia of the left bronchial-lung system, of the left liver, and of the left diaphragm. **CONCLUSION:** The correct development of the diaphragm is essential for the neighboring organs. The observed clinical pattern could be related to a partial modification of neural crest cell detachment or migration, which could be responsible for bowel and diaphragm defects, even though it was not included in typical neural crest cell syndromes. Further researches should be performed in order to define the sporadic or syndromic source of these multiorgan defects.

© 2018 The Authors. Published by Elsevier Ltd on behalf of IJS Publishing Group Ltd. This is an open access article under the CC BY-NC-ND license (<http://creativecommons.org/licenses/by-nc-nd/4.0/>).

1. Introduction

Congenital diaphragmatic disease is a quite common condition that usually occurs in the neonatal period, with an incidence of less than one per 25,000 births [1]; therefore the diagnosis of congenital diaphragmatic disease in adulthood is rare. In some cases, congenital diaphragmatic disease can be a late presenting event (5–25%) [2], sometimes detected as an incidental findings by routine chest

x-ray or abdomen US. Usually, the diagnosis in adults is related to symptoms due to complications, such as respiratory failure, gastric volvulus, bowel occlusion, or perforation, with peritonitis or necrosis [3]. The survival of patients with the late-presenting congenital diaphragmatic disease showed a good outcomes [2], despite the prognosis may be compromised due to complications. Congenital diaphragmatic diseases are currently considered in one of several “classical” sites, such as postero-lateral (*Bochdalek*), anterior (*Morgagni*), and central and anterior (*Cantrell*) localizations [4].

To assess the genetic contribution of diaphragmatic defects is quite complex; even though the gene identification facilitates the understanding of the genotype framework and the phenotype outcome, the real pathogenetic pathways of congenital diaphragmatic disease is still largely unknown.

* Corresponding author at: Digestive and Emergency Surgery Unit, Department of Biomedical Sciences and Human Oncology, University of Bari, Policlinico of Bari, Piazza Giulio Cesare 11, 70124 Bari, Italy.

E-mail address: angelagurrado@libero.it (A. Gurrado).

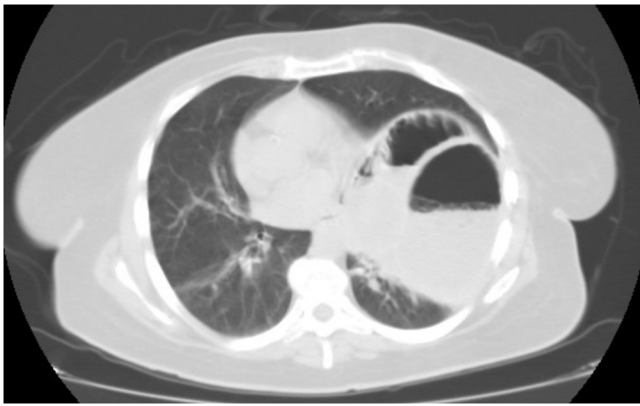


Fig. 1. Thorax-abdominal CT-scan showed a diaphragmatic herniation of the left side with malposition of dilated transverse and descending colon in the chest. In addition to this consensual complete atelectasis of the medial-basal part of the lung, and a right deviation of the mediastinal structures.

We report a case of a 64-year-old woman treated in emergency at our Academic Department for toxic megacolon, with intraoperative diagnosis of hemidiaphragm hypoplasia. The work has been reported in line with the SCARE criteria [5].

2. Presentation of case

A 64-years-old Caucasian woman was admitted in emergency with dyspnea and persistent respiratory failure, cough, general weakness, nausea, bowel not open with abdominal distention and severe pain. The patient showed also intellectual disability, associated with an unusual facial appearance, a heterochromia iridum and a monolateral corneal defect, disproportionate short stature and retarded skeletal maturation, in addition a history of chronic constipation; nevertheless, this cohort of clinical signs was not included in the known classical congenital syndromes.

Blood exams were normal, except for a moderate hydro-electrolyte disorder; the hemogasanalysis demonstrated a severe hypoxia. A chest X-ray, confirmed by thorax-abdominal CT-scan (Fig. 1), showed a probably diaphragmatic herniation of the left side; in the chest was present the malposition of the extremely dilated transverse and descending colon. In addition to this consensual complete atelectasis of the medial-basal part of the lung, and a right deviation of the mediastinal structures. A toxic megacolon was also supposed. Moreover, the left hepatic lobe was not radiologically detectable.

Therefore, consent was obtained and an emergency laparotomy was performed, confirming the preoperative diagnosis of toxic megacolon, with marked distention of the colon (diameter > 10 cm) in the absence of a true diaphragmatic hernia. The transverse and left large bowel, as well as, the spleen appeared malpositioned, indeed, in the left chest, in the presence of the lifting of hypoplastic left diaphragm, and not of the herniation through a diaphragmatic solution of continuity (Fig. 2). Furthermore, the abdominal exploration showed hypoplasia of the left hepatic lobe, and a dysmorphic gallbladder. An intra-operative bronchoscopy with *Carlens's* tube revealed hypoplasia of the left bronchial system and the absence of the left basal lobe.

A sub-total colectomy with mechanical ileo-rectal anastomosis, splenectomy, and temporary ileostomy were performed. Histological examination demonstrated a marked hyperplasia of the *muscularis mucosae* of the colon and cytoplasmic vacuolization of the *Auerbach plexus ganglia*. The karyotype genetic analysis excluded concomitant microdeletion or duplication syndromes.

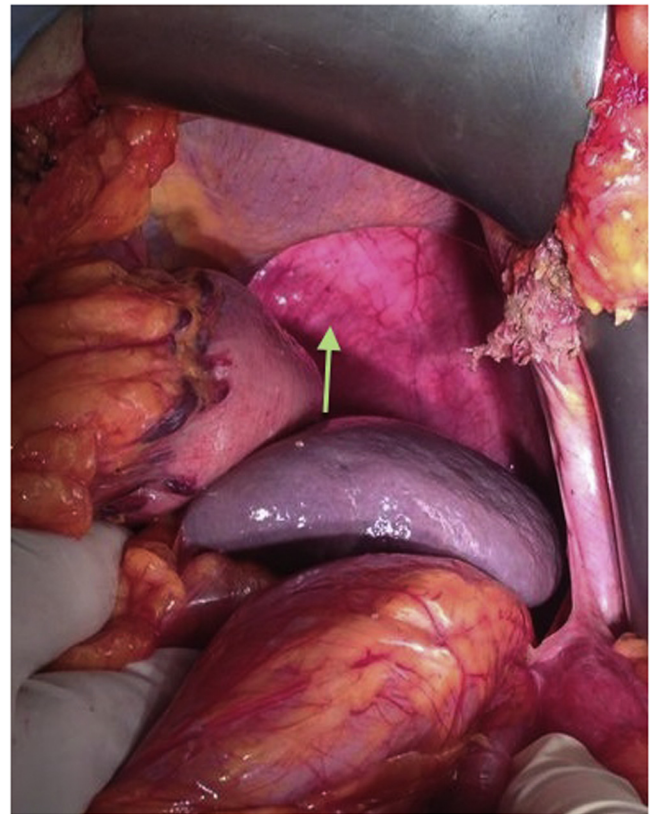


Fig. 2. The transverse and left large bowel, as well as, the spleen appeared malpositioned in the left chest, in the presence of the lifting of hypoplastic left diaphragm indicated by the arrow, and not of the herniation through a diaphragmatic solution of continuity.

The postoperative course was uneventful and the patient was discharged on the 10th post-operative day. Two months after the first operation the patient underwent ileostomy closure.

3. Discussion

To our knowledge, this is the first reported case of toxic megacolon in a patient with congenital hypoplasia of the left bronchial-lung system, of the left liver, with dysmorphism of the gallbladder, and of the left diaphragm. In the current case, we suspected an origin of the congenital diaphragmatic disease to be different from the common congenital diaphragmatic hernia; as it seemed to be related to a multi-organ embryological mistake of development.

The diaphragmatic muscle is a complex structure that develops around the third-fourth month of gestation from several embryonic structures: the *septum transversum* sets into a central tendon; the pleuro-peritoneal membranes form the muscular components; consequently, the diaphragm external border takes its origin from mesodermal tissues of the thoracic wall [6–8]. Finally, the left and the right *crura* develop from the dorsal esophageal mesentery, and they are included in the dorso-medial part of the dome shaped muscle [9,10].

Correct development of the diaphragm is essential for the neighboring organs. In the third week of gestation, the foregut endoderm differentiates into epithelial cell types that form the lungs and the trachea [11]. The lung mesenchyme, instead, originates from the lateral plate of the mesoderm, and develops into several lung components, including connective tissue, smooth muscle surrounding the airways and blood and lymphatic vessels, tracheal cartilages

and pleura. In particular, the lung begins to grow as a ventral outpouching on the floor of the primitive foregut and their development may be divided into two phases: (1) embryonic, which corresponds to formation of bronchial buds, and (2) fetal, which includes four stages, pseudoglandular, acinar/canalicular, saccular, and alveolar [11].

Many factors may influence the normal lung development, including the normal fetal breathing movements [12,13], the appropriate volumes of extra- and intrapulmonary fluids, the pulmonary blood flow, and, in particular, an adequate intrathoracic space [14,15]. During the phase of lung formation (8th–28th week of fetal development), the branches of bronchial buds form the respiratory trees. Around the 10th week, the midgut retracts into the abdomen and rotates.

In this reported case, we suppose that, during these weeks of fetal development, the large intestine, still not fixed to the body wall and under the pressure of the others growing organs (mainly the liver and the elongating ileum), grows towards the left thoracic cavity, partially invading it and inhibiting the normal lung growth, due to the hemidiaphragm hypoplasia. The pathogenetic hypothesis, therefore, to explain the reported left bronchial system hypoplasia was due to the lack of space for the lung germ to spread out, caused by compression from underneath bowel mass. The latter, the diaphragm may have been stretched over time and reduced to a thin rim of tissue, mostly fibrotic at gross inspection, unable to perform the muscular functions.

Considering the liver development [16], the first morphological sign is formation of the hepatic diverticulum, constituted by an epithelial thickening of the ventral foregut, adjacent to the developing heart. The anterior portion of the hepatic diverticulum gives rise to the liver and intrahepatic biliary tree, while the posterior portion forms the gallbladder and extra-hepatic bile ducts. The hepatic endodermal cells, known as hepatoblasts, delaminate from the epithelium and invade the adjacent *septum transversum* mesenchyme to form the liver bud. Consequently, the correct growth of the liver depends on the correct position of all surrounding organs, in particular of the diaphragm [17].

In the current case, therefore, the hypoplastic left lobe of the liver and the dysmorphic gallbladder may be the result of incorrect development from an originally unaltered embryonic liver, because of hypoplastic or a malpositioned diaphragm.

Considering that, an alternative pathogenetic hypothesis, could put together the observed diaphragmatic hypoplasia and the presence of megacolon, regards a possible defect in neural crest cells migration. The alteration of this phenomenon was involved in several well known syndromes, likewise *Peters* anomaly [18], but it may also include a variable degree of mental retardation, unusual facial appearance, eye defects, disproportionate short stature, retarded skeletal maturation, and visceral anomalies. In addition to this an unusual facial appearance, our patient presented a heterochromia iridum and a monolateral corneal defect, which are wholly suggestive of a *Peter's* like anomaly. The observed clinical pattern could be related to a partial modification of neural crest cell detachment or migration, then responsible for both bowel and diaphragm defects, although it was not included in typical neural crest cell syndromes. This hypothesis is supported by the histological report of the *Auerbach plexus ganglia* alteration and by recent data [19,20] on diaphragmatic development.

It has been recently demonstrated, indeed, that, in early mouse embryos, the *alpha4-Integrin* is expressed in a subset of neural crest cells and in epicardial progenitor cells [19]; in addition, this gene is involved in the development of *septum transversum*. This suggests the role of the subset of neural crest cells of *septum transversum* to provide the muscle and tendon components of the adult diaphragm [20].

4. Conclusion

To summarize, the described multiorgan alterations could have been founding their origin in the hypoplasia and malposition of the left hemidiaphragm, maybe sustained by or associated with an alteration of the neural crest cells migration during the embryological development.

Congenital diaphragmatic disease could be caused by several genetic alterations, though their originals molecular and genetic pathways are mostly unknown. The diagnosis could be rarely achieved in the adulthood, because of the absence of symptoms, but the morbidity could increase dramatically when triggering events occur, such toxic megacolon in the current case, thus revealing other possible embryonic developmental alterations.

Conflicts of interest

None.

Funding

None.

Ethical approval

Because this was a report of an interesting case, and not a trial or observational research, we had an exemption from ethical approval.

Consent

Written informed consent was obtained from the patient for publication of this case report and accompanying images. A copy of the written consent is available for review by the Editor-in-Chief of this journal on request.

Author contribution

Study concept or design: Angela Gurrado. Data collection, data analysis or interpretation: Alessandro De Luca, Valentina Ferraro, Daniela Virgintino, Anna Napoli, Giuseppe Cavallaro. Drafting the article: Angela Gurrado, Roberta Maria Isernia. Revising it critically for important content and final approval: Mario Testini, Angela Pezzolla, Eugenio Maiorano.

Registration of research studies

researchregistry3490.

Guarantor

Angela Gurrado.

References

- [1] A.C. Akinkuotu, S.M. Cruz, D.L. Cass, C.I. Cassady, A.R. Mehollin-Ray, J.L. Williams, et al., Revisiting outcomes of right congenital diaphragmatic hernia, *J. Surg. Res.* 198 (2015) 413–417.
- [2] L. Topor, T. Pătrăncuș, R. Caragața, A. Moga, Left congenital diaphragmatic hernia- case report, *Chirurgia (Bucur)* 110 (2015) 84–87.
- [3] P.D. Losty, Congenital diaphragmatic hernia: where and what is the evidence? *Semin. Pediatr. Surg.* 23 (2014) 278–282.
- [4] M.S. Irish, B.A. Holm, P.L. Glick, Congenital diaphragmatic hernia: a historical review, *Clin. Perinatol.* 23 (1996) 625–653.
- [5] R.A. Agha, A.J. Fowler, A. Saetta, I. Barai, S. Rajmohan, D.P. Orgill, for the SCARE Group, The SCARE statement: consensus-based surgical case report guidelines, *Int. J. Surg.* 34 (2016) 180–186.

- [6] S.F. Perry, T. Similowski, W. Klein, J.R. Codd, The evolutionary origin of the mammalian diaphragm, *Respir. Physiol. Neurobiol.* 171 (2010) 1–16.
- [7] I. Iritani, Experimental study on embryogenesis of congenital diaphragmatic hernia, *Anat. Embryol. (Berl.)* 169 (1984) 133–139.
- [8] S. Dietrich, F. Abou-Rebyeh, H. Brohmann, F. Bladt, E. Sonnenberg-Riethmacher, T. Yamaai, et al., The role of SF/HGF and c-Met in the development of skeletal muscle, *Development* 126 (1999) 1621–1629.
- [9] F. Bladt, D. Riethmacher, S. Isenmann, A. Aguzzi, C. Birchmeier, Essential role for the c-met receptor in the migration of myogenic precursor cells into the limb bud, *Nature* 376 (1995) 768–771.
- [10] D. Warburton, A. El-Hashash, G. Carraro, C. Tiozzo, F. Sala, O. Rogers, et al., Lung organogenesis, *Curr. Top. Dev. Biol.* 90 (2010) 73–158.
- [11] K.U. Hong, S.D. Reynolds, S. Watkins, E. Fuchs, B.R. Stripp, In vivo differentiation potential of tracheal basal cells: evidence for multipotent and unipotent subpopulations, *Am. J. Physiol. Lung Cell. Mol. Physiol.* 286 (2004) L643–L649.
- [12] N.C. Featherstone, M.G. Connell, D.G. Fernig, S. Wray, T.V. Burdyga, P.D. Losty, et al., Airway smooth muscle dysfunction precedes teratogenic congenital diaphragmatic hernia and may contribute to hypoplastic lung morphogenesis, *Am. J. Respir. Cell. Mol. Biol.* 35 (2006) 571–578.
- [13] A.A. Miller, S.B. Hooper, R. Harding, Role of fetal breathing movements in control of fetal lung distension, *J. Appl. Physiol.* 75 (1993) 2711–2717.
- [14] J. Que, B. Wilm, H. Hasegawa, F. Wang, D. Bader, B.L. Hogan, Mesothelium contributes to vascular smooth muscle and mesenchyme during lung development, *Proc. Natl. Acad. Sci. U. S. A.* 105 (2008) 16626–16630.
- [15] D.E. Ingber, Mechanobiology and diseases of mechanotransduction, *Ann. Med.* 35 (2003) 564–577.
- [16] K. Si-Tayeb, F.P. Lemaigre, S.A. Duncan, Organogenesis and development of the liver, *Dev. Cell* 18 (2010) 175–189.
- [17] L.M. Ntlhe, T.D. Mokotedi, Congenital hepatophrenic fusion: septum transversum-liver primordium anomaly, *S. Afr. J. Surg.* 45 (2007) 28–30.
- [18] W. Ni, W. Wang, J. Hong, P. Zhang, C. Liu, A novel histopathologic finding in the Descemet's membrane of a patient with Peters Anomaly: a case-report and literature review, *BMC Ophthalmol.* 15 (2015) 139.
- [19] K.A. Pinco, S. Liu, J.T. Yang, A4 integrin is expressed in a subset of cranial neural crest cells and in epicardial progenitor cells during early mouse development, *Mech. Dev.* 100 (2001) 99–103.
- [20] B.R. Pober, M.K. Russell, K.G. Ackerman, Congenital diaphragmatic hernia overview, in: R.A. Pagon, M.P. Adam, H.H. Ardinger, S.E. Wallace, A. Amemiya, L.J.H. Bean, T.D. Bird, N. Ledbetter, H.C. Mefford, R.J.H. Smith, K. Stephens (Eds.), *GeneReviews*® [Internet], Seattle (WA), University of Washington, Seattle; 1993–2017.

Open Access

This article is published Open Access at [sciencedirect.com](https://www.scienceopen.com). It is distributed under the [IJSCR Supplemental terms and conditions](#), which permits unrestricted non commercial use, distribution, and reproduction in any medium, provided the original authors and source are credited.