

# We are IntechOpen, the world's leading publisher of Open Access books Built by scientists, for scientists

4,400

Open access books available

118,000

International authors and editors

130M

Downloads

Our authors are among the

154

Countries delivered to

TOP 1%

most cited scientists

12.2%

Contributors from top 500 universities



WEB OF SCIENCE™

Selection of our books indexed in the Book Citation Index  
in Web of Science™ Core Collection (BKCI)

Interested in publishing with us?  
Contact [book.department@intechopen.com](mailto:book.department@intechopen.com)

Numbers displayed above are based on latest data collected.  
For more information visit [www.intechopen.com](http://www.intechopen.com)



# Echocardiography Evaluation in ECMO Patients

*Luigi Tritapepe, Ernesto Greco and Carlo Gaudio*

## Abstract

Extracorporeal membrane oxygenation (ECMO) is a special form of organ support for selected cases of cardiovascular and severe respiratory failure. Echocardiography is a diagnostic and monitoring tool widely used in all aspects of ECMO support. The pathophysiology of ECMO, and its distinct effects on cardiorespiratory physiology, requires an echocardiographer with high skills to understand the interaction between the ECMO and the patient. In this chapter, we present the main application of echocardiography in ECMO patients and some general concepts on the ECMO working. ECMO, such as the standard cardiopulmonary bypass employed in cardiac surgery, V-V (veno-venous), can support the insufficient respiratory system by oxygenating and removing carbon dioxide from the blood. VA-ECMO (venous-arterial) can support haemodynamics by providing mechanical circulatory assistance. Today, ECMO can be used as bridge to decision, waiting for the development of the clinical conditions to support with other devices the evolution of cardiorespiratory failure or stop the assistance. Echocardiography (trans-thoracic (TTE) or transoesophageal (TOE)) can be used primarily to take decisions regarding appropriateness of ECMO support, therefore to control cannula insertion and confirm final position, to modify number and position of the cannulae in case of malfunctioning of these, and, finally, to assess clinical progress and suitability for weaning from ECMO.

**Keywords:** echocardiography, critical care, ARDS, extracorporeal cardiopulmonary resuscitation, thromboembolism, tamponade, hemodynamic monitoring, VV-ECMO, VA-ECMO

## 1. Introduction

Cardiac surgeons and/or cardiac anaesthesiologists after cardiac operations prevalently use the ECMO in its VA-ECMO configuration for cardio-circulatory failure [1, 2]. Recently, ECMO in its veno-venous configuration is becoming widely used in ICU by intensivists to treat severe form of respiratory failure (ARDS) [3, 4] after the recent successes obtained with the use of ECMO in the A(H1N1) influenza epidemic [5, 6], linked to the results of CESAR Trial [7].

At the same time, the practice of echocardiographic investigation in intensive care units by the intensivists combined the echocardiographic method to haemodynamic monitoring, favouring the use of echocardiography for the assessment of haemodynamic and respiratory instability [8].

The patient who needs extracorporeal support is thus evaluated by the echocardiographer who establishes the timing of the support, the need for support, and the

PRINCIPAL INDICATIONS FOR THE TWO TYPES OF ECMO	
VA-ECMO	VV-ECMO
Cardiac arrest and cardiogenic shock	Pneumonia
Poisoning and drug overdose	ARDS
Pulmonary embolism	Pulmonary contusion
Hypothermia	Status asthmaticus
Massive pulmonary hemorrhage	Aspiration or inhalation injury
Bridge to transplant, to decision, to recovery, to candidacy	Drowning
Sepsis	

**Table 1.**  
Main indications for the use of ECMO assistance.

contraindications to the support and follows the phases of cannulation and functioning of the extracorporeal support [9].

ECMO is a rescue therapy used to provide cardiac and/or respiratory support for critically ill patients in whom maximal conventional medical management failed [3, 4]. VV-ECMO provides adequate oxygenation and removal of carbon dioxide in isolated refractory respiratory failure, while VA-ECMO is used when support for cardiac and /or respiratory failure is needed [1] (**Table 1**).

### 1.1 General role of echocardiography

Echocardiography (ECHO) plays a pivotal role in the management of critical patients, particularly those supported with ECMO [9–11]. ECHO can be used to not only evaluate function and diagnose diseases requiring ECMO but also to detect all cardiac complications or vascular diseases that may arise following ECMO [12, 13].

The central role of ECHO is important to identifying various diseases such as cardiac /undiagnosed valve lesions and left ventricular (LV) dysfunction, which could be the cause of severe haemodynamic instability, as well as to exclude them to avoid ECMO support [11].

The detection of aortic dissection represents an absolute contraindication in VA-ECMO, whereas a moderate to severe aortic valve regurgitation (AVR) is a relative contraindication in VA-ECMO, because the LV afterload increase, determining by ECMO itself, leads a worsening in AVR. ECHO provides information on aortic atherosclerosis and then guides the intensivist to decide the suitable cannulation sites (central versus peripheral) or the technique (surgical versus percutaneous) [13]. ECHO also helps to evaluate the right heart morphology for any structural abnormality, which could prevent the positioning of venous cannula for VV-ECMO or VA-ECMO [14].

In addition, as stated above, ECHO has a key role during ECMO cannulation. First, it guides the correct placement of the ECMO cannulae [15]. TTE may not be able to guide ECMO cannulation because of limited spatial resolution, and therefore transoesophageal echocardiography (TOE) represents the examination of choice to guiding the insertion. Echocardiographer and intensivist have to work together in order to correct the final position of the cannulae [15]. In VV-ECMO the position of the tips of the venous cannulae is essential for the correct functioning of the ECMO. Indeed, the drainage cannula must be positioned just before the entrance of the inferior vena cava (IVC) in the right atrium (RA), while the tip of the return cannula must be positioned in the central part of the RA just before the tricuspid valve but far away from the inter-atrial septum [16].

However, the echocardiographic evaluation is also essential for the identification and management of specific complications that may arise during ECMO support and may determine its malfunction. For the problems related to TTE resolution, also involving to the patient's respiratory pathology, the TOE is preferred to make it clear any possible complication [17]. ECHO allows a rapid evaluation not only of the positioning of the cannula but mainly of the cardiac filling, of the cardiac function, and of the cardiac tamponade [16, 17]. Detection of cardiac tamponade and evaluation of the significance of pericardial effusion or collection may be difficult in patients supported with ECMO because the heart is in a partially bypassed state.

In conclusion, ECHO is mandatory during the start of ECMO, cannulae insertion, haemodynamic monitoring, and detection of complications during weaning [16–18].

### *1.1.1 Ultrasonography for ECMO cannulation*

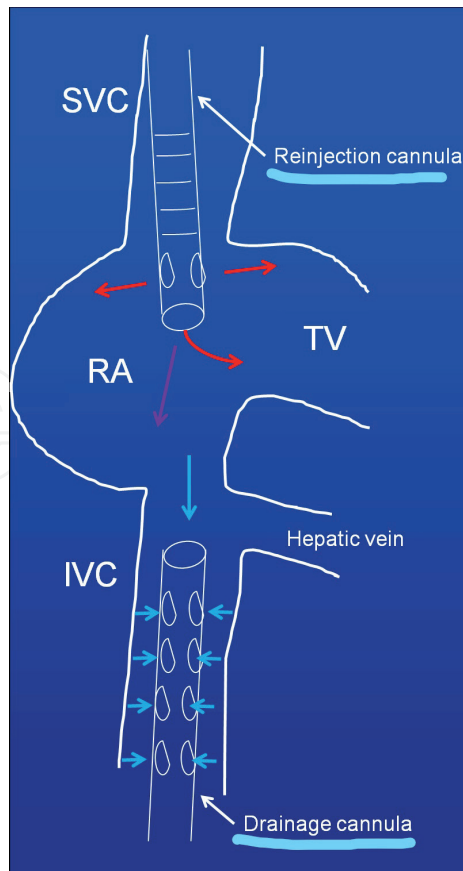
In many cases, cannulation can be performed without ultrasound guidance. However, the use of ultrasound can help to reduce the rate of complications associated with cannulation such as haematoma, retroperitoneal haematoma, vascular damage, cardiac tamponade, and ischemia of the lower leg [19]. In the paediatric patient, the eco-guided cannulation has been shown to reduce complications, especially the need for surgical placement [20, 21].

The ultrasound evaluation of the diameter of the vessels to be cannulated, especially the femoral artery, allows to choose the right size of the cannula, avoiding vascular occlusions distal to the cannulation point, with consequent ischemia, for example, of the lower limb [15, 19]. Cannulation can be carried out echo-guided or echo-assisted, i.e. only by identifying the insertion point. Today the ultrasound shows a greater sensitivity and specificity compared to radiography in identifying the exact point of arrival of the cannulae. The exact position of the femoral arterial cannula allows to optimise the flow, as well as the exact position of the venous cannula in IVC, above the hepatic vein, and contributes to an excellent drainage, clearly optimising hepatic drainage [22] (**Figure 1**). The echocardiography, after the positioning of the cannulae, must be performed to highlight early cardiac tamponade and problems of acute dilatation of the ventricles [14, 16, 23]. The use of colour Doppler also highlights problems of distal perfusion in the lower limb, such as having to provide with dedicated shunts.

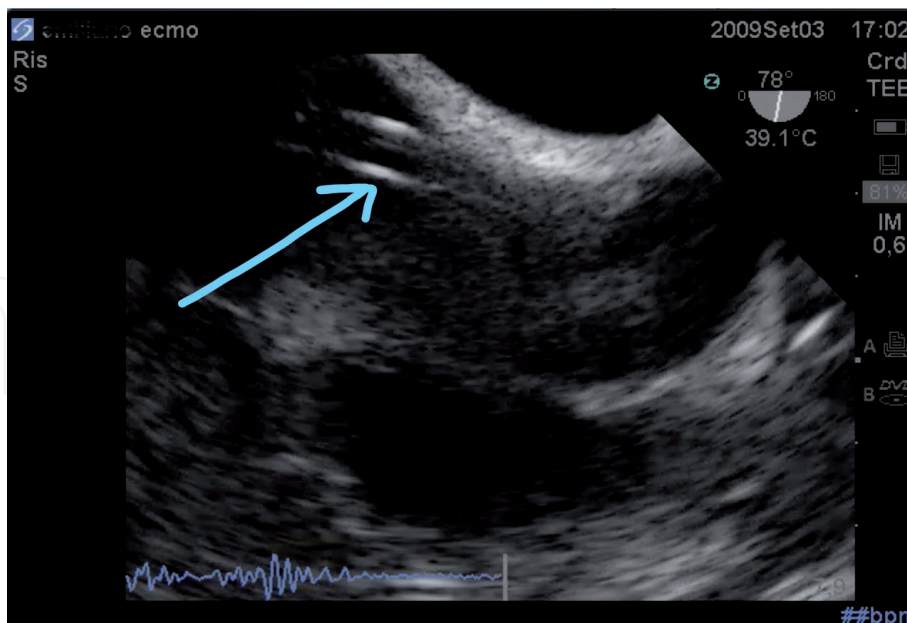
Before dilating vein for venous cannulation, it is necessary to make sure that guide wires, percutaneously inserted, are positioned inside the heart or large vessels. Only after ultrasound confirmation, physicians can proceed to advance the cannulae on these wires. However, it is necessary to discriminate the real images from the echocardiographic artefacts generated by these wires and cannulae, before proceeding to the final position of the cannulae. In the peripheral configurations of ECMO, especially in the VA-ECMO, we must assist with ultrasound the placement of the venous cannula in the middle of the right atrium in order to obtain an optimal drainage [13, 14] (**Figure 2**). With TOE, the bi-caval projection is able to orient perfectly on the optimal position of the venous cannula (**Figure 3**). Although the ultrasounds cannot indicate the level of the arterial cannula tip, which reaches the iliac artery from the femoral artery, they can confirm that the guide wire used in percutaneous arterial cannulation is located in the lumen of the aorta, before the femoral artery dilatation, reducing the risk of extra-arterial placement of the cannula.

### *1.1.2 Cannula position/complications*

Therefore, summing up, it is essential to visualise in real time the positioning of the guide wires in the caval districts (IVC and SVC) with the middle oesophageal

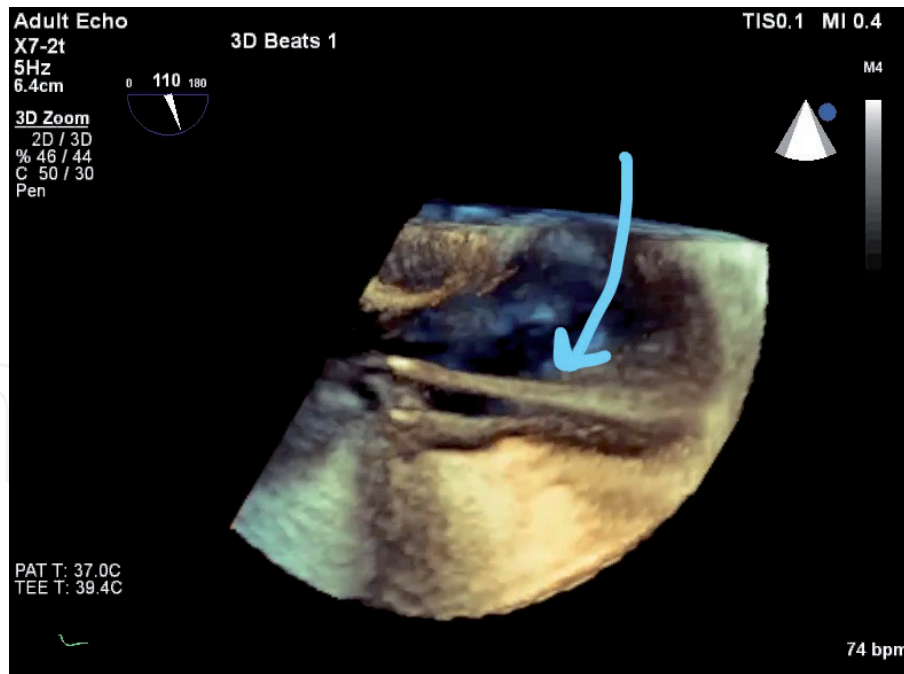


**Figure 1.** Cannulation scheme in VV-ECMO. The red arrows indicate the reinfusion of oxygenated blood, the purple arrow indicates the recirculating blood, and the light blue arrows indicate the drainage of the venous blood. SVC, superior vena cava; IVC, inferior vena cava; TV, tricuspid valve; RA, right atrium.

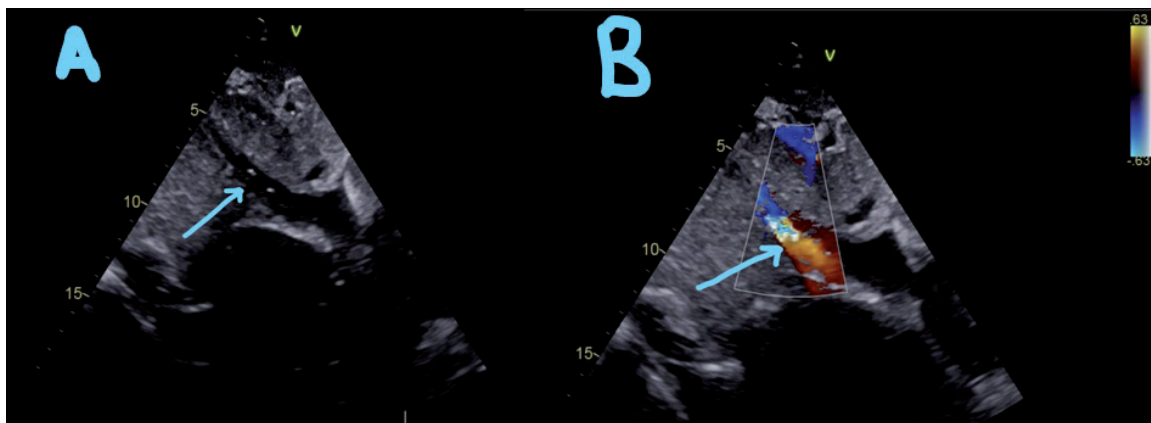


**Figure 2.** Bi-caval view of the TOE: the drainage cannula from the IVC is visible in the middle atrium (arrow light blue).

bi-caval projection to the TOE [11] (Figures 2–4). This is to avoid incorrect positioning of the cannula in the right ventricle, in the coronary sinus, or, worse, in the left atrium through a patent foramen ovale (PFO) [11, 13, 16]. During the entire positioning manoeuvres of the venous cannulae, particular attention must be paid to the presence of pericardial effusion, from atrial/right ventricular trauma, and to



**Figure 3.**  
*Bi-caval view to the 3D TOE: the drainage cannula from the IVC can be seen in the middle atrium (arrow light blue).*



**Figure 4.**  
*(A) Drainage cannula in IVC (light blue arrow) and (B) colour Doppler showing the flow in the cannula.*

the possible suction of the inter-atrial septum, with the obstruction of the drainage flow, linked to the venous aspiration from an adherent cannula to the septum itself [24, 25]. In the case of loss of oxygen performance of the ECMO, when a recirculation phenomenon is suspected due to a close position of the tips of the drainage and reinfusion cannulae, TOE can guide the correct repositioning of the cannulae [26].

### 1.1.3 Special cannulation (Avalon<sup>®</sup> cannula)

Compared to the classic configuration of the VV-ECMO which provides a double cannulation, the development of newer devices, such as the Dual Lumen Bi-Caval catheter (Avalon<sup>®</sup>, Maquet Cardiopulmonary GmbH Kehler Str. 31, 76,437 Rastatt, Germany), allowed VV-ECMO with a single cannula inserted in the right internal jugular vein [27]. This allows greater patient mobility, also reducing the femoral cannula decubitus and the infectious risk that this entails. However, being a stiffer and larger diameter cannula, the placement of the bi-luminal cannula involves greater risks of vessel injury and cardiac tamponade, in addition to the possible malfunction due to migration of the cannula from its original position [28, 29]. It is essential to

use the TOE for the correct positioning of the Avalon<sup>®</sup> catheter. In fact, the tip of the cannula is advanced under the TOE guide until the cannula drainage holes are positioned in the inferior and in the superior venae cavae (like a normal two-stage cannula used for cardiopulmonary bypass), and the re-entry is perfectly aligned with the inflow of the tricuspid valve [27]. This alignment is investigated with the colour Doppler which will measure the linear flow in case of correct positioning or a turbulent flow, in case of malposition. It is best to advance and withdraw the cannula under the TOE guide until the flow is laminar and directed through the centre of the tricuspid valve. Particular attention should be paid to visualising the cannula tip in the hepatic vein. A malposition of the cannula will cause recirculation, because the oxygenated blood from the cannula is drained immediately from the suction areas of the cannula to the ECMO circuit before being circulated systematically [28, 30].

## **1.2 Venovenous ECMO**

In the treatment of severe respiratory failure (severe ARDS), VV-ECMO is a valid option [31]. It can be considered a bridge to the healing of the lung, allowing the therapies to act effectively. Moreover, unlike the VA-ECMO it does not present problems of oxygenation north-south (harlequin syndrome). All this is valid if cardiac function is maintained normal and able to effectively support the systemic circulation. Therefore, before a VV-ECMO is established, a complete evaluation of both the patient's echocardiographic and haemodynamic parameters is essential [11, 16]. Echocardiography, both TTE and TOE, must ensure a correct evaluation of the right ventricular function and evaluate the degree of tricuspid insufficiency and the estimate of pulmonary artery pressure, potentially altered parameters in the course of ARDS, and sepsis [32].

VV-ECMO could improve the performance of the right ventricle and the whole heart. There is an irrelevant modification of the right preload, an increase in the left load due to a reduction in pulmonary pressure with a further increase in SvO<sub>2</sub>, and the saturation of the coronary blood. Approximately 20–25% of patients with ARDS develop an acute cor pulmonale (ACP) with right ventricular dilatation, inter-ventricular septum shift, left ventricular hypo-diastolic status, and pulmonary hypertension [32, 33]. This clinical picture is also typical of the right ventricular failure induced by the septic state. Echocardiography helps to choose the right timing for extracorporeal support and allows to follow the evolutionary state (improvement) of the right performance following VV-ECMO support: reduction of pulmonary pressure, increase in right contractility (increased systolic excursion of the tricuspid annular plane (TAPSE)), and improvement of the cardiac output (CO) [11, 16, 34].

TTE echocardiographic evaluation in patients with ARDS may present some resolution problems; therefore, normally the TOE is used, also because of low invasiveness as the patients are already intubated and sedated.

The presence of pulmonary hypertension and sepsis can create the conditions for a rapid deterioration of cardiac function, so that can worsen from initial presence of respiratory failure to cardiorespiratory insufficiency. Through echocardiographic and haemodynamic monitoring, we can anticipate the worsening of the clinical picture and establish a cardiorespiratory support (VA-ECMO).

### *1.2.1 Echo in VV-ECMO*

The right ventricle echocardiographic assessment in the ECMO patients with acute respiratory distress syndrome (ARDS) plays a key role to reduce complications and to improve the outcome [11, 14, 16, 31].

It is simple to understand the role of ECHO in the risk stratification of patients undergoing VV-ECMO. In fact, ARDS requires an initial aggressive ventilatory

treatment that brings to haemodynamic instability [33]. Patient presents high CVP associated to fluid accumulation in the pleural and abdominal spaces. ECHO shows a dilatation of the right ventricle with associated pulmonary hypertension. This clinical picture is described as ACP [8, 32, 33]. To minimise the impact of the positive end-expiratory pressure (PEEP) on right ventricular haemodynamic, physicians have choice a right balance between the PEEP value and cardio-circulatory stability. The therapeutic request is the protective ventilation aimed at reducing right ventricular failure related to an increase in the afterload of the right chambers [8, 33]. The aim of the treatment is the reduction of pulmonary arterial hypertension to reduce enlargement of right ventricle and consequent shift of the inter-ventricular septum. Unfortunately, despite implementation of protective lung ventilation, ACP still remains until 25% [32, 33, 34]. VV-ECMO represents a real solution to support both the lung and the right ventricle [35, 36].

The improvement of gas exchange and the reduction of airway pressures both contribute at the reduction of pulmonary vascular resistance with consequent hemodynamic improvement.

The daily evaluation of echocardiography in this case is mandatory.

Because the high acoustic impedance is caused by high PEEP values, TTE cannot be straightforward, and TOE is preferred.

A recently published summary paper on the management of ECMO recommends that physician training in echocardiography be part in the ECMO patient care team [37].

However, the role of echocardiography in ECMO is not widely accepted and is still poorly described in the literature.

The echocardiographic examination of the right ventricle requires a long axis and a short axis view to evaluate the size of the cavity with the relationship of the left ventricle and the kinetics of the septum. The examination can be completed by the Doppler of the right ventricular outflow and tricuspid regurgitation when present, to measure the systolic pressure of the pulmonary artery. The measurement of the TAPSE, simple and useful from prognostic point of view, avoids measuring the fractional area change (FAC) of the right ventricle more complicated. Right ventricle TDI (tissue Doppler imaging) is useful to evaluate diastolic and systolic functions [38].

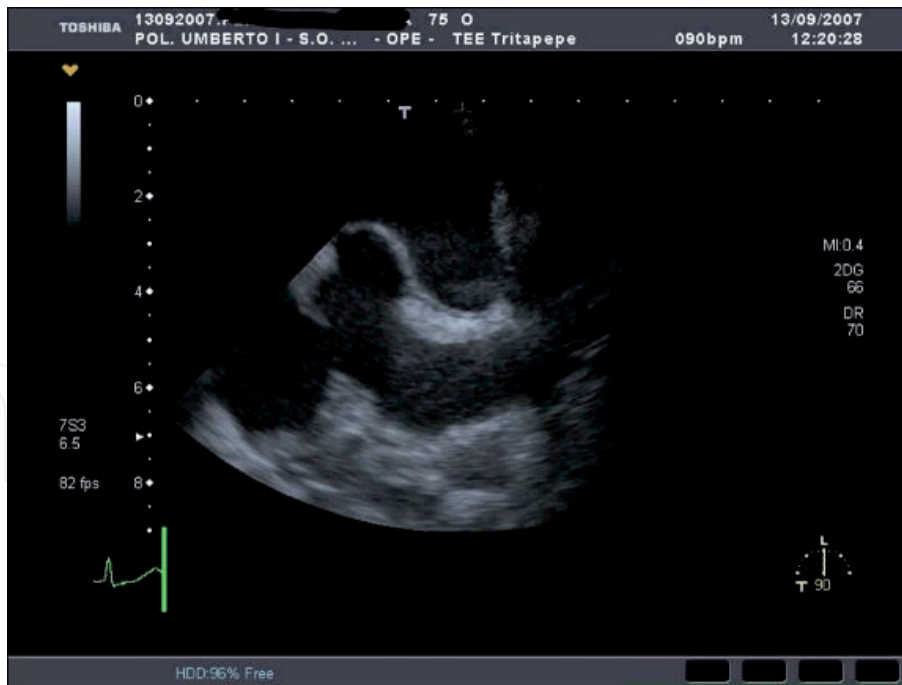
Moderate to severe right ventricular dilatations, defined as a ratio greater than 0.6 and as a ratio greater than or equal to 1, are associated with paradoxical septum motion at the end systole complicating the left ventricular function [8, 39, 40].

Pulmonary hypertension is usually associated with tricuspid regurgitation, but it also depends on right ventricular systolic function, and its value can be very low when associated with low CO [38, 39]. The right ventricular remodelling in ARDS patients is represented by the thickness of free wall, related to the increase in afterload [40]. Most important is also the detection of a PFO that can complicate the oxygenation of ARDS patients [39] (**Figures 5 and 6**). The displacement of septum due to right ventricular dilatation causes the left ventricular hypo-diastolic status, with a consequent low CO syndrome related to the difficult preload of the left ventricle. This is considered an ECHO evaluation of right ventricular function in pre-ECMO stage.

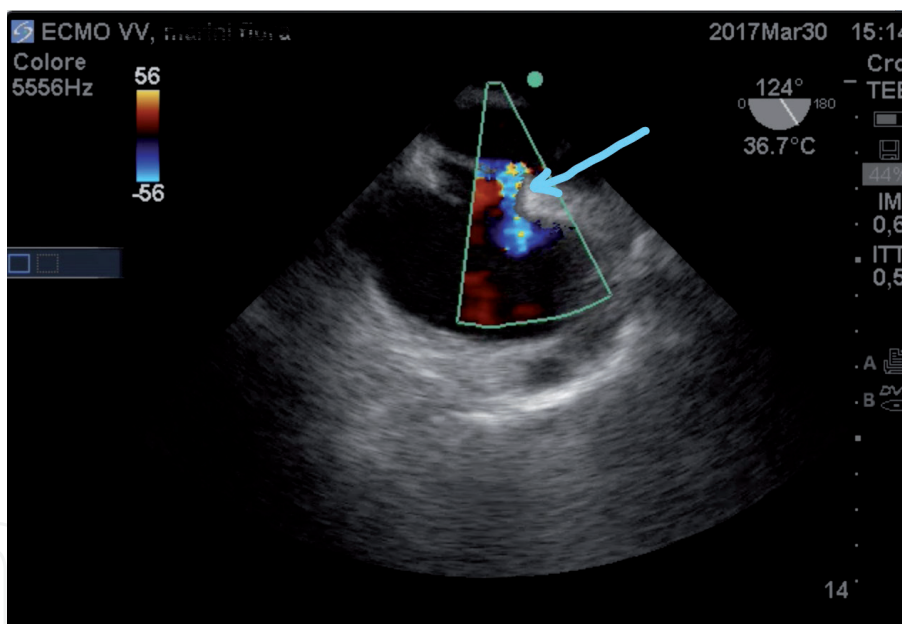
### 1.3 VA-ECMO

The purpose of the VA-ECMO is to support cardio-circulatory function in patients with heart failure refractory to medical therapy [1, 36]. Based on the INTERMACS class it belongs to, VA-ECMO can be used in major risk classes, not only as bridge to recovery or bridge to destination therapy (left ventricular assist device (LVAD) or heart transplantation (HTx)) but also as bridge to decision [41] (**Table 2**). In addition, the VA-ECMO can be used in haemodynamic support to





**Figure 5.**  
*Bi-caval view in which an aneurysm of the inter-atrial septum is seen.*



**Figure 6.**  
*Colour Doppler bi-caval view in which you see the shunt through the PFO.*

refractory cardiac arrest that can result in patient recovery or be used as a procedure for donation of splanchnic organs in non-beating heart [42, 43].

Compared to other mechanical cardiac assistance devices, ECMO has the advantage of reduced costs and the possibility of being set up easily and quickly on the outside of the operating room (intensive care unit, cardiac catheterization theatre, or emergency departments) and also during cardiopulmonary resuscitation manoeuvres [43]. However, it is an invasive assistance technique with major problems such as the short duration of assistance, the possible increase of infections, bleeding and thrombosis, and the increase of the afterload of the left ventricle.

The ultrasound evaluation is important before the implantation of the VA-ECMO. However, the conditions of the left ventricle, the degree of aortic

Type	Description
<b>Bridge to decision</b>	Use of VA-ECMO in pts with drug-refractory acute circulatory collapse and at immediate risk of death to sustain life until a full clinical evaluation can be completed and additional therapeutic options can be evaluated
<b>Bridge to recovery</b>	Use of VA-ECMO to keep patient alive until intrinsic cardiac function recovers sufficiently to remove VA-ECMO
<b>Bridge to candidacy</b>	Use of VA-ECMO to improve end-organ function in order to make an ineligible patient eligible for transplantation/LVAD
<b>Bridge to transplantation</b>	Use of VA-ECMO to keep a patient at high risk of death before transplantation alive until a donor organ becomes available

**Table 2.**  
 Possible uses of VA-ECMO.

insufficiency, and the presence of mitral and tricuspid valve insufficiencies must be carefully evaluated. The configuration of the VA-ECMO involves peripheral cannulations, already partially described, and central cannulations (right atrium and aorta) that can be performed in the cardiac surgery patient who has problems in weaning from the cardiopulmonary bypass.

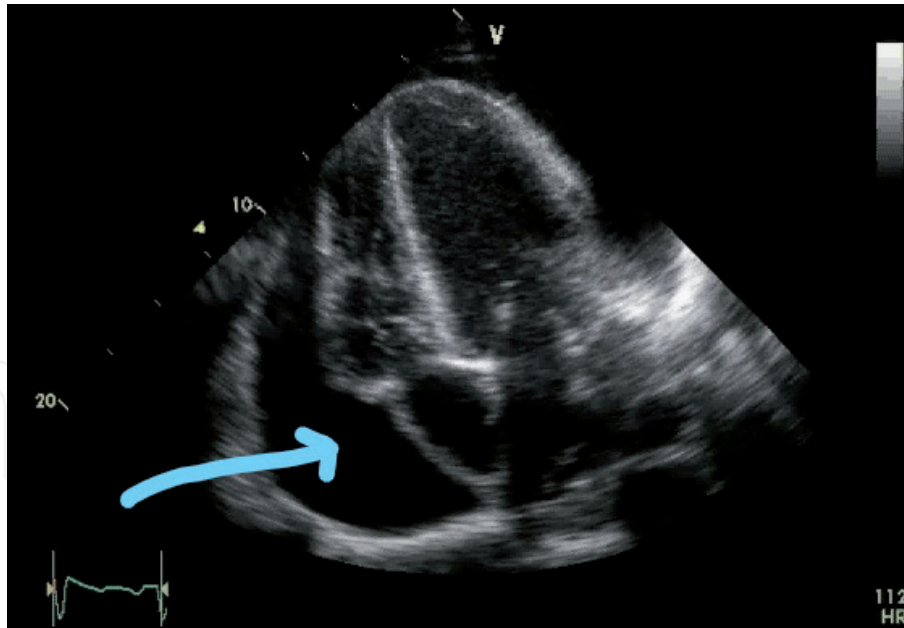
### 1.3.1 Indications to VA-ECMO support: cardiogenic shock

In patients with cardiogenic shock, echocardiographic examination is necessary to determine cause and indication for extracorporeal support [41] (**Table 1**). Even more, the echo exam can identify situations that may contraindicate the placement of circulatory assistance.

The echo examination must be as complete as possible and must highlight the morphology and the systolic and diastolic functions of the ventricles, evaluate the valve continence and the presence of pericardial effusion, and seek, in greater detail, the cause of cardiogenic shock (i.e. regional or global dysfunction of the left ventricle) [39]. In the study of cardiac valvular function, the study of the aortic valve is fundamental since its regurgitation can create unfavourable conditions for the positioning of VA-ECMO, given the increase in the afterload that the VA-ECMO generates. Clearly aortic dissection is an absolute contraindication for VA-ECMO placement. In addition, the morphology and the structure of the right atrium and of the right heart in general must be carefully evaluated. In fact, the presence of leads (pacemaker or ICD), a prominent Chiari network, a PFO, a tricuspid valve prosthesis, they are all elements that can compromise or make atrial cannulation impossible [11].

### 1.3.2 Monitoring during ECMO performance

The echocardiographic examination must fundamentally focus on the systolic function of the left ventricle. The systolic function is evaluated with conventional parameters such as the size of the left ventricle (LV), ejection fraction (EF), mitral regurgitation  $dP/dt$ , and aortic velocity time integral (VTI) [39]. The blood flow of ECMO can be adjusted based on the overall assessment of ventricular systolic function and cardiac preload. Some authors have systematically studied the effect of the flow rate of oxygenation of the extracorporeal membrane on changes in cardiac parameters [44]. A decrease of flow from 4 to 0.7 L/min leads to a 22% increase in the E/E' ratio (from 5.9 to 7.2;  $p < 0.001$ ), an increase of 17% in EF (from 15 to 17.5%;  $0.001$ ), increase of 12 and 45% of VTI (from 8 to 11.6 cm;  $p < 0.001$ ), and increase of 12% of the left ventricular tele-diastolic volume (from 95 to 108 ml,  $p < 0.001$ ) [44, 45].



**Figure 7.**  
*Presence of abundant pericardial effusion (light blue arrow) at TTE.*

A serious problem in the ultrasound evaluation is the detection of an evolving pericardial effusion to the cardiac tamponade (**Figure 7**), due to the passage of wires or cannulae with rupture of the cardiac chambers [11, 14, 16]. Following anticoagulant therapy, necessary in VA-ECMO, the pericardial blood collection can become consistent at many hours from the positioning, and only a series of ultrasound analysis allows the recognition of this clinical situation.

Thrombosis is a major complication during VA-ECMO and can be catastrophic when cerebral embolism occurs [46, 47]. Factors predisposing thrombosis are related to the blood/circuit contact and its activation as well as to the turbulence linked to the lumen of the cannulae [48]. Thrombosis can be more or less evident at ultrasound, and a real pitfall is represented by spontaneous intracavitary echo contrast (smoke) [49]. The evaluation of the opening of the aortic valve guarantees a certain pulsatility to the flow and avoids the stasis linked to the stagnant flow on the closed valve and predictor of thrombosis [46–49]. If the valve does not open, it is necessary to open the valve through changes in the flow of the VA-ECMO, the use of inodilator drugs, or the insertion of the intra-aortic balloon pump (IABP), which also favours the decompression of the left ventricle. Furthermore, in these cases it is necessary to optimise anticoagulation, which can be evaluated with specific point of care (thrombo-elastographic examination (TEG)) [50].

The increase in the afterload generated by the VA-ECMO can promote mitral-aortic valve regurgitation, compromising myocardial oxygenation and favouring the left ventricular distension not good for cardiac functional recovery.

### 1.3.3 ECHO in VA-ECMO

The difficult management of the patient in VA-ECMO must be accompanied by a continuous echocardiographic evaluation, carried out at least two times a day and whenever there is an unforeseen haemodynamic instability. The study of cardiac function should allow to optimise the flows of the mechanical support and the concomitant therapies. The ECHO evaluation must precede the start of the ECMO, follow the initial support phase, evaluate the evolution of the cardiac function in the stabilisation phase, and evaluate the cardiac functional recovery dictating the weaning time from the extracorporeal support.

### 1.3.4 ECMO start

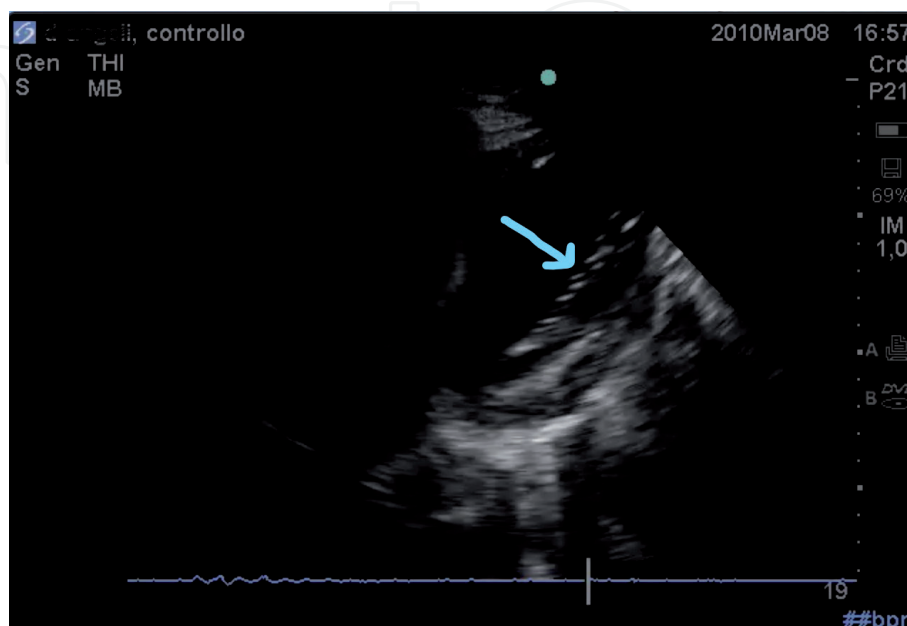
At the start of the VA-ECMO, it is necessary to concentrate the attention on the venous drainage to be able to maintain the flow rate. Flow reduction may be due to obstructions (thrombus) or malposition of the cannula or hypovolaemia [11, 48]. A sudden reduction in perfusion pressure and low flow could lead to the search for aortic dissection or severe aortic valve regurgitation resulting in dilation of the left ventricle.

### 1.3.5 ECMO support

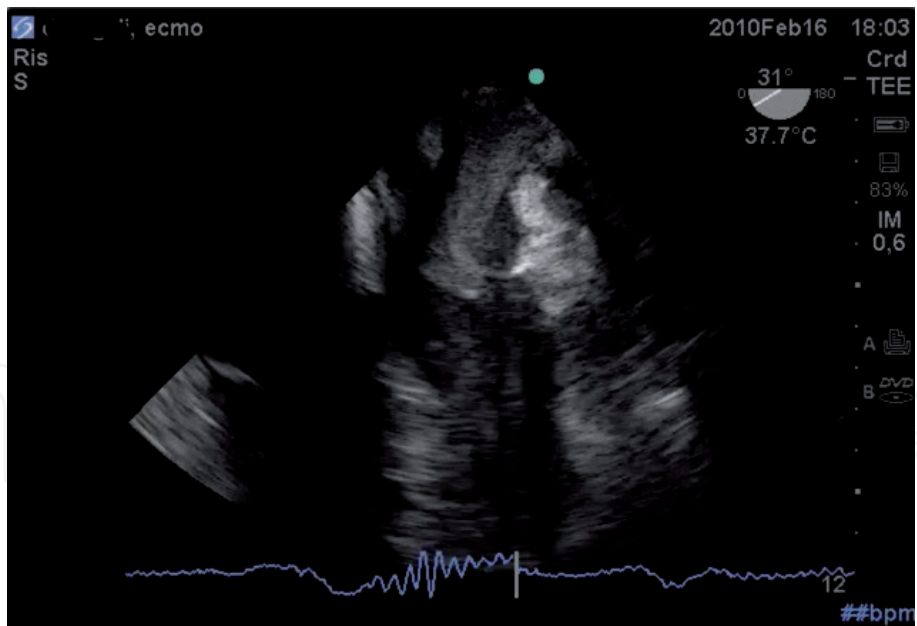
VA-ECMO is usually a medium-short duration assay, allowing the recovery of cardiac function or the bridge to other solutions (LVAD or HTx). At this time, echocardiographic monitoring is essential to monitor cardiac function recovery or lack of it.

One of the major problems, especially in the peripheral configuration of the VA-ECMO, is the distension of the left ventricle, such as to increase the tele-diastolic pressure and compromise the functional recovery of the heart [51, 52]. During peripheral VA-ECMO, LV preload usually decreases, but the LV afterload increases, resulting in a distension of the left ventricle associated with failure to open the aortic valve. The flow thus becomes continuous and non-pulsatile with consequent stasis, tendency to thrombosis, and embolization. This situation compromises the recovery of the heart.

The therapeutic strategy consists in venting the left ventricle [52] (**Figure 8**). The opening of the aortic valve can be done simply by trying to reduce the ECMO flow, but almost always you have to proceed with the IABP or better with the use of Impella® (ABIOMED, Inc., 22 Cherry Hill Drive, Danvers, MA 01923, USA) [53]. The most effective system is the cannulation of the left ventricular apex through a mini-thoracotomy, a procedure that can be performed under ultrasound guidance [52]. Echocardiographic monitoring has a key role in monitoring the distension of the left ventricle which leads to an increase in capillary pressure, interstitial pulmonary oedema, and bi-ventricular insufficiency. An alternative but less effective venting system is represented by an EndoVent in the pulmonary artery that, rather than detecting the left ventricle as it would take, reduces its preload [54]. Another solution for left ventricular decompression, in patients receiving extracorporeal



**Figure 8.**  
The light blue indicates the presence of intraventricular vent for the unloading of the left ventricle.



**Figure 9.**  
*TOE (4Ch view) of patient in VA-ECMO in which there is an extensive thrombotic formation of the left ventricle and of the left atrium.*

membrane oxygenation for myocardial failure, is represented by balloon atrial septostomy, used especially in paediatric patients [55, 56].

Echocardiography, through the evaluation of trans-aortic flow, is a precious instrument to measure CO during ECMO support as all CO monitoring methods are affected by errors.

The evaluation of distal perfusion is mandatory, and in most cases the distal hypoperfusion must be resolved by a retrograde perfusion cannula.

### 1.3.6 Weaning from ECMO

The echocardiographic evaluation reaches its peak in determining the timing and the possibility of weaning from ECMO [57]. Clearly weaning is possible only if the recovery of cardiac function is associated, as is evident, with the resolution of the pathological conditions determining the use of the VA-ECMO. An indirect sign of recovery of cardiac function is the increase in systolic-diastolic blood pressure. The echocardiographic parameters, which may suggest a safe weaning from the VA-ECMO, are the aortic VTI > 10 cm, the absence of cardiac tamponade, the partial recovery of the EF%, but above all an increase of the Sa wave at the TDI (>6 cm/s) [57, 58].

During the weaning of the VA-ECMO, the flow of ECMO is reduced, and clinical, haemodynamic, and echocardiographic parameters are evaluated. ECMO flows are usually not reduced below 1–2 L/min, due to the increased risk of thrombosis (**Figure 9**) of the low-flow circuit [59, 60]. If the patient remains with stable haemodynamic at low flow, they can be ready to be disconnected from the support. Weaning and de-cannulation are delicate phases, and careful haemodynamic and echocardiographic evaluation is needed to identify and promptly deal with contingent problems.

The ultrasonography evaluation also allows the vascular evaluation after de-cannulation.

## 1.4 Conclusions

Ultrasounds play a fundamental role in managing patients supported with ECMO, during all the different stages of assistance [10, 11, 14–16, 58], from

indication to cannulation, monitoring, and weaning. Either during circulatory or respiratory assistance, ultrasounds are fundamental to evaluate the cardiac function of the patients, providing information that determines appropriate patient selection. They are also needed to choose the best vascular access sites, guide the insertion of cannulas, monitor progress, detect complications, and help in determining recovery and weaning of support [10, 14–16, 34].

IntechOpen

## Author details

Luigi Tritapepe<sup>1,2,5\*</sup>, Ernesto Greco<sup>2,3,5</sup> and Carlo Gaudio<sup>2,4,5</sup>

1 Anaesthesia and Intensive Care, Sapienza University of Rome, Italy

2 Department of Cardiovascular, Respiratory, Nephrology, Anaesthesiology and Geriatric Sciences, Rome, Italy

3 Cardiac Surgery, Sapienza University of Rome, Italy

4 Applied Medical Technical Sciences, Sapienza University of Rome, Italy

5 Policlinico Umberto I Hospital, Rome, Italy

\*Address all correspondence to: [luigi.tritapepe@uniroma1.it](mailto:luigi.tritapepe@uniroma1.it)

## IntechOpen

© 2019 The Author(s). Licensee IntechOpen. This chapter is distributed under the terms of the Creative Commons Attribution License (<http://creativecommons.org/licenses/by/3.0>), which permits unrestricted use, distribution, and reproduction in any medium, provided the original work is properly cited. 

## References

- [1] Pellegrino V. Extracorporeal membrane oxygenation. In: Bersten AD, Soni N, editors. *Oh's Intensive Care Manual*. 7th ed. China: Butterworth Heinemann Elsevier; 2014
- [2] Marasco SF, Lukas G, McDonald M, McMillan J, Ihle B. Review of ECMO (extracorporeal membrane oxygenation) support in critically ill adult patients. *Heart, Lung & Circulation*. 2008;**17**(Suppl):S41-S47
- [3] Allen S, Holena D, McCunn M, Kohl B, Sarani B. A review of the fundamental principles and evidence base in the use of extracorporeal membrane oxygenation (ECMO) in critically ill adult patients. *Journal of Intensive Care Medicine*. 2011;**26**:13-26
- [4] Gattinoni L, Carlesso E, Langer T. Clinical review: Extracorporeal membrane oxygenation. *Critical Care*. 2011;**15**:243
- [5] Davies A, Jones D, Bailey M, Beca J, Bellomo R, Blackwell N, et al. Extracorporeal membrane oxygenation for 2009 influenza A(H1N1) acute respiratory distress syndrome. *JAMA*. 2009;**302**:1888-1895
- [6] Firstenberg MS, Blais D, Louis LB, Stevenson KB, Sun B, Mangino JE. Extracorporeal membrane oxygenation for pandemic (H1N1). *Emerging Infectious Diseases*. 2009;**15**:2059-2060
- [7] Peek GJ, Mugford M, Tiruvoipati R, Wilson A, Allen E, Thalanany MM, et al. Efficacy and economic assessment of conventional ventilatory support versus extracorporeal membrane oxygenation for severe adult respiratory failure (CESAR): A multicentre randomised controlled trial. *Lancet*. 2009;**374**:1351-1363
- [8] Caille V, Vieillard-Baron A. The right ventricle during the acute respiratory distress syndrome revisited by echocardiography. *The Open Nuclear Medicine Journal*. 2010;**2**:119-124
- [9] Sedgwick JF, Burstow DJ, Platts DG. The role of echocardiography in the management of patients supported by extracorporeal membranous oxygenation (ECMO). *International Journal of Cardiology*. 2010;**147**(Suppl):S16
- [10] Firstenberg MS, Orsinelli DA. ECMO and echo: The evolving role of quantitative echo in the management of patients requiring extracorporeal membrane oxygenation. *Journal of the American Society of Echocardiography*. 2012;**25**:641-643
- [11] Platts DG, Sedgwick JF, Burstow DJ, Mullany DV, Fraser JF. The role of echo in the management of patients supported by extracorporeal membrane oxygenation. *Journal of the American Society of Echocardiography*. 2012;**25**:131-141
- [12] Douflé G, Roscoe A, Billia F, Fan E. Echocardiography for adult patients supported with extracorporeal membrane oxygenation. *Critical Care*. 2015;**19**:326-336
- [13] Donker DW, Meuwese CL, Braithwaite SA, Broomé M, van der Heijden JJ, Hermens JA, et al. Echocardiography in extracorporeal life support: A key player in procedural guidance, tailoring and monitoring. *Perfusion*. 2018;**33**(1S):31-41
- [14] Guinot PG, Soullignac C, Zogheib E, Guilbart M, Abou-Arab O, Longrois D, et al. Interactions between veno-venous extracorporeal membrane oxygenation and cardiac function: An echocardiographic study upon weaning. *British Journal of Anaesthesia*. 2016;**117**(6):821-835
- [15] Giraud R, Banfi C, Bendjelid K. Echocardiography should be mandatory in ECMO venous cannula placement.

European Heart Journal - Cardiovascular Imaging. 1 Dec 2018;**19**(12):1429-1430.  
DOI: 10.1093/ehjci/jev142

[16] Tritapepe L. ECMO management guided by echo: Is it feasible? *Minerva Anestesiologica*. 2016;**82**(10):1023-1025

[17] Zhang Z. Echocardiography for patients undergoing extracorporeal cardiopulmonary resuscitation: A primer for intensive care physicians. *Journal of Intensive Care*. 2017;**5**:15

[18] Auzinger G, Loveridge R, Willars C, Best T, Kakar V, Hurst T, et al. Transoesophageal echocardiography and extracorporeal membrane oxygenation: Fancy for enthusiasts or indispensable tool? *Critical Care*. 2014;**18**(Suppl 1):P134

[19] Katz WE, Jafar MZ, Mankad S, Keenan RJ, Martich GD. Transesophageal echocardiographic identification of a malpositioned extracorporeal membrane oxygenation cannula. *Journal of Heart and Lung Transplantation*. 1995;**14**:790-792

[20] Kuenzler KA, Arthur LG, Burchard AE, Lawless ST, Wolfson PJ, Murphy SG. Intraoperative ultrasound reduces ECMO catheter malposition requiring surgical correction. *Journal of Pediatric Surgery*. 2002;**37**:691-694

[21] Zreik H, Bengur AR, Meliones JN, Hansell D, Li JS. Superior vena cava obstruction after extracorporeal membrane oxygenation. *Journal of Pediatrics*. 1995;**127**:314-316

[22] Victor K, Barrett N, Glover G, Kapetanakis S, Langrish C. Acute Budd-Chiari syndrome during veno-venous extracorporeal membrane oxygenation diagnosed using transthoracic echocardiography. *British Journal of Anaesthesia*. 2012;**108**:1043-1044

[23] Scherer M, Sirat AS, Moritz A, Martens S. Extracorporeal membrane oxygenation as perioperative right

ventricular support in patients with biventricular failure undergoing left ventricular assist device implantation. *European Journal of Cardio-Thoracic Surgery*. 2011;**39**:939-944

[24] Hirose H, Yamane K, Marhefka G, Cavarocchi N. Right ventricular rupture and tamponade caused by malposition of the Avalon cannula for venovenous extracorporeal membrane oxygenation. *Journal of Cardiothoracic Surgery*. 2012;**7**:36

[25] Yastrebov K, Manganas C, Kapalli T, Peeceeyen S. Right ventricular loop indicating malposition of J-wire introducer for double lumen bicaval venovenous extracorporeal membrane oxygenation (VV ECMO) cannula. *Heart Lung Circulation*. 2014;**23**:e4-e7

[26] Abrams D, Bacchetta M, Brodie D. Recirculation in venovenous extracorporeal membrane oxygenation. *ASAIO Journal*. 2015;**61**:115-121

[27] Avalon Laboratories. Avalon Elite\_ bi-caval dual lumen catheter. Available from: [http://www.avalonlabs.com/html/pulmonary\\_support.html](http://www.avalonlabs.com/html/pulmonary_support.html) [Accessed: 25 Nov 2011]

[28] Javidfar J, Wang D, Zwischenberger J, Costa J, Mongero L, Sonett J, et al. Insertion of bicaval dual lumen extracorporeal membrane oxygenation catheter with image guidance. *ASAIO Journal*. 2011;**57**:203-205

[29] Dolch ME, Frey L, Buerkle MA, Weig T, Wassilowsky D, Irlbeck M. Transesophageal echocardiography-guided technique for extracorporeal membrane oxygenation dual-lumen catheter placement. *ASAIO Journal*. 2011;**57**:341-343

[30] Chacon MM, Shillcutt SK. Intraoperative transesophageal echocardiography-guided placement of bicaval dual-lumen extracorporeal



membrane oxygenation cannula. *CASE (Phila)*. 2017;**1**(3):116-118

[31] Brodie D, Bacchetta M. Extracorporeal membrane oxygenation for ARDS in adults. *The New England Journal of Medicine*. 2011;**365**:1905-1914

[32] Bouferrache K, Vieillard-Baron A. Acute respiratory distress syndrome, mechanical ventilation, and right ventricular function. *Current Opinion in Critical Care*. 2011;**17**:30-35

[33] Tritapepe L. ARDS treatment strategies: After half a century do we still need guidelines? *Journal of Emergency and Critical Care Medicine*. 2017;**1**:24

[34] Sidebotham D, Allen SJ, McGeorge A, Ibbott N, Willcox T. Venovenous extracorporeal membrane oxygenation in adults: Practical aspects of circuits, cannulae, and procedures. *Journal of Cardiothoracic and Vascular Anesthesia*. 2012;**26**:893-909

[35] Miranda DR, van Thiel R, Brodie D, Bakker J. Right ventricular unloading after initiation of VV ECMO. *American Journal of Respiratory and Critical Care Medicine*. 2015;**191**:346-347

[36] Abrams D, Combes A, Brodie D. Extracorporeal membrane oxygenation in cardiopulmonary disease in adults. *Journal of the American College of Cardiology*. 2014;**63**:2769-2778

[37] Combes A, Brodie D, Bartlett R, Brochard L, Brower R, Conrad S, et al. Position paper for the organization of extracorporeal membrane oxygenation programs for acute respiratory failure in adult patients. *American Journal of Respiratory and Critical Care Medicine*. 2014;**190**:488-496

[38] Tritapepe L, De Santis V, Pacilli M. The right ventricle and pulmonary

artery. In: Sarti A, Lorini FL, editors. *Echocardiography for Intensivists*. Milan: Springer-Verlag; 2012. pp. 91-97

[39] Hahn RT, Abraham T, Adams MS, Bruce CJ, Glas KE, Lang RM, et al. Guidelines for performing a comprehensive transesophageal echocardiographic examination: Recommendations from the American Society of Echocardiography and the Society of Cardiovascular Anesthesiologists. *Journal of the American Society of Echocardiography*. 2013;**26**:921-964

[40] Boissier F, Katsahian S, Razazi K, Thille AW, Roche-Campo F, Leon R, et al. Prevalence and prognosis of cor pulmonale during protective ventilation for acute respiratory distress syndrome. *Intensive Care Medicine*. 2013;**39**:1725-1733

[41] Meuwese CL, Ramjankhan FZ, Braithwaite SA, et al. Extracorporeal life support in cardiogenic shock: Indications and management in current practice. *Netherlands Heart Journal*. 2018;**26**:58-66

[42] Chen Y-S, Lin J-W, Yu H-Y, Jerng J-S, Ko W-J, Chang W-T, et al. Cardiopulmonary resuscitation with assisted extracorporeal life-support versus conventional cardiopulmonary resuscitation in adults with in-hospital cardiac arrest: An observational study and propensity analysis. *Lancet*. 2008;**372**:554-561

[43] Cardarelli MG, Young AJ, Griffith B. Use of extracorporeal membrane oxygenation for adults in cardiac arrest (E-CPR): A meta-analysis of observational studies. *ASAIO Journal*. 2009;**55**:581-586

[44] Aissaoui N, Luyt CE, Leprince P, Trouillet JL, Leger P, Pavie A, et al. Predictors of successful extracorporeal membrane oxygenation (ECMO) weaning after assistance for refractory

cardiogenic shock. *Intensive Care Medicine*. 2010;**37**:1738-1745

[45] Aissaoui N, Guerot E, Combes A, Delouche A, Chastre J, Leprince P, et al. Two dimensional strain rate and Doppler tissue myocardial velocities: Analysis by echocardiography of hemodynamic and functional changes of the failed left ventricle during different degrees of extracorporeal life support. *Journal of the American Society of Echocardiography*. 2012;**25**:632-640

[46] Ramjee V, Shreenivas S, Rame JE, Kirkpatrick JN, Jagasia D. Complete spontaneous left heart and aortic thromboses on extracorporeal membrane oxygenation support. *Echocardiography*. 2013;**30**:E342-E343

[47] Madershahian N, Weber C, Scherner M, Langebartels G, Slottosch I, Wahlers T. Thrombosis of the aortic root and ascending aorta during extracorporeal membrane oxygenation. *Intensive Care Medicine*. 2014;**40**:432-433

[48] Hajj-Chahine J, Tomasi J, Lanquetot H, Corbi P. Ascending aortic thrombosis in a patient on extra-corporeal membrane oxygenation. *European Journal of Cardio-Thoracic Surgery*. 2010;**37**:953

[49] Unai S, Nguyen M-L, Tanaka D, Gorbachuk N, Marhefka GD, Hirose H, et al. Clinical significance of spontaneous echo contrast on extracorporeal membrane oxygenation. *The Annals of Thoracic Surgery*. 2017;**103**:773-849

[50] Mulder MMG, Fawzy I, Lancé MD. ECMO and anticoagulation: A comprehensive review. *Netherlands Journal of Critical Care*. 2018;**26**(1):6-13

[51] Rupperecht L, Florchinger B, Schopka S, Schmid C, Philipp A, Lunz D, et al. Cardiac decompression on extracorporeal life support: A review

and discussion of the literature. *ASAIO Journal*. 2013;**59**:547-553

[52] Weymann A, Schmack B, Sabashnikov A, Bowles CT, Raake P, Arif R, et al. Central extracorporeal life support with left ventricular decompression for the treatment of refractory cardiogenic shock and lung failure. *Journal of Cardiothoracic Surgery*. 2014;**9**:60

[53] Koeckert MS, Jorde UP, Naka Y, Moses JW, Takayama H. Impella LP 2.5 for left ventricular unloading during venoarterial extracorporeal membrane oxygenation support. *Journal of Cardiac Surgery*. 2011;**26**:666-668

[54] Avalli L, Maggioni E, Sangalli F, Favini G, Formica F, Fumagalli R. Extracorporeal membrane oxygenation: An alternative to surgical and transeptal venting in adult patients. *ASAIO Journal*. 2011;**57**:38-40

[55] Koenig PR, Ralston MA, Kimball TR, Meyer RA, Daniels SR, Schwartz DC. Balloon atrial septostomy for left ventricular decompression in patients receiving extracorporeal membrane oxygenation for myocardial failure. *The Journal of Pediatrics*. 1993;**122**:S95-S99

[56] O'Connor TA, Downing GJ, Ewing LL, Gowdamarajan R. Echocardiographically guided balloon atrial septostomy during extracorporeal membrane oxygenation (ECMO). *Pediatric Cardiology*. 1999;**14**:167-168

[57] Aissaoui N, El-Banayosy A, Combes A. How to wean a patient from veno-arterial extracorporeal membrane oxygenation. *Intensive Care Medicine*. 2015;**41**:902-905

[58] Cavarocchi NC, Pitcher HT, Yang Q, Karbowski P, Miessau J, Hastings HM, et al. Weaning of extracorporeal membrane oxygenation using continuous hemodynamic transesophageal echocardiography.

Journal of Thoracic and Cardiovascular  
Surgery. 2013;**146**:1474-1479

[59] Konishi H, Misawa Y, Nakagawa Y,  
Fuse K. Doppler aortic flow pattern  
in the recovery heart treated by  
cardiac ECMO. *Artificial Organs*.  
1999;**23**:367-369

[60] Pappalardo F, Pieri M, Arnaez  
Corada B, Ajello S, Melisurgo G, De  
Bonis M, et al. Timing and strategy  
for weaning from venoarterial  
ECMO are complex issues. *Journal of  
Cardiothoracic and Vascular Anesthesia*.  
2014;**29**:906-911

IntechOpen