



Original Article

Neonatal Functional Treatment for Pierre Robin Sequence

Gabriella Galluccio , Valentina Mazzoli , Roberto Vernucci , Alessandro Silvestri , Ersilia Barbato 

Department of Orthodontics and Maxillofacial Surgery, Sapienza University of Rome School of Dentistry, Rome, Italy

Cite this article as: Galluccio G, Mazzoli V, Vernucci R, Silvestri A, Barbato E. Neonatal Functional Treatment for Pierre Robin Sequence. Turk J Orthod 2019; 32(3): 151-9.

ABSTRACT

Objective: Pierre Robin Sequence (PRS) is a heterogeneous pathological condition characterized by the coexistence of micrognathia, glossoptosis, and cleft palate, resulting in upper airway tract obstruction. Among the treatment modalities, the orthodontic approach is one part of the comprehensive care of those patients and will be present in the treatment modalities during all the growth period of the child.

Methods: All patients with PRS observed in the period 2013-2017 were treated with a definite functional approach. The results were retrospectively analyzed with regard to functional outcome, total treatment time, and number of plates provided for a single patient.

Results: In all the patients, the indicated treatment protocol has been applied as early impression and plate supply, stimulation of bottle feeding with the use of the plate, eventual substitution of the plate if no more adequate to the transverse and sagittal growth of the palate, and continuing the use until the surgical closure of the cleft. All the patients showed a positive outcome to the proposed treatment approach, evaluated with regard to the incidence of feeding improvement and weight gain, to the limit for the surgical phase, in the absence of adverse effects.

Conclusion: The use of a functional obturator plate, removing functional alterations to mandibular growth, reduces and, in some cases, eliminates the need for surgical intervention. As also stated in the literature, if despite the presence of the plate nutritional problems persist, immediate different surgical approaches, mainly mandibular osteodistractor, become necessary.

Keywords: Pierre Robin Sequence, functional orthodontic treatment, cleft palate, obturator plate

151

INTRODUCTION

Pierre Robin Sequence (PRS) is a heterogeneous pathological condition characterized by the coexistence of micrognathia, glossoptosis, and cleft palate, resulting in upper airway tract obstruction. The characteristic appearance of patients with PRS is their chinless shape, determined by mandibular hypoplasia or micrognathia. Glossoptosis with upper airway obstruction is the result of mandibular micrognathia. The main symptom of respiratory obstruction consists of an apnea crisis, often during sleep OSAS: obstructive sleep apnea syndrome.

The cleft palate, which is the last element in the pathogenetic sequence, is the consequence of an altered tongue position during the fetal period; its interposition both between the palatine processes and the maxillary processes prevents their fusion. The cleft affects the soft palate and the posterior portion of the hard palate; the remaining part of the hard palate always presents a pronounced concavity (Figure 1, 2). Therefore, the tongue is the cause of the cleft, preventing the migration and fusion of palatal structures; after birth, the tongue continues to fill the pharyngeal space, resulting in glossoptosis and respiratory crisis. The presence of cleft palate is not essential to characterize the PRS; there are cases of micrognathia and glossoptosis without cleft, but a deep palatal vault caused by tongue pressure is always present (1-3) (Figure 3). In this case, the clinical picture and symptoms are less severe. Facial appearance is always characteristic (Figure 4, 5).

The Pierre Robin Sequence can be considered as a malformation with embryologic dysfunctional pathogenesis. The recognition of the pathogenetic mechanism is the premise to a therapeutic orthopedic-functional approach, which should be performed in the neonatal period.

Recently, Van Lieshout et al. (4), in a survey conducted among European clinicians, investigated the most commonly used procedures of therapeutic approach to RS in Europe. In most cases, the decisive factor was related to the patient's breathing possibilities and, therefore, to the need for treatment of the respiratory difficulty that may be present.

In cases of mild obstruction, the most frequent therapy was to maintain the prone position or, if unsuccessful, the use of a naso-

pharyngeal airway. The surgical procedures varied widely from country to country, but in cases of severe obstruction, mandibular osteodistraction was the most frequent treatment modality (4, 5).

In the present study, we emphasize the role of functional therapy and how it is conducted, starting from the immediate neonatal period until palatoplasty, and provide a summary of the therapies performed at our institution over the last 5 years.

The aim of the present study was to present the treatment protocol applied in the Department of Oral and Maxillofacial sciences in 20 consecutive patients treated with an immediate functional therapy based on the above-indicated pathogenetic mechanism. Moreover, the study presented the details of the treatment timing and devices in the sample analyzed and evaluated the treatment results with regard to the positive or negative out-

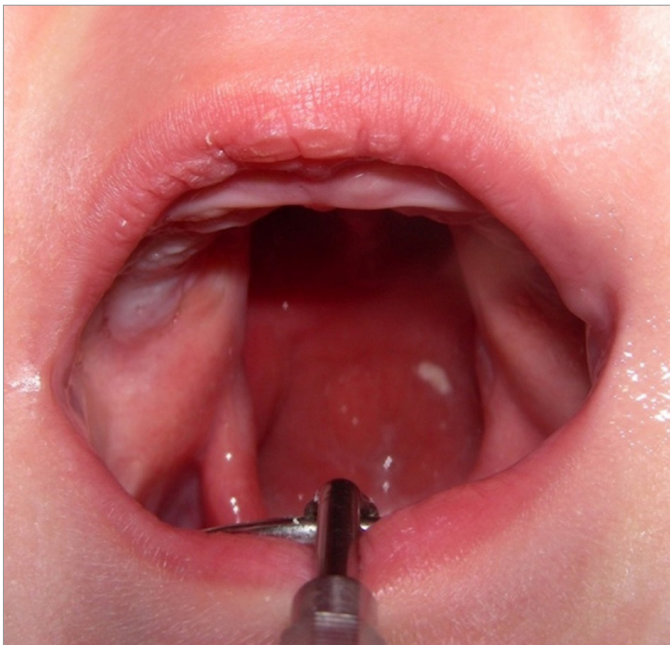

Figure 1. PRS with complete palate cleft

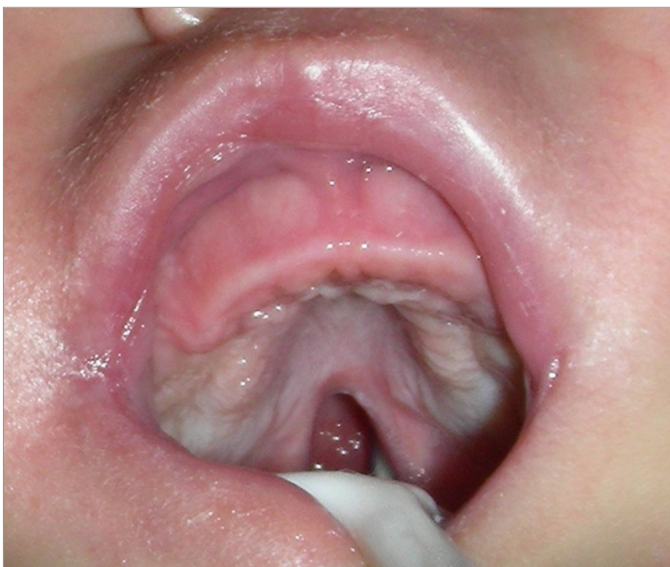

Figure 2. PRS with posterior palate cleft

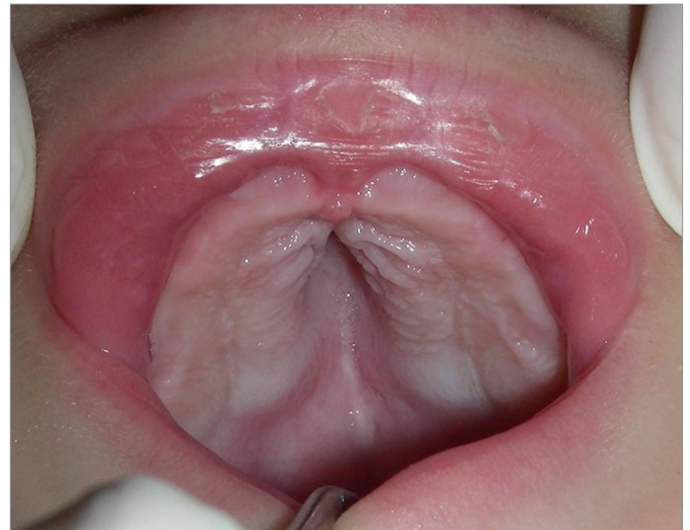

Figure 3. PRS with pseudo palate cleft

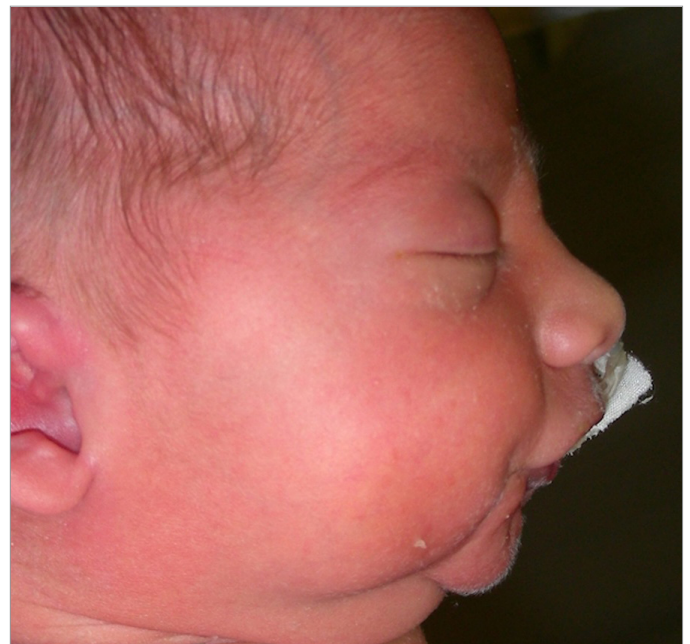

Figure 4. Characteristic shape of a child with PRS

come based on the characteristic of feeding and weight gain up to 8 kg, requested for the surgical phase of cleft closure.

METHODS

A total of 31 patients with features of cleft palate were treated in the Orthodontic Department of the Sapienza University of Rome in the period January 2013-June 2017. Of the 31 patients, 20 were identified as affected by PRS.

Treatment Protocol

The orthodontist begins his intervention just after the birth of the patient and closely follows the patient through all developmental stages, in close communication with other specialists.

Orthodontic treatment occurs in specific stages of development, with well-defined therapeutic goals accepted by plastic and maxillofacial surgeons. This includes the following: a primary treatment with the use of pre-surgical functional obturator or or-

thopedic plates and treatment for deciduous or mixed dentition to improve and guide mandibular growth.

The clinical protocol is an early approach since the very first days of life; impressions in polyvinyl siloxane (PVS) are obtained for construction of an obturator plate, which will be used until the primary closure of the cleft, to facilitate the small patient during suction and breathing.

Thus, the functional plate is usually applied in the first to second week of life and plays a key role in restoring the anatomical individuality of the oral and nasal cavities, holding down the tongue, and recovering the physiological functions of the stomatognathic apparatus (5).

This device will help restore a correct tongue's posture necessary to avoid worsening of the cleft and to allow physiological mandibular growth.

According to the orthodontic functional treatment principles of the Cleft Lip and Palates Zurich School (6, 7), the plate guides the

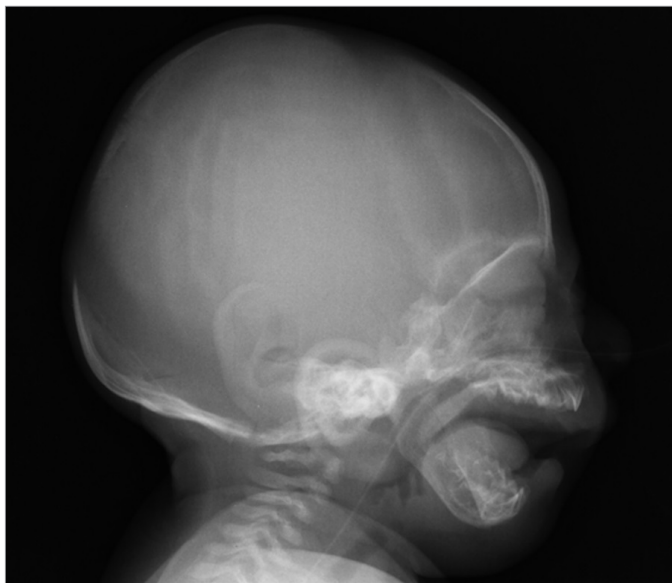

Figure 5. Latero-lateral cephalogram of a newborn with PRS



Figure 7. Kit of trays for newborns

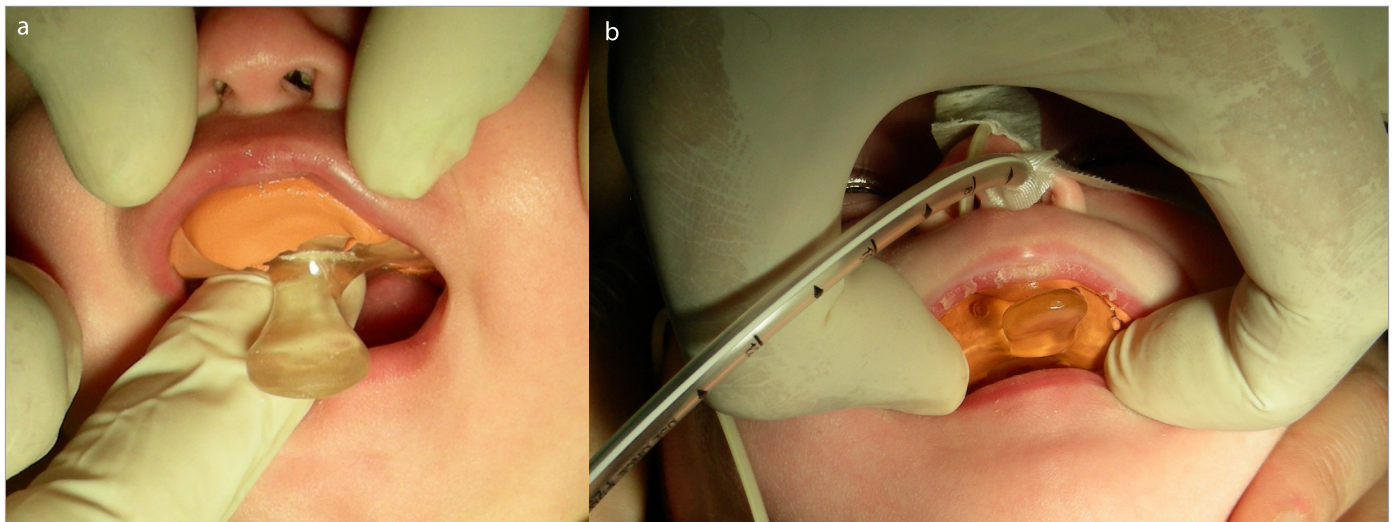


Figure 6. a, b. Obtaining an impression in an awake patient (a) and in sedated and intubated ones (b)

development of the maxillary segments, promoting the medial approach of the palatal processes, thus making surgical treatment easier.

Moreover, the early application of the plate helps the young patient to accept and immediately consider it a natural anatomic part.

The first impression for construction of the plate is always done in a controlled environment under the supervision of a pediatrician and anesthetist and under cardiorespiratory monitoring,

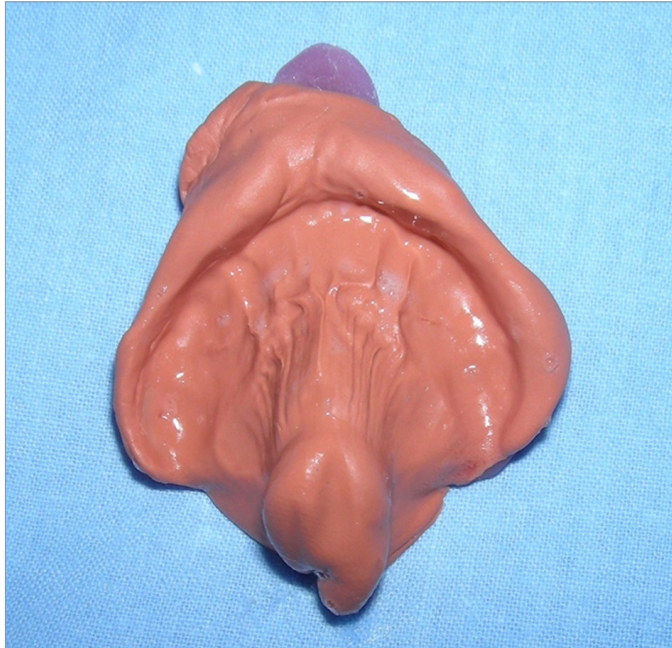

Figure 8. Impression in silicon material

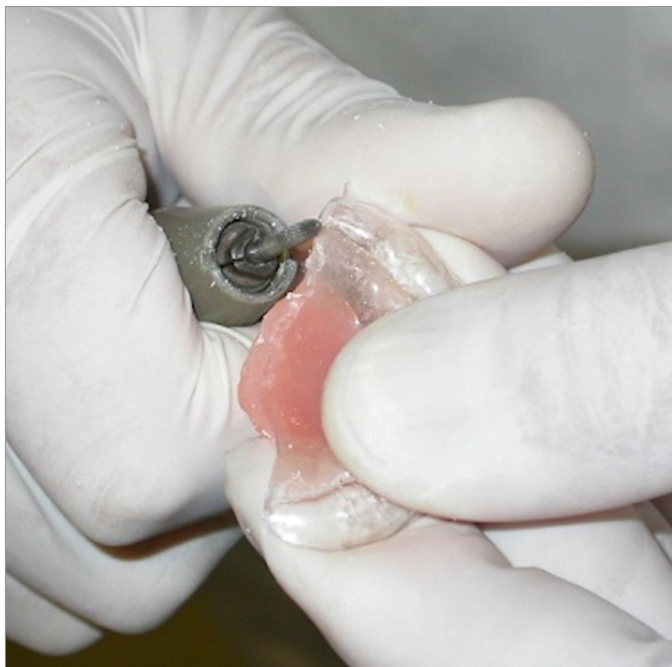

Figure 9. Discarding the plate to allow free growth medially and inferiorly

usually with the patient awake; sedation is needed only in a limited number of cases, based on the judgment of the anesthetist (Figure 6. a, b).

A set of trays, built on models of cleft patients, is available for selection of the correct size (Figure 7); only in particular anatomic conditions is it necessary to build an individual tray.

According to the Zurich School (6, 7), the impression material for construction of the plate is PVS, and the plate is made with acrylic resin, without relining the soft resin (Figure 8).

Before application, we discard the middle part of the plate to remove its contact with the palatal processes to allow for free growth medially and inferiorly (Figure 9).

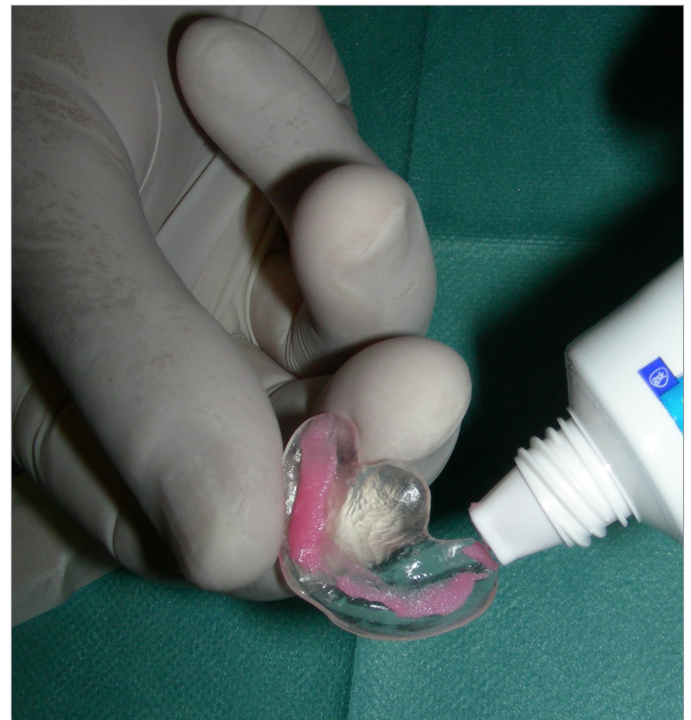

Figure 10. Application of a prosthetic paste on the functional plate

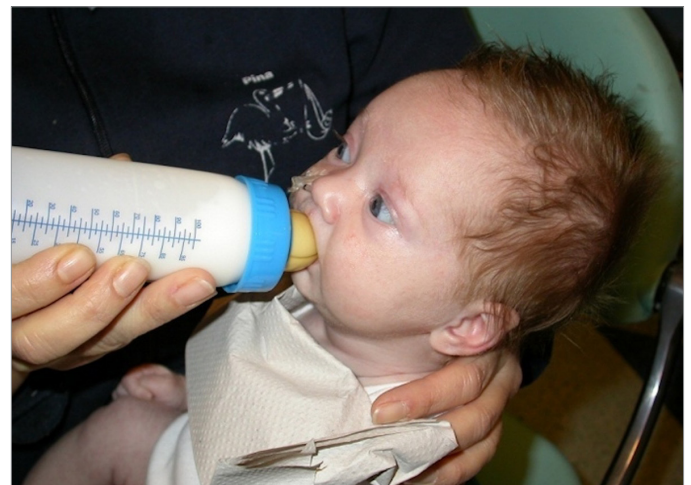

Figure 11. Application of the functional plate: newborn patient feeding with an obturator plate

In this method, the support of the plate to the maxilla is circular on the alveolar processes; to ensure the perfect adhesion of the plate, we use a neutral and hypoallergenic prosthetic adhesive paste (Kukident Neutral) that can also play a notable role of atraumatic thickness (Figure 10).

The plasticity of the adhesive amplifies the functional stimulus on the upper jaw by pressure variations that occur in the oral cavity with tongue movement, in particular during sucking (Figure 11).

Patients wear the plate full-time, removing it only once daily to clean it.

Clinical examinations are performed monthly to evaluate possible early teeth eruptions or decubitus and eventually the increases in the maxillary dimension.

In some cases, in fact, two functional plates are built for each patient, at a distance of 3-4 months apart, to meet the growth of the mouth of the patient and to favor the reunion of the palatine bones. In a very small newborn, it was also necessary to build three functional plates before reaching the ideal body weight (8 kg) necessary to undergo palatoplasty.

The primary treatment goal is to provide the stomatognathic apparatus with a new morphological and functional environment through repositioning lingual posture and restoring functional balance, allowing for a normal growth pattern. We encourage the use of a pacifier to amplify the functional stimulus. Thus, this orthopedic-functional therapeutic protocol provides the use of two elements, namely, the functional plate and the baby pacifier. The therapeutic mechanism of such therapeutic functional devices is described below.

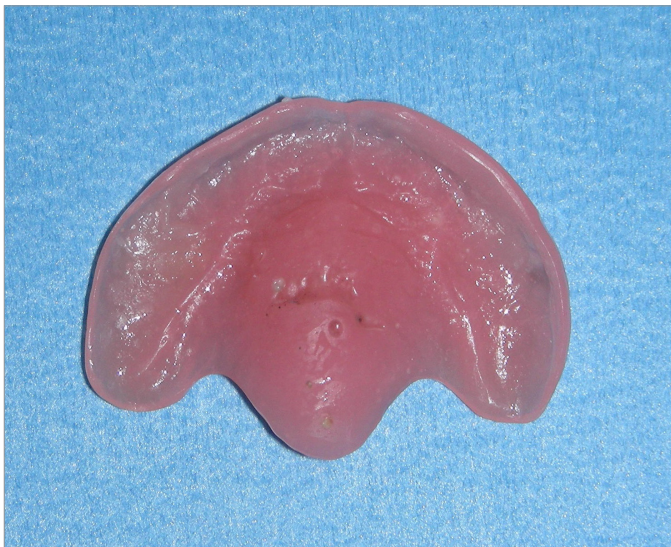

Figure 12. Final aspect of the functional plate

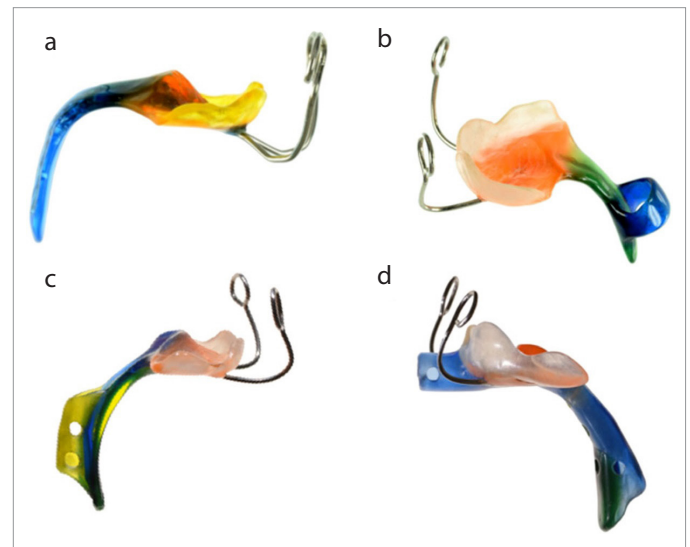


Figure 13. a-d. Various types of palatal plates used PRS. Data from Müller-Hagedorn et al. *Head & Face Medicine* (2017) 13:4

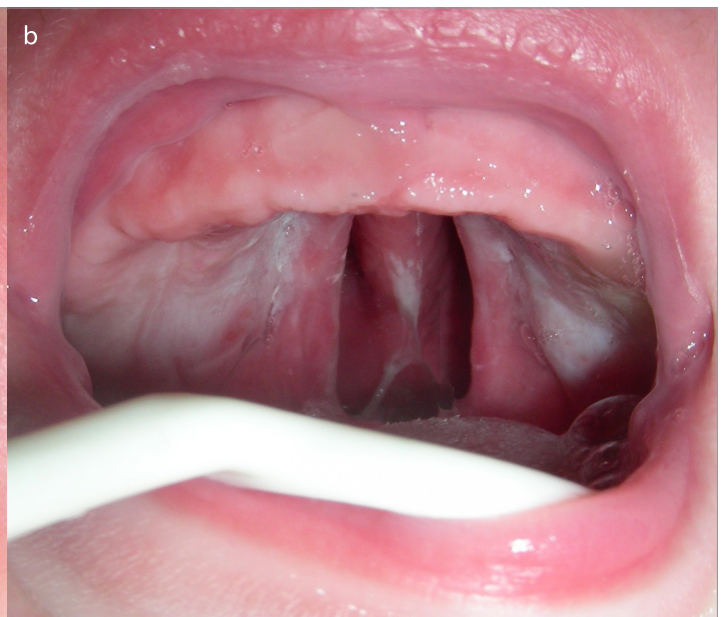
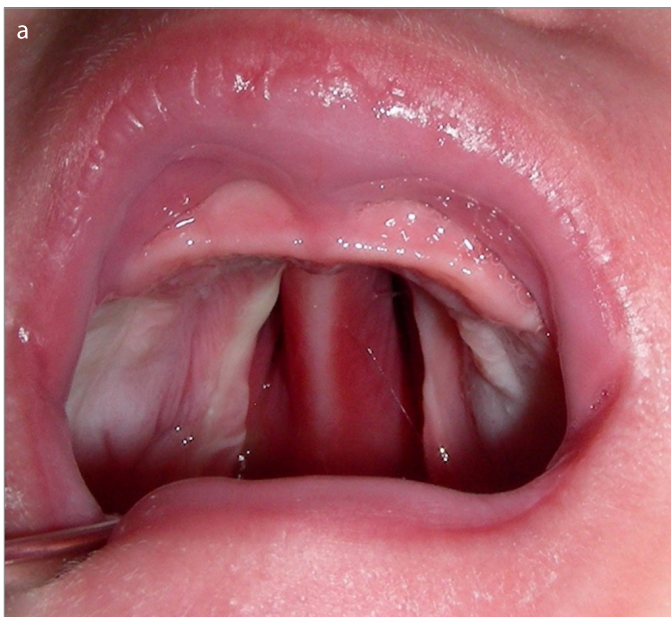
Figure 14. a, b. Variations in palate cleft size at starting time therapy (a) and after 5 months (b)

Case Series

We collected all the data of the 20 infants with PRS. All of them had a cleft palate, and 15 had a complete cleft palate.

The patients were referred to the Pre-Surgical Orthodontic Service both from the Pediatric Department of the same

hospital, Policlinico Umberto I of Rome, and from other hospitals.

All the patients were treated with the protocol mentioned above. The palatal plate was delivered to the patient and checked immediately both for presence of excessive pressure on the mucosa and for possibility to nipple or bottle feeding.

All the patients also underwent a polysomnographic control after the application of the plate to control the eventually present respiratory difficulties.

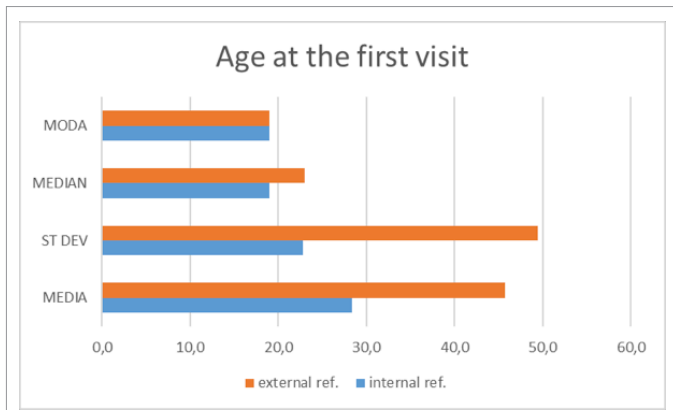
A second check for presence of eventually present decubitus was made 1 week after plate delivery.

From that moment, a periodical control in the pediatric unit, to verify the weight gain and the grooving curve of the patients, is planned, and the periodicity is decided from the global evaluation of the patient. The pediatric unit also takes care of the need of subsequent polysomnographic evaluation. A weight increase is considered an indirect index of the feeding efficiency with the use of the plate.

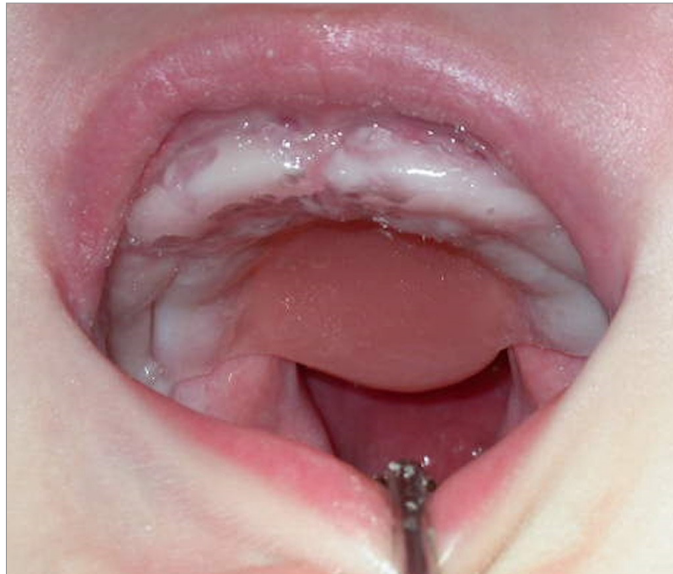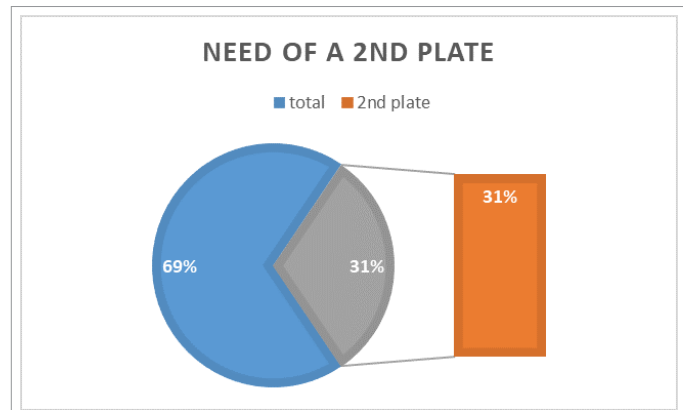


Figure 15. Obturator plate positioned

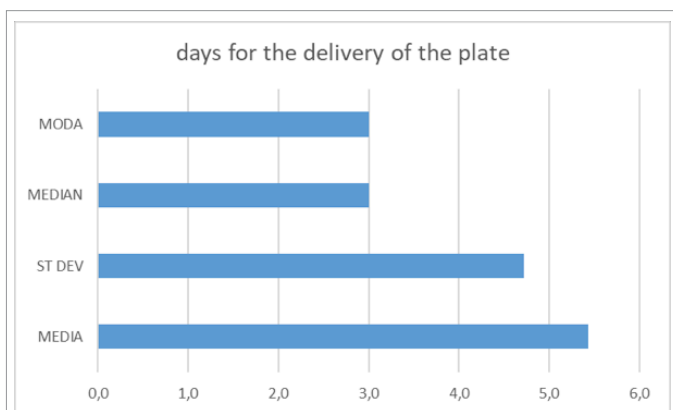
156



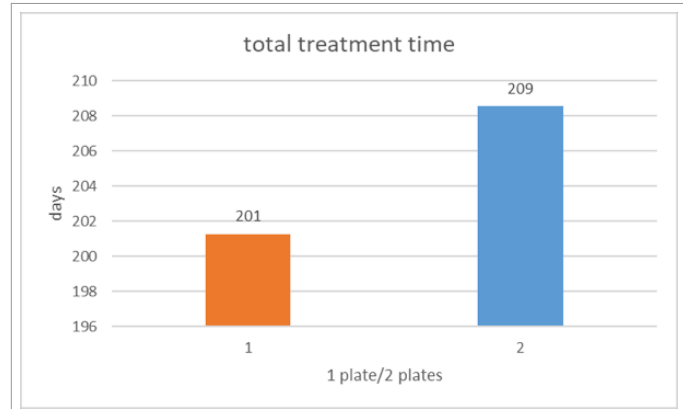
Graph 1. Patient's age at the first control (days)



Graph 3. The total number of patients needing a second plate was 9 out of 20 (31%)



Graph 2. Total time (days) needed for delivery of the plate



Graph 4. Treatment time in days in the group receiving one plate versus the group receiving two plates

RESULTS

The ages of the patients at the first visit were within the first 2 weeks (six cases), within month 1 (eight cases), and within month 4 (six cases) of life. The median age was different for subjects referred from the same hospital with respect to those coming from other hospitals (Graph 1).

Impressions for construction of the first functional obturator plate were made for 16 (80%) patients within 7 days from the first visit. In three patients, the impression was obtained between days 10 and 14 because the children had not been fasting within 4 h of the procedure. In fact, fasting for 4 h prior to the procedure is mandatory to prepare the patient for obtaining the impression for the functional obturator plate. In only 1 (5%) patient, there was a need to repeat the impression because the borders were not completely visible in the first one. The functional plate was delivered in a median time of 5 days, ranging between 1 and 10 days (Graph 2).

In only nine patients, there has been a need of a second plate to reach the target weight (Graph 3). The second plate was delivered at a median age of 119 ± 47 days. The total treatment time was 201 ± 55 days, with only a slight difference in the subgroup of patients needing two plates instead of only one (total treatment time 209 ± 54 days) (Graph 4).

DISCUSSION

In our decade-long clinical practice with children affected by PRS, the difficulties facing young patients are breathing and feeding order. The extreme heterogeneity of the family structure, such as geographic origin, caste, wealth, ethnicity, and education, led us to develop a therapeutic support system that is practical, functional, simple, and cost effective.

A positive aspect of the use of a functional plate is its simplicity of construction and management (Figure 12). The plate is constituted by a semilunar resin base recessed within, on which is spread a small amount of adhesive prosthetic paste. The adhesive paste, together with the precise plate adhesion to tissues, is very stable due to surface tension, without the need for extraoral aids, such as braces, hooks, plasters, or elastics (8-11).

The plate differs from the plate shape suggested by several authors (12-14) usually designed with pharyngeal extension, i.e., the pre-epiglottic baton plate (PEBP). The pharyngeal extension is dedicated to the increase of posterior respiratory space maintenance, but often is not well tolerated from the patient and more difficult to use during feeding (Figure 13).

The functional plate we suggest results in a palatal cleft filling while preventing the growth of the palatine processes and rather guiding and stimulating pre-surgical reduction of the size of the cleft (Figure 14. a, b).

The position of the plate causes a redistribution of the buccal space while reducing the height of the palate, and consequently, a postural re-education and lowering of the tongue happens,

thus stimulating mandibular growth (Figure 15). Moreover, the separation of the oral and nasal cavities is achieved, improving breathing without the need for hypopharyngeal extensions that can decrease the baby's comfort or necessitate frequent and removal. The rigidity of the functional plate allows the child to properly latch onto the mother's nipple and/or an artificial nipple, thus improving feeding.

Patient Cohort Analysis

All 20 patients in our cohort received an immediate benefit from the use of the functional obturator plate, particularly with regard to breathing and feeding. The presence of a functional plate enables them to feed without aspiration and coughing; latching is accomplished because the functional plate re-creates the palatal plane. Feedings are longer, more nutritious, and less fatiguing to the small patient.

An obvious comparison is with other palatal plate shapes used in the literature to close the cleft in those patients. PEBP, an "orthodontic appliance with a velar extension shifting the base of the tongue forward," is the most widely used as defined by Buchenau (11, 15).

As referred from the literature, the positive effect of the velar extension is to reduce apnea episodes due to the effect of shifting the tongue base forward. A certain difficulty in the degree of tolerance of this plate has been reported due to the gag reflex.

As verified in our sample, during sleep, the functional plate described avoids glossoptosis, reducing the phenomena of OSA.

If necessary, small adjustments to the plate can be made; the plate is applied as soon as possible for natural bottle feeding. This functional activity is very important to stimulate the lingual, perioral, and mandibular muscles to increase intraoral pressure and mandibular growth (Figure 11).

The use of a baby pacifier in association with the obturator plate favors the oral frontal seal. Its encumbrance pushes the tongue down and forward, stimulating a more correct position. The resulting muscular activation and increased intraoral pressure acts as a stimulus for mandibular growth.

Respiratory efficiency plays an important role in patient recovery.

As referred in the literature, "tongue-lip adhesion and tongue repositioning increase the efficiency of natural breathing reducing the number of apnea/hypopnea episodes" (16).

One of the positive effects of the palatal plate is the position of the tongue, forced forward from the lowering of the palatal surface; in addition, the closure of the palatal cleft avoids tongue insertion in this space, partially responsible of its backward fall. The final effect is so similar to a series of therapeutic approaches that imply a change in the tongue position, such as the tongue-lip adhesion. The lack of valuable randomized studies on the effect on the successful relief of the airway obstruction of the orthodontic appliances implies the need for further research (17), in particular comparing the results of the

respiratory pattern in patients treated with conservative functional approach with palatal plates to the breathing relief of the surgical approach (18, 19).

Further development of the present study could be referred to the evaluation of measurable parameters, such as polysomnographic records or the closure amount of cleft size or interarch widths or depth of the maxilla. For polysomnographic records, in the routine care of the hospitals considered, all these patients are initially monitored for respiratory status in the pediatric intensive care unit, where the polysomnographic record (PSG) is also performed. All these patients are discharged only if no risk of apnea-hypopnea is present; thus, data are not planned to be recorded periodically. Similarly, as also reported in the literature, a general agreement about the guideline for timing and periodical assessment of the PSG is still not achieved (22).

Finally, the appraisal of the changes of maxillary shape and depth and the possibility of a tridimensional evaluation before the surgical procedures is limited to the need of a new impression of the maxillary arch; thus, in the sample used for the present study, data were available only for subjects who underwent a second plate construction and only limited to the first phase of treatment.

Eventually, future improvement of the impression procedure would allow the patients to have several impressions also in the first period.

CONCLUSION

The use of a functional obturator plate, combined with the active use of a pacifier, causes neuromuscular and morphological changes of the stomatognathic system, removing functional alterations to mandibular growth and consequently beginning a process of structural and morphological normalization. This treatment with a functional plate reduces and, in some cases, eliminates the need for surgical intervention, such as tongue-lip adhesion (which was not performed), nasopharyngeal airway, or other types of interventions used to treat apnea. In fact, repositioning and re-education of lingual posture is essential to improve and permanently correct respiratory problems and gradually recover the sucking reflex (20, 21). In our view, the first stage of functional-orthopedic postural therapy could be aided by keeping the baby in the prone position. If after 15 days of plate application nutritional problems persist, a different surgical approach is necessary.

Ethics Committee Approval: Ethics committee approval was received for this study from the Ethics Committee of Sapienza University of Rome (2201/12).

Informed Consent: Written informed consent was obtained from the parents' or legal guardians of the patients who participated in this study.

Peer-review: Externally peer-reviewed.

Author Contributions: Concept - A.S., V.M.; Design - G.G.; Supervision - A.S., G.G.; Fundings - V.M., R.V.; Materials - A.S., V.M., R.V.; Data Collec-

tion and/or Processing - G.G.; Analysis and/or Interpretation - G.G., V.M.; Literature Search - E.B.; Writing Manuscript - G.G.; Critical Review - G.G., E.B.; Other - E.B.

Conflict of Interest: The authors have no conflict of interest to declare.

Financial Disclosure: The authors declared that this study has received no financial support.

REFERENCES

- Leonardo ME, Mantuano MT, Silvestri A. Nuovo inquadramento patogenetico disfunzionale e ruolo della terapia funzionale nella sequela di Pierre Robin. *Ortognatodonzia Italiana* 2000; 9-3: 339-44.
- Shprintzen RJ. The implications of the diagnosis of Robin sequence. *Cleft Palate Craniofac J* 1992; 29: 205-9. [\[CrossRef\]](#)
- Cole A, Lynch P, Slator R. A new grading of Pierre Robin Sequence. *Cleft Palate Craniofac J* 2008; 45: 603-6. [\[CrossRef\]](#)
- van Lieshout MJ, Joosten KF, Mathijssen IM, Koudstaal MJ, Hoeve HL, van der Schroeff MP, et al. Robin sequence: A European survey on current practice patterns. *J Craniomaxillofac Surg* 2015; 43: 1626-31. [\[CrossRef\]](#)
- Cascone P, Papoff P, Arangio P, Vellone V, Calafati V, Silvestri A. Fast and early mandibular osteodistraction (FEMOD) in severe Pierre Robin Sequence. *J Craniomaxillofac Surg* 2014; 42: 1364-70. [\[CrossRef\]](#)
- Kogo M, Okada G, Ishii S, Shikata M, Iida S, Matsuya T. Breast feeding for Cleft Lip and Palate Patients, using the Hotz-type Plate Cleft Palate Craniofac J 1997; 34: 351-3. [\[CrossRef\]](#)
- Hotz H, Gnoinski W. Comprehensive care of cleft lip and palate children at Zurich University: a preliminary report. *Am J Orthod* 1976; 70: 481-503. [\[CrossRef\]](#)
- Bacher M, Sautermeister J, Urschitz MS, Buchenau W, Arand J, Poets CF. An oral appliance with velar extension for treatment of obstructive sleep apnea in infants with Pierre Robin Sequence. *Cleft Palate Craniofac J* 2011; 48: 331-6. [\[CrossRef\]](#)
- Radhakrishnan J, Sharma A. Feeding plate for a neonate with Pierre Robin sequence. *J Indian Soc Pedod Prev Dent* 2011; 29: 239-43. [\[CrossRef\]](#)
- Oliver HT. Construction of orthodontic appliances for the treatment of newborn infants with cleft of the lip and palate. *Am J of Orthodontics* 1969; 56: 468-73. [\[CrossRef\]](#)
- Müller-Hagedorn S, Buchenau W, Arand J, Bacher M, Poets CF. Treatment of infants with Syndromic Robin sequence with modified palatal plates: a minimally invasive treatment option. *Head Face Med* 2017; 13: 4. [\[CrossRef\]](#)
- Gómez OJ, Barón OI, Peñarredonda ML. Pierre Robin Sequence: An Evidence-Based Treatment Proposal. *J Craniofac Surg* 2018; 29: 332-8.
- Poets CF, Bacher M. Treatment of upper airway obstruction and feeding problems in robin-like phenotype. *J Pediatr* 2011; 159: 887-92. [\[CrossRef\]](#)
- Poets CF, Maas C, Buchenau W, Arand J, Vierzig A, Braumann B, et al. Multicenter study on the effectiveness of the pre-epiglottic baton plate for airway obstruction and feeding problems in Robin sequence. *Orphanet J Rare Dis* 2017; 12: 46. [\[CrossRef\]](#)
- Buchenau W, Wenzel S, Bacher M, Müller-Hagedorn S, Arand J, Poets CF. Functional treatment of airway obstruction and feeding problems in infants with Robin sequence. *Arch Dis Child Fetal Neonatal Ed* 2017; 102: 142-6. [\[CrossRef\]](#)
- Camacho M, Noller MW, Zaghi S, Reckley LK, Fernandez-Salvador C, Ho E, et al. Tongue-lip adhesion and tongue repositioning for obstructive sleep apnoea in Pierre Robin sequence: A systematic review and meta-analysis. *J Laryngol Otol* 2017; 131: 378-83. [\[CrossRef\]](#)
- Bütow KW, Naidoo S, Zwahlen RA, Morkel JA. Pierre Robin sequence: Subdivision, data, theories, and treatment - Part 4: Recommended management and treatment of Pierre Robin sequence and its application. *Ann Maxillofac Surg* 2016; 6: 44-9. [\[CrossRef\]](#)

18. Ramieri V, Basile E, Bosco G, Caresta E, Papoff P, Cascone P. Three-dimensional airways volumetric analysis before and after fast and early mandibular osteodistraction. *J Craniomaxillofac Surg* 2017; 45: 377-80. [\[CrossRef\]](#)
19. van Lieshout MJ, Joosten KF, Mathijssen IM, Koudstaal MJ, Wolvius EB, van der Schroeff MP. Non-surgical and surgical interventions for airway obstruction in children with Robin Sequence. *J Craniomaxillofac Surg* 2016; 44: 1871-9. [\[CrossRef\]](#)
20. Mackay DR. Controversies in the diagnosis and management of the Robin sequence. *J Craniofac Surg* 2011; 22: 415-20. [\[CrossRef\]](#)
21. Turner L, Jacobsen C, Humenczuk M, Singhal VK, Moore D, Bell H, et al. The effects of lactation education and a prosthetic obturator appliance on feeding efficiency in infants with cleft lip and palate. *Cleft Palate Craniofac J* 2008; 38: XX [\[CrossRef\]](#)
22. Khayat A, Bin-Hassan S, Al-Saleh S. Polysomnographic findings in infants with Pierre Robin sequence. *Ann Thorac Med* 2017; 12: 25-9. [\[CrossRef\]](#)