

THE PRESENT AND FUTURE

JACC STATE-OF-THE-ART REVIEW

Cardiovascular Magnetic Resonance in Nonischemic Myocardial Inflammation



Expert Recommendations

Vanessa M. Ferreira, MD, DPHIL,^a Jeanette Schulz-Menger, MD,^b Godtfred Holmvang, MD,^c
Christopher M. Kramer, MD,^d Iacopo Carbone, MD,^e Udo Sechtem, MD,^f Ingrid Kindermann, MD,^g
Matthias Gutberlet, MD,^h Leslie T. Cooper, MD,ⁱ Peter Liu, MD,^j Matthias G. Friedrich, MD^{k,l,m}

JACC JOURNAL CME/MOC/ECME

This article has been selected as the month's JACC CME/MOC/ECME activity, available online at <http://www.acc.org/jacc-journals-cme> by selecting the JACC Journals CME/MOC/ECME tab.

Accreditation and Designation Statement

The American College of Cardiology Foundation (ACCF) is accredited by the Accreditation Council for Continuing Medical Education to provide continuing medical education for physicians.

The ACCF designates this Journal-based CME activity for a maximum of 1 AMA PRA Category 1 Credit(s)[™]. Physicians should claim only the credit commensurate with the extent of their participation in the activity.

Successful completion of this CME activity, which includes participation in the evaluation component, enables the participant to earn up to 1 Medical Knowledge MOC point in the American Board of Internal Medicine's (ABIM) Maintenance of Certification (MOC) program. Participants will earn MOC points equivalent to the amount of CME credits claimed for the activity. It is the CME activity provider's responsibility to submit participant completion information to ACCME for the purpose of granting ABIM MOC credit.

Cardiovascular Magnetic Resonance in Nonischemic Myocardial Inflammation: Expert Recommendations will be accredited by the European Board for Accreditation in Cardiology (EBAC) for 1 hour of External CME credits. Each participant should claim only those hours of credit that have actually been spent in the educational activity. The Accreditation Council for Continuing Medical Education (ACCME) and the European Board for Accreditation in Cardiology (EBAC) have recognized each other's accreditation systems as substantially equivalent. Apply for credit through the post-course evaluation. While offering the credits noted above, this program is not intended to provide extensive training or certification in the field.

Method of Participation and Receipt of CME/MOC/ECME Certificate

To obtain credit for JACC CME/MOC/ECME, you must:

1. Be an ACC member or JACC subscriber.
2. Carefully read the CME/MOC/ECME-designated article available online and in this issue of the *Journal*.

3. Answer the post-test questions. A passing score of at least 70% must be achieved to obtain credit.
4. Complete a brief evaluation.
5. Claim your CME/MOC/ECME credit and receive your certificate electronically by following the instructions given at the conclusion of the activity.

CME/MOC/ECME Objective for This Article: Upon completion of this activity, the learner should be able to: 1) identify patients with an appropriate indication for a CMR assessment for nonischemic myocardial inflammation; 2) describe the diagnostic targets used by cardiovascular magnetic resonance (CMR) to identify active myocardial inflammation; 3) discuss the Consensus Recommendations for CMR in nonischemic myocardial inflammation (2018 Update of the Lake Louise Criteria) in comparison with the original Lake Louise Criteria; 4) compare the diagnostic utility of CMR with that of other imaging modalities; 5) estimate the diagnostic accuracy of a CMR in patients with suspected myocardial inflammation; and 6) list the CMR techniques that are recommended in the 2018 Lake Louise Criteria.

CME/MOC/ECME Editor Disclosure: JACC CME/MOC/ECME Editor Ragavendra R. Baliga, MD, FACC, has reported that he has no financial relationships or interests to disclose.

Author Disclosures: Dr. Ferreira acknowledges support from the National Institute of Health Research Biomedical Research Centre, Oxford, and the British Heart Foundation Centre of Research Excellence, Oxford. Dr. Friedrich is a board member, adviser, and shareholder of Circle Cardiovascular Imaging. Dr. Kramer is a consultant for Bayer Healthcare; and has received a research grant from Biotelemetry. Dr. Schulz-Menger is a consultant for Bayer Healthcare and Siemens Healthineers. Dr. Gutberlet has received moderate speaker honoraria from Bayer, Bracco, Siemens, and Philips. All other authors have reported that they have no relationships relevant to the contents of this paper to disclose.

Medium of Participation: Print (article only); online (article and quiz).

CME/MOC/ECME Term of Approval

Issue Date: December 18, 2018

Expiration Date: December 17, 2019



Listen to this manuscript's audio summary by Editor-in-Chief Dr. Valentin Fuster on JACC.org.

From the ^aUniversity of Oxford Centre for Clinical Magnetic Resonance Research, John Radcliffe Hospital, Oxford, United Kingdom; ^bCharité-Universitätsmedizin, Department of Cardiology and Helios-Klinikum, DZHK-Partnersite-Berlin, Germany; ^cDivision of Cardiology and Department of Radiology, Massachusetts General Hospital, Boston, Massachusetts; ^dDepartments of Medicine (Cardiology) and Radiology, University of Virginia Health System, Charlottesville, Virginia; ^eDepartment of Radiological,

Cardiovascular Magnetic Resonance in Nonischemic Myocardial Inflammation

Expert Recommendations

Vanessa M. Ferreira, MD, DPHIL,^a Jeanette Schulz-Menger, MD,^b Godtfred Holmvang, MD,^c Christopher M. Kramer, MD,^d Iacopo Carbone, MD,^e Udo Sechtem, MD,^f Ingrid Kindermann, MD,^g Matthias Gutberlet, MD,^h Leslie T. Cooper, MD,ⁱ Peter Liu, MD,^j Matthias G. Friedrich, MD^{k,l,m}

ABSTRACT

This JACC Scientific Expert Panel provides consensus recommendations for an update of the cardiovascular magnetic resonance (CMR) diagnostic criteria for myocardial inflammation in patients with suspected acute or active myocardial inflammation (Lake Louise Criteria) that include options to use parametric mapping techniques. While each parameter may indicate myocardial inflammation, the authors propose that CMR provides strong evidence for myocardial inflammation, with increasing specificity, if the CMR scan demonstrates the combination of myocardial edema with other CMR markers of inflammatory myocardial injury. This is based on at least one T2-based criterion (global or regional increase of myocardial T2 relaxation time or an increased signal intensity in T2-weighted CMR images), with at least one T1-based criterion (increased myocardial T1, extracellular volume, or late gadolinium enhancement). While having both a positive T2-based marker and a T1-based marker will increase specificity for diagnosing acute myocardial inflammation, having only one (i.e., T2-based OR T1-based) marker may still support a diagnosis of acute myocardial inflammation in an appropriate clinical scenario, albeit with less specificity. The update is expected to improve the diagnostic accuracy of CMR further in detecting myocardial inflammation. (J Am Coll Cardiol 2018;72:3158-76) © 2018 Published by Elsevier on behalf of the American College of Cardiology Foundation.

PURPOSE OF AN UPDATE OF THE LAKE LOUISE CRITERIA

In 2009, the Consensus Criteria for Cardiovascular Magnetic Resonance (CMR) in Myocardial Inflammation (“Lake Louise Criteria”) were published (1). These criteria proposed 3 diagnostic targets in the myocardial tissue—edema, hyperemia, and necrosis or scar—derived from signal intensity assessment in T2-weighted, early gadolinium enhancement (EGE) and late gadolinium enhancement (LGE) CMR images. On the basis of published data, it was suggested to assume a high likelihood of acute myocarditis (inflammation) if the CMR images indicated that 2 out

of 3 criteria were positive (1). On the basis of a limited number of published studies at that time, the diagnostic accuracy had been estimated at 78%, with a sensitivity of 67% and a specificity of 91%. Since then, the Lake Louise Criteria have been used extensively in both clinical and research settings. Although some of the criteria and methods for their evaluation have been the subject of discussion, these numbers were largely confirmed by subsequent studies, including in vivo validation. These were summarized by recent meta-analyses evaluating the Lake Louise Criteria to identify acute myocarditis, with 1 reporting a pooled diagnostic accuracy of 83% (sensitivity, 80%; specificity, 87%) (2) and another reporting similar

Oncological and Pathological Sciences, Sapienza, University of Rome, Rome, Italy; ^fDepartment of Cardiology, Robert-Bosch-Krankenhaus, Stuttgart, Germany; ^gDepartment of Internal Medicine III, Saarland University Medical Center, Homburg/Saar, Germany; ^hDepartment of Diagnostic and Interventional Radiology, University of Leipzig, Heart Center, Leipzig, Germany; ⁱDepartment of Cardiology, Mayo Clinic, Rochester, Minnesota; ^jOttawa Heart Institute, Ottawa, Canada; ^kHeidelberg University Hospital, Heidelberg, Germany; ^lDepartment of Cardiology, McGill University Health Centre, Montreal, Canada; and the ^mDepartment of Diagnostic Radiology, McGill University Health Centre, Montreal, Canada. Dr. Ferreira acknowledges support from the National Institute of Health Research Biomedical Research Centre, Oxford, and the British Heart Foundation Centre of Research Excellence, Oxford. Dr. Friedrich is a board member, adviser, and shareholder of Circle Cardiovascular Imaging. Dr. Kramer is a consultant for Bayer Healthcare; and has received a research grant from Biotelemetry. Dr. Schulz-Menger is a consultant for Bayer Healthcare and Siemens Healthineers. Dr. Gutberlet has received moderate speaker honoraria from Bayer, Bracco, Siemens, and Philips. All other authors have reported that they have no relationships relevant to the contents of this paper to disclose.

Manuscript received July 18, 2018; revised manuscript received September 14, 2018, accepted September 25, 2018.

ABBREVIATIONS AND ACRONYMS

AUC	= area-under-the-curve
AUC*	= estimated area-under-the-curve
CMR	= cardiovascular magnetic resonance
ECG	= electrocardiogram
ECV	= extracellular volume
EGE	= early gadolinium enhancement
EMB	= endomyocardial biopsy
ESC	= European Society of Cardiology
GBCA	= gadolinium-based contrast agent
LGE	= late gadolinium enhancement
MR	= magnetic resonance

diagnostic accuracy based on 7 studies, with summary sensitivity of 78%, specificity of 88%, and area-under-the-curve (AUC) of 83% (3). CMR has informed clinical decision making in many thousands of patients and can avoid invasive procedures, such as coronary angiography and endomyocardial biopsies (EMBs) (3).

CMR tissue characterization using signal intensities only, however, has some shortcomings. When the inflammatory processes become increasingly diffuse throughout the myocardium (more common after the first several days as myocarditis transitions from acute to subacute), T2 and EGE signal intensity may also become progressively more homogeneous, to the point where discrete lesions may no longer be easily detected on qualitative review. Although diffuse changes

could still be identified as an increased global signal intensity ratio, normalized against reference regions in skeletal muscle, coexisting skeletal muscle inflammation may lead to false negative results (4,5). Furthermore, other noninflammatory conditions, such as infiltrative cardiomyopathies, may also increase the myocardial extracellular space and gadolinium uptake.

Technical advances, specifically the development of pixel-wise mapping of T1 and T2 relaxation times, have led to multiple studies reporting their clinical potential in patients with suspected myocardial inflammation. It is therefore timely to review the current published evidence and revise the Lake Louise Criteria accordingly.

BACKGROUND

Myocardial inflammation can be caused by the immune response to viruses, autoimmune disease, ischemic injury, or toxic agents (6,7), and it is an important underlying cause of chest pain and other symptoms. The cascade of pathophysiological mechanisms is complex, and therapeutic options, especially for viral myocarditis, are the subject of intense research (8). In the clinical setting of acute chest pain and cardiomyopathy, a diagnosis of myocardial inflammation by CMR imaging or biopsy can significantly affect prognosis and management (9,10). Imaging in the acute setting can provide valuable clues to the etiology of the presenting symptom(s), especially differentiating ischemic from nonischemic causes, and diagnosing valvular and pericardial disease (11). The current European Society of Cardiology (ESC) position statement (12) and the

American Heart Association (AHA) scientific statement on the management of myocarditis (13) consider CMR useful for the evaluation of suspected myocarditis. Although definitive confirmation of specific causes of myocarditis (e.g., viral) requires histopathologic and molecular biological evaluation of myocardial tissue samples, CMR has a unique role in both the noninvasive detection and exclusion of myocardial inflammation. This is especially relevant in cases involving the epicardium, pericardium, or other regions not accessible to EMB, as well as assessment of alternate diagnoses responsible for the acute presentation. CMR is able to provide a noninvasive, biopsy-like approach to verify pathognomonic imaging features of myocardial inflammation, and the current ESC guidelines on acute and chronic heart failure include a Class I indication for CMR for the assessment of myocarditis and storage diseases (14).

CMR characteristics of myocardial inflammation may not only aid in the diagnosis of myocarditis, but also provide information on prognosis. Although inflammatory syndromes often evolve over days to weeks and then resolve, they may also transition into chronic dilated cardiomyopathy. The course of myocardial inflammation limits the optimal sensitivity for diagnostic imaging to a few weeks from presentation (15). Within this window, however, CMR can identify useful features, which may also predict outcome (16). In acute cases, myocardial edema without LGE on CMR has been associated with improved recovery and outcomes (17). In adults requiring ventricular assist device support, myocarditis is one of the best predictors of a bridge to recovery (18). In cases of acute viral heart disease, the CMR pattern of myocardial inflammation may vary, and findings on edema-sensitive T2-weighted images correlate with the presence of viral genomes in the blood (19). CMR provides incremental data to EMB that may aid disease management (20). Thus, CMR has evolved to become a key evaluation tool in patients with suspected myocardial inflammation.

CLINICAL CONTEXT OF PATIENTS WITH SUSPECTED MYOCARDIAL INFLAMMATION

CLINICAL PRESENTATION. Patients with myocarditis may present with a broad spectrum of symptoms related to the various cardiac structures involved in the inflammatory process (cardiomyocytes, interstitium, endothelium, and pericardium) (6,11). These symptoms range from mild discomfort caused by palpitations or nonspecific chest pain to more dramatic clinical features similar to acute myocardial infarction, including angina pectoris, and ST-segment

elevations on electrocardiogram (ECG), as well as elevated markers of myocyte necrosis (troponin, creatine kinase). Acute congestive heart failure, with or without cardiogenic shock, or progressive chronic heart failure can occur. Furthermore, supraventricular and ventricular tachyarrhythmias, as well as bradyarrhythmias and intraventricular conduction delays, are common in these patients (21).

The acute phase of viral myocarditis lasts only for a few (1 to 3) days. It is characterized by pathognomonic myocyte necrosis induced by virus replication after infection. The resulting exposure of intracellular antigens may lead to the activation of a cascade of humoral and cellular immunologic processes aimed to eliminate the virus in the myocardium. In some patients, this immunologic reaction may persist for several weeks or months, independent of myocardial viral genome detection, thus resulting in chronic post-infectious autoimmune myocarditis (6,9).

CLINICAL WORK-UP OF ACUTE MYOCARDIAL INFLAMMATION. In suspected acute myocardial injury, acute coronary syndrome and stress-induced cardiomyopathy should be excluded, especially in patients with chest pain, heart failure, or new arrhythmia. The clinical presentation and symptoms of a patient with acute myocardial inflammation may provide clues to the etiology of the disease, such as recent exposure to toxic or allergenic agents. Regarding viral myocarditis, the position statement of the ESC Working Group on Myocardial and Pericardial Diseases (2013) proposed new diagnostic criteria, which are intended to reinforce the diagnosis (12). According to this statement, myocarditis is suspected if 1 or more symptoms, such as chest pain, dyspnea, fatigue, palpitations, or syncope, and at least 1 of the diagnostic (including CMR) criteria in Table 1, are present. Most of the recommendations were based on assessment of viral myocarditis, but they can be extended to myocardial inflammation of other causes.

OTHER TESTS FOR MYOCARDIAL INFLAMMATION. Several laboratory tests are recommended in patients with clinically suspected myocarditis (12), although serum markers of inflammation are not very sensitive (22), and routine viral serology testing is not very specific (23).

Standard 12-lead ECG may show ST-segment elevation, T-wave changes, and conduction abnormalities, as well as arrhythmia, but these ECGs are neither specific nor sensitive enough to allow a definitive diagnosis (12,21) or rule out inflammatory heart disease (24) as a stand-alone diagnostic test.

Echocardiography may help to rule out other causes of heart failure, such as valvular disease,

TABLE 1 Diagnostic Tests and Potential Findings in Patients With Acute Myocarditis*

ECG, Holter, or stress test
AV block I-III, bundle branch block, sinus arrest
Extrasystoles
Supraventricular tachycardia, atrial fibrillation
Ventricular tachycardia, ventricular fibrillation, asystole
ST-segment and T-wave changes (ST-segment elevation, T-wave inversion)
Intraventricular conduction delay
New Q waves
Low voltage
Seromarkers for myocardial necrosis
Troponin elevation
Creatine kinase elevation
Cardiac imaging
Echocardiography/angiography
Regional or global systolic or diastolic dysfunction, with or without LV dilatation
Increased wall thickness
Pericardial effusion
Intracavitary thrombi
CMR
Edema
Hyperemia or capillary leak (early gadolinium enhancement)
Irreversible injury (necrosis, scar; late gadolinium enhancement)
Regional or global systolic or diastolic dysfunction, with or without LV dilatation
Increased wall thickness
Pericardial effusion
Intracavitary thrombi

*Clinically suspected myocarditis if ≥1 clinical presentation and ≥1 diagnostic criteria from different categories, in the absence of: 1) angiographically detectable coronary artery disease (coronary stenosis ≥50%); 2) known pre-existing cardiovascular disease or extracardiac causes that could explain the syndrome (e.g., valve disease, congenital heart disease, hyperthyroidism). Suspicion is higher with higher number of fulfilled criteria. If the patient is asymptomatic, ≥2 diagnostic criteria should be met. Modified with permission from Caforio et al. (12).
 AV = atrioventricular; CMR = cardiovascular magnetic resonance; ECG = electrocardiogram; LV = left ventricular.

congenital heart disease, or other cardiomyopathies, and to monitor significant changes of wall motion (12,25). In case of acute myocardial inflammation, echocardiography may show normal or altered ventricular dimensions, impaired function, and, less frequently, increased wall thickness secondary to edema, whereas chronic myocarditis may manifest with ventricular dilatation and regional or global hypokinesis. These changes are nonspecific but may be useful for longitudinal studies. Echocardiography may also help visualize pericardial effusion or intracavitary thrombi (6).

Recently, positron emission tomography (PET) has shown good agreement with CMR criteria of inflammation (26), although its clinical use remains uncommon because of limited availability and high cost. Table 1 lists the currently used noninvasive diagnostic procedures and potential findings in myocarditis (12).

Endomyocardial biopsy (EMB) is still the gold standard for identifying the specific etiology of

myocarditis, and it uses histopathologic, immunohistochemical, and molecular biological criteria. In the hands of experienced operators, EMB has a low complication rate of <1% (27). According to the recommendations of the American Heart Association, the American College of Cardiology, and the ESC, the indication for EMB should be considered for patients with acute (<2 weeks), severe new onset heart failure with hemodynamic compromise, as well as new onset heart failure (between 2 weeks and 3 months) with a dilated left ventricle and new ventricular arrhythmias, atrioventricular block II to III, or failure to respond to medical therapy and usual care within 1 to 2 weeks (Class I, Level of Evidence: B) (28). For patients with an infarction-like presentation, the ESC Working Group statement recommends EMB after the exclusion of coronary heart disease (12), whereas more recent heart failure guidelines grant CMR a Class I recommendation to identify myocarditis in patients with suspected or established heart failure (14). EMB should also be considered in patients with persistently elevated troponin values and progressive cardiac dysfunction despite maximal heart failure therapy. The pre-procedural localization of inflammatory changes in CMR images may reduce sampling errors and improve therapeutic decision making and prognostication (29-31).

DIAGNOSTIC TARGETS OF CMR IN MYOCARDIAL INFLAMMATION

CMR imaging sequences are sensitive to the tissue changes that occur during myocardial inflammation, regardless of etiology. These pathophysiological changes include: dilatation of the myocardial vascular bed with hyperemia; increased vascular permeability or capillary leak; edema (both intracellular and interstitial); myocyte injury with loss of cell membrane integrity; myocyte necrosis; accumulation of debris in the extracellular space; infiltration of inflammatory cells or macrophages; and, ultimately, collagen deposition with formation of interstitial fibrosis and scar. The magnitude and spatial extent of these changes depend on the severity of the inflammation. Although there may be distinct types of clinical presentations of myocardial inflammation (e.g., infarct-like or heart failure-like), ultimately, the determinants of clinical presentation in an individual are multifactorial, including the etiology of myocarditis, the load of the offending agent, the degree of severity, and the extent of the inflammatory process, as well as host factors, such as the immune response and symptoms experienced. Accordingly, CMR

detects only the presence or absence of signal changes that are the result of underlying tissue inflammation, but in most cases it does not define the origins of the myocardial inflammation that is observed. However, CMR may be useful as a phenotypic tool to examine for any systematic differences or characteristics among patients' subgroups on the basis of presentation features.

MYOCARDIAL EDEMA. Tissue edema, mediated by bradykinin, serotonin, and prostaglandins, is a hallmark of inflammation in all soft tissues. Clinically relevant inflammation inevitably includes edema of the affected tissue. On CMR, the increased tissue water content (edema) causes prolongation of both T1 and, especially, T2 relaxation times in the myocardium. Several CMR approaches can therefore be used to detect edema. In T2-weighted images, edema appears as regional or global signal hyperintensity. T2 mapping allows for the direct measurement of the water-induced prolongation of myocardial T2 relaxation time (32). Edema also leads to an increase of myocardial T1 relaxation time (33), although the increase of T1 is less specific for active inflammation because it can also be seen in areas of fibrosis where free water may accumulate (34). It is important to note that myocardial edema can also result from venous congestion as in acute decompensated heart failure (35).

HYPEREMIA AND CAPILLARY LEAK. In addition to the increased free water content of tissue, inflammation also leads to hyperemia, increased vascular permeability, and a net expansion of the extracellular space. CMR techniques to target these changes include T1-weighted spin echo images acquired pre-administration and early post-administration of an extracellular gadolinium-based contrast agent (GBCA) (36). Because gadolinium in its ligated form is an extracellular contrast agent, it is believed that the increased volume of distribution available for GBCA leads to greater contrast enhancement compared with noninflamed myocardium, although it ultimately remains unclear whether these methods can specifically reflect hyperemia or are just markers of an expansion of the extracellular space.

NECROSIS AND FIBROSIS. If the inflammation is severe enough to cause myocyte injury, followed by necrosis, fibrosis, and scarring, there will be a further substantial increase in the volume of distribution available for GBCA, as the contrast agent gains access to the intracellular space of myocytes that are injured or no longer viable. Studies using LGE images have identified common patterns of the regional

distribution of such injuries. These images have become well established as an invaluable tool for identifying the “signature pattern” of nonischemic inflammatory injury and to differentiate it from other types of myocardial disease. Myocarditis lesions tend to be patchy, subepicardial (in contrast to ischemic lesions that involve the subendocardium), and mid-wall and to favor the basal to mid-inferolateral walls. Exceptions do occur, and in severe inflammation, the high-signal intensity regions may extend fully through to the subendocardium. Myocardial inflammation secondary to hypereosinophilia syndromes typically shows a circumferential subendocardial LGE pattern that does not localize to any specific coronary territory (37).

FUNCTIONAL ABNORMALITIES. Dysfunction (“*functio laesa*”) is considered a feature of inflammation. Dysfunction in myocarditis, however, can be focal, and the surrounding myocardium may compensate by an increase in contractility, which lets the tethered, affected myocardium appear inconspicuous. Furthermore, the predominantly subepicardial involvement of more severe injury may leave the contraction of other myocardial layers unaffected. Wall motion abnormalities can be the result of other conditions, and ejection fraction may be preserved even in the presence of elevated T2 or LGE abnormalities. Thus, ventricular dysfunction is neither a very sensitive nor a specific finding for myocardial inflammation. However, if there is evidence for a recent, rapid decline in ventricular function, the list of other noninflammatory causes is relatively short and may be easy to exclude (e.g., tachycardia-mediated, chemotherapy, alcohol, thyroid disorders), an ischemic injury can usually be excluded by the LGE images. Myocardial strain mapping may increase sensitivity for detection of subtle wall motion abnormalities but is unlikely to add specificity for myocardial inflammation. Overall, functional abnormalities are considered a supportive criterion for myocardial inflammation.

PERICARDIAL ABNORMALITIES. Myocardial inflammation may be associated with pericardial involvement, and vice versa. The presence of pericardial effusion alone does not prove pericarditis because this may simply reflect coexisting heart failure. Active pericardial inflammation, however, becomes likely if there is associated thickening of the pericardial layers in high-resolution fast spin echo T1 images, hyperintensity of the pericardium on T2-weighted images, T2 or T1 mapping, and abnormal pericardial LGE (38). Pericardial abnormalities indicating inflammation are considered a supportive criterion.

NOVEL CMR MAPPING TECHNIQUES FOR DETECTING MYOCARDIAL INFLAMMATION

Recently, there has been substantial progress in the development of CMR mapping techniques, allowing efficient measurement of myocardial T1 and T2 relaxation times in patients with acute myocardial inflammation (5,39). T1 and T2 relaxation times are magnetic properties of tissue that are influenced by intrinsic tissue characteristics, their extrinsic environment, and method of measurement, including hardware and software platforms. Each tissue type has a specific normal range of T1 and T2 relaxation times (dependent on the method of measurement), deviation from which may indicate disease or a change in physiology. T1 and T2 relaxation times are calculated on a pixel-by-pixel basis and displayed as maps; global or regional myocardial T1 or T2 values can then be obtained. The extracellular volume (ECV) may also be estimated in myocarditis using T1 maps acquired pre- and post-administration of GBCA and adjusting for the hematocrit value (40). Beyond providing global T1, T2, or ECV values, advanced image analysis may be required, and is recommended as necessary, for identifying regional abnormalities and nonischemic patterns of acute myocardial injury compatible with myocarditis, on the basis of validated thresholds, and potentially pixel heterogeneity (5,39,41-43).

Cardiac mapping is a rapidly evolving field, and thus standardized methods and protocols are still being established. For T1 mapping, the most widely used approaches include inversion recovery (e.g., modified Look-Locker inversion recovery [MOLLI], shortened modified Look-Locker inversion recovery [ShMOLLI]), saturation recovery (saturation recovery single-shot acquisition [SASHA]), or hybrid methods (44). T2-mapping techniques commonly use gradient and spin echo using multiecho readouts (39,45,46). Because mapping is sensitive to the hardware and software used, local validation should be performed and benchmarked against established norms for a chosen method (44). Significant deviation from known norms for a method should prompt investigation, so that any issues with method implementation or application may be addressed. Validated diagnostic thresholds are likely to be method-specific. It is important to note that the use of thresholds (whether semiquantitative or quantitative) is always a trade-off between sensitivity and specificity in detecting a disease entity. The diagnostic performance of CMR for detecting myocarditis, whether using conventional methods or newer

TABLE 2 Descriptive Statistics of Currently Available Evidence Comparing the Diagnostic Performance of CMR Markers for the Detection of Acute Myocarditis (see also Figure 1 and Online Appendix)

CMR Criteria	Median AUC* (Total Range)	Number of Published Studies	Total Number of Cases
Individual			
T2W imaging	73 (58-100)	13	981
EGE	73 (62-93)	10	711
LGE	83 (53-96)	14	1,073
T1 mapping	89 (71-99)	9	682
T2 mapping	80 (73-86)	6	449
Extracellular volume	74 (59-82)	7	555
Combinations			
Original Lake Louise Criteria	84 (57-90)	8	630
T2W + LGE	76 (71-89)	3	191
T2W + EGE	75	1	45
EGE + LGE	70	1	45
T2 mapping + LGE	90 (83-97)	2	120
T2 mapping + T1 mapping	86	1	36
T2W + T1 mapping	84 (73-95)	2	176
T1 mapping + LGE	96 (82-97)	5	350

AUC* = estimated area-under-the-curve, calculated as the average of the sensitivity and specificity reported for each combination in published studies (this allowed direct comparison of various combinations even for studies which did not provide the actual AUC); CMR = cardiac magnetic resonance; EGE = early gadolinium enhancement; LGE = late gadolinium enhancement; T2W = T2-weighted imaging.

mapping techniques, depends on multiple factors, including the method's metrological properties, hardware and software platforms, end-user adherence to prescribed protocols and experience, the quality of the images, and standardization. Further recommendations on the setup and use of parametric mapping methods may be found in consensus statements published in conjunction with scientific bodies such as the Society for Cardiovascular Magnetic Resonance (SCMR) and the European Association of Cardiovascular Imaging (EACVI), which may release regular updates as the field evolves (44,47). The Consensus Group looks forward to more data becoming available regarding the possibility of using a standardized phantom to relate T1, ECV, and T2 measurements of normal ranges and diagnostic thresholds, across different magnetic resonance imaging (MRI) system vendors, pulse sequences, and imaging sites.

MAPPING OF T1 AND T2 FOR THE DETECTION OF MYOCARDIAL INFLAMMATION

Inflamed myocardium exhibits higher values of T1, T2, and ECV, all of which can be quantified directly without relying on relative signal intensity changes, thereby circumventing the limitations of semi-quantitative tissue characterization techniques.

Multiple studies have described excellent sensitivity, specificity, and diagnostic accuracy achieved by mapping techniques for the CMR evaluation of suspected myocarditis. Table 2 and the Online Appendix (including Online Figures 1 and 2 and Online Tables 1 to 3) provide pooled data from currently available clinical studies on the diagnostic performance of the original Lake Louise Criteria I and novel mapping techniques (2).

For example, Ferreira et al. (42) reported an 89% diagnostic accuracy of native T1 mapping alone in patients hospitalized for acute myocarditis studied within 14 days of symptom onset. In the MyoRacer myocarditis trial (which used EMB as the diagnostic standard), native T1 mapping yielded the highest diagnostic accuracy (81%) of all the CMR parameters tested in the patient group with acute symptoms (≤ 14 days from symptom onset to hospital admission), but accuracy dropped to 45% in differentiation from the chronic group (studied >14 days after onset of symptoms) (15). The MyoRacer trial included patients with chronic heart failure, as long as they had evidence of recent systemic viral disease. Studies in suspected chronic myocarditis are also more likely to include patients with heart failure secondary to other noninflammatory forms of heart disease known to be associated with prolongation of myocardial T1 values (and ECV expansion). These may include infiltrative cardiomyopathies, such as amyloidosis, or diffuse myocardial fibrosis from any of multiple causes, resulting in reduced specificity for acute inflammation (a similar limitation described for the EGE technique).

There is evidence that T2 mapping may be more specific for acute inflammation compared with T1 mapping, which is also sensitive to detection of water in more chronic settings, such as in areas of scarring, ischemia, or other causes of expanded extracellular space, and this deserves further investigation. In the MyoRacer trial, T2 mapping was the only CMR parameter with acceptable diagnostic accuracy (73%) for detecting biopsy-proven myocarditis in patients with chronic (>14 days) symptoms (15). This finding underlines the complementary nature of T1- and T2-based measurements and the need to include both in the CMR protocol on the basis of current evidence. T1 and T2 elevations are most marked during early, acute inflammation (48). As acute inflammation and tissue edema subside, the associated prolongation of T1 and T2 relaxation times also diminishes, eventually leaving only sequelae in the form of residual subepicardial or midwall fibrosis or scar, typically seen on LGE images. Both T1 and T2 are sensitive to changes in tissue water, but method design and MRI

parameters, including magnetization transfer effects (49), may highlight certain magnetic resonance (MR) signals in certain disease settings. Larger and longer-term studies on mapping techniques are needed to determine their clinical impact on patients in myocarditis.

EVIDENCE OF CLINICAL UTILITY OF CMR IN PATIENTS WITH SUSPECTED ACUTE MYOCARDIAL INFLAMMATION

The original Lake Louise Criteria I provide a good overall diagnostic performance (Table 2, Figure 1), and thus they should remain in use in centers that have good experience with their application. Any diagnostic criteria should include diagnostic targets associated with inflammation, such as: 1) myocardial edema; 2) global hyperemia and capillary leak (increased vascular and extravascular space); and 3) focal necrosis, fibrosis, or scar.

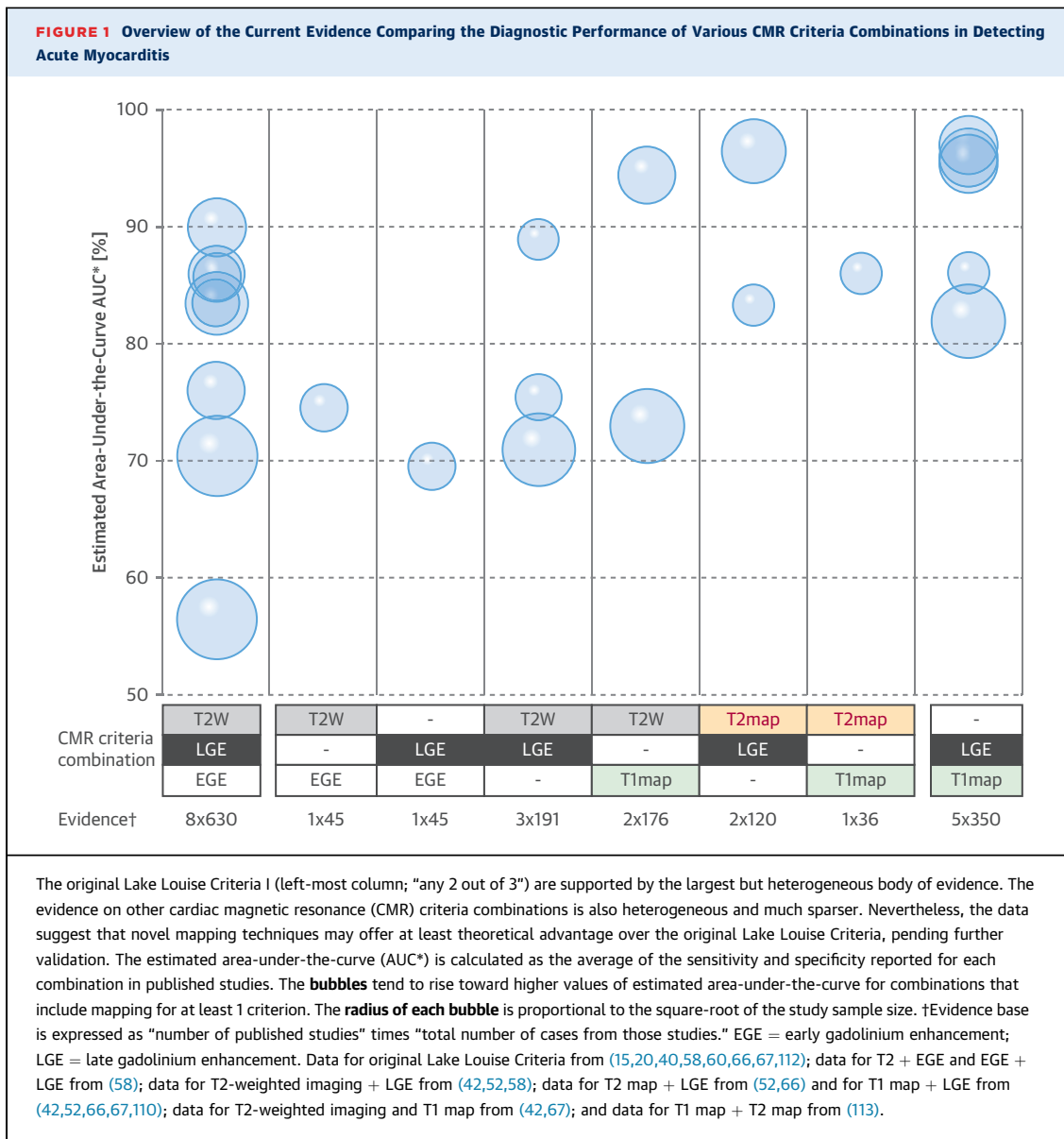
MYOCARDIAL EDEMA (T2-WEIGHTED IMAGING). Black-blood spin echo sequences (typically as a short-tau inversion recovery sequence [STIR]) exploit T2 and T1 changes in myocardial edema (50,51), and they generally have very good accuracy (52). Triple inversion recovery (IR) techniques typically allow for more homogeneous fat suppression compared with dual IR techniques with chemical fat saturation, but this comes with a signal-to-noise penalty. T2-prepared steady-state free precession (SSFP)-based bright blood sequences appear to be an alternative, albeit less robust for detecting global myocardial edema (33). Systolic images of regular SSFP cine sequences can also be helpful in detecting regional signal hyperintensity in edematous areas (53). When no localized T2 hyperintensity is visible in the images to allow identification of focal inflammatory lesions, the increase in global T2 signal can still be detected by an increased ratio of signal intensity in the myocardium relative to a reference region in skeletal muscle within the same image (with a ratio of ≥ 2.0 considered abnormal) (1). The ratio may vary slightly among MR systems, and it also depends on the use of the integrated body coil. A recent study found that the presence of transmural edema, as visualized in T2-weighted CMR images, was the only independent predictor of T-wave inversions observed on the ECG (odds ratio: 9.96; 95% confidence interval: 2.71 to 36.6) (54). However, the technique is often limited by an inherently low signal-to-noise ratio, susceptibility to arrhythmia and motion, and inconsistent image quality (55,56). Data indicate that the main value of T2-weighted imaging, when the image quality is

good, lies in its ability to rule out significant myocarditis (negative predictive value of 80%) (2). Of note, the involvement of skeletal muscle in a systemic inflammatory disease may yield false negative results for the ratio (5,57).

HYPEREMIA AND CAPILLARY LEAKAGE (EARLY GADOLINIUM ENHANCEMENT). The increased uptake of an interstitial contrast agent can be visualized and semiquantitatively assessed in T1-weighted CMR images before and early after GBCA administration. The uptake can be quantified using the myocardial signal intensity enhancement relative to a skeletal muscle reference region in the same image (with a ratio of ≥ 4.0 consistent with inflammation). This has been referred to as the early gadolinium enhancement ratio. Alternatively, the contrast media-induced relative myocardial signal intensity increase (cutoff 45%) can be used. The value of the ratio may vary slightly among different MR systems and settings. EGE is considered useful by many experts; yet, in most centers, it is not routinely used because of difficulties with the consistency of image quality. Recent data indicated that removing EGE from the original Lake Louise Criteria does not significantly reduce diagnostic accuracy for myocarditis, although the positive likelihood ratio may be slightly lowered (58). EGE has been considered useful as a third CMR technique, especially in cases of nondiagnostic image quality of either T2-weighted or LGE imaging. Thus, centers experienced in the use of EGE and without access to myocardial mapping sequences may prefer to use the original Lake Louise Criteria that include EGE.

MYOCARDIAL NECROSIS AND FIBROSIS (LATE GADOLINIUM ENHANCEMENT). If inflammation is severe enough, it will cause cell death, which leads to necrosis and an additional compartment for GBCA accumulation. Following a delay after injection (typically about 10 min) to allow time for contrast to wash out of noninjured myocardium, there is a GBCA concentration differential between regions with more severe versus less intense or absent myocyte damage. This allows visualization of the necrosis and scarring as a result of the differential enhancement. Inversion-recovery prepared gradient echo pulse sequences are used to produce LGE images, to visualize the lesions by nulling the signal intensity of reference normal myocardium to zero.

As the acute inflammatory lesions (necrosis) transition to fibrosis and scar formation, the markers of active inflammation gradually resolve, whereas the regional LGE usually persists on follow-up imaging because GBCA distributes into the extracellular space



of the collagen matrix in a manner similar to the evolution of an ischemic scar. The spatial extent of LGE lesions shrinks over time (59) and their signal intensity tend to increase, as the tissue swelling from edema subsides and the scar contracts, but despite these changes over time, LGE imaging alone cannot, by itself, reliably differentiate between a recent and a remote episode of myocarditis.

LGE is widely used for detecting regional replacement fibrosis or other forms of irreversible injury, infiltration, or fibrous degeneration. In acute, "infarct-like" myocarditis, its sensitivity is high (60). LGE use in isolation is not recommended, however, because it is not very sensitive in very mild cases and

is not specific for active or acute inflammation, especially in cases of predominantly global edema. It should be emphasized that, although LGE specifically detects expanded extracellular space caused by the disease process (e.g., myocyte necrosis, fibrosis, or edema), it does not signal inflammation itself.

Most clinical studies have used clinical criteria to define myocardial inflammation. EMB studies, however, may also suffer from selection bias because of the narrow range of clinical indications for EMB in more severe and chronic cases and the need for an invasive procedure. In the absence of the true gold standard, which is the whole-heart specimen for histopathologic examination for myocardial

inflammation, limitations to commonly used diagnostic tools would need to be acknowledged and accepted for pragmatic clinical practice.

EVIDENCE FOR NOVEL CMR MAPPING TECHNIQUES (T2 MAPPING, T1 MAPPING, AND ECV)

T2 MAPPING. Experimental and clinical studies have shown that T2 mapping can identify acute myocardial edema, with very good diagnostic accuracy when compared with traditional T2-weighted imaging (15,39,61,62). Specific advantages of mapping, such as higher signal-to-noise ratio, shorter breath-holds with fewer breathing motion artifacts, and direct quantification, all improve intraobserver and interobserver variability and diagnostic confidence. The sensitivity of T2-weighted imaging in chronic stages of myocardial inflammation has been questioned (20,63,64), although patient selection and definition of chronic myocarditis may have introduced bias. Recently published data, conversely, demonstrated an advantage of T2 mapping over T2-weighted imaging in patients with biopsy-proven active chronic myocarditis (15). Like T2-weighted imaging, T2 mapping may be particularly useful in ruling out active inflammation (sensitivity of 89% [52]). Recent data confirm the ability of T2 mapping to discriminate active from healed myocarditis (65). Because of its specificity for acute processes, the presence of edema in the absence of acute ischemic injury is considered an important criterion for inflammation.

NATIVE T1 MAPPING. As discussed, T1 relaxation time is highly sensitive to detecting both acute and chronic forms of increased free water content within the myocardium and thus may be best paired with T2-based imaging to augment the specificity for active inflammation and edema in myocarditis (42). Additionally, in acute myocardial inflammation, vasodilation, hyperemia, and increased interstitial space also increase native T1 (42,66). Native T1 is sensitive to intracellular and extracellular changes in free water content.

Several studies have shown that T1 is increased in acute (5,42,67,68) and chronic (52,65,68) myocarditis. Although some data suggested that native T1 may allow for differentiating different stages of myocarditis (68), there is considerable overlap between results found in acute and convalescent myocarditis, given that areas of chronic regional or diffuse fibrosis also increase T1 (69,70). Accordingly, a recent study indicated that T1 alone may not be able to discriminate acute from chronic disease (52). Thus, an increased myocardial T1 should be considered a

sensitive marker for diseased myocardium and not necessarily specific for the activity of the disease. This profile resembles the experience with EGE, which has also been found to remain increased even after clinical convalescence (65), as well as with LGE. The high overall negative predictive value of T1 mapping (92%) (2) makes it especially useful for ruling out myocardial inflammation.

EXTRACELLULAR VOLUME MAPPING. ECV also detects an expanded extracellular space. In contrast to LGE imaging, ECV may also detect milder but global processes such as diffuse edema and fibrosis, which may be very useful as an additional biomarker (40,71) for identifying changes not detected by LGE (72). More evidence is needed to demonstrate its incremental value beyond LGE in combination with the aforementioned CMR tissue characterization approaches, especially the native mapping techniques.

THE DIAGNOSTIC PERFORMANCE OF VARIOUS CMR CRITERIA COMBINATIONS

Figure 1 provides an overview of current evidence on the diagnostic accuracy of CMR in detecting acute myocarditis. The original Lake Louise Criteria (“any 2 out of 3”) currently has the largest evidence base supporting its diagnostic performance in detecting acute myocardial inflammation. Removing EGE does not appear to hamper the diagnostic performance of the original Lake Louise Criteria substantially, consistent with previous findings (58), and T2-weighted imaging combined with LGE (“2 out of 2”) demonstrates a reasonable ability to detect acute myocarditis. Although other “2 out of 2” combinations, such as “T2-weighted imaging + EGE” or “LGE + EGE,” are possible, their performance is reported by only 1 study of 45 cases.

In **Figure 1**, the diagnostic ability of CMR combination criteria for detecting myocarditis, as assessed using estimated AUC (AUC*), indicates varied performance, even within a particular combination (e.g., T2-weighted imaging, EGE, or LGE). This may be driven in part by the desire to optimize sensitivity over the specificity, which decreases the AUC*. Similar conclusions may be drawn from meta-analysis of currently available published data ([Online Appendix](#)). Although various statistical approaches are possible (3), they are subject to the choice of methods and assumptions made about the underlying data distributions (73,74). Most importantly, summary comparisons conceal the high degree of heterogeneity in published reports, as demonstrated in **Figure 1** (see also the Statistical Methods section in the [Online Appendix](#) for a discussion of formal measures

TABLE 3 Updated Recommendations of CMR Criteria of Myocardial Inflammation

Original Lake Louise Criteria I (Any 2 Out of 3)	Updated Lake Louise Criteria II (2 Out of 2)	Diagnostic Targets
Main criteria		
T2-weighted imaging Regional* high T2 SI or Global T2 SI ratio ≥ 2.0 † in T2W CMR images	T2-based imaging Regional* high T2 SI or Global T2 SI ratio ≥ 2.0 † in T2W CMR images or Regional or global increase of myocardial T2 relaxation time‡	Myocardial edema
Early gadolinium enhancement SI ratio myocardium/skeletal muscle (EGE ratio) of ≥ 4.0 † in EGE images	T1-based imaging Regional or global increase of native myocardial T1 relaxation time or ECV†† or Areas with high SI in a nonischemic distribution pattern in LGE images	↑ T1 - edema (intra or extra-cellular), hyperemia/capillary leak, necrosis, fibrosis EGE - hyperemia, capillary leak LGE - necrosis, fibrosis, (extracellular acute edema) ↑ ECV - edema (extracellular), hyperemia/capillary leak, necrosis, fibrosis
Late gadolinium enhancement Areas with high SI in a nonischemic distribution pattern in LGE images		
Supportive criteria		
Pericardial effusion in cine CMR images	Pericardial effusion in cine CMR images or High signal intensity of the pericardium in LGE images, T1-mapping or T2-mapping or T1 mapping or T2 mapping	Pericardial inflammation
Systolic LV wall motion abnormality in cine CMR images	Systolic LV wall motion abnormality in cine CMR images	LV dysfunction
<p>**"Regional" refers to an area of at least 10 contiguous pixels. †Published or local normal values, LV coverage and proper analysis tools must be acknowledged. ‡T1 mapping is highly sensitive to detecting both acute and chronic forms of increased free water content within the myocardium, and thus, the Consensus Group recommends treating it as an alternative criterion to EGE. If paired with LGE to diagnose myocarditis, the areas of T1 abnormality should be beyond that detected by LGE imaging.</p> <p>† = increased; ECV = extracellular volume; other abbreviations as in Tables 1 and 2.</p>		

of heterogeneity). Despite these limitations in performing summary statistics on currently available data, it appears clear that novel mapping techniques offer at least a theoretical advantage over the original Lake Louise Criteria.

The following proposed update of the Lake Louise Criteria represents a “2 out of 2” approach, with one positive T2-based criterion and one T1-based criterion to increase the specificity of detecting acute myocardial inflammation. The combination of T2 mapping and LGE provides very good accuracy, although this is based on only 2 published studies thus far (52,66). A gadolinium-free protocol, combining T2-based CMR with T1 mapping, is highly attractive and may be very useful in cases where the administration of contrast agents is not desirable, although further studies are warranted.

Combining T2 mapping and ECV may theoretically improve diagnostic confidence in cases where global myocardial edema predominates, where LGE is negative, and if the diagnostic quality of T2-weighted imaging is impaired by technical issues; further evidence is needed for this approach.

Although the combination of T1 mapping with LGE achieved a high diagnostic performance in published studies, and some data suggest that the degree of T1

increase differs between hyper edema and diffuse fibrosis, it remains unclear whether native T1 can differentiate acute inflammation from chronic injury or diffuse fibrosis.

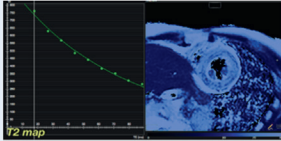
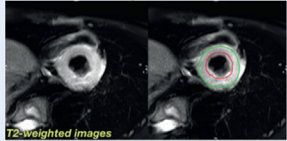
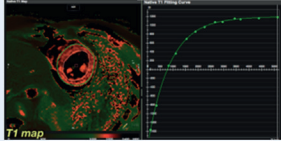
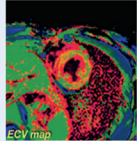
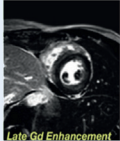
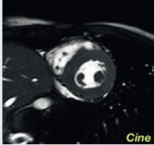
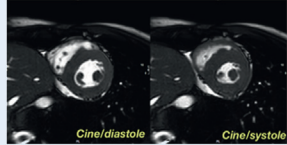
Quantitative mapping is a nascent field, with emerging evidence of its clinical utility, especially in aiding the noninvasive diagnosis of myocarditis. More head-to-head studies comparing mapping with conventional CMR imaging techniques are needed to establish their true diagnostic performance relative to each other in the detection of myocarditis. Longitudinal and multicenter studies to establish the prognostic power of these promising imaging biomarkers and how they may guide treatment, specifically in inflammatory myocardial diseases, would further add to the clinical value of mapping techniques.

UPDATE TO THE LAKE LOUISE CRITERIA

On the basis of established statistical methods (75), the diagnostic accuracy can be significantly improved by combining edema-sensitive CMR (T2-weighted images or T2 mapping) with at least 1 additional T1-based tissue characterization technique (Table 3).

On the basis of currently available clinical evidence, the Consensus Group recommends that, in

CENTRAL ILLUSTRATION Overview of the Updated Lake Louise Criteria

2018 Lake Louise Criteria		CMR Image Examples	
Main Criteria	Myocardial Edema (T2-mapping or T2W images)	Regional or global increase of native T2 	Regional or global increase of T2 signal intensity 
	Non-ischemic Myocardial Injury (Abnormal T1, ECV, or LGE)	Regional or global increase of native T1 	Regional or global increase of ECV  or Regional LGE signal increase 
Supportive Criteria	Pericarditis (Effusion in cine images or abnormal LGE, T2, or T1)	Pericardial effusion 	
	Systolic LV Dysfunction (Regional or global wall motion abnormality)	Regional or global hypokinesia 	

Ferreira, V.M. et al. *J Am Coll Cardiol.* 2018;72(24):3158-76.

ECV = extracellular volume; LGE = late gadolinium enhancement; T2W = T2-weighted.

patients with a significant clinical pre-test probability (12), a CMR scan provides strong evidence for acute myocardial inflammation if at least 1 criterion in each of the following 2 categories is positive (**Central Illustration**): T2-based marker for myocardial edema and T1-based marker for associated myocardial injury.

T2-BASED MARKER FOR MYOCARDIAL EDEMA.

Methods. T2-weighted imaging or T2 mapping.

Rationale. Because edema is an essential component of acute or active inflammation, the presence of a specific marker for edema (either on T2-weighted images or T2 mapping) is considered important. T2, as measured by T2 mapping, is a reliable marker for myocardial edema and is recommended as an alternative to T2-weighted CMR images.

T1-BASED MARKER FOR ASSOCIATED MYOCARDIAL INJURY.

Methods. LGE, T1 mapping, or ECV.

Rationale. LGE detects acute myocyte necrosis, focal fibrosis and scarring, and, to some extent, acute

extracellular edema. Native T1 relaxation time is prolonged by intracellular or extracellular edema, hyperemia and capillary leak, and in areas of myocyte necrosis and fibrosis in myocarditis. ECV may be expanded by extracellular edema, hyperemia or capillary leak, and in areas of necrosis and fibrosis.

While having both a positive T2-based marker and a T1-based marker will increase specificity for diagnosing acute myocardial inflammation, having only one (i.e., T2-based or T1-based) marker may still support a diagnosis of acute myocardial inflammation in an appropriate clinical scenario, albeit with less specificity.

REPORTING OF CMR RESULTS

The evaluation of CMR images for acute inflammation should follow standard recommendations (76) and ensure that artifacts and areas with inadequate image quality are excluded from the analysis. The evaluation should be performed qualitatively (regional

TABLE 4 CMR Image Evaluation and Parameters for Reporting Acute Myocardial Inflammation

Image Evaluation	Parameters for Reporting
Ventricular function	Presence and location of global or regional systolic dysfunction Left ventricular end-diastolic volume (LVEDV) Left ventricular end-systolic volume (LVESV) Ejection fraction (EF) Stroke volume (SV) and stroke volume index (SVI) Cardiac index (CI)
Edema*	Presence, extent, and localization of visually apparent edema T2 SI ratio or native T2
Hyperemia and capillary leakage	Native T1 or ECV
Necrosis and fibrosis	Presence, extent, and localization of visually apparent necrosis or scar on LGE imaging Native T1 or ECV
Pericardium	Presence, extent, and localization of effusion Signal increase in LGE, T2 or T1 mapping Pericardial thickness if >3 mm Hemodynamic relevance if applicable: evidence of constriction

*Native T1 and ECV are also sensitive to, although not specific for, myocardial inflammation and edema, because these parameters also reflect chronic changes, such as focal and diffuse myocardial fibrosis.
Abbreviations as in Tables 2 and 3.

function, regional edema, regional necrosis or scarring, pericardial effusion) and quantitatively (for signal intensity ratios and mapping). For the quantitative assessment, certified post-processing and evaluation software with the capability to accurately quantify signal intensities, areas, volumes and relaxation parameters accurately should be used. The signal intensity in skeletal muscle for the calculation of the T2 signal intensity ratio should be measured in the serratus anterior muscle if accessible (77). The CMR reader should remain mindful of the likely presence or absence of underlying noninflammatory myocardial disease causing diffuse fibrosis or infiltration, which may have a confounding effect when interpreting the significance of T1 prolongation detected by myocardial mapping. Table 4 lists the evaluation and parameters to be reported.

UTILITY OF CMR IN SPECIFIC CLINICAL SCENARIOS

Table 5 provides an overview of CMR features in myocardial inflammation according to disease acuity and etiology.

CLINICAL PRESENTATION SUGGESTING ACUTE ONSET MYOCARDIAL INFLAMMATION. In patients presenting with symptoms indicating acute myocardial injury, it is critically important to rule out acute coronary syndrome. Although CMR is a very useful tool for identifying acute coronary syndrome, any additional diagnostic procedure may delay urgently required revascularization, especially in patients with a significant pre-test likelihood of coronary artery

disease. In patients with low atherosclerotic risk, such as young patients without risk factors, however, acute myocardial inflammation caused by infectious or autoimmune disease is much more likely than an ischemic event, and thus CMR may be considered a first-line diagnostic tool. The protocol should include full coverage of the left ventricle while applying edema-sensitive techniques. This approach is helpful to detect small areas of regional edema.

Although the Lake Louise Criteria are suitable only for patients with suspected active or acute inflammation, CMR has demonstrated its utility in identifying inflammation in various chronic inflammatory conditions, ranging from chronic myocarditis to sarcoidosis to human immunodeficiency virus (HIV) disease. LGE has been commonly used, as has T2-weighted imaging, but parametric mapping is beginning to show its merit, especially for identifying ongoing inflammation in chronic cases.

Clinical scenarios can be classified according to their symptoms:

INFARCT-LIKE ACUTE MYOCARDITIS. Clinically severe myocarditis with ST-segment elevation and increased troponin levels is a presentation found mostly in acute viral myocarditis of younger patients, especially men (78-80). Prognostic data on this pattern are still scarce, yet it may be associated with a worse outcome (79). The CMR findings are typically impressive, with widespread edema and patchy, often inferolateral, necrosis in LGE images (79,80). Therefore, in this setting, the Lake Louise Criteria have very high sensitivity and, given the distinct regional distribution pattern of injury, high specificity. In select institutions, immediate access to CMR may obviate coronary angiography in young patients without atherosclerotic risk factors and a recent history consistent with acute myocarditis.

NEW ONSET HEART FAILURE. Heart failure is caused either by systolic dysfunction or by impaired filling with increased intraventricular pressure. Therefore, more extensive myocardial involvement would be expected. In the absence of symptoms indicating acute inflammation, this scenario typically reflects a previous episode of severe inflammatory injury with subsequent extensive scarring. Acute giant cell myocarditis is known for its often fulminant course with overt, sudden onset heart failure, but any severe inflammation could cause sufficient damage.

ARRHYTHMIA. Myocardial inflammation and scars can lead to various forms of arrhythmia, including atrioventricular block, supraventricular or ventricular premature complexes, and even fatal arrhythmias such as ventricular fibrillation. The diagnostic

TABLE 5 CMR Features in Myocardial Inflammation According to Disease Acuity and Etiology

Presentation	Diseases	Pathology	Typical CMR Findings	Disease-Specific Aspects
Acute (active)	Viral myocarditis Autoimmune Allergic Giant cell myocarditis Other	Edema Hyperemia ± Necrosis	T2 ↑ T1 ↑ LGE (-) or (+)	Intramural or subepicardial distribution; important to differentiate from ischemic injury
Chronic	Viral myocarditis Autoimmune Sarcoidosis Hyperthyroidism Other	± Edema ± Hyperemia ± Necrosis ± Regional fibrosis (scar) ± Diffuse fibrosis	T2 (-) or ↑ T1 (-) or ↑ LGE (-) or (+)	ECV may provide incremental information
Healed	All	± Regional fibrosis (scar) ± Diffuse fibrosis	T2 (-) or ↓ T1 (-) or ↑ LGE (-) or (+)	ECV may provide incremental information

↓ = decreased; ↑ = increased; (+) = present; (-) = absent; other abbreviations as in Tables 2 and 3.

work-up of patients with unexplained arrhythmia therefore should include myocardial tissue characterization. Myocardial scars can often be associated with the electrocardiographic localization of arrhythmic foci.

SPECIFIC ASPECTS RELATED TO CERTAIN CAUSES OF ACUTE MYOCARDIAL INFLAMMATION

Although inflammation per se is nonspecific, its severity, regional distribution, involvement of anatomic structures, and impact on pathophysiology often affect its presentation in CMR images.

VIRAL MYOCARDITIS. Viral infections frequently affect the heart. Although mostly benign, viral myocarditis may be severe and present with acute heart failure or, typically in young men, with “infarct-like” symptoms and findings (ST-segment elevation, positive seromarkers for myocardial necrosis). CMR is the only diagnostic modality that can noninvasively identify myocardial edema, with or without necrosis, and provide a specific marker for acute inflammation, including its severity and localization. CMR thus plays an important role in diagnostic and therapeutic decision making in patients with acute viral myocarditis. CMR, however, cannot differentiate acute viral infection from a secondary immune response. The most frequent pattern includes subepicardial layers of edema and necrosis, with a predominant involvement of the lateral and inferolateral wall of the left ventricle.

CMR has also been proven useful for the identification of chronic viral myocarditis (63), although its utility is less well established than in acute myocarditis. LGE is an important finding and is seen in up to 70% of patients with biopsy-proven chronic inflammation in the setting of heart failure (81). The presence

of pericardial effusion is nonspecific and not particularly helpful in the diagnosis of chronic myocarditis because it was seen in only 28 of 62 such patients (82). In the MyoRacer study, EMB was used as the gold standard for establishing the diagnosis of myocarditis (15). A total of 68 patients with chronic symptoms and a mean ejection fraction of 27% were studied. Of these patients with chronic symptoms, 71% were diagnosed with myocarditis by EMB, with a collagen volume fraction of 14 ± 9%. Of all conventional Lake Louise Criteria and novel mapping techniques, only T2 mapping was found to be sufficiently diagnostic in chronic myocarditis, with an AUC of 0.77, higher than for the Lake Louise Criteria I (0.53) and native T1 (0.53). One study of patients with acute myocarditis and those in clinical convalescence also showed that, although significantly increased T1 values in the acute stage diminish in the convalescent stage, they remain elevated compared with normal (68). Another study of 24 patients with active myocarditis showed that all CMR markers of inflammation showed normalization by 5 weeks after presentation (48).

ACUTE GIANT CELL MYOCARDITIS. The diagnosis of acute giant cell myocarditis is of particular importance because immediate treatment with immunosuppressive agents may improve outcome of this typically fulminant disease (83). The CMR appearance of giant cell myocarditis has not been systematically studied, but reports and personal experience from experts indicate various forms of tissue disease, including the presence of large areas of high signal intensity in various, sometimes atypically sub-endocardial, layers of the myocardium (84-86), similar to severe forms of sarcoidosis (87). The value of CMR, thus, will be the confirmation of widespread yet nonischemic necrosis in acute cases.

EOSINOPHILIC MYOCARDITIS. Eosinophilic myocarditis can be caused by hypersensitivity, allergy, drug sensitivity, neoplasia, drugs, vasculitis, and hematologic disorders (37). Different from the more subepicardial or patchy intramyocardial distribution patterns of viral myocarditis, eosinophilic myocarditis tends to display diffuse subendocardial areas of high signal intensity in LGE images (37).

MYOCARDITIS IN PEDIATRIC POPULATIONS. In children, cardiomyopathy secondary to myocarditis may manifest with fulminant heart failure requiring hemodynamic support (88). In this setting, CMR may provide diagnostic and prognostic value (89). The use of CMR is increasing, with 28% of children hospitalized for myocarditis having a CMR in 2011 (90). As in adults, the presence of LGE correlates with a greater risk of assist device implantation, transplantation, or death (91).

AUTOIMMUNE MYOCARDITIS. Systemic autoimmune diseases and vasculitides are associated with myocardial inflammation. In a study of 39 patients with rheumatoid arthritis and 29 matched controls, focal LGE was noted in 46% of patients, and patients had larger areas of myocardial edema on T2-weighted imaging (10% vs. 0% of left ventricular myocardium in controls), higher native T1, and ECV (92). A similar study in 60 female patients with rheumatoid arthritis showed a prevalence of LGE of 55% as well as higher native T1 (93). In systemic sclerosis, a study of 19 patients showed focal LGE in 10 (53%) as well as higher native T1 and ECV and areas of elevated T2 signal (94). Native T1 and ECV correlated with disease activity and abnormal systolic and diastolic strain. Another study of 40 patients with systemic sclerosis showed a lower incidence of LGE (17.5%), primarily in the basal and midseptum and right ventricular insertion sites (95).

SYSTEMIC LUPUS ERYTHEMATOSUS. In systemic lupus erythematosus (SLE), a study of 20 patients showed that T2 ratio and EGE ratio were increased, which correlated with disease activity (96). LGE was noted in 3 of 8 patients examined. A more recent study noted LGE in 9 of 13 subjects with SLE (97). Another study of 33 patients with SLE demonstrated increased native T1 and ECV compared with controls (98). In addition, diffuse coronary vessel wall contrast enhancement was noted in 89% of 27 patients studied (99). Thus, CMR tissue characterization, including the novel mapping techniques, can detect subclinical myocarditis as part of systemic autoimmune diseases.

PHEOCHROMOCYTOMA AND CATECHOLAMINE-ASSOCIATED MYOCARDITIS. Pheochromocytoma is associated with catecholamine-associated myocardial

inflammation, which is demonstrable using multiparametric CMR, including T1 mapping. A systematic CMR study characterized the cardiac phenotype in 60 patients with pheochromocytoma compared with healthy and hypertensive controls (100). This study showed that subclinical catecholamine myocarditis was frequent in patients with pheochromocytoma, which can lead to focal or diffuse fibrosis, and residual impairment of systolic and diastolic strain parameters even after curative surgical procedures. These effects surpass those of hypertensive heart disease alone, thus supporting a direct role of catecholamine toxicity that may produce subtle but long-lasting myocardial alterations.

Similar pathophysiology exists in stress-induced cardiomyopathy (Takotsubo), that has been found to exhibit the CMR features of myocardial inflammation, albeit typically without significant abnormalities in LGE images (33,101).

CARDIAC SARCOIDOSIS. Several studies have demonstrated the utility of LGE to identify cardiac involvement in sarcoidosis. One study of 81 patients showed an incidence of 26% of LGE, much higher than the 12% of patients identified by the Japanese Ministry of Health criteria (102). In the largest cohort studied to date, 152 patients with extracardiac sarcoidosis underwent CMR, and the incidence of LGE was 19% (103). Similarly, the incidence of focal LGE in another study of 28 patients with systemic sarcoidosis was 21% (104). In this study, however, T2 values were paradoxically lower in these regions of LGE. A small study of 8 patients with sarcoidosis imaged serially showed that, in the 6 of 8 who received adequate immunosuppressive therapy, T2 values declined from 70.0 ± 5.5 ms to 59.2 ± 6.1 ms, changes associated with improvement in clinical markers of disease (105). A more recent systematic study incorporated CMR cine, LGE, and all novel mapping techniques to assess for myocardial involvement in 61 patients with sarcoidosis (106). It was found that native T1 mapping was the best discriminator between patients and healthy controls. This study demonstrated that mapping offers incremental value in detecting subclinical myocardial involvement when LGE and left ventricular systolic function are unrevealing.

HYPERTHYROIDISM. In 50 patients with hyperthyroidism 1 to 3 months after euthyroidism with therapy, CMR findings consistent with myocarditis were noted in 15 (30%) (107). Eight of the 15 patients demonstrated LGE, and, on the whole, they demonstrated elevated T2 and EGE ratios. Myocarditis in this setting was thought to be autoimmune because of

the presence of circulating antimicrobial and antithyroglobulin antibodies.

OTHER CONDITIONS. CMR techniques often demonstrate inflammation in other systemic infectious conditions. In Chagas disease, 1 study of 51 patients showed evidence of LGE in 69% of patients, and the prevalence correlated with clinical severity of disease (108). A more recent study of 54 patients showed that 78% of patients had elevated T2 signal intensity that correlated with the presence of LGE, and 74% had evidence of higher EGE ratio (109). In a study of 28 asymptomatic patients with chronic HIV infection, LGE was seen in 82%, primarily sub-epicardial (110). In addition, native T1, EGE, and T2 ratios were elevated compared with normal subjects. In a study with 103 HIV-treated individuals without known cardiac disease (111), CMR demonstrated higher rates of subclinical myocardial edema, fibrosis, frequent pericardial effusions, and changes in myocardial structure and function.

Peripartum cardiomyopathy may involve myocardial inflammation, but data are still emerging. Recently, checkpoint inhibitor-mediated myocarditis has been identified as a clinical entity that may benefit from including CMR in its diagnostic work-up (7).

SUMMARY AND OUTLOOK

Despite the substantial heterogeneity and high risk of bias (mainly related to design issues) of most published reports to date (3), current evidence supports the use of CMR as a noninvasive means to detect signs of acute myocardial inflammation. In a clinical work-

up of a patient with suspected myocarditis, CMR may provide strong evidence for active myocardial inflammation based on at least one T2-based criterion, with at least one T1-based criterion. While having both a positive T2-based marker and a T1-based marker will increase specificity for diagnosing acute myocardial inflammation, having only one (i.e., T2-based or T1-based) marker may still support a diagnosis of acute myocardial inflammation in an appropriate clinical scenario, albeit with less specificity.

CMR should be used in clinical trials of novel treatment options for diseases with significant myocardial inflammation because this may overcome the limitations of previous trials that were not able to demonstrate a therapeutic benefit.

ACKNOWLEDGMENTS The authors acknowledge the tremendous help of Dr. Stefan Piechnik, Associate Professor of Biomedical Imaging, University of Oxford Centre for Clinical Magnetic Resonance Research, for his extensive review and systematic statistical analysis. The authors also thank Ebe Schaub, MD, University Hospital Heidelberg, for help with preparing the example images for the **Central Illustration**. Special thanks also go to Dr. Iacopo Carbone for his hospitality at the meeting venue in Italy.

ADDRESS FOR CORRESPONDENCE: Dr. Matthias G. Friedrich, Departments of Medicine and Diagnostic Radiology, McGill University Health Centre, 1001 Decarie Boulevard, Montreal, Quebec H4A 3J1, Canada. E-mail: mgwfriedrich@gmail.com. Twitter: [@mgwfriedrich](https://twitter.com/mgwfriedrich), [@cusm_muhc](https://twitter.com/cusm_muhc).

REFERENCES

1. Friedrich MG, Sechtem U, Schulz-Menger J, et al. Cardiovascular magnetic resonance in myocarditis: a JACC White Paper. *J Am Coll Cardiol* 2009;53:1475-87.
2. Lagan J, Schmitt M, Miller CA. Clinical applications of multi-parametric CMR in myocarditis and systemic inflammatory diseases. *Int J Cardiovasc Imaging* 2017;93:1-20.
3. Kotonidis CP, Bazmpani M-A, Haidich A-B, Karvounis C, Antoniadis C, Karamitsos TD. Diagnostic accuracy of cardiovascular magnetic resonance in acute myocarditis: a systematic review and meta-analysis. *J Am Coll Cardiol* 2018;11:1583-90.
4. Laissy J-P, Hyafil F, Feldman LJ, et al. Differentiating acute myocardial infarction from myocarditis: diagnostic value of early- and delayed-perfusion cardiac MR imaging. *Radiology* 2005;237:75-82.
5. Ferreira VM, Piechnik SK, Dall'armellina E, et al. T1 Mapping for the diagnosis of acute myocarditis using CMR: comparison to T2-weighted and late gadolinium enhanced imaging. *J Am Coll Cardiol* 2013;6:1048-58.
6. Kindermann I, Barth C, Mahfoud F, et al. Update on myocarditis. *J Am Coll Cardiol* 2012;59:779-92.
7. Mahmood SS, Fradley MG, Cohen JV, et al. Myocarditis in patients treated with immune checkpoint inhibitors. *J Am Coll Cardiol* 2018;71:1755-64.
8. Fung G, Luo H, Qiu Y, Yang D, McManus B. Myocarditis. *Circ Res* 2016;118:496-514.
9. Heymans S, Eriksson U, Lehtonen J, Cooper LT. The quest for new approaches in myocarditis and inflammatory cardiomyopathy. *J Am Coll Cardiol* 2016;68:2348-64.
10. Maron BJ, Udelson JE, Bonow RO, et al. Eligibility and disqualification recommendations for competitive athletes with cardiovascular abnormalities: Task Force 3: Hypertrophic cardiomyopathy, arrhythmogenic right ventricular cardiomyopathy and other cardiomyopathies, and myocarditis: a scientific statement from the American Heart Association and American College of Cardiology. *J Am Coll Cardiol* 2015;66:2362-71.
11. Cooper LT Jr. Myocarditis. *N Engl J Med* 2009;360:1526-38.
12. Caforio AL, Pankuweit S, Arbustini E, et al. Current state of knowledge on aetiology, diagnosis, management, and therapy of myocarditis: a position statement of the European Society of Cardiology Working Group on Myocardial and Pericardial Diseases. *Eur Heart J* 2013;34:2636-48. 2648a-d.
13. Bozkurt B, Colvin M, Cook J, et al. Current diagnostic and treatment strategies for specific dilated cardiomyopathies: a scientific statement from the American Heart Association. *Circulation* 2016;134:e579-646.
14. Ponikowski P, Voors AA, Anker SD, et al. 2016 ESC guidelines for the diagnosis and treatment of acute and chronic heart failure: the Task Force for the Diagnosis and Treatment of Acute and Chronic Heart Failure of the European Society of Cardiology (ESC) developed with the special contribution

- of the Heart Failure Association (HFA) of the ESC. *Eur Heart J* 2016;37:2129-200.
15. Lurz P, Luecke C, Eitel I, et al. Comprehensive cardiac magnetic resonance imaging in patients with suspected myocarditis. *J Am Coll Cardiol* 2016;67:1800-11.
 16. Schumm J, Greulich S, Wagner A, et al. Cardiovascular magnetic resonance risk stratification in patients with clinically suspected myocarditis. *J Cardiovasc Magn Reson* 2014;16:1-12.
 17. Vermes E, Childs H, Faris P, Friedrich MG. Predictive value of CMR criteria for LV functional improvement in patients with acute myocarditis. *Eur Heart J Cardiovasc Imaging* 2014;15:1140-4.
 18. Boehmer JP, Starling RC, Cooper LT, et al. Left ventricular assist device support and myocardial recovery in recent onset cardiomyopathy. *J Card Fail* 2012;18:755-61.
 19. Jeserich M, Brunner E, Kandolf R, et al. Diagnosis of viral myocarditis by cardiac magnetic resonance and viral genome detection in peripheral blood. *Int J Cardiovasc Imaging* 2013;29:121-9.
 20. Lurz P, Eitel I, Adam J, et al. Diagnostic performance of CMR imaging compared with EMB in patients with suspected myocarditis. *J Am Coll Cardiol Img* 2012;5:513-24.
 21. Ukena C, Mahfoud F, Kindermann I, Kandolf R, Kindermann M, Böhm M. Prognostic electrocardiographic parameters in patients with suspected myocarditis. *Eur J Heart Fail* 2011;13:398-405.
 22. Ukena C, Kindermann M, Mahfoud F, et al. Diagnostic and prognostic validity of different biomarkers in patients with suspected myocarditis. *Clin Res Cardiol* 2014;103:743-51.
 23. Mahfoud F, Gärtner B, Kindermann M, et al. Virus serology in patients with suspected myocarditis: utility or futility? *Eur Heart J* 2011;32:897-903.
 24. Florian A, Schäufele T, Ludwig A, et al. Diagnostic value of CMR in young patients with clinically suspected acute myocarditis is determined by cardiac enzymes. *Clin Res Cardiol* 2015;104:154-63.
 25. Yilmaz A, Klingel K, Kandolf R, Sechtem U. Imaging in inflammatory heart disease: from the past to current clinical practice. *Hellenic J Cardiol* 2009;50:449-60.
 26. Nensa F, Kloth J, Tezgan E, et al. Feasibility of FDG-PET in myocarditis: comparison to CMR using integrated PET/MRI. *J Nucl Cardiol* 2018;25:785-94.
 27. Yilmaz A, Kindermann I, Kindermann M, et al. Comparative evaluation of left and right ventricular endomyocardial biopsy: differences in complication rate and diagnostic performance. *Circulation* 2010;122:900-9.
 28. Cooper LT, Baughman KL, Feldman AM, et al. The role of endomyocardial biopsy in the management of cardiovascular disease: a scientific statement from the American Heart Association, the American College of Cardiology, and the European Society of Cardiology Endorsed by the Heart Failure Society of America and the Heart Failure Association of the European Society of Cardiology. *Eur Heart J* 2007;28:3076-93.
 29. Ardehali H, Qasim A, Cappola T, et al. Endomyocardial biopsy plays a role in diagnosing patients with unexplained cardiomyopathy. *Am Heart J* 2004;147:919-23.
 30. Kindermann I, Kindermann M, Kandolf R, et al. Predictors of outcome in patients with suspected myocarditis. *Circulation* 2008;118:639-48.
 31. Baccouche H, Mahrholdt H, Meinhardt G, et al. Diagnostic synergy of non-invasive cardiovascular magnetic resonance and invasive endomyocardial biopsy in troponin-positive patients without coronary artery disease. *Eur Heart J* 2009;30:2869-79.
 32. Fernández-Jiménez R, Sánchez-González J, Aguero J, et al. Fast T2 gradient-spin-echo (T2-GraSE) mapping for myocardial edema quantification: first in vivo validation in a porcine model of ischemia/reperfusion. *J Cardiovasc Magn Reson* 2015;17:92.
 33. Ferreira VM, Piechnik SK, Dall'armellina E, et al. Non-contrast T1-mapping detects acute myocardial edema with high diagnostic accuracy: a comparison to T2-weighted cardiovascular magnetic resonance. *J Cardiovasc Magn Reson* 2012;14:42.
 34. Iles LM, Ellims AH, Llewellyn H, et al. Histological validation of cardiac magnetic resonance analysis of regional and diffuse interstitial myocardial fibrosis. *Eur Heart J Cardiovasc Imaging* 2015;16:14-22.
 35. Verbrugge FH, Bertrand PB, Willems E, et al. Global myocardial oedema in advanced decompensated heart failure. *Eur Heart J Cardiovasc Imaging* 2017;18:787-94.
 36. Zarka S, Bouleti C, Arangalage D, et al. Usefulness of subepicardial hyperemia on contrast-enhanced first-pass magnetic resonance perfusion imaging for diagnosis of acute myocarditis. *Am J Cardiol* 2016;118:440-5.
 37. Kuchynka P, Palecek T, Masek M, et al. Current diagnostic and therapeutic aspects of eosinophilic myocarditis. *Biomed Res Int* 2016;2016:2829583-6.
 38. Bogaert J, Francone M. Cardiovascular magnetic resonance in pericardial diseases. *J Cardiovasc Magn Reson* 2009;11:14.
 39. Thavendiranathan P, Walls M, Giri S, et al. Improved detection of myocardial involvement in acute inflammatory cardiomyopathies using T2 mapping. *Circ Cardiovasc Imaging* 2012;5:102-10.
 40. Radunski UK, Lund GK, Stehning C, et al. CMR in patients with severe myocarditis: diagnostic value of quantitative tissue markers including extracellular volume imaging. *J Am Coll Cardiol Img* 2014;7:667-75.
 41. Kellman P, Wilson JR, Xue H, Ugander M, Arai AE. Extracellular volume fraction mapping in the myocardium, part 1: evaluation of an automated method. *J Cardiovasc Magn Reson* 2012;14:1-1.
 42. Ferreira VM, Piechnik SK, Dall'armellina E, et al. Native T1-mapping detects the location, extent and patterns of acute myocarditis without the need for gadolinium contrast agents. *J Cardiovasc Magn Reson* 2014;16:36.
 43. Baeßler B, Schaarschmidt F, Stehning C, Schnackenburg B, Maintz D, Bunck AC. A systematic evaluation of three different cardiac T2-mapping sequences at 1.5 and 3T in healthy volunteers. *Eur J Radiol* 2015;84:2161-70.
 44. Moon JC, Messroghli DR, Kellman P, et al. Myocardial T1 mapping and extracellular volume quantification: a Society for Cardiovascular Magnetic Resonance (SCMR) and CMR Working Group of the European Society of Cardiology consensus statement. *J Cardiovasc Magn Reson* 2013;15:92.
 45. Aletras AH, Kellman P, Derbyshire JA, Arai AE. ACUT2E TSE-SSFP: A hybrid method for T2-weighted imaging of edema in the heart. *Magn Reson Med* 2008;59:229-35.
 46. van Heeswijk RB, Feliciano H, Bongard C, et al. Free-breathing 3 T magnetic resonance T2-mapping of the heart. *J Am Coll Cardiol Img* 2012;5:1231-9.
 47. Messroghli DR, Moon JC, Ferreira VM, et al. Clinical recommendations for cardiovascular magnetic resonance mapping of T1, T2, T2* and extracellular volume: a consensus statement by the Society for Cardiovascular Magnetic Resonance (SCMR) endorsed by the European Association for Cardiovascular Imaging (EACVI). *J Cardiovasc Magn Reson* 2017;19:75.
 48. Luetkens JA, Homsí R, Dabir D, et al. Comprehensive cardiac magnetic resonance for short-term follow-up in acute myocarditis. *J Am Heart Assoc* 2016;5:e003603.
 49. Robson MD, Piechnik SK, Tunnicliffe EM, Neubauer S. T1 measurements in the human myocardium: the effects of magnetization transfer on the SASHA and MOLLÍ sequences. *Magn Reson Med* 2013;70:664-70.
 50. Simonetti OP, Finn JP, White RD, Laub G, Henry DA. "Black blood" T2-weighted inversion-recovery MR imaging of the heart. *Radiology* 1996;199:49-57.
 51. O h-Ici D, Ridgway JP, Kuehne T, et al. Cardiovascular magnetic resonance of myocardial edema using a short inversion time inversion recovery (STIR) black-blood technique: diagnostic accuracy of visual and semi-quantitative assessment. *J Cardiovasc Magn Reson* 2012;14:22.
 52. Knobelsdorff-Brenkenhoff von F, Schüler J, Doganguzel S, et al. Detection and monitoring of acute myocarditis applying quantitative cardiovascular magnetic resonance. *Circ Cardiovasc Imaging* 2017;10:e005242.
 53. Kumar A, Beohar N, Arumana JM, et al. CMR imaging of edema in myocardial infarction using cine balanced steady-state free precession. *J Am Coll Cardiol Img* 2011;4:1265-73.
 54. De Lazzari M, Zorzi A, Baritussio A, et al. Relationship between T-wave inversion and transmural myocardial edema as evidenced by cardiac magnetic resonance in patients with clinically suspected acute myocarditis: clinical and prognostic implications. *J Electrocardiol* 2016;49:587-95.
 55. Nordlund D, Klug G, Heiberg E, et al. Multi-vendor, multicentre comparison of contrast-enhanced SSFP and T2-STIR CMR for determining

myocardium at risk in ST-elevation myocardial infarction. *Eur Heart J Cardiovasc Imaging* 2016; 17:744-53.

56. Kellman P, Aletas AH, Mancini C, McVeigh ER, Arai AE. T2-prepared SSFP improves diagnostic confidence in edema imaging in acute myocardial infarction compared to turbo spin echo. *Magn Reson Med* 2007;57:891-7.

57. Laissy J-P, Messin B, Varenne O, et al. MRI of acute myocarditis: a comprehensive approach based on various imaging sequences. *Chest* 2002; 122:1638-48.

58. Chu GCW, Flewitt JA, Mikami Y, Vermes E, Friedrich MG. Assessment of acute myocarditis by cardiovascular MR: diagnostic performance of shortened protocols. *Int J Cardiovasc Imaging* 2013;29:1077-83.

59. Ammirati E, Moroni F, Sormani P, et al. Quantitative changes in late gadolinium enhancement at cardiac magnetic resonance in the early phase of acute myocarditis. *Int J Cardiol* 2017;231:216-21.

60. Schwab J, Rogg HJ, Pauschinger M, et al. Functional and morphological parameters with tissue characterization of cardiovascular magnetic imaging in clinically verified "infarct-like myocarditis." *Rofo* 2016;188:365-73.

61. Verhaert D, Thavendiranathan P, Giri S, et al. Direct T2 quantification of myocardial edema in acute ischemic injury. *J Am Coll Cardiol Img* 2011; 4:269-78.

62. Spiekler M, Haberkorn S, Gastl M, et al. Abnormal T2 mapping cardiovascular magnetic resonance correlates with adverse clinical outcome in patients with suspected acute myocarditis. *J Cardiovasc Magn Reson* 2017;19:38.

63. Gutberlet M, Spors B, Thoma T, et al. Suspected chronic myocarditis at cardiac MR: diagnostic accuracy and association with immunohistologically detected inflammation and viral persistence. *Radiology* 2008;246:401-9.

64. Francone M, Chimenti C, Galea N, et al. CMR sensitivity varies with clinical presentation and extent of cell necrosis in biopsy-proven acute myocarditis. *J Am Coll Cardiol Img* 2014;7:254-63.

65. Bohnen S, Radunski UK, Lund GK, et al. T1 mapping cardiovascular magnetic resonance imaging to detect myocarditis-impact of slice orientation on the diagnostic performance. *Eur J Radiol* 2017;86:6-12.

66. Luetkens JA, Homsí R, Sprinkart AM, et al. Incremental value of quantitative CMR including parametric mapping for the diagnosis of acute myocarditis. *Eur Heart J Cardiovasc Imaging* 2016; 17:154-61.

67. Luetkens JA, Doerner J, Thomas DK, et al. Acute myocarditis: multiparametric cardiac MR imaging. *Radiology* 2014;273:383-92.

68. Hinojar R, Foote L, Arroyo Ucar E, et al. Native T1 in discrimination of acute and convalescent stages in patients with clinical diagnosis of myocarditis: a proposed diagnostic algorithm using CMR. *J Am Coll Cardiol Img* 2015;8:37-46.

69. Kali A, Choi E-Y, Sharif B, et al. Native T1 mapping by 3-T CMR imaging for characterization of chronic myocardial infarctions. *J Am Coll Cardiol Img* 2015;8:1019-30.

70. Liu D, Borlotti A, Viliani D, Jerosch-Herold M, Alkhalil M. CMR native T1 mapping allows differentiation of reversible versus irreversible myocardial damage in ST-segment-elevation myocardial infarction: An OxAMI Study (Oxford Acute Myocardial Infarction). *Circ Cardiovasc Imaging* 2017;10:e005986.

71. Nadjiri J, Nieberler H, Hendrich E, et al. Performance of native and contrast-enhanced T1 mapping to detect myocardial damage in patients with suspected myocarditis: a head-to-head comparison of different cardiovascular magnetic resonance techniques. *Int J Cardiovasc Imaging* 2016:1-9.

72. Radunski UK, Lund GK, Säring D, et al. T1 and T2 mapping cardiovascular magnetic resonance imaging techniques reveal unapparent myocardial injury in patients with myocarditis. *Clin Res Cardiol* 2017;106:10-7.

73. Bandos AI, Guo B, Gur D. Estimating the area under ROC curve when the fitted binormal curves demonstrate improper shape. *Acad Radiol* 2017; 24:209-19.

74. Marzban C. The ROC curve and the area under it as performance measures. *Weather and Forecasting* 2004;19:1106-14.

75. Weinstein S, Obuchowski NA, Lieber ML. Clinical evaluation of diagnostic tests. *AJR Am J Roentgenol* 2005;184:14-9.

76. Schulz-Menger J, Bluemke DA, Bremerich J, et al. Standardized image interpretation and post processing in cardiovascular magnetic resonance: Society for Cardiovascular Magnetic Resonance (SCMR) Board of Trustees Task Force on Standardized Post Processing. *J Cardiovasc Magn Reson* 2013;15:35.

77. Carbone I, Childs H, Aljazeera A, Merchant N, Friedrich MG. Importance of reference muscle selection in quantitative signal intensity analysis of T2-weighted images of myocardial edema using a T2 ratio method. *Biomed Res Int* 2015;2015:1-10.

78. Cocker MS, Abdel-Aty H, Strohm O, Friedrich MG. Age and gender effects on the extent of myocardial involvement in acute myocarditis: a cardiovascular magnetic resonance study. *Heart* 2009;95:1925-30.

79. Chopra H, Arangalage D, Bouleti C, et al. Prognostic value of the infarct- and non-infarct like patterns and cardiovascular magnetic resonance parameters on long-term outcome of patients after acute myocarditis. *Int J Cardiol* 2016;212:63-9.

80. Faletti R, Gatti M, Baralis I, et al. Clinical and magnetic resonance evolution of "infarct-like" myocarditis. *Radiol Med* 2017;122:273-9.

81. De Cobelli F, Pieroni M, Esposito A, et al. Delayed gadolinium-enhanced cardiac magnetic resonance in patients with chronic myocarditis presenting with heart failure or recurrent arrhythmias. *J Am Coll Cardiol* 2006;47:1649-54.

82. Lurz P, Eitel I, Klieme B, et al. The potential additional diagnostic value of assessing for pericardial effusion on cardiac magnetic resonance imaging in patients with suspected myocarditis. *Eur Heart J Cardiovasc Imaging* 2014;15:643-50.

83. Cooper LT, Elamm C. Giant cell myocarditis. Diagnosis and treatment. *Herz* 2012;37:632-6.

84. Shonk JR, Vogel-Claussen J, Halushka MK, Lima JAC, Bluemke DA. Giant cell myocarditis depicted by cardiac magnetic resonance imaging. *Journal of computer assisted tomography* 2005; 29:742-4.

85. Azarine A, Guillemain R, Bruneval P. Different focal delayed gadolinium-enhancement patterns using cardiac magnetic resonance in a case of diffuse giant cell myocarditis. *Eur Heart J* 2009; 30:1485.

86. Sujino Y, Kimura F, Tanno J, et al. Cardiac magnetic resonance imaging in giant cell myocarditis: intriguing associations with clinical and pathological features. *Circulation* 2014;129:e467-9.

87. Bogabathina H, Olson P, Rathi VK, Biederman RWW. Cardiac sarcoidosis or giant cell myocarditis? On treatment improvement of fulminant myocarditis as demonstrated by cardiovascular magnetic resonance imaging. *Case Rep Cardiol* 2012;2012:647041.

88. Ghelani SJ, Spaeder MC, Pastor W, Spurney CF, Klugman D. Demographics, trends, and outcomes in pediatric acute myocarditis in the United States, 2006 to 2011. *Circ Cardiovasc Qual Outcomes* 2012;5:622-7.

89. Banka P, Robinson JD, Uppu SC, et al. Cardiovascular magnetic resonance techniques and findings in children with myocarditis: a multicenter retrospective study. *J Cardiovasc Magn Reson* 2015;17:96.

90. Canter CE, Simpson KE. Diagnosis and treatment of myocarditis in children in the current era. *Circulation* 2014;129:115-28.

91. Sachdeva S, Song X, Dham N, Heath DM, DeBiasi RL. Analysis of clinical parameters and cardiac magnetic resonance imaging as predictors of outcome in pediatric myocarditis. *Am J Cardiol* 2015;115:499-504.

92. Ntusi NAB, Piechnik SK, Francis JM, et al. Diffuse myocardial fibrosis and inflammation in rheumatoid arthritis: insights from CMR T1 mapping. *J Am Coll Cardiol Img* 2015;8:526-36.

93. Holmström M, Koivuniemi R, Korpi K, et al. Cardiac magnetic resonance imaging reveals frequent myocardial involvement and dysfunction in active rheumatoid arthritis. *Clin Exp Rheumatol* 2016;34:416-23.

94. Ntusi NAB, Piechnik SK, Francis JM, et al. Subclinical myocardial inflammation and diffuse fibrosis are common in systemic sclerosis—a clinical study using myocardial T1-mapping and extracellular volume quantification. *J Cardiovasc Magn Reson* 2014;16:21.

95. Sano M, Satoh H, Suwa K, et al. Characteristics and clinical relevance of late gadolinium enhancement in cardiac magnetic resonance in patients with systemic sclerosis. *Heart Vessels* 2015;30:779-88.

96. Abdel-Aty H, Siegle N, Natusch A, et al. Myocardial tissue characterization in systemic lupus erythematosus: value of a comprehensive cardiovascular magnetic resonance approach. *Lupus* 2008;17:561-7.

97. Thomas G, Cohen Aubart F, Chiche L, et al. Lupus myocarditis: initial presentation and

longterm outcomes in a multicentric series of 29 patients. *J Rheumatol* 2017;44:24-32.

98. Puntmann VO, Puntmann VO, D'Cruz D, et al. Native myocardial T1 mapping by cardiovascular magnetic resonance imaging in subclinical cardiomyopathy in patients with systemic lupus erythematosus. *Circ Cardiovasc Imaging* 2013;6:295-301.

99. Varma N, Hinojar R, D'Cruz D, et al. Coronary vessel wall contrast enhancement imaging as a potential direct marker of coronary involvement: integration of findings from CAD and SLE patients. *J Am Coll Cardiol Img* 2014;7:762-70.

100. Ferreira VM, Marcelino M, Piechnik SK, et al. Pheochromocytoma is characterized by catecholamine-mediated myocarditis, focal and diffuse myocardial fibrosis, and myocardial dysfunction. *J Am Coll Cardiol* 2016;67:2364-74.

101. Eitel I, Knobelsdorff-Brenkenhoff von F, Bernhardt P, et al. Clinical characteristics and cardiovascular magnetic resonance findings in stress (takotsubo) cardiomyopathy. *JAMA* 2011;306:277-86.

102. Patel MR, Cawley PJ, Heitner JF, et al. Detection of myocardial damage in patients with sarcoidosis. *Circulation* 2009;120:1969-77.

103. Patel AR, Klein MR, Chandra S, et al. Myocardial damage in patients with sarcoidosis and preserved left ventricular systolic function: an observational study. *Eur J Heart Fail* 2011;13:1231-7.

104. Yang Y, Safka K, Graham JJ, et al. Correlation of late gadolinium enhancement MRI and quantitative T2 measurement in cardiac

sarcoidosis. *J Magn Reson Imaging* 2014;39:609-16.

105. Crouser ED, Ruden E, Julian MW, Raman SV. Resolution of abnormal cardiac MRI T2 signal following immune suppression for cardiac sarcoidosis. *J Investig Med* 2016;64:1148-50.

106. Greulich S, Deluigi CC, Gloekler S, et al. CMR imaging predicts death and other adverse events in suspected cardiac sarcoidosis. *J Am Coll Cardiol Img* 2013;6:501-11.

107. Mavrogeni S, Markussis V, Bratis K, et al. Hyperthyroidism induced autoimmune myocarditis. Evaluation by cardiovascular magnetic resonance and endomyocardial biopsy. *Int J Cardiol* 2012;158:166-8.

108. Rochitte CE, Oliveira PF, Andrade JM, et al. Myocardial delayed enhancement by magnetic resonance imaging in patients with Chagas' disease: a marker of disease severity. *J Am Coll Cardiol* 2005;46:1553-8.

109. Torreão JA, Ianni BM, Mady C, et al. Myocardial tissue characterization in Chagas' heart disease by cardiovascular magnetic resonance. *J Cardiovasc Magn Reson* 2015;17:97.

110. Luetkens JA, Doerner J, Schwarze-Zander C, et al. Cardiac magnetic resonance reveals signs of subclinical myocardial inflammation in asymptomatic HIV-infected patients. *Circ Cardiovasc Imaging* 2016;9:e004091.

111. Ntusi N, O'Dwyer E, Dorrell L, et al. HIV-1-related cardiovascular disease is associated with

chronic inflammation, frequent pericardial effusions, and probable myocardial edema. *Circ Cardiovasc Imaging* 2016;9:e004430.

112. Abdel-Aty H, Boyé P, Zagrosek A, et al. Diagnostic performance of cardiovascular magnetic resonance in patients with suspected acute myocarditis: comparison of different approaches. *J Am Coll Cardiol* 2005;45:1815-22.

113. Knobelsdorff von F, Prothmann M, Dieringer MA, et al. Differentiation of acute and chronic myocardial infarction using T2-weighted imaging, late enhancement and T1 and T2 mapping - a pilot study at 3T. *J Cardiovasc Magn Reson* 2014;16:P222.

KEY WORDS cardiovascular magnetic resonance, myocardial inflammation, myocarditis

APPENDIX For a supplemental cardiac magnetic resonance protocol, a supplemental statistical methods section, and supplemental tables, figures, and references, please see the online version of this paper.



Go to <http://www.acc.org/jacc-journals-cme> to take the CME/MOC/ECME quiz for this article.