

Thyroid Ultrasound: State of the Art

Part 1 – Thyroid Ultrasound reporting and Diffuse Thyroid Diseases

Manjiri Dighe¹, Richard Barr², Jörg Bojunga³, Vito Cantisani⁴, Maria Cristina Chammas⁵, David Cosgrove⁶, Xin-Wu Cui⁷, Yi Dong⁸, Franziska Fenner⁹, Maija Radzina¹⁰, Sudhir Vinayak¹¹, Jun-Mei Xu¹², Christoph F Dietrich^{13,14}

¹Department of Radiology, University of Washington, Seattle, USA, ²Department of Radiology, Northeastern Ohio Medical University, Rootstown, Ohio, USA and Southwoods Imaging, Youngstown, Ohio, USA, ³Department of Internal Medicine 1, Endocrinology and Diabetology, Goethe University Hospital, Frankfurt am Main, Germany, ⁴Department of Radiological Sciences, Oncology and Pathology, Policlinico Umberto I, University Sapienza, Rome, Italy, ⁵Ultrasound Division, Department of Radiology, Hospital das Clínicas, School of Medicine, University of São Paulo, São Paulo, Brazil, ⁶Division of Radiology, Imperial and Kings Colleges, London, UK, ⁷Department of Medical Ultrasound, Tongji Hospital, Tongji Medical College, Huazhong University of Science and Technology, Wuhan, China, ⁸Department of Ultrasound, Zhongshan Hospital, Fudan University, Shanghai, China, ⁹Department of Surgery, Caritas-Krankenhaus Bad Mergentheim, Germany, ¹⁰Diagnostic Radiology Institute, Paula Stradins Clinical University Hospital, Riga, Latvia, ¹¹Department of Imaging and Diagnostic Radiology, Aga Khan University Hospital, Nairobi, Kenya, ¹²Department of Medical Ultrasound, Shanghai Tenth People's Hospital, Ultrasound Research and Education Institute, Tongji University School of Medicine, China, ¹³Department of Internal Medicine 2, Caritas Hospital, Bad Mergentheim, Germany, ¹⁴Sino-German Research Center of Ultrasound in Medicine, The First Affiliated Hospital of Zhengzhou University, Zhengzhou, China

Abstract

Accurate differentiation of focal thyroid nodules (FTL) and thyroid abnormalities is pivotal for proper diagnostic and therapeutic work-up. In these two part articles, the role of ultrasound techniques in the characterization of FTL and evaluation of diffuse thyroid diseases is described to expand on the recently published World Federation in Ultrasound and Medicine (WFUMB) thyroid elastography guidelines and review how this guideline fits into a complete thyroid ultrasound exam.

Keywords: thyroid; ultrasonography; elastography; color Doppler; contrast enhanced ultrasound (CEUS); point of care (POC).

Introduction

Ultrasound (US) of the thyroid is well established for a variety of indications and applications. US is the most sensitive imaging test available for the examination of the thyroid gland, to detect and characterize le-

sions, accurately calculate their dimensions, identify the internal structure and vascularization using color Doppler imaging (CDI) and evaluate diffuse changes in the thyroid parenchyma. Thyroid US is able to confirm the presence of a thyroid nodule when the physical examination is equivocal and differentiate between thyroid nodules and cervical masses from other origins [1,2]. In this setting, the accurate differentiation of benign from malignant lesions is critical to ensure that the patient undergoes the appropriate diagnostic and therapeutic decision.

In the present two part papers, the role of ultrasound techniques in the evaluation of diffuse thyroid disease (DTD) (Part 1) and characterization of focal thyroid lesions (FTL) (Part 2) is described to accompany the recently published WFUMB thyroid elastography guide-

Received 09.11.2016 Accepted 20.12.2016

Med Ultrason

2017, Vol. 19, No 1, 79-93

Corresponding author: Prof. Dr. med. Christoph F. Dietrich

Department of Internal Medicine 2,

Caritas Krankenhaus,

Uhlandstr. 7, D-97980 Bad Mergentheim,

Germany

Phone: 49 (0)7931 – 58 – 2201 / 2200

Fax: 49 (0)7931 – 58 – 2290

Email: Christoph.dietrich@ckbm.de

lines and review how the guidelines fit into a complete thyroid ultrasound exam.

Clinical indications according to guidelines

Thyroid ultrasound is recommended in [1,2]:

1. All patients with a palpable thyroid nodule or with multinodular goiter.
2. High-risk patients for thyroid malignancy: history of familial thyroid cancer, multiple endocrine neoplasia (MEN) type II and irradiated neck in childhood.
3. Patients with palpable cervical adenopathy suspicious for malignancy.
4. Follow-up and monitoring thyroid nodules.

Thyroid ultrasound is not recommended in [1,2]:

1. Patients with a normal thyroid on palpation and low risk of thyroid cancer.
2. As a screening test in the general population.

Examination technique

The recommended protocol for thyroid US is as follows [3,4] (Table I):

1. Patient is scanned in supine position with neck extended with a small pillow or rolled towel behind the shoulders.
2. Axial scans of the whole gland at the upper, mid, lower poles and the isthmus, and side-by-side images of each lobe, to compare echogenicity and size of both lobes. Each lobe width and AP diameters are measured.
3. Longitudinal scans through each lobe, on medial, mid and lateral planes. The length of the lobes is measured.
4. Identify focal lesions, measure the main lesions and identify the dominant one (according to size).
5. Evaluation of vascularization using CDI of both lobes and any lesions if detected.
6. Document the presence of enlarged lymph nodes [5,6] or thrombosed jugular vein.

Nodules with any malignant potential (essentially all nodules except pure cysts) should be identified [3,7].

Table I. Standardized structured US reporting criteria for thyroid evaluation.

Thyroid gland	Thyroid nodules
Position	Size / Location
Shape	Margins
Size	Composition (solid, cystic, spongiform, proportion)
Content	Presence and type of calcifications
Echogenicity	Echogenicity iso/hyper/hypo
Vascular pattern	Vascular pattern

The value of thyroid ultrasound examination

The value of thyroid ultrasound examination is as follows:

1. To detect FTL;
2. To differentiate between benign and malignant FTL;
3. To evaluate cervical lymphadenopathy;
4. To guide interventions, e.g., biopsy and percutaneous treatment;
5. To assess change in size of thyroid nodules with follow up US.

In all patients with palpable thyroid nodules, US should be performed to accomplish the following [3]:

1. Detect US features suggestive of malignant growth and select the lesions to be recommended for fine-needle aspiration (FNA);
2. Look for coincidental thyroid nodules;
3. Help with the diagnosis in difficult cases (as in Hashimoto's thyroiditis);
4. Choose the gauge and length of the biopsy needle;
5. Obtain an objective measure of the baseline volume and characteristics of the lesions that will be assigned to follow-up or medical or minimally invasive therapy – Radiofrequency ablation (RFA), Microwave ablation (MWA), Laser.

Indications for thyroid US, following the American Association of Clinical Endocrinologists (AACE) are as follows [8]:

1. To confirm presence of a thyroid nodule when physical examination is equivocal.
2. To characterize a thyroid nodule(s), i.e. to measure the dimensions accurately and to identify internal structure and vascularization.
3. To differentiate between benign and malignant thyroid masses, based on their sonographic appearance.
4. To differentiate between thyroid nodules and other cervical masses like lymphadenopathy, thyroglossal cyst and cystic hygroma.
5. To evaluate diffuse changes in thyroid parenchyma.
6. To detect post-operative residual or recurrent tumor in thyroid bed or metastases to neck lymph nodes.
7. To screen high-risk patients for thyroid malignancy like patients with history of familial thyroid cancer, MEN type II and irradiated neck in childhood.
8. To guide diagnostic (FNA cytology/biopsy) and therapeutic interventional procedures.

TIRADS (thyroid imaging reporting and data system) – Classification

In the last few years, assessment concepts called as 'grading system' or 'reporting system' have emerged. In

Table II. TIRADS classification [9].

Category	1	2	3	4	5	6
Definition	Normal thyroid gland	Benign	Probably benign	Suspicious for malignancy 4a 4b 4c	Probably malignant	Biopsy proven malignancy
Number of suspicious features				One Two 3-4	All 5	

a way similar to BIRADS (Breast Imaging-Reporting and Data System) these systems were named “Thyroid Imaging Reporting and Data System” or TIRADS. Thyroid nodules were classified into categories related to their US patterns and indications for FNA were based on these categories calculating a qualitative risk [9]. However, these systems are time consuming, somewhat cumbersome and interobserver agreement is reported to be quite low [10]. For this reason subsequent studies tried to simplify the systems.

In 2011, Kwak et al developed a practical TIRADS with which to categorize thyroid nodules and stratify their malignant risk. The following US features showed a significant association with malignancy: solid component, hypoechogenicity, marked hypoechogenicity, microlobulated or irregular margins, microcalcifications, and taller-than-wide shape [11].

When reporting a thyroid ultrasound, some general rules should be fulfilled:

1. Describe sonographic appearance of the thyroid gland and structural, shape and size alterations as shown above.
2. Describe the imaging characteristics of the nodule as shown in table I.
3. Identify the nodule at risk to be malignant by risk stratification based on identification of high risk factors [12].
4. The proposed risk stratification system based on solidity and echogenicity will be useful for risk stratification and management decision of thyroid nodules [13].
5. Additional evaluation of the nodule with elastography can be performed, if available.

Clinical work up

In the clinical work up of thyroid nodules, there are some main questions should be asked:

1. Is the nodule suspicious for malignancy?
2. Is there a history of MEN II, previous neck radiation or thyroid resection?
3. Are cervical lymph nodes involved?
4. Is there a primary focus in the thyroid gland in a patient with cervical adenopathy?
5. Is there a post-operative residual or recurrent tumor in the thyroid bed or metastases to neck lymph nodes?

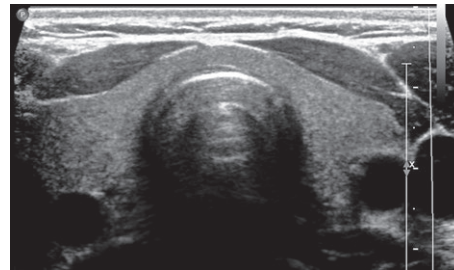


Fig 1. Normal thyroid gland. Transverse ultrasound through the neck shows that the normal thyroid consists of two lobes and a bridging isthmus with a homogenous appearance on ultrasound.

In case of a positive answer to any of the above questions, FNA must be performed. Recommendations for FNA of thyroid nodules based on US features were published by the American Thyroid Association (ATA) in 2015 [2].

The TIRADS classification is shown in Table II [9].

Normal size, shape, echogenicity

The normal thyroid gland consists of two lobes and a bridging isthmus. Thyroid size, shape, and volume vary with age and sex. The normal thyroid gland (fig 1) weighs approximately 30 g but the size and shape vary according to age [14].

When the gland enlarges, it may extend inferiorly into the superior mediastinum and is then described as a retrosternal thyroid. The volume of the thyroid gland is quite important for clinical practice since it identifies the enlargement of the thyroid gland (goiter) and its response to suppressive therapy. For the treatment of Graves’ disease it allows a rigorous calculation of the appropriate radio-iodine dose. Diminution of the thyroid volume (thyroid atrophy) can be detected in some cases, but has less clinical importance. Normal thyroid lobe dimensions are: 18-20 mm longitudinal and 8-9 mm antero-posterior (AP) diameter in newborn; 25 mm longitudinal and 12-15 mm AP diameter at one year age; and 40-60 mm longitudinal and 13-18 mm AP diameter in adult population. Measurement of the thyroid lobe involves three measurements: the width, depth and length, then the volume is calculated by the formula $V = W \times D \times L \times 0.523$ (V-volume, W-width, D-depth, L-length). The total volume

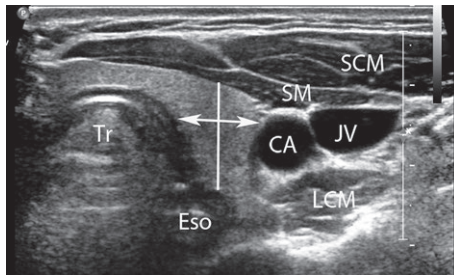


Fig 2. Thyroid lobe, transverse image through the left lobe – note the relationships of the surrounding structures: sternocleidomastoid (SCM) and strap muscles (SM) anteriorly; trachea (Tr)/esophagus (Eso) and longus colli muscles (LCM) posteriorly; and common carotid arteries (CA) and jugular veins (JV) bilaterally.

results from the sum of the two volumes; the isthmus is omitted, unless its thickness is over 3 mm. The limits of normal thyroid volume are 10-15 ml for females and 12-18 ml for males. The width and depth are measured on transverse section of the lobe: the width is the distance between the most lateral point of the lobe and the acoustic shadowing of the trachea and the depth is the maximum antero-posterior distance in the middle third of the lobe (fig 2) [15].

In some cases, on the upper margin of the isthmus there is an accessory lobe (Lalouette pyramid), which must be identified and measured, and the volume must be added to that of the lobes [16].

The structure of the thyroid gland is granulated (ground glass appearance) and the echogenicity is similar to that of the parotid glands, and of increased echogenicity compared to that of the adjacent muscles [15]. The relationships with surrounding structures are: sternocleidomastoid and strap muscles anteriorly; trachea/esophagus and longus colli muscles posteriorly; and common carotid arteries and jugular veins bilaterally (fig 2) [17,18].

Congenital anomalies

Congenital agenesis or hypoplasia of the thyroid gland may include the whole gland or just one of the lobes [19]. Congenital hypothyroidism is a relatively common endocrine disorder [20]. Approximately 80% of congenital hypothyroidism is caused by thyroid dysgenesis due to absence, hypoplasia or ectopia of the gland, which is almost always sporadic in nature [21]. Ectopic thyroid tissue is derived from incomplete migration of thyroid gland and can be found anywhere along the migration course of the thyroid primordium [22] which is between the base of tongue and pretracheal region. The most common presentation is a euthyroid neck mass [23]. Ectopic

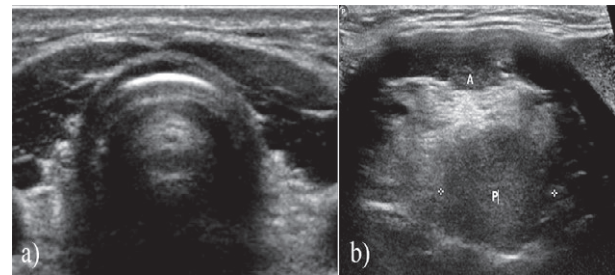


Fig 3. Ectopic thyroid – 24 year old with a known ectopic thyroid with a growing mass at the base of the tongue – note absence of the normal thyroid gland in the neck seen on transverse image through the neck (a) and presence of a hypoechoic rounded mass (P) in the base of the tongue (A). This mass was biopsied and was consistent with a benign adenoma.

thyroid tissue most commonly appears in the midline in the cervical region (90 % of the cases) [24]. Appearance varies on US, but the tissue is generally located close to the hyoid bone (fig 3) [20]. Its prevalence is approximately 1/100,000 – 1/300,000 [25].

Tips and tricks: Scintigraphy is more sensitive than US for detecting an ectopic thyroid. Scintigraphy provides functional information of the thyroid which is not available based on ultrasound examination alone. The thyroid gland appears normal on US in patients with hypoplasia; however, scintigraphy reveals decreased isotope uptake [20].

Diffuse thyroid disease (DTD)

A wide spectrum of DTDs affect the thyroid gland with the most common being autoimmune thyroid disease (AITD). Hashimoto's thyroiditis and Graves' disease are the most common AITDs. US is not generally required for the diagnosis of DTD and diagnosis is based on presenting symptoms, laboratory analysis of thyroid function, immunology, and occasionally radioactive iodine uptake scans [26]. Radioiodine scans are neither needed nor recommended to diagnose Hashimoto or Graves' disease. In some cases, like Hashimoto's thyroiditis, the disease is primarily subclinical and US is helpful in detecting these patients. In addition, US helps exclude focal thyroid disease in these patients and in assessing the size of the thyroid gland.

Ultrasonography findings indicative of DTD are characterized by a diffusely enlarged or normal size thyroid gland or small size in later stages of DTD, decreased or increased diffuse heterogeneous parenchymal echogenicity, a coarse echotexture, and micronodulation [27,28].

In theory, differentiation with ultrasound elastography is feasible because of the different pathologic fea-

tures and stiffness. Yang et al in their study found that the strain ratio (SR) values (calculated by comparing the strain in the thyroid nodule to the sternocleidomastoid muscle in the same image) ranked in ascending order, control group < hyperthyroidism group < Hashimoto's thyroiditis group < subacute thyroiditis group with statistically significant difference ($p < 0.05$) between groups and that it is feasible to assess diffuse thyroid disease with strain ratios obtained with ultrasound elastography [29]. In clinical practice, elastography is usually not used for these indications.

Goiter, *Struma diffusa*

Generalized enlargement of the thyroid is called goiter and can be diffuse or nodular. It may be within a range from simple diffuse nontoxic non-nodular thyroid enlargement to multinodular goiter in a euthyroid patient. The cause of simple goiter is multifactorial and involves complex interactions between environmental (iodine intake), genetic, and endogenous (female gender) factors [30]. Insufficient thyroid hormone input is the most frequent cause worldwide except for the United States; it begins as reaction with follicular epithelium compensatory hypertrophy which generates ordinary, polyclonal follicles alternating with scarring caused by hemorrhagic necrosis over the course of goiter growth in an attempt to maintain a euthyroid state [31,32]. At conventional B-mode US and CDI multinodular goiter frequently appears as thyroid enlargement with focal or diffuse replacement of the thyroid parenchyma by strictly adjacent, sometimes, not distinctive, variable echo structure nodules containing variable amount of cystic degeneration, vascularization and dystrophic calcifications, without or with minimal normal remaining parenchyma (fig 4). In the case of multiple sonographically similar appearing nodules, representative nodules, or nodule clusters when involvement is focal, can be identified for measurement to obtain more reproducible follow-up [33]. The main aim of ultrasound is to iden-

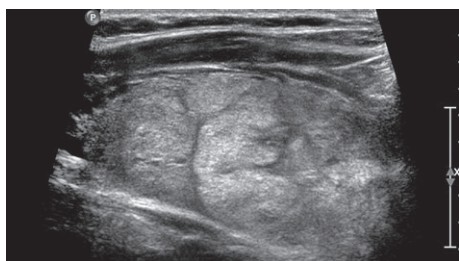

Fig 4. Multinodular goiter. A 43 year old patient with multinodular goiter and hypothyroidism. Sagittal ultrasound the right lobe showed an enlarged thyroid gland with multiple iso- to hyperechoic nodules of variable size, however similar in appearance.

tify nodules that have malignant sonographic features (see TIRADS) to be submitted to ultrasound-guided FNA [34].

Elastography

To date, no specific papers, neither specific recommendation, to the best of our knowledge have been published focusing on diffuse goiter. For the specific features regarding single nodules please see below.

Contrast enhanced ultrasound

To date, no specific papers, to the best of our knowledge have been published focusing on diffuse goiter. For the specific features regarding single nodules please see below.

Tips and tricks

Thyroid scintigraphy is often used in cases where the cause of the hyperthyroidism is unclear and to evaluate for thyroid nodules before treatment [35]. Society of Radiologists in Ultrasound [36] recommend that sonographic features of individual nodules in a multinodular gland should be the primary criteria for suggesting biopsy rather than using nodule size. In their recent guidelines published in 2015 ATA [2] recommends that patients with multiple nodules >1cm should be evaluated in the same fashion as patients with a solitary nodule >1cm with each nodule >1cm carrying an independent risk of malignancy. If multiple nodules >1cm are present, those with a suspicious sonographic pattern should be aspirated preferentially and if none of the nodules have a high or moderately suspicious sonographic pattern, nodules greater than 2 cm should be aspirated and the rest should undergo follow up with serial US examinations [2]. The ATA guidelines use size criteria not since there is an increased risk of cancer in larger nodules but because lesions with different size have different prognosis.

Thyroiditis

Different causes of thyroiditis have been identified including: infection, autoimmune processes, medication, and ionizing radiation. As a result of the inflammatory process, temporary or permanent impairment of thyroid function usually follows. The different forms of thyroiditis may be clearly distinguished on the basis of clinical findings, a few laboratory values, and the ultrasound results [37]. US guided FNA with cytological examination is rarely needed. Scintigraphy of the thyroid is usually of no added diagnostic value. Impairment of thyroid function is divided into hyper- and hypothyroidism [38].

The commonest types of thyroiditis encountered are Hashimoto's thyroiditis and de Quervain's thyroiditis. This section will restrict itself to discussion of these two conditions in addition to a discussion of Graves' disease [39].

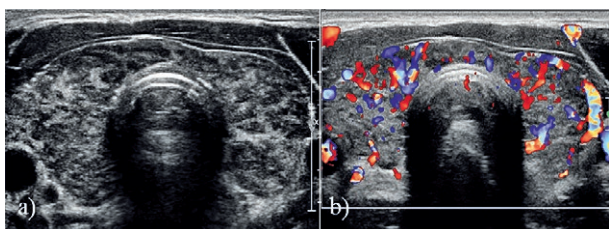


Fig 5. Hashimoto's thyroiditis – transverse scan through the neck shows a heterogeneous thyroid gland with multiple hypoechoic areas in it on the Bode image (a) and increased vascularity on the Color Doppler (b) image.

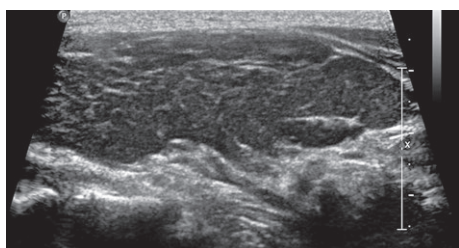


Fig 6. Hashimoto's thyroiditis with fibrosis – Sagittal image through the right lobe shows a hypoechoic thyroid lobe with multiple echogenic linear strands in it which are consistent with fibrosis.

a) Hashimoto's thyroiditis or Chronic Lymphocytic thyroiditis

Hashimoto's thyroiditis or chronic lymphocytic thyroiditis (CLT) is the most common form of organ-specific autoimmune diseases [20]. It is the commonest cause of hypothyroidism in the United States [27]. Its annual incidence is estimated to be between 0.3 and 1.5 cases per 1000 persons, with no significant race-related predominance [27]. Hashimoto's thyroiditis affects 1.3% of children and has a female predominance [40], with a 8 to 9:1 female to male ratio [41]. The disease usually develops in young or middle aged women and leads to progressive thyroid failure [42]. It is characterized by diffuse interstitial lymphocytic infiltration and a variable degree of fibrosis [43]. Diagnosis is made by detecting anti-thyroid antibodies, including anti-thyroid peroxidase and anti-thyroglobulin antibodies [20]. Patients with the acute form present with painless, lobular, diffusely enlarged thyroid gland (classical Hashimoto's) or – much more common – an atrophic thyroid (historically named as Ord's thyroiditis) [27].

Conventional B-mode ultrasound

Hashimoto's thyroiditis is primarily a subclinical disease, and US can detect this subset of patients before they come to clinical attention when typical US findings are present [44].

US is useful for measuring thyroid size and assessing echotexture. Sonographic appearances vary depending on

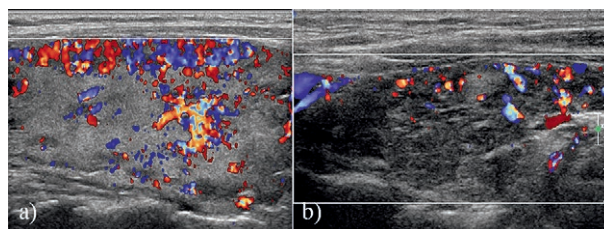


Fig 7. Vascularity in thyroiditis can be variable depending on the stage of the disease. a) Sagittal US image through the right lobe shows a heterogeneous gland with hypervascularity in it on color Doppler which is due to early stage in this patient. b) Different patient with known chronic thyroiditis shows a decreased vascularity likely due to the atrophic stage in this patient.

the degree of gland involvement, which include severity of follicular disruption, lymphocytic infiltration, and chronicity of disease and extent of thyroid involvement. Initially the parenchyma is heterogeneous and coarsened compared with normal thyroid (fig 5). In some patients, innumerable hypoechoic solid micro nodules are seen ranging in size from 1 to 7 mm surrounded by echogenic rim of fibrosis. This appearance is highly specific with a positive predictive value of 95% [28]. As the disease progresses, thyroid parenchyma is progressively destroyed and develops echogenic linear bands of parenchymal fibrosis which can become confluent and thicker (fig 6). There can be asymmetric involvement with preference for the anterior part of the gland. Eventually the gland becomes atrophic with a hypoechoic appearance similar to that of strap muscles.

Color Doppler imaging (CDI)

CDI in Hashimoto's is variable with either normal or increased vascularity seen in the early disease. The increase in vascularity seems to be associated with development of hypothyroidism [45]. Later in the disease course, the gland shows decreased vascularity.

On CDI, the hypertrophic form (Hashimoto's thyroiditis) presents itself with slightly increased vascularity (hyperthyroid phase) in the early stages (fig 7a), whereas the stage of atrophy is characterized by reduced or absent vascularization (fig 7b). During the phase of clinically manifest hypothyroidism, vascularization may increase once more. Peak systolic velocity (PSV) in the afferent arteries is normal in all stages (slightly increased in the case of manifest hypothyroidism), thereby facilitating the differentiation from Graves' disease [38].

Elastography

Sporea et al reported a cut-off value >2.53 m/s using shear wave elastography (SWE) for differentiation between normal thyroid and diffuse thyroid diseases, with a positive predictive value $>90\%$ [46]. They also found a statistically significant difference in velocity values in autoimmune pathology with a value of 2.07 ± 0.44 m/s in

Graves' disease compared with 2.68 ± 0.50 m/s in chronic autoimmune thyroiditis [47].

Kim et al found a cut-off mean value of the EI (elasticity index) using carotid artery as the internal compression source, in cases of diffuse thyroid disease, of 27.6 kPa and a maximum value of 41.3 kPa, with a sensitivity of 40.9% and a specificity of 82.9% [48]. Magri et al studied the EI in patients with chronic autoimmune thyroiditis and found that the elasticity of extra nodular tissue is decreased according to the thyroid antibody titer and the degree of thyroid function damage [49].

Fukuhara et al evaluated the utility of Acoustic Radiation Force Impulse (ARFI) SWE for diagnosing chronic autoimmune thyroiditis (CAT) and to verify the effect of fibrotic thyroid tissue on SWV. The SWV for CAT (2.47 ± 0.57 m/s) was significantly higher than that for controls healthy subjects (1.59 ± 0.41 m/s) ($p < 0.001$). AUROC for CAT was 0.899, and the SWV cut-off value was 1.96 m/s. The sensitivity, specificity, and diagnostic accuracy were 87.4%, 78.7%, and 85.1%, respectively. Levels of anti-thyroperoxidase antibodies and thyroid isthmus thickness were correlated with tissue stiffness in CAT. However, there was no correlation between levels of anti-thyroglobulin antibodies and tissue stiffness. Quantitative SWE is useful for diagnosing CAT, and it is possible that SWE can be used to evaluate the degree of fibrosis in patients with CAT [50].

Magri et al indicated that SWE correctly defines the elasticity of thyroid nodules independently from the co-existence of autoimmune thyroiditis, always being able to differentiate nodular tissue from the surrounding parenchyma. In Hashimoto's thyroiditis the stiffness of extra-nodular tissue increases in relation to both the thyroid antibody titer and the degree of impairment of thyroid function [49]. For a cut-off value of 22.3 kPa, which resulted in the highest sum of sensitivity and specificity, the EI assessed by SWE had a sensitivity of 59.6% and a specificity of 76.9% (AUROC=0.71; $p < 0.001$) for predicting the presence of autoimmune thyroid disease [51].

However, in clinical practice, elastography is usually not needed for these indications.

Contrast enhanced ultrasound

To date, no specific papers, to the best of our knowledge have been published focusing on Hashimoto's thyroiditis. For the specific features regarding single nodules please see below.

Tips and tricks

US guided FNA is an appropriate means of establishing tissue diagnosis and should be used in association with appropriate laboratory studies, FNA, demonstrating diffuse lymphocytic infiltration, as well as high-titer antibodies against thyroid peroxidase (anti-TPO) (sensitivity 70-90%) might be helpful in the diagnostics of chronic

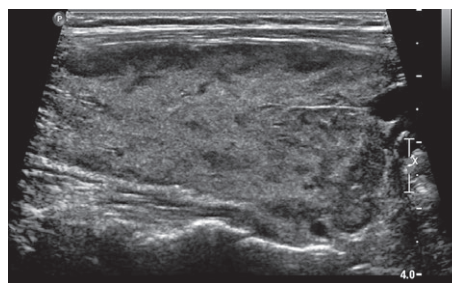


Fig 8. Graves' disease – 30 year old female with known Graves' disease. Sagittal US through the right lobe shows an enlarged gland with a heterogeneous appearance.

Hashimoto's thyroiditis in the early stages. The atrophic form is characterized by an elevated basal TSH level and requires no further laboratory tests or cytological diagnostics. Scintigraphy (mottled accumulation pattern and low nuclide uptake) provides no additional information [38].

b) Graves' disease

Hyperthyroidism is rare in childhood and is most commonly caused by Graves' disease. It affects 0.02 % of children or 1 in 5000 [40]. The peak incidence occurs from 11-15 years of age with a female predominance. A positive family history is common. Graves' disease is an autoimmune disorder that results in hyper-functioning of the thyroid. It is caused by thyroid receptor antibodies binding to the thyrotropin receptor (TSH-receptor). The typical biochemical thyrotoxic profile is matched by a diffuse enlargement of the thyroid gland with rounding of the normal angular outline [52].

Conventional B-mode ultrasound

No specific findings are present, however findings suggestive of the disease include diffuse enlargement, convex bowing of the anterior gland margin and mild textural coarsening (fig 8). The echogenicity is often decreased due to the increased blood flow, increased cellularity and decreased colloid content. Compared to Hashimoto's thyroiditis, the appearance of the thyroid in Graves' disease is less heterogeneous and the contour is lobulated [53]. Features of increased volume, hypervascularity, and heterogeneous reduced echogenicity have been shown in Graves' disease [35].

Color Doppler imaging

Normal thyroid parenchyma shows occasional spots of flow on color Doppler; peak systolic velocities between 15 and 30 cm/s in the inferior thyroid artery and 3 to 5 cm/s in the intrathyroid arteries are considered within the range of normal [54]. Increased vascularity and arteriovenous shunting is called "thyroid inferno" which is suggestive of Graves' disease (fig 9). Studies have shown that

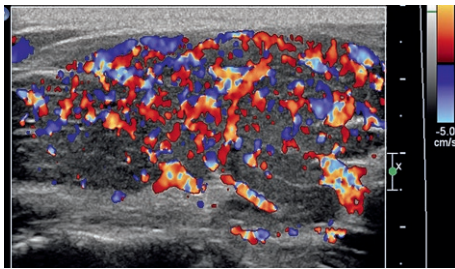


Fig 9. Thyroid inferno. A 44 year old female with known Graves' disease. Sagittal US through the left lobe shows a significantly hypervascular gland with the appearance suggesting an inferno hence called as "thyroid inferno".

color and spectral Doppler interrogation can differentiate Graves' disease from other causes of hyperthyroidism with high specificity [54]. Patients with untreated, active Graves' disease show markedly increased vascularity at color Doppler. Thyroid blood flow (TBF) can present clearer information of minute blood flow than traditional power Doppler mode and is calculated as an advanced dynamic flow/region of interest (ADF/ROI) ratio by special software. ADF is a recently developed high-resolution power Doppler mode used as a quantitative method for calculating TBF. TBF was significantly higher ($p < 0.0001$) in Graves' disease than in painless thyroiditis, subacute thyroiditis, or normal controls. The TBF of patients with Graves' disease was consistently $>4\%$, and all other patients had TBF $<4\%$, indicating that 4% is the cutoff for distinguishing destruction-induced thyrotoxicosis and Graves' disease [55]. Patients with Graves' disease show an approximately 15-fold higher TBF measured in mL/min compared with normal and high peak systolic velocity flow on spectral Doppler in the medium-sized perithyroid and intra-thyroid arteries [56].

English et al described the typical sonographic features of the thyroid gland in patients with Graves' hyperthyroidism after radioiodine therapy (RIT). The sonographic features of the post-RIT gland included a significantly reduced mean total volume of 4.2 mL, hypovascularity, coarse echotexture, and hyperechogenicity [35]. Currently, thyroid imaging does not play a routine role in the post-treatment follow-up of RIT patients, but thyroid ultrasound would be employed if there was a change in the size (enlargement) or nodularity of a treated gland [35].

Elastography

Sporea et al found that thyroid stiffness (TS) assessed by means of ARFI SWE in healthy subjects (2 ± 0.40 m/s) was significantly lower than in Graves' disease (2.67 ± 0.53 m/s) ($p < 0.0001$) and CAT patients (2.43 ± 0.58 m/s) ($p = 0.0002$), but the differences were not significant between Graves' disease and CAT patients ($p = 0.053$).

The optimal cut-off value for the prediction of diffuse thyroid pathology was 2.36 m/s. For this cut-off value, TS had 62.5% sensitivity, 79.5% specificity, 87.6% predictive positive value, 55.5% negative predictive value, and 72.7% accuracy for the presence of diffuse thyroid gland pathology (AUROC=0.804). There were no significant differences between the TS values obtained with linear vs convex probes and when 5 vs 10 measurements were taken in each lobe (median values). ARFI SWE seems to be a useful method for the evaluation of diffuse thyroid gland pathology and is able to predict with sufficient accuracy the presence of diffuse thyroid diseases (AUROC=0.80) [46,47].

Contrast enhanced ultrasound

To date, no specific papers, to the best of our knowledge have been published focusing on Graves' disease.

Tips and tricks

Thyroid scintigraphy is often used in cases where the cause of the hyperthyroidism is unclear and to evaluate thyroid nodules before treatment [35].

c) Subacute granulomatous thyroiditis

(De Quervain or granulomatous thyroiditis)

The clinical scenario differs in that the patient presents with a painful swelling in the lower neck, fever, and sometimes lethargy; typically following a viral illness. Typically no hyperthyroidism is observed. The biochemistry in the acute phase might appear as thyroid toxicity, sometimes followed by a period of hypothyroidism. Typically (after a period of 6 – 18 months from acute onset) the patient recovers and becomes euthyroid. Subacute granulomatous thyroiditis (SGT) is a self-limiting subacute inflammatory disease of the thyroid [57]. It typically occurs in the area of the gland in mid-aged hyperthyroid women complaining of pain, tenderness, fatigue and mild fever [58] and constitutes nearly 3-6% of all thyroid diseases. Generally appears 2 weeks after a viral upper respiratory tract infection and regresses spontaneously within 2-3 months. Although its etiology remains unknown, it is believed have a viral origin, similar to the mumps virus, hepatitis B and C viruses, cytomegalovirus, enterovirus, and type A and B coxsackie viruses. Clinically, patients present with localized anterior neck pain associated with glandular tenderness and diffuse pain in the ears and the jaw, which might be accompanied by fatigue, weight loss, low-grade fever, elevated C-Reactive Protein (CRP), elevated erythrocyte sedimentation rate, suppression in the TSH level and occasionally dysphagia [59].

Conventional B-mode ultrasound

Characteristic US findings include ill-defined, moderately or markedly patchy hypoechoic areas in the thyroid. Hypoechoic areas tend to elongate along the long axis of

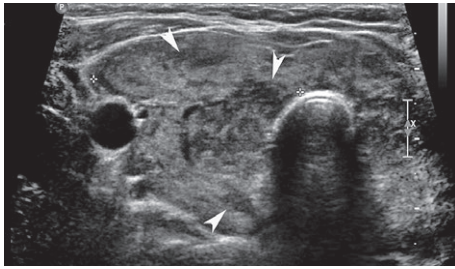


Fig 10. Subacute granulomatous thyroiditis. A 32 year old male with subacute granulomatous thyroiditis. Transverse US image through the right lobe shows patchy hypoechoic areas (arrowheads) in the thyroid gland which did not conform to nodules on the sagittal image.

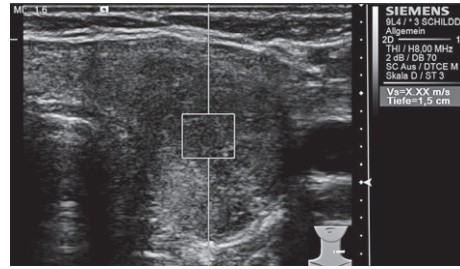


Fig 11. A 38 year old female with cytology proven subacute granulomatous thyroiditis. Elastography with ARFI showed a very hard thyroid gland with stiffness measurement of >8 m/s.

the thyroid. In severe disease, the capsule can be expanded in the affected regions [60]. Generally, an increase in the size of the thyroid and heterogeneous, diffuse, hypoechoic and confluent areas with negative margins, characteristically defined as “lava flow,” are observed on US (fig 10) [59,61,62]. Hypoechoic appearance can also be seen in malignancy, however other features like calcifications and taller than wide shape are absent. Short-term follow up is useful to document regression or resolution. In addition, a prompt clinical response to anti-inflammatory therapy is highly diagnostic.

In the acute phase, US can detect a hypoechoic ill-defined mass, usually tender. The adjacent thyroid tissue is heterogeneous in echotexture. In the subacute phase, the hypoechoic area increases in size to involve the ipsilateral thyroid lobe and sometimes extends to the contralateral lobe. And during recovery phase, thyroid appearances returns to normal or atrophy may develop [62]. Typically, enlarged and activated lymph nodes can be found on US as well.

Color Doppler imaging

No increase in vascularity occurs at CDI. However, these findings are nonspecific because they may also be seen in CLT, multinodular goiter, and Graves’ diseases, and the clinical findings may assist in the differential diagnosis [59,62].

On CDI, the hypoechoic lesions show reduced or absent vascularity, whereas the remaining thyroid displays normal vascularity. Peak systolic velocity of the afferent arteries is typically normal [63].

The sonographic changes described above are no longer demonstrable after complete remission of the disease.

Elastography

Stiff areas are seen in the thyroid gland in SGT and these stiff areas can be stiffer comparing with chronic thyroiditis, resembling malignant nodules on elastogra-

phy (fig 11) [64,65]. Xie et al found that real-time strain US elastography does not provide conclusive information in the diagnosis and differential diagnosis of SGT due to its inability to distinguish between this pathology and thyroid cancer [64].

Yang et al found that the SR (mean±standard deviation) (calculated by using the sternocleidomastoid muscle on the same side of the thyroid as the reference tissue) of patients with hyperthyroidism, Hashimoto’s thyroiditis, and SGT were 2.30±1.08, 7.04±7.74, and 24.09±13.56, respectively. The SR of the control group was 1.76±0.54. SR values ranked in ascending order were control group, hyperthyroidism group, Hashimoto’s thyroiditis group, SGT group. There were statistically significant (p<0.05) differences in thyroid hardness between groups with different diffuse thyroid diseases [29].

Thyroid tissue stiffness was higher in SGT at baseline (214.26±32.5 kPa) in comparison with values recorded at a 4-week follow-up (45.92±17.4 kPa) and at 10 weeks following diagnosis and treatment initiation (21.65±5.3 kPa, p<0.0001). Baseline thyroid stiffness in SGT was higher than in CAT (36.15±18.7 kPa, p<0.0001) and healthy control subjects (16.18±5.4 kPa, p<0.0001). In the remission of SGT, thyroid stiffness was lower than that found in CAT (p=0.006), and higher comparing with healthy control subjects (p=0.0008) [66].

Subacute inflammatory pseudonodules were found to have greater stiffness comparing with nodules found in chronic thyroiditis, and in this condition, elastography could be unable to detect thyroid cancer [66].

Contrast enhanced ultrasound

To date, no specific papers, to the best of our knowledge have been published focusing on subacute granulomatous thyroiditis.

Tips and tricks

SGT may be diagnosed conclusively by B mode ultrasound in 90% of cases if the clinical picture is

typical. Rarely, other thyroid diseases with hypoechoic echo texture must be considered, and CDI contributes with important additional information towards the differential diagnosis. Complementary US guided FNA, demonstrating giant cells and histiocytes, confirms the diagnosis and may be helpful in unclear cases. Scintigraphy, as in other cases of thyroid inflammation, does not contribute any additional information and should not be performed [38].

d) Riedel struma

Riedel's struma (fibrosing thyroiditis) is an extremely rare, local manifestation of a systemic form of fibrosclerosis. Most patients with Riedel's thyroiditis (RT) are between 30 and 50 years old at the time of diagnosis [67]. It is a rare inflammatory disease that results in fibrosis of the thyroid gland and invasion to the surrounding structures of the neck [68]. Although the etiology of RT is unclear, the most probable cause is an autoimmune process [69]. The condition is associated with extensive fibrosis in the gland that spreads to the neighboring tissues and is associated with the presence of inflammatory cell infiltrates. It is characterized by an increasingly massive fibrous alteration of the thyroid and the surrounding tissues, resulting in indolent hard swelling of the neck [70]. RT is more common in females, with an operative incidence of 0.06% reported. The disease is frequently associated with fibrosis of the mediastinum and retroperitoneum, similar to IgG4-mediated disease such as Ormond's disease [71].

Conventional B-mode ultrasound

US shows an enlarged, hypoechoic gland or with a coarsened echotexture with fibrous septations resulting in pseudonodular appearance (fig 12a) [72]. Perithyroid extension is present [73-75].

Color Doppler imaging

Previously published CDI features of RT include a decrease in vascular flow [76], or only slight vascularization of the mass (fig 12 b) [73]. The US vascular en-

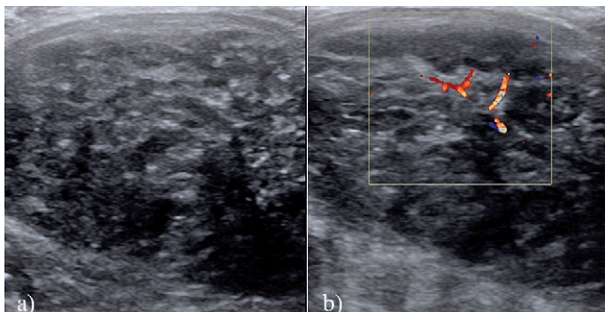


Fig 12. Riedel's Thyroiditis. B mode image showing a heterogeneous thyroid parenchyma with macro calcifications. There is no discrete nodule and the entire gland is involved. The linear echogenic 'streaks' represent fibrotic bands. Vascularity was mainly peripheral, whereas centrally it is reduced

casement and improvement with corticosteroid treatment clearly appear to be specific to RT [75].

Elastography

Elastography showed heterogeneity in the stiffness values of the thyroid parenchyma varying between 21 kPa and 281 kPa. USE revealed heterogeneity in the stiffness values of the thyroid parenchyma. It should be noted that the hypoechoic areas corresponded to the highest stiffness values. These areas could correspond to a high degree of fibrosis. Longer follow-up times are necessary to evaluate the extent to which corticosteroid treatment can alter such stiffness values [75].

Contrast enhanced ultrasound

To date, no specific papers, to the best of our knowledge have been published focusing on RT.

Tips and tricks

Currently, there are no well-established cytomorphic criteria published in the literature in RT [77].

e) Post partum thyroiditis

Post-partum thyroiditis (PPT) is a special form of autoimmune thyroiditis, which occurs in the first year after parturition. PPT is characterized by transient hyperthyroidism followed by transient hypothyroidism during the first six postpartum months. It is seen in 5-9% of women and recurred in 75% of cases in subsequent pregnancies, often being not recognized because the symptoms of hyperthyroidism (1-3 months post partum) and of slight hypothyroidism (4-10 months post partum) are misinterpreted as puerperal depression or as a [78]. The disease is self-limiting, and thyroid function commonly returns to normal after one year; permanent hypothyroidism is rare. Diagnosis is based upon clinical manifestations and thyroid function tests (TSH and free T4). Assessment of anti-TPO antibodies may also help in the diagnosis and thyrotropin receptor antibodies (TRAB) should be negative [79].

Conventional B-mode ultrasound

Typically the gland appears hypoechoic either diffuse or with multifocal areas of low echogenicity scattered throughout both lobes of the thyroid resulting in a heterogeneous appearance [80].

Color Doppler imaging

In comparison to Graves' disease, there is no 'vascular inferno'. In older studies, blood flow is reported to be mostly reduced and increased vascularity is rare. Peak systolic velocity is normal [38]. However, depending on US-devices used, an increased blood flow can be detected very similar to that seen in the acute phase of Hashimoto's disease.

Elastography

To date, no specific papers, to the best of our knowledge have been published focusing on postpartum thyroiditis.

Contrast enhanced ultrasound

To date, no specific papers, to the best of our knowledge have been published focusing on postpartum thyroiditis.

Tips and tricks

Scintigraphy does not have any role in diagnosis or follow up of patients with PPT, especially since the postpartum patients might be breastfeeding her child, which is a contraindication to radioiodine administration. Neither is biopsy recommended in these patients, unless a concomitant focal lesion is seen.

f) Silent thyroiditis

Silent thyroiditis is a rare painless disease. Slight hypothyroidism is clinically apparent, seldom followed by hypothyroidism. Anti-TPO antibodies are often low and only temporarily present. The disease shows spontaneous remission within a few months [81].

Conventional B-mode ultrasound

Sonographic findings equal post-partum thyroiditis [82].

Color Doppler imaging

No specific information has been listed in the literature in regards to CDI in silent thyroiditis. From personal experience it can be reported that an increased blood flow can be detected very similar to that seen in the acute phase of Hashimoto's or postpartum thyroiditis.

Elastography

To date, no specific papers, to the best of our knowledge have been published focusing on silent thyroiditis.

Contrast enhanced ultrasound

To date, no specific papers, to the best of our knowledge have been published focusing on silent thyroiditis.

Tips and tricks

Because silent thyroiditis might show US features very similar to other forms of hyperthyroidism, a radiscan can be helpful in differentiating silent thyroiditis from TRAB negative Graves' disease or a diffuse autonomy. Scintigraphy during the hyperthyroid phase of thyroiditis would show low values for radioiodine uptake, usually less than 1% compared with high values seen in Graves' disease. This can help in differentiating between the two diseases [83].

g) Varia: Amiodaron and interferon induced thyroid disease

Amiodarone is a potent iodine-rich drug; however, side effects on the thyroid and other organs may counterbalance its beneficial effects on the heart. It can cause isolated abnormalities of thyroid function tests and overt thyroid dysfunction, either hypothyroidism (amiodarone-induced hypothyroidism [AIH]) or thyrotoxicosis (amiodarone-induced thyrotoxicosis [AIT] [84]). It may develop early on or after many years of amiodarone treat-

ment, sometimes following drug withdrawal due to prolonged tissue storage of iodinated amiodarone metabolites [85].

AIH occurs more frequently than AIT in iodine-sufficient areas. In contrast to AIT, AIH is more frequent in females with a female to male ratio of 1.5:1 [86]. AIH patients are also older than AIT with circulating thyroid autoantibodies seen in almost 53% of AIH patients with underlying thyroid abnormalities especially Hashimoto's thyroiditis [87].

Males are more frequently affected by AIT (M/F ratio 3:1). Incidence has been reported to range between 1% and 23% [88]. 15-20% of patients on amiodarone treatment develop either AIT or hypothyroidism. Two types of AIT are present; type 1 is a form of iodine-induced hyperthyroidism that develops in abnormal glands (multinodular goiter or latent Graves' disease). The thyrotoxicosis in this type is caused by excessive thyroid hormone synthesis and is treated with anti-thyroid drugs. The more common type 2 AIT occurs in patients without underlying thyroid disease. Thyrotoxicosis in these patients is caused by amiodarone-induced destructive thyroiditis; the disease is treated with steroids [89].

In addition, thyroid disease is a common side effect of interferon-based antiviral therapy for chronic hepatitis C, which may lead to dose reduction or discontinuation of therapy. The two entities observed are destructive forms of thyroiditis as well as INF-induced Graves' disease [90].

Conventional B-mode ultrasound

In patients with AIT type 1, US shows a diffuse or nodular goiter (fig 13), while in patients with AIT type 2, ultrasound shows a normal or small diffuse goiter. US-findings of IFN-induced thyroid disease are similar to the entities observed without IFN.

Color Doppler imaging

CDI has been shown to be a useful tool in differentiating type 1 AIT from type 2. Using a classification that subdivides CDI features into four patterns (0-III), some

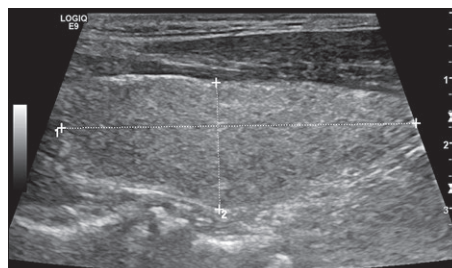


Fig 13. A 69 year old male patient with known cardiac disease being treated with Amiodarone. Patient had initially hyperthyroidism and hence was sent for a thyroid US which showed an echogenic appearing thyroid lobe with no nodules.

authors have reported that CDI showed mild to markedly increased flow in the thyroid in patients with AIT type 1, whereas flow within the thyroid is markedly decreased or absent in patients with AIT type 2 [91-93]. Moreover, the analysis of nodular and extranodular blood flow was useful in the definition of the underlying thyroid diseases in type 1 AIT, being able to differentiate toxic multinodular goiter and toxic adenoma from Graves' disease [91]. This differentiation appeared to be of clinical relevance regarding therapeutic choice and outcome [94,95]. Separate evaluation of parenchymal blood flow from that of nodules may prove beneficial in the diagnosis of underlying thyroid diseases in patients with type 1 AIT [91].

In IFN-induced thyroid disease, a reduction in echogenicity suggestive for a destructive process of the thyroid gland was observed on US even before changes in thyroid function of antibody status could be measured. Risk factors for the development of thyroid dysfunction were age, female gender, pre-treatment thyroid volume, pre-existing thyroglobulin/thyroid peroxidase antibodies and viral load. Power-Doppler ultrasound could reliably differentiate between destructive thyroiditis and Graves' disease [90].

Elastography

To date, no specific papers, to the best of our knowledge have been published focusing on Amiodarone induced thyrotoxicosis

Contrast enhanced ultrasound

To date, no specific papers, to the best of our knowledge have been published focusing on Amiodarone induced thyrotoxicosis

Tips and tricks

Scintigraphy can differentiate between the two forms of AIT with positive scans seen in AIT 1 and negligible uptake seen in AIT II [96].

h) Acute thyroiditis

Acute thyroiditis is a very rare disease, predominantly occurring in immuno-suppressed patients. It may develop locally or hematogenically in septicemia. The classical symptoms of a florid inflammation with fever, sore throat, painful swelling, reddening of the skin and lymph node enlargement can be found [38]. Acute suppurative thyroiditis is uncommon due to the excellent lymphatic drainage, encapsulation, and high iodine content in the gland. It usually affects children and young adults with congenital fourth branchial pouch sinus tracts [27].

Conventional B-mode ultrasound

Conventional US scan depicts ill-defined thyroid borders, the echo texture is inhomogeneous; hypoechoic and anechoic areas represent colligation. In most cases, lymph nodes with inflammatory changes may be demonstrated [38]. US findings are nonspecific and the gland

may appear enlarged and hypoechoic due to inflammation. Focal fluid collection with bright echoes in it from gas can suggest an abscess [48].

Color Doppler imaging

May show normal or increased blood flow.

Elastography

To date, no specific papers, to the best of our knowledge have been published focusing on acute thyroiditis

Contrast enhanced ultrasound

To date, no specific papers, to the best of our knowledge have been published focusing on acute thyroiditis

Tips and tricks

FNA confirms the diagnosis by identifying the causative pathogen. If clinical and sonographic findings are inconclusive, other forms of thyroiditis or malignant tumor might have to be excluded by cytological examination. Acute thyroiditis may usually be cured by antibiotic therapy. In advanced stages with abscess formation, local drainage or even surgery might become necessary [38,97].

Conclusion

A wide spectrum of DTD's affect the thyroid gland and US is not generally required for the diagnosis of DTD. In some cases, like Hashimoto's thyroiditis, US helps exclude focal thyroid disease in these patients and in assessing the size of the thyroid gland. US contrast and elastography is in its infancy and larger studies are needed to evaluate the utility of these new techniques in diffuse thyroid diseases. We also refer to the recently published World Federation in Ultrasound and Medicine (WFUMB) thyroid elastography guidelines [98].

Conflict of interest: none

References

1. Gharib H, Papini E, Paschke R, et al. American Association of Clinical Endocrinologists, Associazione Medici Endocrinologi, and European Thyroid Association Medical Guidelines for Clinical Practice for the Diagnosis and Management of Thyroid Nodules. *Endocr Pract* 2010;16 Suppl 1:1-43.
2. Haugen BR, Alexander EK, Bible KC, et al. 2015 American Thyroid Association Management Guidelines for Adult Patients with Thyroid Nodules and Differentiated Thyroid Cancer: The American Thyroid Association Guidelines Task Force on Thyroid Nodules and Differentiated Thyroid Cancer. *Thyroid* 2016;26:1-133.
3. Thyroid/Parathyroid Ultrasound. American College of Radiology Practice Guideline. In: <http://www.acr.org/Sec->

- ondaryMainMenuCategories/quality_safety/guidelines/us/us_thyroid_parathyroid.aspx; 2007.
4. Jarrell JF, Vilos GA, Allaire C, et al. Consensus guidelines for the management of chronic pelvic pain. *J Obstet Gynaecol Can* 2005;27:869-910.
 5. Cui XW, Jenssen C, Saftoiu A, Ignee A, Dietrich CF. New ultrasound techniques for lymph node evaluation. *World J Gastroenterol* 2013;19:4850-4860.
 6. Cui XW, Hocke M, Jenssen C, et al. Conventional ultrasound for lymph node evaluation, update 2013. *Z Gastroenterol* 2014;52:212-221.
 7. Baskin HJ. Ultrasound of thyroid nodules. In: Baskin HJ, ed. *Thyroid ultrasound and ultrasound-guided FNA biopsy*. Boston: Kluwer Academic Publisher, 2007:71-86.
 8. Gharib H, Papini E, Valcavi R, et al. American Association of Clinical Endocrinologists and Associazione Medici Endocrinologi medical guidelines for clinical practice for the diagnosis and management of thyroid nodules. *Endocr Pract* 2006;12:63-102.
 9. Horvath E, Majlis S, Rossi R, et al. An ultrasonogram reporting system for thyroid nodules stratifying cancer risk for clinical management. *J Clin Endocrinol Metab* 2009;94:1748-1751.
 10. Friedrich-Rust M, Meyer G, Dauth N, et al. Interobserver agreement of Thyroid Imaging Reporting and Data System (TIRADS) and strain elastography for the assessment of thyroid nodules. *PLoS One* 2013;8:e77927.
 11. Kwak JY, Han KH, Yoon JH, et al. Thyroid imaging reporting and data system for US features of nodules: a step in establishing better stratification of cancer risk. *Radiology* 2011;260:892-899.
 12. Grant EG, Tessler FN, Hoang JK, et al. Thyroid Ultrasound Reporting Lexicon: White Paper of the ACR Thyroid Imaging, Reporting and Data System (TIRADS) Committee. *J Am Coll Radiol* 2015;12:1272-1279.
 13. Na DG, Baek JH, Sung JY, et al. Thyroid Imaging Reporting and Data System for Risk Stratification of Thyroid Nodules: Categorization Based on Solidity and Echogenicity. *Thyroid* 2016;26:562-572.
 14. Gray H, Clemente CD. *Anatomy of the Human Body* (American ed 30). Philadelphia, 1985.
 15. Ghervan C. Thyroid and parathyroid ultrasound. *Med Ultrason* 2011;13:80-84.
 16. Hegedus L, Perrild H, Poulsen LR, et al. The determination of thyroid volume by ultrasound and its relationship to body weight, age, and sex in normal subjects. *J Clin Endocrinol Metab* 1983;56:260-263.
 17. Ozgur Z, Celik S, Govsa F, Ozgur T. Anatomical and surgical aspects of the lobes of the thyroid glands. *Eur Arch Otorhinolaryngol* 2011;268:1357-1363.
 18. Aydinler Ö, Karakoç Aydinler E, Akpınar İ, Turan S, Bereket A. Normative Data of Thyroid Volume-Ultrasonographic Evaluation of 422 Subjects Aged 0-55 Years. *J Clin Res Pediatr Endocrinol* 2015;7:98-101.
 19. Supakul N, Delaney LR, Siddiqui AR, Jennings SG, Eugster EA, Karmazyn B. Ultrasound for primary imaging of congenital hypothyroidism. *AJR Am J Roentgenol* 2012;199:W360-W366.
 20. Hong HS, Lee EH, Jeong SH, Park J, Lee HS. Ultrasonography of various thyroid diseases in children and adolescents: a pictorial essay. *Korean J Radiol* 2015;16:419-429.
 21. Hashemipour M, Rostampour N, Nasry P, et al. The role of ultrasonography in primary congenital hypothyroidism. *J Res Med Sci* 2011;16:1122-1128.
 22. Zander DA, Smoker WR. Imaging of ectopic thyroid tissue and thyroglossal duct cysts. *Radiographics* 2014;34:37-50.
 23. Çeliker M, Beyazal Çeliker F, Turan A, Beyazal M, Beyazal Polat H. Submandibular Lateral Ectopic Thyroid Tissue: Ultrasonography, Computed Tomography, and Scintigraphic Findings. *Case Rep Otolaryngol* 2015;2015:769604.
 24. Tewfik TL, Yoskovitch A. Thyroglossal Duct Cysts/Ectopic Thyroid. In: Neck E, ed. *Congenital Malformations*, 2010.
 25. Amoodi HA, Makki F, Taylor M, Trites J, Bullock M, Hart RD. Lateral ectopic thyroid goiter with a normally located thyroid. *Thyroid* 2010;20:217-220.
 26. Slatosky J, Shipton B, Wahba H. Thyroiditis: differential diagnosis and management. *Am Fam Physician* 2000;61:1047-1052.
 27. Pearce EN, Farwell AP, Braverman LE. Thyroiditis. *N Engl J Med* 2003;348:2646-2655.
 28. Yeh HC, Futterweit W, Gilbert P. Micronodulation: ultrasonographic sign of Hashimoto thyroiditis. *J Ultrasound Med* 1996;15:813-819.
 29. Yang Z, Zhang H, Wang K, Cui G, Fu F. Assessment of Diffuse Thyroid Disease by Strain Ratio in Ultrasound Elastography. *Ultrasound Med Biol* 2015;41:2884-2889.
 30. Hegedus L, Bonnema SJ, Bennedbaek FN. Management of simple nodular goiter: current status and future perspectives. *Endocr Rev* 2003;24:102-132.
 31. Ramelli F, Studer H, Bruggisser D. Pathogenesis of thyroid nodules in multinodular goiter. *Am J Pathol* 1982;109:215-223.
 32. Loevner LA, Kaplan SL, Cunnane ME, Moonis G. Cross-sectional imaging of the thyroid gland. *Neuroimaging Clin N Am* 2008;18:445-461.
 33. Sholosh B, Borhani AA. Thyroid ultrasound part 1: technique and diffuse disease. *Radiol Clin North Am* 2011;49:391-416.
 34. Shulkin BL, Shapiro B. The role of imaging tests in the diagnosis of thyroid carcinoma. *Endocrinol Metab Clin North Am* 1990;19:523-543.
 35. English C, Casey R, Bell M, Bergin D, Murphy J. The Sonographic Features of the Thyroid Gland After Treatment with Radioiodine Therapy in Patients with Graves' Disease. *Ultrasound Med Biol* 2016;42:60-67.
 36. Frates MC, Benson CB, Charboneau JW, et al. Management of thyroid nodules detected at US: Society of Radiologists in Ultrasound consensus conference statement. *Radiology* 2005;237:794-800.
 37. Dudea SM, Botar-Jid C. Ultrasound elastography in thyroid disease. *Med Ultrason*. 2015;17:74-96.

38. Blank W, Braun B. Sonography of the Thyroid-Part 2: Thyroid Inflammation, Impairment of Thyroid Function and Interventions. *Ultraschall Med* 2008;29:128-155.
39. Singer PA. Thyroiditis. Acute, subacute, and chronic. *Med Clin North Am* 1991;75:61-77.
40. Babcock DS. Thyroid disease in the pediatric patient: emphasizing imaging with sonography. *Pediatr Radiol* 2006;36:299-308.
41. Farwell AP, Braverman LE. Inflammatory thyroid disorders. *Otolaryngol Clin North Am* 1996;29:541-556.
42. Vanderpump MP, Tunbridge WM. Epidemiology and prevention of clinical and subclinical hypothyroidism. *Thyroid* 2002;12:839-847.
43. Caturegli P, De Remigis A, Rose NR. Hashimoto thyroiditis: clinical and diagnostic criteria. *Autoimmun Rev* 2014;13:391-397.
44. Pedersen OM, Aardal NP, Larssen TB, Varhaug JE, Myking O, Vik-Mo H. The value of ultrasonography in predicting autoimmune thyroid disease. *Thyroid* 2000;10:251-259.
45. Kerr L. High resolution thyroid ultrasound: The value of color doppler. *Ultrasound Q* 1994;12:21-43.
46. Sporea I, Sirlu R, Bota S, Vlad M, Popescu A, Zosin I. ARFI elastography for the evaluation of diffuse thyroid gland pathology: Preliminary results. *World J Radiol* 2012;4:174-178.
47. Sporea I, Vlad M, Bota S, et al. Thyroid stiffness assessment by acoustic radiation force impulse elastography (ARFI). *Ultraschall Med* 2011;32:281-285.
48. Kim I, Kim EK, Yoon JH, et al. Diagnostic role of conventional ultrasonography and shearwave elastography in asymptomatic patients with diffuse thyroid disease: initial experience with 57 patients. *Yonsei Med J* 2014;55:247-253.
49. Magri F, Chytiris S, Capelli V, et al. Shear wave elastography in the diagnosis of thyroid nodules: feasibility in the case of coexistent chronic autoimmune Hashimoto's thyroiditis. *Clin Endocrinol (Oxf)* 2012;76:137-141.
50. Fukuhara T, Matsuda E, Izawa S, Fujiwara K, Kitano H. Utility of Shear Wave Elastography for Diagnosing Chronic Autoimmune Thyroiditis. *J Thyroid Res* 2015;2015:164548.
51. Vlad M, Golu I, Bota S, et al. Real-time shear wave elastography may predict autoimmune thyroid disease. *Wien Klin Wochenschr* 2015;127:330-336.
52. Carlé A, Knudsen N, Pedersen IB, et al. Determinants of serum T4 and T3 at the time of diagnosis in nosological types of thyrotoxicosis: a population-based study. *Eur J Endocrinol* 2013;169:537-545.
53. Rago T, Chiovato L, Grasso L, Pinchera A, Vitti P. Thyroid ultrasonography as a tool for detecting thyroid autoimmune diseases and predicting thyroid dysfunction in apparently healthy subjects. *J Endocrinol Invest* 2001;24:763.
54. Erdoğan MF, Anil C, Cesur M, Başkal N, Erdoğan G. Color flow Doppler sonography for the etiologic diagnosis of hyperthyroidism. *Thyroid* 2007;17:223-228.
55. Ota H, Amino N, Morita S, et al. Quantitative measurement of thyroid blood flow for differentiation of painless thyroiditis from Graves' disease. *Clin Endocrinol (Oxf)* 2007;67:41-45.
56. Bogazzi F. Color flow Doppler sonography of the thyroid. In: Baskin HJ, ed. *Thyroid ultrasound and ultrasound-guided FNA Biopsy*. Boston: Kluwer Academic Publishers, 2000: 215-238.
57. Oláh R, Hajós P, Soós Z, Winkler G. De Quervain thyroiditis. Corner points of the diagnosis. *Orv Hetil* 2014;155:676-680.
58. Alfadda AA, Sallam RM, Elawad GE, Aldhukair H, Alyahya MM. Subacute thyroiditis: clinical presentation and long term outcome. *Int J Endocrinol* 2014;2014:794943.
59. Omori N, Omori K, Takano K. Association of the ultrasonographic findings of subacute thyroiditis with thyroid pain and laboratory findings. *Endocr J* 2008;55:583-588.
60. Nishihara E, Ohye H, Amino N, et al. Clinical characteristics of 852 patients with subacute thyroiditis before treatment. *Intern Med* 2008;47:725-729.
61. Cappelli C, Pirola I, Gandossi E, Formenti AM, Agosti B, Castellano M. Ultrasound findings of subacute thyroiditis: A single institution retrospective review. *Acta Radiol* 2014;55:429-433.
62. Park SY, Kim EK, Kim MJ, et al. Ultrasonographic characteristics of subacute granulomatous thyroiditis. *Korean J Radiol* 2006;7:229-234.
63. Kunz A, Blank W, Braun B. De Quervain's subacute thyroiditis – colour Doppler sonography findings. *Ultraschall Med* 2005;26:102-106.
64. Xie P, Xiao Y, Liu F. Real-time ultrasound elastography in the diagnosis and differential diagnosis of subacute thyroiditis. *J Clin Ultrasound* 2011;39:435-440.
65. Ruchala M, Szczepanek E, Sowinski J. Sonoelastography in de Quervain thyroiditis. *J Clin Endocrinol Metab* 2011;96:289-290.
66. Ruchala M, Szczepanek-Parulska E, Zybek A, et al. The role of sonoelastography in acute, subacute and chronic thyroiditis: a novel application of the method. *Eur J Endocrinol* 2012;166:425-432.
67. Hay ID. Thyroiditis: a clinical update. *Mayo Clin Proc* 1985;60:836-843.
68. Zakeri H, Kashi Z. Variable clinical presentations of Riedel's thyroiditis: report of two cases. *Case Report Med* 2011;2011:709264.
69. Ozgur T, Gokce H, Ustun I, Yaldiz M, Akin MM, Gokce C. A case of asymptomatic Riedel thyroiditis with follicular adenoma in a patient with a multinodular goiter: an unusual association. *Eur Thyroid J* 2012;1:204-207.
70. Junik R, Juraniec O, Pypkowski J, Krymer A, Marszalek A. A difficult diagnosis: a case report of combined Riedel's disease and fibrosing Hashimoto's thyroiditis. *Endokrynol Pol* 2011;62:351-356.
71. LiVolsi V. Werner and Ingbars's the thyroid: A fundamental and clinical text. In: Braverman LE, Untiger RE, eds. *Pathology of Thyroid Diseases*. Philadelphia: Lippincott Williams & Wilkins, 2000:488-511.
72. Malotte MJ, Chonkich GD, Zuppan CW. Riedel's thyroiditis. *Arch Otolaryngol Head Neck Surg* 1991;117:214-217.
73. Ozbayrak M, Kantarci F, Olgun DC, Akman C, Mihmanli I, Kadioglu P. Riedel thyroiditis associated with massive neck fibrosis. *J Ultrasound Med* 2009;28:267-271.

74. Perez Fontan FJ, Cordido Carballido F, Pombo Felipe F, Mosquera Osés J, Villalba Martin C. Riedel thyroiditis: US, CT, and MR evaluation. *J Comput Assist Tomogr* 1993;17:324-325.
75. Slman R, Monpeyssen H, Desarnaud S, et al. Ultrasound, elastography, and fluorodeoxyglucose positron emission tomography/computed tomography imaging in Riedel's thyroiditis: report of two cases. *Thyroid* 2011;21:799-804.
76. Ozgen A, Cila A. Riedel's thyroiditis in multifocal fibrosclerosis: CT and MR imaging findings. *AJNR Am J Neuroradiol* 2000;21:320-321.
77. Harigopal M, Sahoo S, Recant WM, DeMay RM. Fine-needle aspiration of Riedel's disease: report of a case and review of the literature. *Diagn Cytopathol* 2004;30:193-197.
78. Lazarus JH, Parkes AB, Premawardhana LD. Postpartum thyroiditis. *Autoimmunity* 2002;35:169-173.
79. Nikolai TF, Turney SL, Roberts RC. Postpartum lymphocytic thyroiditis. Prevalence, clinical course and long term follow up. *Arch Intern Med* 1987;147:221-224.
80. Shahbazian HB, Sarvghadi F, Azizi F. Ultrasonographic characteristics and follow-up in post-partum thyroiditis. *J Endocrinol Invest* 2005;28:410-412.
81. Zuhur SS, Ozel A, Kuzu I, et al. The Diagnostic Utility of Color Doppler Ultrasonography, Tc-99m Perchnetate Uptake, and TSH-Receptor Antibody for Differential Diagnosis of Graves' Disease and Silent Thyroiditis: A Comparative Study. *Endocr Pract* 2014;20:310-319.
82. Miyakawa M, Tsushima T, Onoda N, et al. Thyroid ultrasonography related to clinical and laboratory findings in patients with silent thyroiditis. *J Endocrinol Invest* 1992;15:289-295.
83. Ross DS. Syndromes of thyrotoxicosis with low radioactive iodine uptake. *Endocrinol Metab Clin North Am* 1998;27:169-185.
84. Diehl LA, Romaldini JH, Graf H, et al. Management of amiodarone-induced thyrotoxicosis in Latin America: an electronic survey. *Clin Endocrinol (Oxf)* 2006;65:433-438.
85. Martino E, Bartalena L, Bogazzi F, Braverman LR. The effects of amiodarone on the thyroid. *Endocr Rev* 2001;22:240-254.
86. Martino E, Safran M, Aghini-Lombardi F, et al. Environmental iodine intake and thyroid dysfunction during chronic amiodarone therapy. *Ann Intern Med* 1984;101:28-34.
87. Wimpfheimer C, Staubli M, Schadelin J, Studer H. Prednisone in amiodarone-induced thyrotoxicosis. *Br Med J* 1982;284:1835-1836.
88. Harjai KJ, Licata AA. Effects of amiodarone on thyroid function. *Ann Intern Med* 1997;126:63-73.
89. Martino E, Bartalena L, Bogazzi F, Braverman LE. The effects of amiodarone on the thyroid. *Endocr Rev* 2001;22:240-254.
90. Friedrich-Rust M, Theobald J, Zeuzem S, Bojunga J. Thyroid function and changes in ultrasound morphology during antiviral therapy with pegylated interferon and ribavirin in patients with chronic hepatitis C. *J Viral Hepat* 2009;16:168-177.
91. Loy M, Perra E, Melis A, et al. Color-flow Doppler sonography in the differential diagnosis and management of amiodarone-induced thyrotoxicosis. *Acta Radiol* 2007;48:628-634.
92. Bartalena L, Bogazzi F, Martino E. Amiodarone induced thyrotoxicosis: a difficult diagnostic and therapeutic challenge. *Clin Endocrinol (Oxf)* 2002;56:23-24.
93. Eaton SE, Euinton HA, Newman CM, Weetman AP, Bennet WM. Clinical experience of amiodarone-induced thyrotoxicosis over a 3-year period: role of colour-flow Doppler sonography. *Clin Endocrinol* 2002;56:33-38.
94. Theodoraki A, Vanderpump MP. Thyrotoxicosis associated with the use of amiodarone: the utility of ultrasound in patient management. *Clin Endocrinol (Oxf)* 2015. doi:10.1111/cen.12988
95. Alzahrani AS, Ceresini G, Aldasouqi SA. Role of ultrasonography in the differential diagnosis of thyrotoxicosis: a noninvasive, cost-effective, and widely available but underutilized diagnostic tool. *Endocr Pract* 2012;18:567-578.
96. Piga M, Cocco MC, Serra A, Boi F, Loy M, Mariotti S. The usefulness of 99mTc-sestaMIBI thyroid scan in the differential diagnosis and management of amiodarone-induced thyrotoxicosis. *Eur J Endocrinol* 2008;159:423-429.
97. Dietrich CF, Bojunga J. Ultrasound of the thyroid. *Z Gastroenterol* 2015; 53(3):208-225.
98. Cosgrove D, Barr R, Bojunga J, Cantisani V, Chammas MC, Dighe M, Vinayak S, et al. WFUMB Guidelines and Recommendations on the Clinical Use of Ultrasound Elastography: Part 4. Thyroid. *Ultrasound Med Biol* 2017;43(1):4-26.