

---

# Multidisciplinary Approaches to the Stimulation of Wound Healing and Use of Dermal Substitutes in Chronic Phlebostatic Ulcers

---

Raffaele Capoano, Rita Businaro, Besar Kolce, Andrea Biancucci, Silvia Izzo, Lidia De Felice and Bruno Salvati

Additional information is available at the end of the chapter

<http://dx.doi.org/10.5772/intechopen.81791>

---

## Abstract

**Research focus:** Skin injuries are evolving as an epidemic issue. Chronic skin lesion is a globally widespread disease, often referred to as a “wound difficult to heal” and one which has a strong impact on both overall health and quality of life. Genetic and clinical variables, such as diabetes, smoking and inflammatory/immunological pathologies, are among the important risk factors limiting the regenerative powers of many therapeutic applications. Therefore, optimisation of current clinical strategies is critical. **Experimental research:** Here we summarise the field’s current state by focusing on the use of stem-cell therapeutic applications in wound healing, placing considerable emphasis on current clinical approaches being developed at Rome’s *Sapienza* University. These involve protocols for the ex vivo expansion of adipose tissue-derived mesenchyme stem cells using a patented GMP-compliant platelet lysate, Mesengen™, and cellular and acellular dermal substitutes. A combination of multiple strategies, including genetic modifications of stem cells, biomimetic scaffolds or novel vehicles like nanoparticles, is also discussed as future approaches. **Case studies:** Here we present a report portraying our clinical experience of the treatment of chronic phlebostatic ulcers. The aim of the study reported here was to evaluate the effectiveness of treatment with dermal substitutes of cutaneous lesions originating from chronic venous insufficiency, therapy which took into consideration parameters such as the reduction of wound size and the improvement of quality of life. Chronic skin lesion, a globally widespread disease, is often referred to as a “difficult wound” and has a strong impact on both overall health and quality of life. The difficulties encountered when seeking to heal this ailment have led to a quest for and development of new therapeutic approaches, including dermal substitutes. We can subdivide these into acellular matrices, such as Integra and Hyalomatrix, and cell therapies such as platelet concentrate and mesenchyme cell concentrate. **Results:** In all the patients treated, elements of improvement

were observed: the appearance on the wound bed of small islands of granulation tissue, superficialization of the bottom of the ulcer and a growth of marginal tissue. During the first 30 days, a reduction in more than 25% of the area of the lesion and a reduction in more than 50% at the end of the observation period were recorded in 10 of the patients who underwent preliminary surgical treatment out of the 13 subjects included in the study sample. On the whole, at the end of the observation period, we witnessed an average 57% decrease in the lesion in all the patients; furthermore, during the treatment period, there was a gradual reduction in pain, measured using the NRS numerical scale. An overall average reduction in pain of four points on the NRS numerical scale was achieved. At the end of the 8-week evaluation period, the majority of the patients reported an improvement in the quality of their lives, since, in addition to the reduction of spontaneous pain, there was a diminution of pruritus, secretions—often malodorous and capable of affecting social life negatively—with recovery of functional capacity and almost complete recovery of habitual daily activities. During the period of treatment, no superinfections of the wounds or secondary complications related to the use of the various products were detected. **Main conclusions:** The numerous technological opportunities provided by regenerative medicine—including advanced dressings and dermal substitutes—if applied correctly, in compliance with a multidisciplinary approach where necessary, seem to offer advantages not only in terms of clinical efficacy and patient life quality but also in terms, it would appear, of healthcare costs, an aspect which should not be either overlooked or underestimated.

**Keywords:** wound healing, skin lesion, regenerative medicine, dermal substitutes, phlebostatic ulcers

---

## 1. Introduction

The management of scarring in chronic wounds represents one of the most relevant clinical problems affecting healthcare in the United States and in Europe [1]. Scars can cause severe physical damage, resulting, predominantly, in damage to the skin.

This kind of lesion causes loss of cutaneous substance, varies in size and involves loss of underlying tissue as well; this kind of lesion is often defined as “difficult” because it fails to heal spontaneously or achieve speedy and complete recovery. Acute or chronic wounds of this type are due to multifactor pathogeneses, and their healing is impeded, as a rule, by persistent local or systemic factors which favour chronicisation.

Medical-surgical treatment of these so-called “difficult” lesions represents a constantly increasing social-health issue, a “silent epidemic” affecting large sectors of the world’s population, one which, at present, concerns about 2,000,000 Italians; these numbers are destined to grow further due not only to diverse risk factors but also to the phenomenon of ageing [2, 3]. Subjects with pre-existing diseases are of particular concern, as treatment and resolution of injury frequently require long-term care. Healing is often compromised in similar individuals because of the presence of diabetes, the metabolic syndrome, chronic renal failure and ageing [4] since the ability to rapidly re-epithelialise and revascularise injured tissue is impaired. In some cases, the evolution of the lesion is correlated to the root-cause pathology, as, in particular, in the case of “immunohaematological” ulcers.

Both clinical and genetic features of individual patients must be considered when addressing wound healing, as well as variations in medical responses based on the type of chemical tools employed and the nature and extent of the injured area. In fact, large wounds, under either adverse local or systemic conditions, respond poorly to treatment and can frequently reopen.

It is calculated that about 10% of the population is likely to develop a chronic lesion during its lifetime, leading to discomfort (pain, reduced hygiene, sleep disturbance), loss of autonomy, need of assistance and frequent hospitalisation, with considerable deterioration of the quality of life (QoL) due, among other things, to embarrassment, social isolation, compromisation of employability, monetary costs, anxiety-depressive syndromes [5] as well as a mortality rate of 2.5% [6, 7]. A chronic dermal lesion means having to live with a persistent, enduring and treatment-resistant wound, which has a significant impact on the overall health and quality of life of patients, members of their families and caregivers.

Chronic venous insufficiency is responsible for 80% of the ulcers affecting the lower limbs, a sequela constituting one of the gravest complications encountered by CVIs [2].

As people grow older, venous ulcers begin to constitute a serious health problem, considering the fact that 4% of people aged over 65 suffer from them. This renders the whole issue highly topical while making possible therapeutic treatments within the ambit of regenerative medicine of considerable interest.

A number of strategies have been developed recently to treat dermal wounds resulting from chemical exposure. One of the most efficient methods used to reduce bacterial load and the incidence of sepsis is debridement of the wound [8]. Cleansing agents and topical antibiotics are also useful when seeking to reduce microbial growth and invasive infection [9].

Current literature contains numerous studies [10–12], which underline the diffusion of medication considered “advanced” and capable of producing improved clinical and economic outcomes associated with the healing of similar lesions. The notion “advanced” implies not only the use of particular products and medications, surpassing the therapeutic concept of keeping the ulcer in a “dry” environment and leaving medication on the lesion for lengthy periods of time, but also means changing wound management substantially. Advanced methodologies seem to lead to a diminution of the number of medication sessions required compared to those prescribed by traditional approaches and, theoretically speaking, a reduction in overall healing time, which also spells a reduction in costs. We have expressed ourselves in dubitative terms here because many factors of a logistic and not simply clinical nature, capable of impacting negatively or positively on the treatment opted for, are involved and can contribute to the success or failure of the therapy. One of the factors—common to acute and chronic lesions and, therefore, regardless of aetiopathogenesis—which is capable of having a positive impact on regenerative therapy is appropriate “wound bed preparation” (WBP). “Wound bed preparation” involves a detailed, coordinated and sometimes multidisciplinary management of the lesion aimed at removing all the factors, which may hamper tissue regeneration, while favouring endogenous healing, promoting cellular proliferation and the reparatory processes “triggered” by the products applied. This concept, no longer considered recent, has significantly affected the management of chronic cutaneous wounds and the results obtained.

In order to outline the principles of WBP more precisely, the English acronym TIME (tissue, infection or inflammation, moisture imbalance, epidermal margin) is used. TIME breaks up what is actually a single therapeutic process into parts, indicating the fundamental aspects to be dealt with during preparation of the wound bed.

In lesion management, WBP permits definitive elimination of all the elements that may hinder the development of granulation tissue, thus laying the foundations for effective use of innovative therapeutic tools. The purpose of advanced dressing is to create an environment ideal for proliferative cicatrisation processes, for the isolation of the wound from traumatic and infectious agents, while improving the state of the bottom of the wound and promoting maximum possible tropism of the margins and the periwound skin.

Additionally, treatment of the wound with autologous leukocytes seeded in a proangiogenic matrix and enriched with a platelet concentrate preparation has been reported to induce the release of growth factors, cytokines and chemokines, thus increasing the in situ recruitment of endothelial precursor cells and promoting the resolution of microbial infections [13]. Despite these improvements, treatment of dermal wounds has not always produced positive outcomes. Major drawbacks include the fact that the skin is a highly complex organ and is, therefore, difficult to reconstruct after injury. In actual fact, the physiological re-epithelialisation phase is a multistep process involving several cell types and molecular mechanisms, and the presence of a favourable environment for bacterial colonisation is highly undesirable [14, 15]. As a consequence, most current treatments have been palliative only, aiming mainly at accelerating healing time and limiting additional clinical complications caused by fortuitous bacterial infection. Therefore, alternative strategies are required to balance the treatment of patients, economic costs and the safety of civilians.

The main aim of regenerative medicine is to repair organs and tissues that have been damaged by pathological events and/or trauma and/or ageing in order to restore or improve their biological functions. It is a multidisciplinary field undergoing rapid growth and involving the medical, humanistic and engineering sciences, a field which endeavours to develop functional cells and substitute tissues or organs with a view to repairing, replacing or improving the biological functions lost due to congenital anomalies, trauma and illness or as a result of ageing. The increase in average life expectancy has led, actually, to the need to protract the time people spend in active employment and has made the physical and mental efficiency of older subjects mandatory, but it also implies an inevitable rise in incidences of neoplasms and pathologies that cannot always be cured by the therapies available at present. From this stems the need to develop therapies capable of replacing or regenerating organs damaged by pathological processes or traumas. Referring specifically to the present text, regenerative medicine can solve the problem of chronic vascular ulcers. Some lesions can benefit particularly from regenerative, cellulated and acellulated materials as well as biochemical supports (scaffolds) used to “trigger” granulation, repair tissue and, therefore, cover wounds.

Scaffolds, according to the definition of tissue engineering provided by the National Science, are materials that can best attend to the restoration, maintenance and improvement of the function of tissues, playing a unique role in their repair and above all, in their regeneration [16–18]. Scaffolds provide an appropriate platform for the essential provision of various



factors associated with cell survival, proliferation and differentiation [19]. They can consist in synthetic or absorbable polymeric materials present in nature which may be biological, degradable or nondegradable.

The four main approaches to scaffolding include the use of ECM-secreting cell sheets; preconstituted porous scaffolds of synthetic, natural and biodegradable biomaterials; decellularised ECM scaffolds and cells enveloped in hydrogel [20].

In the field of surface-tissue regeneration, numerous grafts based on acellular dermal and epidermal scaffolds have been tested, using natural and synthetic polymers, or a combination of both, described as “effective substitutes for wound healing”.

Another important area where regenerative medicine is applied is that of cell therapy, which is based on the autologous cell suspension (SCAut) technique, that is, the exploitation of cells taken from the patients themselves.

A new chapter in the history of regenerative medicine, though still very controversial and limited to specifically clinical application, is that of tissue bioengineering, that is, the use of totipotent, pluripotent and unipotent cells, potentially capable of originating, respectively, any kind of tissue, a wide range of tissues and a sole cell line; the cells chosen for cropping can come from autologous, homologous and heterologous samples. The isolation, culture and maturation of stem cells are resorted to with a view to replacing damaged tissue. Among the first mechanical and chemical processing techniques used is the *in vitro* cultivation of the epidermis using the “feeder-layer” methodology proposed by Rheinwald J.G. and Green H. in 1977 and the grafting of laminates of expanded *in vitro* keratinocytes or keratinocyte suspensions onto de-epidermised human dermis (DED) introduced by Cuono C.B. in 1987. The potential use of different types of stem cells for regenerative skin-lesion repair has recently received considerable attention [21]. “Difficult” or “stubborn” chronic wounds, characterised by extensive loss of substance and an enduring clinical history of healing and recurrence, represent one of the fields where the bioengineering of tissue may be applied and one of the discipline’s main areas of challenge.

The cell lines which arouse the greatest interest at the moment are those taken from the embryo, the foetus and the umbilical cord as well as a number of adult cells like adipose-tissue-derived mesenchymal stem cells.

Several protocols have been established aimed at ensuring the resolution of wound issues by targeting different phases of the healing process, namely, control of inflammation in a suitable microenvironment, enhancement of stem-cell engraftment after implantation, efficient and terminal transdifferentiation of progenitors towards dermal lineages and the reconstruction of the vasculature system surrounding the wound [22, 23]. Mesenchymal stem cells (MSCs) have recently been proposed as a promising solution capable of enhancing the re-epithelialisation phase [24]. Studies using mouse models have shown that the intradermal injection of human MSCs or adipose-tissue-derived stromal cells (ASCs) accelerates skin-wound healing in nude mice [1]. Similarly, results of clinical trials have demonstrated the benefits derived from the employment of both autologous or heterologous MSCs, especially in chronic wounds [25–28]. Defined as adult multipotent cells, MSCs can be easily obtained from multiple sources, including

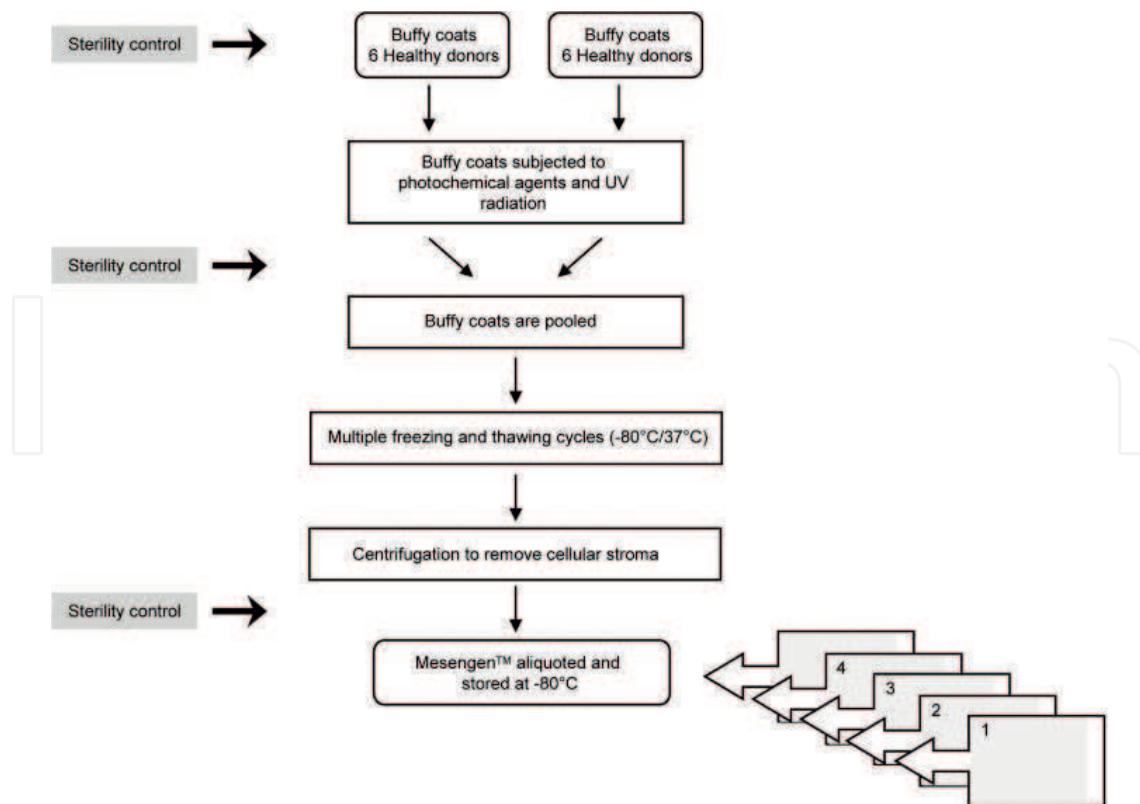
adipose tissue deposits localised in different areas of the body and gathered during major and/or aesthetic surgical procedures [29, 30]. Multiple mechanisms underlying the potential ability of both populations to influence wound repair positively have been proposed; these include modulation of inflammatory states, stimulation of angiogenesis, cell proliferation and fibroblast activity, activation and enhanced migration of keratinocytes to sites of injury in a paracrine fashion, possible direct transdifferentiation of MSCs towards dermal lineage (including fibroblasts and keratinocytes) and, finally, the recruitment of host cells [25, 31, 32]. After in vivo administration, the immune tolerance generated by ASCs, defined as the ability to modulate the immune-surveillance system in the recipient, has been largely reported as their chief biological property, thus highlighting one important advantage their use brings [33, 34]. Moreover, cross communication between ASCs and inflammatory cells at the site of an injury is a major contributory factor. Soluble factors released by MSCs and ASCs, such as vascular endothelial growth factor, interleukin-6 or transforming growth factors, are known to regulate local cellular responses during cutaneous injury [24]. It has been noted that MSCs may also exert antibacterial effects at the site of a wound both by secreting an antimicrobial protein, IL-37, directly and by influencing immune-system phagocytosis positively [24, 35]. The proliferative and transdifferentiative potential of MSCs has been highlighted also in tissue-engineering-based applications, specifically with regard to skin graft reconstruction, where MSCs are employed either alone, as a feeder layer for keratinocytes or seeded in combination with gelatine-, collagen-/chitosan- or fibrin polymer-based scaffolds [36–38]. Of note among suitable substrates, synthetic polymers have been shown to possess considerable ability to absorb and transport fluids as well as provide protection against bacterial exposure [39]. Other methods used to deliver MSCs to the wound site include injection and local or systemic administration of a range of conveyers such as scaffolds, matrices and human amniotic membrane grafts [40–43].

## 2. Novel strategies developed at Rome's *Sapienza* University

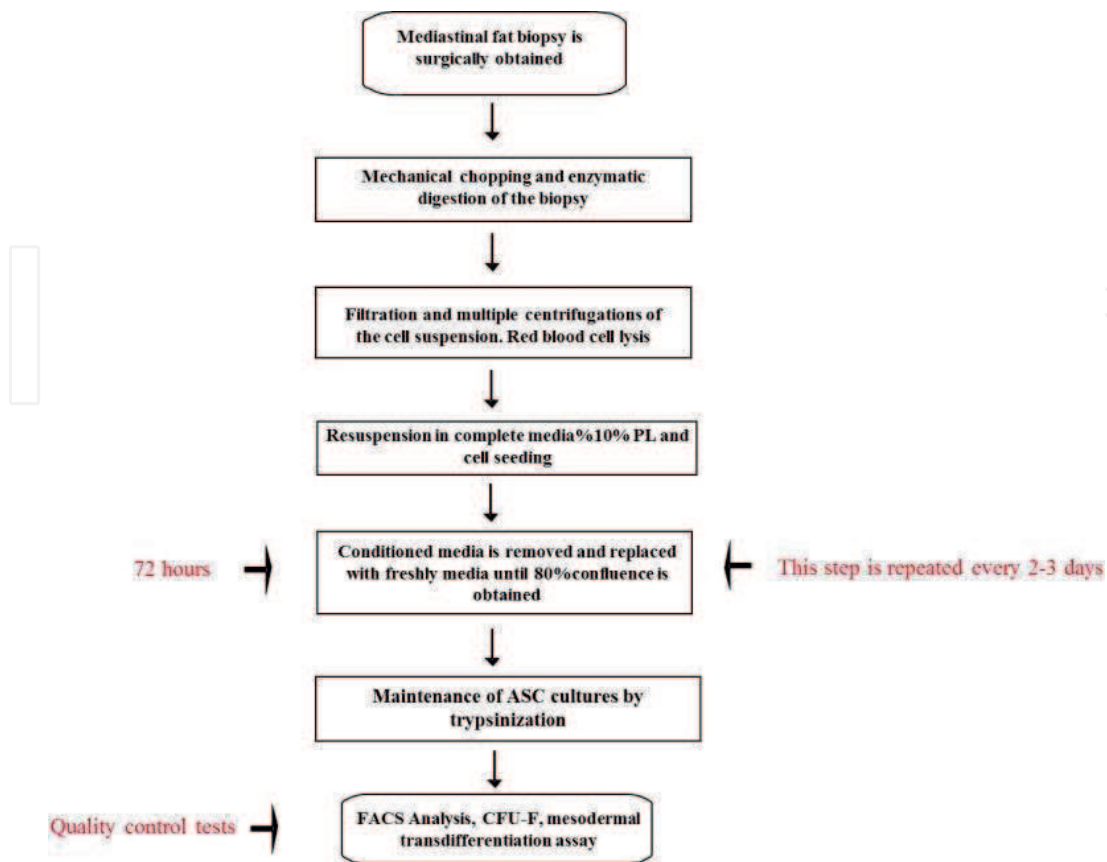
Despite considerable improvements in the employment of ASCs and MSCs in skin-regenerative procedures, their current use is limited because of the presence of foetal bovine serum (FBS) in the cultures during their *ex vivo* expansion. According to the European Union's Good Manufacturing Practice (GMP) guidelines, the employment of FBS is to be discouraged, as it is a potential source of zoonoses [29, 44, 45]. In the light of this, platelet lysate (PL), a haemoderivative enriched with soluble mitogenic factors [29, 44, 46], represents a superior alternative to FBS. Reported to enhance the biological stem-cell properties of ASCs, such as proliferation, clonogenic capacity and migration [28, 46, 47], PL has been also been recently shown to be capable of promoting ASC's pluripotency and being committed to specific phenotypes [46–49]. Interestingly, PL, manufactured in injectable form or gel [8, 9, 13, 14], embedded in scaffolds or incorporated in nanoparticles, also represents a widely investigated clinical strategy deemed to accelerate wound healing in chronic ocular and diabetic dermal ulcers. Because of the large amounts of cytokines and growth factors contained in PL, it presents multiple and significant advantages if applied locally to skin wounds when seeking enhancement of angiogenesis and fibroblast migration, restoration of collagen synthesis and reduction of oxidative stress [46]. In addition, it has been demonstrated that PL is capable of re-establishing skin integrity efficiently [50].

Recently, a GMP-compliant PL (Mesengen™, Pub. No. WO/2013/042095) has been developed as an adjuvant for culturing human ASCs, endothelial progenitor cells and fibroblasts [29, 46, 51, 52].

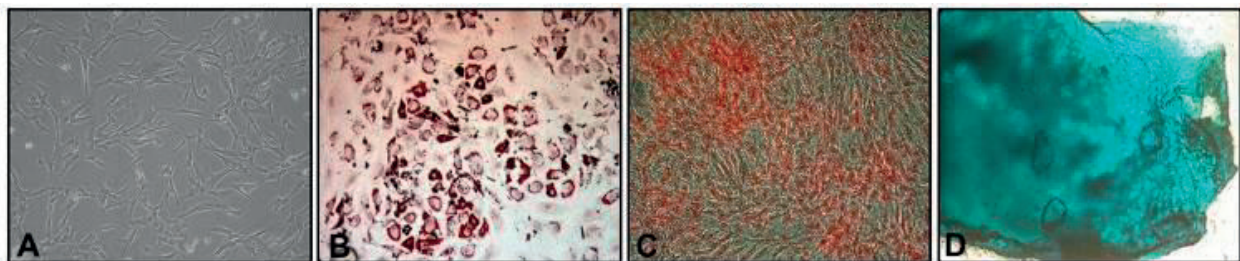
The Mesengen™ generation method has been standardised and optimised so as to determine the amounts of cytokines and growth factors in the preparation. Importantly, potential fungi, viruses and bacteria known to contaminate human haemoderivatives are avoided by rapidly inactivating the Mesengen™ by means of a combination of a photochemical agent and UV radiation. A summary of the basic steps in the preparation of PL is provided in **Figure 1**. It is worth noting that researchers at *Sapienza* have exploited the biological and molecular properties of Mesengen™ by concurrently establishing a standardised protocol (**Figure 2**) to isolate and expand *ex vivo* ASCs from alternative fat deposits like the mediastinum (**Figure 3**) [29, 47]. Recent studies on Mesengen™ carried out by our team have also elucidated its ability to influence the commitment of ASCs by inducing epigenetic modifications [47] as well as positively altering the *in vitro* microenvironment by decreasing oxidative stress [46]. These studies highlight the ability of PL to boost the biological and functional properties of mesenchymal-like cell populations. Therefore, it is plausible that the combination of Mesengen™ and ASCs or other progenitor-cell populations might be employed successfully to target wound repair and regeneration. Furthermore, PL has been reported to maintain its properties either as a liquid formulation or frozen, highlighting an important clinical advantage. In the future, this approach might be considered complementary to routine strategies developed at Rome's *Sapienza* University, where a centre of excellence for



**Figure 1.** Overview of the major steps in the manufacturing of platelet lysate (Mesengen™).



**Figure 2.** Flow diagram showing the optimization and standardisation phases to isolate and expand in vitro ASCs derived from the mediastinal fat depots.



**Figure 3.** Optical image of ASCs at passage 3 cultured in PL and displaying the typically spindle-shaped morphology (A). Note that platelet lysate is able to preserve the mesodermal transdifferentiation of ASCs towards the adipogenic (B), osteogenic (C) and chondrogenic (D) lineages. Magnification 5 $\times$ .

in vitro culturing of skin substitutes exists already, providing the treatment of a wide range of dermal disorders, such as burns, chronic ulcers, giant congenital melanocytic nevi and even the reconstruction of epithelial mucosa [53–58]. Specifically, the epithelial “organoid” developed by our research group is based on a combination of transplanted autologous cells seeded in biomimetic scaffolds. This methodology has been successfully established, is clinically available at several hospitals collaborating with *Sapienza* and has already been shown to significantly reduce hospitalisation time and costs [59].



Our group's experience of advanced dressings and dermal substitutes over the years during treatment of patients with acute and chronic ulcers of multifactorial origin (arteriopathic, phlebopathic, immunological and traumatic) produced a study based on chronic arteriopathic patients, the results of which were published in the article "Wounds Difficult to Heal: An Effective Treatment Strategy" [60]. There we highlighted the fact that recognition of the aetiology of a skin lesion and the correction of the pathophysiological conditions that determine and support it are the assumption and "step" fundamental to the success of local treatment. It also emerged that a "standard", univocal treatment applicable to all and every kind of wound does not exist. Appropriate local treatment involves a combination of multiple medications, products and devices demanding respect of their timing and guarantees regarding their ongoing management.

In a very recent study we focused, instead, on the treatment of chronic phlebostatic ulcers. This study was conducted at the Department of Surgical Sciences of Rome's *Sapienza* University between October 2016 and March 2018.

The purpose of that study was to assess the efficacy of using dermic substitutes when treating patients suffering from chronic skin ailments due to and sustained by venous insufficiency.

This examination took parameters like the following into consideration: reduction of the size of the wound and improvement of quality of life (QoL) as expressed subjectively, on the basis of a number of elective factors.

## 2.1. Materials and methodology

The study sample involved 13 patients suffering from chronic venous insufficiency (CVI) and postthrombotic syndrome, 5 of whom were also affected by pronounced varicosity, with incontinence of the saphenous-femoral junction and protracted reflux of the great saphenous vein (GSV). Ten of the patients, before proceeding to treatment with dermal substitutes, had been treated surgically for phlebopathy: six had undergone "stripping" of the GSV (of the "short" in two cases); two patients underwent crossectomy due to recurrence accompanied by inguinal-cruel cavernoma; in five of the patients, the "feeder" veins were identified and linked, two of them as treatment in isolation (the other three in association with treatment for varices); and in the remaining three cases, the only management, besides local intervention, was elastic compression.

Eight other patients, initially included in the study, were excluded later on because of the impossibility of proceeding with the therapy in the manner set down by the team's protocol.

The patients were chosen according to the following criteria:

- They had to be aged 50 or over.
- They had to present with chronic venous insufficiency, accompanied or not by varicosity of the great saphenous vein.
- Their ulcers had to have an area no greater than 20 cm<sup>2</sup>.

The presence of undermined margins was an indication of treatment with infiltrations of platelet concentrate (PC) or mesenchymal (“regenerate”) cells.

The presence of wound contamination was a criterion dictating temporary exclusion although patients were readmitted to the study once this condition was resolved.

All the patients provided informed consent, having evaluated compliance with the proviso requiring their participation for the entire duration of the treatment.

The criteria for exclusion were:

- Exposure of bone or nerve, ligament or aponeurotic tissue
- The presence of immunohaematological disease
- Neoplasms and chemoradiotherapy treatment
- The use of anti-inflammatory drugs, immunosuppressant and cytostatic drugs and oral anticoagulants for severe comorbidity (chronic renal failure requiring dialysis, congestive cardiomyopathies, liver failure) and concomitant arteriopathies (mixed genesis of the ulcer)
- Poor/low self-sufficiency and/or lack of family or caregiving support, a factor mandatory for participation in the study

All the patients were assessed preliminarily by an ecocolor Doppler examination and other tests useful for inclusion/exclusion in the study. The ultrasound check sought confirmation of proximal saphenous-femoral valve incontinence and/or of saphenous perforators; in cases with referred stripping, it looked for the presence of accessory saphenoids or lapses of the cross (cavernoma) and, as far as deep circulation was concerned, the patency and absence of reflux with severe incontinence. These data, together with an objective examination, were the criteria adopted for preliminary surgical treatment and for the choice of local treatment recurring to one or more of the four dermal substitutes foreseen by the study, in some cases in sequence and/or in combination.

All the patients underwent local “wound bed preparation”, requiring different lengths of time for different patients. WBP was followed by the applications of dermal substitutes. The dermal substances used were autologous or homologous platelet concentrates (PC); “micro-grafts” of autologous mesenchymal origin (“Rigenera Activa” System); “HyaloMatrix” PA Tissue Reconstruction Matrix (Fidia), on a hyaluronic acid base; and “Integra” Dermal Regeneration Template (LifeSciences Corp.), on a collagen base.

For the preparation and application of platelet concentrate, both from whole autologous and homologous blood, a specific protocol is followed: in the former case, the donor’s personal data are recorded in the Blood Transfusion Service’s management system (Emonet) which assigns an identification number to the donation; the blood collected is contained in a bag containing ACD (citrate glucose) anticoagulant, and the CP is produced by recurring to two centrifugation cycles: the first of these at a low rpm rate (210 g × 10 minutes) to obtain platelet-rich plasma and eliminate the red blood cells and leucocytes and the second at a higher rpm rate (2000 g × 15 minutes) to concentrate the platelets by eliminating the depleted plasma.

The platelet concentrate should be  $1 \times 10^6/\text{ml} \pm 20\%$ . All the preparations thus obtained are checked for the biological validation required by law; a blood count is carried out as well as a microbiological test to verify their sterile state.

To keep the CP, sterile containers are used, each dose is rendered identifiable by its donation code; the type of the blood component and the expiry date of the product are also provided. All production and packaging procedures are carried out in aseptic conditions, in a sterile-welded closed circuit or under a laminar flow hood during the phases when it is necessary to open the circuit. The pouches containing the CP are deposited in protective cases with labels bearing the same data as those indicated on each dose and stored in a freezer at  $-80^\circ\text{C}$ .

In cases where the patient's clinical and/or haematological conditions, the size of the ulcer and the number of medications to be carried out do not permit harvesting of autologous blood, umbilical cord or fractional blood from an adult donor is used.

To produce CP from umbilical-cord blood, cord blood units deemed unsuitable for the haematopoietic stem-cell transplant bank are availed of. Cord units are considered suitable for the production of CP if they meet the foreseen regulatory requirements and are endorsed by specific informed consent as prescribed for their use. The production method used is the same as that described for CP obtained from whole autologous blood. For the treatment units compatible with the blood group of the candidate for treatment are used.

For the production of homologous fractional-blood CP, the blood component is prepared by collecting one or more units of single buffy-coat platelets and a bag of freshly frozen plasma, fractioned with blood donations free of transmissible viral diseases. The final platelet concentration should always be  $1 \times 10^6/\text{ml} \pm 20\%$ . The CP thus obtained is stored in the manner described above.

On the day of the treatment, the platelet concentrate is defrosted and activated by adding 10% calcium gluconate (0.3 ml of Ca per ml of CP): in practice, 10 ml of the CP are placed on a sterile plate and mixed with 3 ml of calcium gluconate. The solution, stirred gently and left to rest for 10'–15', forms the platelet gel to be placed on a sterile gauze and placed directly on the ulcer, making sure that it covers the entire area of the lesion.

CP gel was used on seven patients, in compliance with our protocol of one application every 4 days for a maximum of 8 weeks (for a total of 14 dressings), in three cases homologous CP (with low Hb values found upon haemochromocytometric examination), and in four cases, autologous CPs (blood sampling of 410 cc) were considered sufficient for the applications foreseen.

In six patients, the "regenerate" system was used, with one application every 4–5 days, for a maximum of four applications, over a total of about 20 days; in three of these cases, the treatment was used in association with and subsequent to CP, because it had not been possible to prolong the application of CP for the entire 8-week period (in the case of two patients) or because, at the end of the maximum number of 14 applications of the platelet concentrate, a completely unsatisfactory result was obtained (in the case of one patient); in the other three cases, after treatment with Rigenera (for a maximum of four applications over a total period of 3 weeks), Thiersch thin dermo-epidermal grafts were carried out.

The “Hyalomatrix PA” dermal substitute was applied to one patient and the “Integra” dermal substitute to two patients. This choice was made when the patients presented a particularly “lively” tissue granulation phase and the size of the lesion was close to the 20-cm<sup>2</sup> limit (the size of the product used being 5 × 5 cm). These patients were medicated every 3–4 days, according to the modalities set down in the technical data sheet, until the product was absorbed. On the basis of our protocol, all 13 patients were medicated every 3–7 days, monitored and observed for a total period of 8 weeks.

At the beginning of the study and at the end of the 8-week treatment period, in order to assess its efficacy, the following parameters were considered and used to define the results:

- a. The extent of the reduction of the size of the ulcer
- b. Patients’ subjective perception of pain according to the NRS numerical scale, a scale of values from 0 to 10, where 0 corresponds to absence of pain and 10 to the maximum level of pain perceived
- c. Quality of life, this too based on patients’ subjective judgement, with reference to night-time rest, itching, pain, need for painkillers, wet impregnation of the wound, bad smell and hygiene of the wound.

All these are elements that strongly impact upon life relationships and recovery of habitual daily activities, including work. A numerical value was attributed to each parameter, used together with all the others and employed to calculate overall average values.

Our study’s 13-patient sample, as shown in **Table 1**, included 6 females and 7 males, whose ages ranged between 65 and 77 (for a mean age of 71); at the beginning of the treatment, the maximum average diameter of the wounds was 5 cm, a range of between 3 and 6.5 cm.

## 2.2. Results

During the 8 weeks of treatment, some signs of improvement were observed in all patients: appearance in the wound bed of small islands of granulation tissue, superficialization of the bottom of the ulcer and growth of margin tissue. During the first 30 days, a reduction in over 25% of the area of the wound was observed; a reduction in more than 50% was observed in the 10 patients who underwent preliminary surgical treatment. In the remaining three cases, that is, the patients subjected to elastic-compressive bandaging only, there was an average reduction in 45% by the end of the 8 week.

The first four patients treated with CP, obtained on average a 57.5% reduction of the wound’s maximum diameter. The three patients treated with a combination of CP and Rigenera achieved

Diameters of the ulcers during the treatment				
	Beginning (cm)	End (cm)	Reduction (%)	P-value
Average value	5.0	2.1	56.9	0.001
Standard deviation	1.1	0.6	7.2	

**Table 1.** Variations of the diameters of the lesions from the beginning to the end of the treatment.



<b>Pain (numerical rating scale)</b>				
	<b>Time 0</b>	<b>4 weeks</b>	<b>8 weeks</b>	<b>P-value</b>
Average value	6.9	4.3	3.2	0.001
Standard deviation	1.3	1.3	1.2	

**Table 2.** Variations of the “pain” from the beginning to the end of the treatment.

	<b>Aggravated (A)</b>	<b>Unmodified (B)</b>	<b>Slightly ameliorated (C)</b>	<b>Clearly ameliorated (D)</b>
Nocturnal rest	0 pts.	3 pts.	3 pts.	7 pts.
Itch	0 pts.	3 pts.	2 pts.	8 pts.
Pain	0 pts.	0 pts.	4 pts.	9 pts.
Need of analgesics	0 pts.	0 pts.	3 pts.	10 pts.
Mobilisation	0 pts.	3 pts.	3 pts.	7 pts.
Foul odour	0 pts.	2 pts.	2 pts.	9 pts.
Restart of daily activities	0 pts.	2 pts.	4 pts.	7 pts.
Social and relational life	0 pts.	1 pts.	3 pts.	9 pts.
Total (average values)	0	1.75	3	8.25

**Table 3.** Variations in QoL, stated by the patients.

a 60% reduction, a result just marginally better than the previous one; but one needs to keep in mind that these presented graver lesions are harder to manage than those of other patients. The three other cases, treated with Rigenera and a Thiersch graft, achieved a 55% reduction in the ulcer’s greatest diameter. The two patients treated with the “Integra” dermic substitute obtained a 52.5% diminution of the wound’s maximum diameter. Finally, the patient treated with the “Hyalomatrix” skin substitute achieved a 60% reduction. On the whole, by the end of the observation period, the average reduction of the lesion for 13 patients was 57%.

All the patients during the period of treatment reported a gradual reduction in pain, from an initial average of 7 on the NRS scale (range 9–5) to an average of 3 (range 6–2) at the end of the period (see graph 1). On the whole, the average reduction of perceived pain dropped by 4 points on the NRS numerical scale.

At the end of the 8-week treatment period, an average of 8.25 out of 13 patients reported improvements in their quality of life, a spontaneous reduction in pain, a lessening of itchiness and secretion, lower incidence of bad odour with a recovery of functional capacity and almost complete resumption of habitual everyday activities. The results are summarised in **Tables 1–3**.

It needs to be pointed out that during the treatment period no superinfections of the wounds requiring interruption of the therapy arose nor did other secondary complications associated with the use of the products occur.

### 3. Perspectives and conclusions

Despite advances in wound-healing treatment, dermal tissue still remains a difficult organ to regenerate. Our work in the future will probably consist in multistep approaches rather than in single repair strategies, which have proven to be only partially efficacious. Future strategies will, most likely, combine stem-cell properties, next-generation scaffolds or vehicles (i.e. nanoparticles) and growth factors or supplements, like PL. Improvements in our understanding of skin biology and the physiological processes of wound repair should permit us to interpret healing microenvironments better. To achieve our final goal, we will be required to design more personalised therapies, taking into account genetic variability, wound types as well as patients' clinical and metabolic features.

It is not possible, in actual fact, to reach definitive conclusions given the variability of the factors capable of influencing the outcome of therapy and the difficulty of rendering populations of patients treated totally homogeneous. Furthermore, this aspect also emerges from the field's latest literature [60–62], being the only source available at present (since there are no definitive guidelines available). In addition, this kind of patient is not always willing to follow the lengthy periods of treatment often deemed necessary or comply with the temporal parameters the cure requires. Due to certain events like intercurrent pathologies, hospitalisation or logistic problems, exclusion from a study sample may become inevitable. For these reasons we consider the results obtained here as preliminary.

- Having said this, we are in a position to assert that skin substitutes are capable of determining a clinical improvement of chronic ulcers caused by pathologies of the vein when, after use of traditional medication, or accurate advanced debridement, the condition of the ulcer is such that regeneration of tissue is feasible. Indeed, timing seems essential for prescriptions as well: both precocious and tardy dressing may nullify the effectiveness of a treatment, jeopardising the outcome.
- The integrated use of different compounds can prove useful, especially in relation to the long periods often needed to obtain complete healing. Every single treatment may determine partial, even substantial, improvement but may fail to cure the lesion completely: there is no “ideal” medication for all ulcers, just as there is no “ideal” medication applicable to all the developmental stages of an ulcer.
- The specific treatment of comorbidities and restoration of a satisfactory level of nutrition are of great importance when pursuing positive outcomes of any local therapy, though chances of complete success are related mainly to a correct diagnosis regarding the origin of the ulcer and, above all, the removal, surgical if necessary, of factors impeding recovery: “The beginning of healing lies in knowledge of the ailment” (*Epicurus, 341–270 BCE*).
- Dermal substitutes have become, therefore, part of the modern concept of the multidisciplinary approach to the treatment of chronic skin lesions, in particular, the management of wounds that are less likely to heal availing of standard therapy. They represent a valid therapeutic “step”, whether used alone or in combination, also considering the potential clinical benefits demonstrated and the low percentage of complications related to their use.

- The use of these substitutes *does* cause a reduction in the size of ulcers, improving, above all, the quality of life of patients. One notices, in particular, a reduction in levels of pain and resumption of habitual everyday activities.
- The choice of the best therapy, from among the different options available, also depends on the physician's ability to perceive the one most suitable for the type and characteristics of the patient and the availability of his/her caregivers.

In conclusion, the numerous technological opportunities made available by regenerative medicine, including advanced dressings and dermal substitutes, if used correctly and following a multidisciplinary approach if necessary, seem to offer advantages in terms of clinical efficacy, patients' quality of life and, last but not least, also in terms of healthcare costs.

## Acknowledgements

This work was supported by Ateneo ("Sapienza" University of Rome).

## Conflicts of interest

The authors declare no conflicts of interest.

## Author details

Raffaele Capoano<sup>1\*</sup>, Rita Businaro<sup>2</sup>, Besar Kolce<sup>1</sup>, Andrea Biancucci<sup>1</sup>, Silvia Izzo<sup>1</sup>, Lidia De Felice<sup>3</sup> and Bruno Salvati<sup>1</sup>

\*Address all correspondence to: [raffaele.capoano@uniroma1.it](mailto:raffaele.capoano@uniroma1.it)

1 Department of Surgical Sciences, "Sapienza" University of Rome, Italy

2 Department of Medico-Surgical Sciences and Biotechnologies, "Sapienza" University of Rome, Italy

3 Department of Molecular Medicine, "Sapienza" University of Rome, Italy

## References

- [1] Rodriguez J, Boucher F, Lequeux C, et al. Intradermal injection of human adipose-derived stem cells accelerates skin wound healing in nude mice. *Stem Cell Research & Therapy*. 2015;6:241

- [2] Hellström A, Nilsson C, Nilsson A, Fagerström C. Leg ulcers in older people: A national study addressing variation in diagnosis, pain and sleep disturbance. *BMC Geriatrics*. 2016;**16**:25
- [3] Fried LP, Tangen CM, Walston J, Newman AB, Hirsch C, Gottdiener J, et al. Frailty in older adults: Evidence for a phenotype. *Journal of Gerontology. Series A, Biological Sciences and Medical Sciences*. 2001;**56**(3):M146-M156
- [4] Scuderi N, Ceccarelli S, Onesti MG, et al. Human adipose-derived stromal cells for cell-based therapies in the treatment of systemic sclerosis. *Cell Transplantation*. 2013; **22**:779-795
- [5] Maddox D. Effects of venous leg ulceration on patients' quality of life. *Nursing Standard*. 2012;**26**(38):42-49
- [6] Suthar M, Gupta S, Bukhari S, Ponemone VJ. Treatment of chronic non-healing ulcers using autologous platelet rich plasma: A case series. *Biomedical Science*. 2017;**24**(1):16
- [7] Agale SV. Chronic leg ulcers: Epidemiology, aetiopathogenesis, and management. *Ulcers*. 2013; Art ID 413604. DOI: 10.1155/2013/413604
- [8] Sandri G, Bonferoni MC, Rossi S, et al. Platelet lysate embedded scaffolds for skin regeneration. *Expert Opinion on Drug Delivery*. 2015;**12**:525-545
- [9] Fontana F, Mori M, Riva F, et al. Platelet lysate-modified porous silicon microparticles for enhanced cell proliferation in wound healing applications. *ACS Applied Materials & Interfaces*. 2016;**8**:988-996
- [10] Treadwell T, Sabolinski ML, Skornicki M, Parsons NB. Comparative effectiveness of a bioengineered living cellular construct and cryopreserved cadaveric skin allograft for the treatment of venous leg ulcers in a real-world setting. *Advances in Wound Care (New Rochelle)*. 2018;**7**(3):69-76
- [11] Mostow EN, Haraway GD, Dalsing M, Hodde JP, King D. OASIS Venus Ulcer Study Group. Effectiveness of an extracellular matrix graft (OASIS Wound Matrix) in the treatment of chronic leg ulcers: A randomized clinical trial. *Journal of Vascular Surgery*. 2005;**41**(5):837-843
- [12] Edwards H, Finlayson K, Courtney M, Graves N, Gibb M, Parker C. Health service pathways for patients with chronic leg ulcers: Identifying effective pathways for facilitation of evidence based wound care. *BMC Health Services Research*. 2013;**13**:86
- [13] Fabi S, Sundaram H. The potential of topical and injectable growth factors and cytokines for skin rejuvenation. *Facial Plastic Surgery*. 2014;**30**:157-171
- [14] Sun BK, Siprashvili Z, Khavari PA. Advances in skin grafting and treatment of cutaneous wounds. *Science*. 2014;**346**:941-945
- [15] Eming SA, Martin P, Tomic-Canic M. Wound repair and regeneration: Mechanisms, signaling, and translation. *Science Translational Medicine*. 2014;**6**:265, sr6



- [16] Chaudhari AA, Vig K, Baganizi DR, Sahu R, Dixit S, Dennis V, et al. Future prospects for scaffolding methods and biomaterials in skin tissue engineering: A review. *International Journal of Molecular Sciences*. 2016;**17**(12):1974
- [17] Nyame TT, Chiang HA, Leavitt T, Ozambela M, Orgill DP. Tissue-engineered skin substitutes. *Plastic and Reconstructive Surgery*. 2015;**136**:1379-1388
- [18] Suresh DH, Suryanarayan S, Sarvainamurthy S, et al. Treatment of a non-healing diabetic foot ulcer with platelet rich plasma. *Journal of Cutaneous and Aesthetic Surgery*. 2014;**7**(4):229-231
- [19] AS1 M, DJ2 M. Regenerative medicine: Current therapies and future directions. *Proceedings of the National Academy of Sciences of the United States of America*. 2015; **112**(47):14452-14459
- [20] Eming SA, Krieg T, Davidson JM. Inflammation in wound repair: Molecular and cellular mechanisms. *The Journal of Investigative Dermatology*. 2007;**127**(3):514-525
- [21] Ojeh N, Pastar I, Tomic-Canic M, et al. Stem cells in skin regeneration, wound healing, and their clinical applications. *International Journal of Molecular Sciences*. 2015;**16**: 25476-25501
- [22] Caramella CM, Sandri G, Rossi S, et al. New therapeutic platforms for the treatment of epithelial and cutaneous lesions. *Current Drug Delivery*. 2013;**10**:18-31
- [23] Kasuya A, Tokura Y. Attempts to accelerate wound healing. *Journal of Dermatological Science*. 2014;**76**:169-172
- [24] Li X, Hamada T, Ohata C. Potential mesenchymal stem cell therapy for skin diseases. *Experimental Dermatology*. 2013;**22**:515-516
- [25] Wu Y, Chen L, Scott PG, et al. Mesenchymal stem cells enhance wound healing through differentiation and angiogenesis. *Stem Cells*. 2007;**25**:2648-2659
- [26] Isakson M, de Blacam C, Whelan D, et al. Mesenchymal stem cells and cutaneous wound healing: Current evidence and future potential. *Stem Cells International*. 2015;**2015**: 831095
- [27] Kruglikov IL, Scherer PE. Dermal adipocytes: From irrelevance to metabolic targets? *Trends in Endocrinology and Metabolism*. 2016;**27**:1-10
- [28] Chen D, Hao H, Fu X, Han XW. Insight into reepithelialization: How do mesenchymal stem cells perform? *Stem Cells International*. 2016;**2016**:6120173
- [29] Siciliano C, Ibrahim M, Scafetta G, et al. Optimization of the isolation and expansion method of human mediastinal-adipose tissue derived mesenchymal stem cells with virally inactivated GMP-grade platelet lysate. *Cytotechnology*. 2015;**67**:165-174
- [30] Bastianelli D, Siciliano C, Puca R, et al. Influence of Egr-1 in cardiac tissue-derived mesenchymal stem cells in response to glucose variations. *BioMed Research International*. 2014;**2014**:254793

- [31] Sasaki M, Abe R, Fujita Y, et al. Mesenchymal stem cells are recruited into wounded skin and contribute to wound repair by transdifferentiation into multiple skin cell type. *Journal of Immunology*. 2008;**180**:2581-2587
- [32] Ozpur MA, Guneren E, Canter HI, et al. Generation of skin tissue using adipose tissue-derived stem cells. *Plastic and Reconstructive Surgery*. 2016;**137**:134-143
- [33] Vériter S, Wivine A, Aouassar N, et al. Human adipose-derived mesenchymal stem cells in cell therapy: Safety and feasibility in different “hospital exemption” clinical applications. *PLoS One*. 2015;**10**:e0139566
- [34] Condé-Green A, Marano AA, Lee ES, et al. Fat grafting and adipose-derived regenerative cells in burn wound healing and scarring: A systematic review of the literature. *Plastic and Reconstructive Surgery*. 2016;**137**:302-312
- [35] Krasnodembskaya A, Song Y, Fang X, et al. Antibacterial effect of human mesenchymal stem cells is mediated in part from secretion of the antimicrobial peptide LL-37. *Stem Cells*. 2010;**28**:2229-2238
- [36] Fierro FA, O’Neal AJ, Beegle JR, et al. Hypoxic pre-conditioning increases the infiltration of endothelial cells into scaffolds for dermal regeneration pre-seeded with mesenchymal stem cells. *Frontiers in Cell and Development Biology*. 2015;**3**:68
- [37] Wahl EA, Fierro FA, Peavy TR, et al. In vitro evaluation of scaffolds for the delivery of mesenchymal stem cells to wounds. *BioMed Research International*. 2015;**2015**:108571
- [38] Rodrigues C, De Assis AM, Moura DJ, et al. New therapy of skin repair combining adipose-derived mesenchymal stem cells with sodium carboxymethylcellulose scaffold in a pre-clinical rat model. *PLoS One*. 2 May 2014;**9**(5):e96241
- [39] Gomathysankar S, Halim AS, Yaacob NS. Proliferation of keratinocytes induced by adipose derived stem cells on a chitosan scaffold and its role in wound healing, a review. *Archives of Plastic Surgery*. 2014;**41**:452-457
- [40] Gould LJ. Topical collagen-based biomaterials for chronic wounds: Rationale and clinical application. *Advances in Wound Care (New Rochelle)*. 2016;**5**:19-31
- [41] Oyarzun-Ampuero F, Vidal A, Concha M, et al. Secretory profiles and wound healing effects of human amniotic fluid-derived mesenchymal stem cells. *Stem Cells and Development*. 2010;**(6)**:887-902
- [42] Sánchez-Sánchez R, Brena-Molina A, Martínez-López V, et al. Generation of two biological wound dressings as a potential delivery system of human adipose-derived mesenchymal stem cells. *ASAIO Journal*. 2015;**61**:718-725
- [43] Chimenti I, Gaetani R, Forte E, et al. Serum and supplement optimization for EU GMP-compliance in cardiospheres cell culture. *Journal of Cellular and Molecular Medicine*. 2014;**18**:624-634
- [44] Committee for Medicinal Products for Human Use (CHMP). Guideline on the Use of Bovine Serum in the Manufacture of Human Biological Medicinal Products. 2013 EMA/CHMP/BWP/457920/2012 rev 1

- [45] Carducci A, Scafetta G, Siciliano C, et al. GMP-grade platelet lysate enhances proliferation and migration of tenon fibroblasts. *Frontiers in Bioscience (Elite Edition)*. 2016;**8**:84-99
- [46] Siciliano C, Chimenti I, Bordin A, et al. The potential of GMP-compliant platelet lysate to induce a permissive state for cardiovascular transdifferentiation in human mediastinal adipose tissue-derived mesenchymal stem cells. *BioMed Research International*. 2015;**2015**:162439
- [47] Keating A. Mesenchymal stromal cells. *Current Opinion in Hematology*. 2006;**13**:419-425
- [48] Zuk PA, Zhu M, Mizuno H, et al. Multilineage cells from human adipose tissue: Implications for cell-based therapies. *Tissue Engineering*. 2001;**7**:211-228
- [49] Lima AC, Mano JF, Concheiro A, Alvarez-Lorenzo C. Fast and mild strategy, using superhydrophobic surfaces, to produce collagen/platelet lysate gel beads for skin regeneration. *Stem Cell Reviews*. 2015;**11**:161-179
- [50] Tasev D, van Wijhe MH, Weijers EM, et al. Long-term expansion in platelet lysate increases growth of peripheral blood-derived endothelial-colony forming cells and their growth factor-induced sprouting capacity. *PLoS One*. 2015;**10**:e0129935
- [51] Mirabet V, Solves P, Miñana MD, et al. Human platelet lysate enhances the proliferative activity of cultured human fibroblast-like cells from different tissues. *Cell and Tissue Banking*. 2008;**9**:1-10
- [52] Onesti G, Carella S, Ceccarelli S, et al. The use of human adipose-derived stem cells in the treatment of physiological and pathological vulvar dystrophies. *Stem Cells International*. 2016;**2016**:2561461
- [53] Benedetti Panici P, Maffucci D, Ceccarelli S, et al. Autologous in vitro cultured vaginal tissue for vaginoplasty in women with Mayer-Rokitansky-Küster-Hauser syndrome: Anatomic and functional results. *Journal of Minimally Invasive Gynecology*. 2015;**22**:205-211
- [54] Nodale C, Vescarelli E, D'Amici S, et al. Characterization of human vaginal mucosa cells for autologous in vitro cultured vaginal tissue transplantation in patients with MRKH syndrome. *BioMed Research International*. 2014;**2014**:201518
- [55] Nodale C, Ceccarelli S, Giuliano M, et al. Gene expression profile of patients with Mayer-Rokitansky-Küster-Hauser syndrome: New insights into the potential role of developmental pathways. *PLoS One*. 2014;**9**:e91010
- [56] Fioramonti P, Onesti MG, Marchese C, et al. Autologous cultured melanocytes in vitiligo treatment comparison of two techniques to prepare the recipient site: Erbium-doped yttrium aluminum garnet laser versus dermabrasion. *Dermatologic Surgery*. 2012;**38**:809-812
- [57] Mancino R, Aiello F, Ceccarelli S, et al. Autologous conjunctival epithelium transplantation and scleral patch graft for postlensectomy wound leakage in Marfan syndrome. *European Journal of Ophthalmology*. 2012;**22**:830-833
- [58] Gurtner GC, Werner S, Barrandon Y, et al. Wound repair and regeneration. *Nature*. 2008;**453**:314-321

- [59] Businaro R, Corsi M, Di Raimo T, Marasco S, Laskin DL, Salvati B, et al. Multidisciplinary approaches to stimulate wound healing. *Annals of the New York Academy of Sciences*. 2016;**1378**(1):137-142
- [60] Oliveira MG, Abbade LPF, Miot HA, Ferreira RR, Deffune E. Pilot study of homologous platelet gel in venous ulcers. *Anais Brasileiros de Dermatologia*. 2017;**92**(4):499-504
- [61] Frykberg RG, Driver VR, Carman D, Lucero B, Borris-Hale C, Fylling CP, et al. Chronic wounds treated with a physiologically relevant concentration of platelet-rich plasma gel: A prospective case series. *Ostomy/Wound Management*. 2010;**56**:36-44
- [62] Capoano R, Businaro R, Tesori MC, Donello C, Lombardo F, Lo Vasco VR, et al. Wounds difficult to heal: An effective treatment strategy. *Current Vascular Pharmacology*. 2017;**15**(6):582-588