

Assessment of Masticatory and Cervical Muscles' Thickness by Ultrasonography in Patients with Facial Asymmetry

A. Impellizzeri¹, E. Serritella², A. Putrino², Vizzielli G³, A. Polimeni⁴, G. Galluccio⁵

¹ PhD Student, Doctoral School in innovative technologies in diseases of the skeleton, of the skin and of the oro-maxillofacial district. Department of Orthodontics, school of Dentistry. Specialist in Orthognatodontic, Department of Orthodontics. "Sapienza" University of Rome; ² PhD Student, Doctoral School in innovative technologies in diseases of the skeleton, of the skin and of the oro-maxillofacial district. Department of Orthodontics, school of Dentistry. Specialist in Orthognatodontic, Department of Orthodontics. "Sapienza" University of Rome; ³ Specialist in Orthognatodontic, Unit of Orthodontics. Department of Oral and Maxillofacial Sciences, "Sapienza" University of Rome, Private Doctor in Rome; ⁴ Professor and Director of Department of Oral and Maxillofacial Sciences, Umberto I Hospital, "Sapienza" University of Rome; ⁵ Associate Professor, Director of Post-Graduate Course in Functional Orthodontics, Vice-President of the Course for Dental Degree - Department of Oral and Maxillofacial Sciences, "Sapienza" University of Rome, Italy

Abstract

Objective. The aim of this study was to determine the relationship between the thickness of masticatory and cervical muscles (temporalis, masseter and sternocleidomastoid) and facial asymmetries in young patients.

Methods. 21 subjects were selected, through a detailed anamnesis and clinical examination, in order to assess the normality of oral tissues, the presence of normal occlusion, the absence of alteration in tooth dimensions and of congenital or developmental anomalies of lips, mouth or face.

Results. The present investigation showed that temporalis, masseter and sternocleidomastoid muscles in untreated and growing individuals with facial asymmetries are thinner on the contralateral side when compared with controlateral normal side, but in the untreated one this value is more statistically significantly.

Conclusion. In conclusion, the cervical muscle's thickness resulted increased in young patients. Ultrasound is beginning to be recognized to have potential use in dentistry as a safe, noninvasive, comfortable and cost-effective adjunct to diagnosis by producing high-resolution images more easily than magnetic resonance (MRI) and computed tomography (CT) (27-kubo). *Clin Ter* 2019; 170(4):e272-277. doi: 10.7417/CT.2019.2147

Key words: masticatory muscles, cervical muscles, thickness, ultrasonography, facial asymmetry

Introduction

Cranio-facial asymmetries are an heterogeneous group of dysgnathia that recognize a small part of a genetic basis (1); most often they are caused by acquired factors such as trauma or inflammation, but mostly by functional alterations.

The morpho-structural alterations may relate to the bones of the skull base, the maxillo-mandibular complex or both, and occur at dentoalveolar level in a more or less marked.

Intensive use of any skeletal muscle may cause changes in the muscle fiber size and composition, which in turn will increase the strength of the muscle and the resistance to fatigue (2).

This is also true of masticatory muscles (3). Prolonged high activity of these muscles resulted in increased ultrasonographic thickness of the masseter muscle (4) and increased maximal bite force values (5).

Thus, it could be expected that this prolonged bilateral difference in the activity level of the masticatory muscles may work as an asymmetric training stimulation, resulting in differences in these muscles thickness. However, the masticatory muscles are also involved in functions that are not necessarily related only to mastication, and thus it is unknown if the bilateral differences in the muscles activity level previously observed are enough to create detectable changes in the muscle thickness.

Some parameters of masticatory muscle function have been shown to correlate with facial morphology; these investigators have found that stronger and more active muscles are associated with a tendency to parallelism of the jaws and other features of short face syndrome (6). To describe facial morphology, the structure of the facial muscles should be investigated thoroughly to determine the pattern of interaction of the skeleton and muscles (7).

Several authors have determined the cross-sectional area and volumes of masticatory muscles with CT (8), and magnetic resonance imaging (MRI) (9-10).

Ultrasound is beginning to be recognized to have potential use in dentistry as a safe, noninvasive, comfortable and cost-effective adjunct to diagnosis by producing high-resolution images more easily than MRI images and CT (11). It has several advantages over CT and MRI, which makes it suitable for larger scale studies. In contrast to CT, ultrasonography has no cumulative biological effects; it is proven to be a reproducible, simple and inexpensive method for accurately measuring muscle thickness.

Correspondence: Impellizzeri Alessandra, Department of Oral and Maxillo-facial Sciences, "Sapienza" University of Rome, via Caserta 6, Rome, Italy. Telephone: +393209711872, Fax: 0961738012. E-mail address: ale.impellizzeri@gmail.com

The aim of this study was to determine the relationship between the thickness of masticatory and cervical muscles (temporalis, masseter and sternocleidomastoid) and facial asymmetries in young patients.

Materials and methods

A sample of 21 subjects, 7 males and 14 females, was selected, all patients attending an orthodontic treatment at Orthodontic Unit of the Department of Oral and Maxillo-facial Sciences of Sapienza University of Rome. The range age of the group was 9 to 14 years; the mean age was 12.1 years.

They were selected after a detailed anamnesis and clinical examination in order to assess the normality of oral tissues, the presence of normal occlusion, the absence of alteration in tooth dimensions and of congenital or developmental anomalies of lips, mouth or face.

All participants had natural and healthy dentitions and were free of dental and neuromuscular symptoms.

They were divided into two groups: treated group (group A) and control group (group B).

Treated group (group A): consisted of 12 subjects (8 female and 4 male), mean age of 12.8 years; the following selection criteria were used:

- patients with facial asymmetry treated with orthodontic appliances to correct the asymmetry;
- patients with facial asymmetry and unilateral crossbite, treated using quad-helix or expansion's appliance.

Control group (group B): consisted of 9 subjects (6 female and 3 male), mean age of 11.2 years; the following selection criteria were used:

- patients with facial asymmetry, who have never worn an orthodontic appliance;
- patients with facial asymmetry and unilateral crossbite never treated;
- facial dimensions were determined by standardized frontal photograph that were taken with the subjects stand up in front of a digital camera (Nikon Coolpix P600), teeth in maximal intercuspidal position and the Frankfort plane parallel to the floor;
- the planes and measurements (12-13) were hand traced as they are presented in Figures 1-2. The angle of the eye (AE) was determined between the mid-sagittal plane (vertical line formed by soft tissue nasion and soft tissue sub-nasal) and interpupillary line; the angle of the mouth (AM) was determined between the mid-sagittal plane and the commissure line.

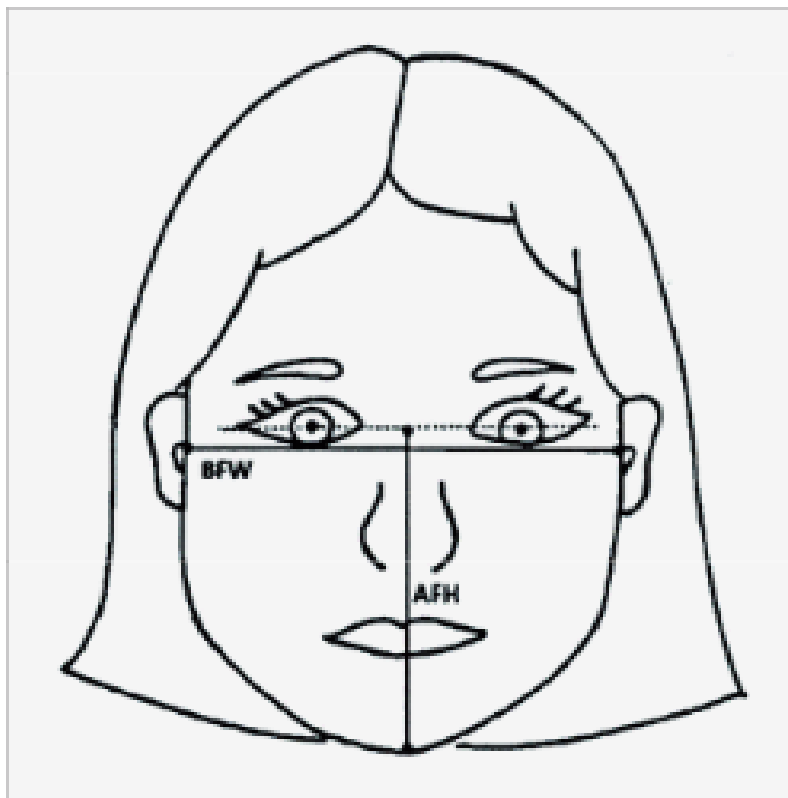


Fig 1. AFH: anterior face height (distance between the interpupillary plane and the inferior margin of the menton). BFW: bizygomatic facial width (distance between bilateral points marked at the outmost tip of the zygomatic arches).

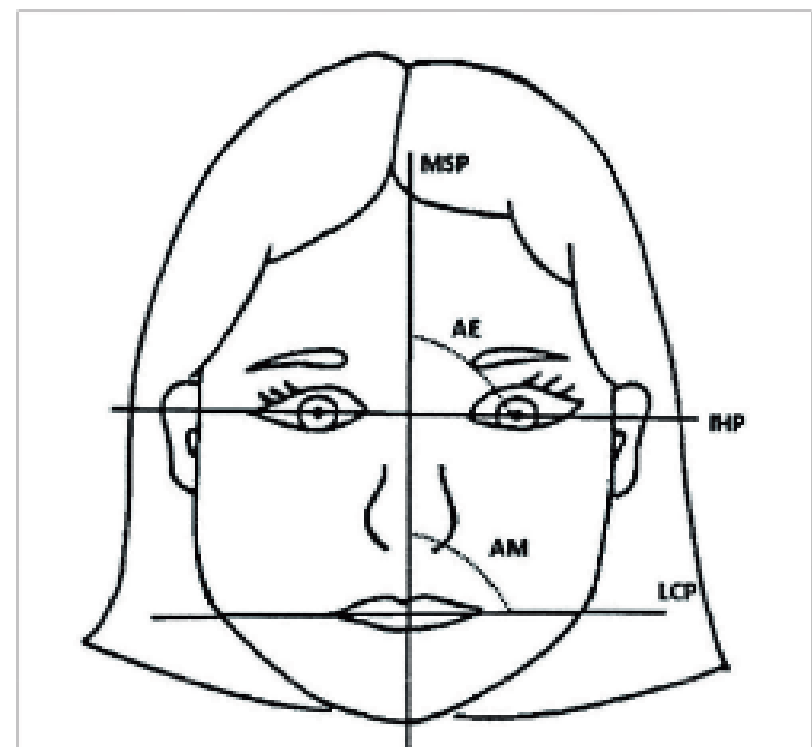


Fig 2. MSP: mid-sagittal plane (glabella-sub-nasal); IHP: interpupillary horizontal plane; LCP: labial commissure plane; AE: angle of the eye; AM: angle of mouth

All patients have been previously informed about the study its aims and the potential risks, we have been given an informed consent paper.

The ethical approval for this study was obtained from the Ethics Committee of Sapienza University of Rome (n°4663/2017).

Ultrasound procedure

Ultrasonographic investigation consisted of bilateral scanning of the anterior temporalis, anterior and deep masseter and sternocleidomastoid muscles (14). To recorder the data is necessary to have a darkened room with the patients placed in a supine position, with their heads turned sideways to provide good access for the probe. The subjects were instructed to maintain slight interocclusal contact and to avoid clenching. The orientation of the scan series was based on a standardized protocol to obtain cross section inter-setting the muscles parallel or perpendicular to their long axis (1). The anterior temporalis muscle was scanned at a 60-degree angle to the Frankfort Horizontal plane and about 1 cm cranially to the zygomatic arch. The anterior and deep masseter muscle scans were taken parallel to the occlusal plane and at a height just above the superior border of mandible.

The sternocleidomastoid muscle was scanned in a horizontal plane at a level halfway between the origin and insertion of the muscle.

When all images were captured, the sonographer made thickness measurement (Figure 3) from each image using the inherent electronic calipers of the machine (14).

Results

The Statistical analysis were performed using SPSS 17.0, and each group was separately analyzed. The independent t-test was used to compare differences of muscle's thickness between latero-deviation and controlateral side both in case group than in control group. For these analyses we have used different test, specifically: the **Mann-Whitney-Wilcoxon** was done to evaluate the variation of parameters

in latero-deviation patients. It is a nonparametric test of the null hypothesis that it is equally likely that a randomly selected value from one sample will be less than or greater than a randomly selected value from a second sample; the **Fisher's exact test** was done to evaluate the association between morphologic variation of sex, it is a statistical significance test used in the analysis of contingency tables; the **Chi-squared test** was used to determine whether there is a significant difference between the expected frequencies and the observed frequencies in Age variable. We have decided not to consider the decimal values, for the unsuccessful significance that they would have had at clinical, esteemed level the limit of measurements tied to the machine used for the surveying.

The table 1 showed the difference (Δ) (mean, median and range) between muscles' thickness on omolateral side of latero-deviation in both groups. It was found that the thickness of muscles on the latero-deviation side were statistically significantly thinner than muscles on the controlateral side:

- temporalis: $p = 0.012$
- masseter: $p = 0.03$
- sternocleidomastoid: $p = 0.023$

The difference (Δ) shows that this value is more statistically significantly in case control (treated group).

The table 2 showed the difference (Δ) (mean, median and range) between Thickness of temporal, masseter and sternocleidomastoid muscles on latero-deviation side and controlateral side. It was found that thickness of Temporal muscle on controlateral deviation side, Sterno-cleid muscle on latero-deviation side and Sterno-cleid muscle on controlateral deviation side were statistically significantly thinner than other muscles analyzed:

- temporalis controlateral deviation side: $p = 0.03$
- sternocleidomastoid on latero-deviation: $p = 0.004$
- sternocleidomastoid on controlateral deviation: $p = 0.01$

Discussion

The effects of muscle thickness on bone morphology can be explained by a theory which is recognized in the field of biodynamics as Wolff's law (15-16). This law points out that the internal structure and the shape of the bone is closely related to function and defines a relationship between bone shape and muscle function.

The present investigation has shown that temporalis, masseter and sternocleidomastoid muscles in untreated and growing individuals with facial asymmetries are thinner on the omolateral side when compared with controlateral normal side, but in the untreated one this value is more statistically significantly.

Ultrasonography of the masticatory and cervical muscles was found to be a quick and reproducible method to detect muscle thickness, meanwhile the operator follows a strict imaging protocol (17).

Ultrasound is beginning to be recognized to have potential use in dentistry as a safe, noninvasive, comfortable and cost-effective adjunct to diagnosis by producing high-resolution images more easily than MRI and CT (27-kubo).

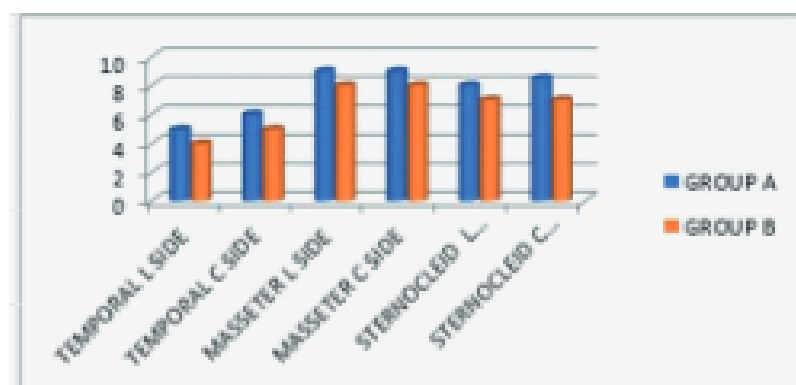


Fig. 3. Muscles' thickness on laterodeviation side and omolateral side in both groups.

Table 1. Δ The Difference between Case and Control group on thickness of Temporal, masseter and sternocleidomastoid muscle on omolateral side.

| Variable | Case Group (N) (%) | Control group (N) (%) | p value ^a | RR (95% CI) |
|---|----------------------|-----------------------|----------------------|-----------------------|
| Cases | 12 | 9 | | |
| Age (median)(range) (Chi test) | 13 (11-14) | 11 (9-14) | 0.06 ^c | |
| Gender Female Male (Fisher's exact test) | 8 (66.7) 4 (33.3) | 6 (66.7) 3 (33.3) | 1.0 ^f | 1.0 (0.1 – 6.2) |
| Laterodeviation Left Right (Mann-Whitney test) | 7 (58.3) 5 (41.7) | 5 (55.6) 4 (44.4) | 0.89 ^a | 1.12 (0.19 – 6.41) |
| T Test Student P value<0,005 | | | | |
| Δ Temporal muscle thickness on omolateral side (mm) (median)(range) | 0 (0-1) | 1 (0-2) | 0.012 ^d | n.a. ^g |
| Δ Masseter muscle thickness on omolateral side (mm) (median)(range) | 0 (0-1) | 1 (0-2) | 0.003 ^d | n.a. ^g |
| Δ Sternocleidomastoid muscle thickness on omolateral side (mm) (median)(range) | 0 (0-1) | 1 (0-2) | 0.023 ^d | n.a. ^g |

^a = P value < 0.005. Mann-Whitney test (^a), Fisher's exact test (^f), chi-square test(^c), T the Student (^d) analysis was performed where occurred. ^gn.a.: not applicable RR: Risk Ratio. CI: Confidence Interval. Statistically significantly results are shown as bold numbers.

Table 2. Thickness of temporal, masseter and sternocleidomastoid muscles on latero-deviation side and controlateral side.

| Variable | Case Group (N) (%) | Control group (N) (%) | p value ^a | RR (95% CI) |
|---|----------------------|-----------------------|----------------------|-----------------------|
| Cases | 12 | 9 | | |
| Age (median)(range) (Chi test) | 13 (11-14) | 11 (9-14) | 0.06 ^c | |
| Gender Female Male (Fisher's exact test) | 8 (66.7) 4 (33.3) | 6 (66.7) 3 (33.3) | 1.0 ^f | 1.0 (0.1 – 6.2) |
| Latero-deviation Left Right (Mann-Whitney test) | 7 (58.3) 5 (41.7) | 5 (55.6) 4 (44.4) | 0.89 ^a | 1.12 (0.19 – 6.41) |
| T Test Student P value<0,005 | | | | |
| Temporal muscle thickness on latero-deviation side (mm) (median)(range) | 5.0 (5-6) | 4.0 (4-6) | 0.06 ^d | |
| Temporal muscle thickness on controlateral deviation side (mm) (median)(range) | 6.0 (5-6) | 5.0 (4-6) | 0.03 ^d | |
| Masseter muscle thickness on latero-deviation side (mm) (median)(range) | 9.0 (8-10) | 8.0 (7-10) | 0.12 ^d | |
| Masseter muscle thickness on controlateral deviation side (mm) (median)(range) | 9.0 (8-11) | 8.0 (8-10) | 0.38 ^d | |
| Sternocleidomastoid muscle thickness on latero-deviation side (mm) (median)(range) | 8.0 (7-9) | 7.0 (6-9) | 0.004 ^d | |
| Sternocleidomastoid muscle thickness on controlateral deviation side (mm) (median)(range) | 8.5 (7-9) | 7.0 (6-9) | 0.01 ^d | |

^a = Mann-Whitney test (^a), Fisher's exact test (^f), chi-square test(^c), T the Student (^d) analysis was performed where occurred. RR: Risk Ratio. CI: Confidence Interval. Statistically significantly results are shown as bold numbers.

In literature, some studies treated the association between Unilateral Posterior Cross Bite (UPCB) and masticatory muscle thickness, half of them reporting a significant association and half of them not (18). Indeed, Kiliaridis et al. (19) reported that in UPCB subjects the thickness of the masseter muscle was significantly thinner on the crossbite side, with no significant differences in the non-crossbite group. Castelo et al. reported in a study (20) that bite force and temporalis muscle thickness increased significantly in children after early treatment of functional crossbite; in another study (21) reported that children with crossbite presented greater facial asymmetry than those with normal occlusion, and a greater masseter thickness was related to larger faces in the mixed dentition. On the other hand, Andrade et al. (22) found no differences either between sides or between UPCB and no-UPCB groups. Interestingly, the opposite findings were reported by the same authors in different studies in a three-year time lapse. This could be ascribed to the different sample size of the studies. Hence, no conclusions can currently be drawn on UPCB and muscle thickness.

The study has some limitations. It was not possible to identify all facial muscles, but this is also true for computed tomography and magnetic resonance imaging (23). An important confounding factor could be ascribed to the lack of validity of the methods used to assess skeletal asymmetry (24). Indeed, for this study we have used an ultrasonography machine that have the limitation due to caliper's diameter and to an unequal magnification of right-left sides in the horizontal dimension if the mid-sagittal plane of the patient's head is not good positioned. Furthermore, using standardized section planes is important to allow for standardization of the procedure, but this limits the exploration to a group of very thin muscle fibers around the eye and the mouth. This limitation may be overcome in the future by 3-dimensional ultrasound (25-27). The pressure of the transducer on the skin may lead to a major difference in muscle thickness measurements, especially in small muscles, such as those of the face. The investigators were instructed to not exert probe pressure on the skin, but no objective method was used to control and maintain consistency of pressure between measurements. All studies analyzed children/adolescents, we have no information available on adults on this topic.

Conclusion

The results showed a significant association between facial asymmetries and masticatory and cervical muscles, in fact, in individuals untreated there are muscles thinner in the latero-deviation side than in the contralateral normal side. This study has used simple ultrasound technique to investigate possible relationship with facial asymmetries and facial and neck muscles. Future work should optimize accuracy and reduce error in ultrasound measurements. Currently, the use of ultrasound for mainstream orthodontic treatment planning is unproven but holds great promise for the future. This study of gender - and age - specific data sets of masticatory cervical muscles in healthy young people has demonstrated that ultrasound is a method that meets high standards for reliable quantitative examination of muscle

size and the confront between right and left side muscles, in presence of facial asymmetries. For future research, it is suggested that the sample size is increased so that it gives a better representation of the population. In addition, because ultrasonography is a non-invasive and easily accessible technique that gives no radiation exposure, it is a promising method for monitoring facial asymmetries progression and evaluating treatment effects.

References

- Schmid W, Deregibus A, Mongini F. Conservative treatment of craniomandibular asymmetries during growth. A long term study. *Prog. Orthod* 2007; 8(1):62-73
- Kiliaridis S, Payam H, Maarten C, et al. Ultrasonographic thickness of the masseter muscle in growing Individuals with unilateral crossbite. *Angle Orthod* 2007; 77:607-11
- Sullivan JD, Olha AE, Rohan I, et al. The properties of skeletal muscle. *Orthop Rev* 1996; 15:349-63
- Georgiakaki I, Kiliaridis S. Intensive chewing and chewing training on masseter muscle thickness. *J Dent Res* 1988; 77:10-18
- Kiliaridis S, Carlsson GE. Effect of fatigue and chewing training on maximal bite force and endurance. *Am J Orthod Dentofacial Orthop* 1995; 107:372-8
- Philip C, Benington, Gardener JE, et al. Masseter muscle volume measured using ultrasonography and its relationship with facial morphology. *Eur J Orthod* 1999; 21:659-70
- Fikret S, Tulin A, Fulya I. Comparative data on facial morphology and muscle thickness using ultrasonography. *Eur J Orthod* 2005; 27:562-7
- Weijjs WA, Hillen B. Correlation between the cross-sectional area of the jaw muscles and craniofacial size and shape. *Am J Phys Antropol*, 1986; 70:423-31
- Hannam AG, Wood WW. Relationship between the size and spatial morphology of human masseter and medial pterygoid muscles, the craniofacial skeleton, and the jaw biomechanics. *Am J Phys Antropol* 1989; 80:429-45
- Van Spronsen PH, Weijjs WA, Prah-Andersen B, et al. Relationship between jaw muscle cross-section and craniofacial morphology in normal adults, studied with magnetic resonance imaging. *Eur J Orthod* 1991; 13:351-61
- Kubo K, Kawata T, Ogawa T, et al. Outer shape changes of human masseter with contraction by ultrasound morphometry. *Arch Oral Biol* 2006 Feb;51(2):146-153. Epub 2005 Aug 10
- Ferrario VF, Sforza C, Miani A, et al. Craniofacial morphometry by photographic evaluation. *Am J Orthod Dentofacial Orthop* 1993; 103:327-37
- Pompei VTM, Carvalho AS, Cunha FL. Evaluation of face asymmetry in individuals with posterior crossbite trough frontal photographs. *Orthodontia*. 2005; 38:337-44
- Emshoff R, Bertram S, Strobl H. Ultrasonographic cross-sectional characteristics of muscles of the head and neck. *Oral Surg, Oral Med, Oral Path, Oral Radiol, and Endod.* 1999; 87(1):93-106
- Michelotti A, Farella M, Gallo LM, et al. Effect of occlusal interference on habitual activity of human masseter. *J Dent Res* 2005; 84:644-8
- He T, Olsson S, Dangaard JR, et al. Functional influence of masticatory muscles on the fibres characteristics and capil-

- lary distribution in growing patients. *Arch Oral Biol* 2004; 49:983-9
17. Fikret S, Tulin A, Fulya I. Comparative data on facial morphology and muscle thickness using ultrasonography. *Eur J Orthod* 2005; 27(6):562-7
 18. Iodice G, Danzi G, Cimino R, et al. Association between posterior crossbite, skeletal, and muscle asymmetry: a systematic review *Eur Jour of Orth*, 2016; 38(6):638-51
 19. Kiliaridis S, Mahboubi P.H, Raadsheer M.C. and Katsaros C. Ultrasonographic thickness of the masseter muscle in growing individuals with unilateral crossbite. *The Angle Orthodontist* 2007; 77: 607-11
 20. Castelo PM, Gavião MB, Pereira LJ, et al. Evaluation of changes in muscle thickness, bite force and facial asymmetry during early treatment of functional posterior crossbite. *J Clin Pediatr Dent* 2010; 34(4):369-74
 21. Castelo PM, Pereira LJ, Andrade AS, et al. Evaluation of facial asymmetry and masticatory muscle thickness in children with normal occlusion and functional posterior crossbite. *Minerva Stomatol.* 2010; 59(7-8):423-30
 22. Andrade Ada S, Gameiro GH, Derossi M, et al. Posterior crossbite and functional changes. A systematic review. *The Angle Orthodontist* 2009; 79:380-6
 23. Emery L, Hess TM. Cognitive consequences of expressive regulation in older adults. *Psychol Aging* 2011; 26:388-96
 24. Volk GF1, Sauer M, Pohlmann M, et al. Reference values for dynamic facial muscle ultrasonography in adults. *Muscle Nerve.* 2014; 50(3):348-57
 25. Kaylie DM, Wax MK, Weissman JL. Preoperative facial muscle imaging predicts final facial function after facial nerve grafting. *Am J Neuroradiol* 2003; 24:326-30
 26. Pooj RK. Normal anatomy by three-dimensional ultrasound in the second and third trimesters. *Sem Fetal Neonatal Med* 2012; 17:269-77
 27. Alias A, Ibrahim A, Abu Bakar SN, et al. Anthropometric analysis of mandible: an important step for sex determination. *Clin Ter* 2018; 169(5):e217-e23