

Ultrasound of verrucous hyperplasia of the skin related to venous stasis and effects of compression treatment

Alberto Caggiati, MD, PhD, Rome, Italy

ABSTRACT

Verrucous hyperplasia of the skin rarely occurs in legs with severe venous stasis. In these cases, ultrasound demonstrated thickening and hyperechogenicity of the skin layers. The core of the verrucous-like protrusions consisted of a fibrous lump of the reticular dermis, surrounded by an anechogenic layer and covered by a thickened epidermal shell. Compression treatment provokes the progressive disappearance of the dermal plications, accompanied by reduction of the cutaneous and subcutaneous edema and infiltration. Ultrasound easily demonstrates the histologic changes of verrucous hyperplasia of the skin and allows evaluation of the evolution of the disease and the efficacy of treatments. (*J Vasc Surg Cases and Innovative Techniques* 2019;5:225-7.)

Keywords: Skin ultrasound; Verrucous skin hyperplasia; Venous stasis; Compression treatment

Verrucous hyperplasia of the skin (VHS) is currently considered pathognomonic for severe lymphatic stasis and belongs to the signs characterizing the third stage of lymphedema¹ (synonyms: lymphostatic verrucosis, lymphedematous keratoderma, lymphatic papillomatosis, verrucous elephantiasis, elephantiasis nostras verruciformis).²

Actually, VHS may occur in legs with no history of diseases or treatments damaging lymph vessels and nodes. In particular, VHS was described in patients with congestive heart failure (CHF), in obese patients, and in limbs with post-thrombotic syndrome (PTS).^{3,4}

The purpose of this article was to describe ultrasound findings from the skin of legs affected by VHS unrelated to lymphatic diseases. The effects of compression treatment on skin morphology are also described.

CASE REPORT

From May 2016 to April 2018, three patients seeking advice at the vein clinic showed VHS. VHS affected both legs in two patients suffering from CHF, renal insufficiency, and obesity (G.L., an 84-year-old bedridden woman; and N.T., a 77-year-old sedentary man). Unilateral VHS was present in the right leg of R.C., a 55-year-old man suffering from ipsilateral PTS. All these patients reported a history of chronic skin changes (>5 years in G.L. and N.T.; >2 years in R.C.) with episodes of acute skin inflammation.

Besides the usual therapy for the comorbidities, local treatment of the limbs with VHS consisted of two-layer bandaging:

From the Department of Anatomy, Sapienza University of Rome.

Author conflict of interest: none.

Correspondence: Alberto Caggiati, MD, PhD, Department of Anatomy, Sapienza University, Via Borelli 50, 00161 Rome, Italy (e-mail: alberto.caggiati@uniroma1.it).

The editors and reviewers of this article have no relevant financial relationships to disclose per the Journal policy that requires reviewers to decline review of any manuscript for which they may have a conflict of interest.

2468-4287

© 2019 The Author. Published by Elsevier Inc. on behalf of Society for Vascular Surgery. This is an open access article under the CC BY-NC-ND license (<http://creativecommons.org/licenses/by-nc-nd/4.0/>).

<https://doi.org/10.1016/j.jvscit.2019.01.003>

the skin was protected by gauze impregnated with a creamy mixture of zinc oxide overlapped by a self-adhesive inelastic dressing. Bandaging was repeated each week and finally substituted with class 2 elastic stockings.

The structure of the skin was evaluated by ultrasound with a high-frequency probe (8-14 MHz) as previously described.⁵

Clinical findings. The legs affected by VHS were swollen, with evident chronic inflammation of the skin. The skin was thickened and hyperkeratotic, showing a cobblestone-like verrucous appearance with a profuse papillomatous growth causing large warty protrusions (Figs 1 and 2). Thin skin fissures could be seen at the base of the verrucous formations (Fig 1, A).

Compression treatment during 6 weeks resulted in progressive reduction of the height of the verrucous protrusions, skin inflammation, and leg edema (Fig 2, B-D).

Ultrasound findings. Ultrasound demonstrated thickening of the epidermis and dermis with plications of variable size and shape (Figs 1, B and 2, E). The papillary dermis was edematous with disappearance of the dermal papillae, whereas the reticular dermis was thickened and hyperechogenic.⁶ The subcutaneous layer was thickened and diffusely hyperechogenic. The core of the verrucous-like protrusions consisted of a fibrous lump of the reticular dermis, surrounded by an anechogenic layer corresponding to the papillary dermis and covered by a thickened epidermal shell.

Compression treatment resulted in progressive disappearance of the dermal hyperplastic plications accompanied by reduction of the dermal and subcutaneous thickness (Table) and infiltration (Fig 2, F-H).

All patients gave their informed consent, which was previously approved by the Institutional Ethics Committee, to publish this report.

DISCUSSION

Verrucous-like skin changes are considered pathognomonic for severe primary or secondary lymphedema. In turn, similar skin changes may also occur in patients without history of lymphatic disorders.

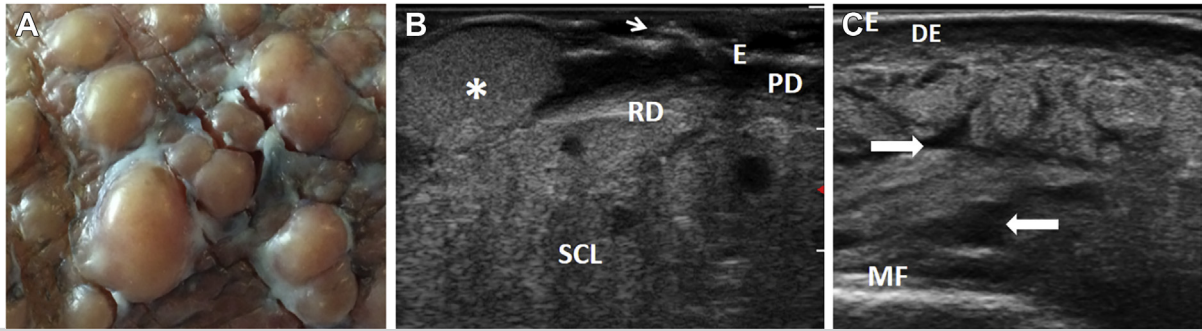


Fig 1. Patient G.L., 84 years old. **A**, The cobblestone-like appearance of verrucous hyperplasia of the skin (VHS). Note the thin skin fissures. **B**, The corresponding ultrasound appearance. The epidermis (*E*) is discontinuous (*arrow*). The papillary dermis (*PD*) is thickened and edematous. Reticular dermis (*RD*) proliferations (*) are the core of the verrucous-like projections. The subcutaneous layer (*SCL*) is hyperechogenic because of inflammatory infiltration. **C**, Ultrasound appearance of skin not affected with verrucous projections. Note the regular epidermal profile (*E*), marked dermal edema (*DE*), widened lymphatic clefts, and suprafascial fluid accumulation (*arrows*). *MF*, Muscular fascia.

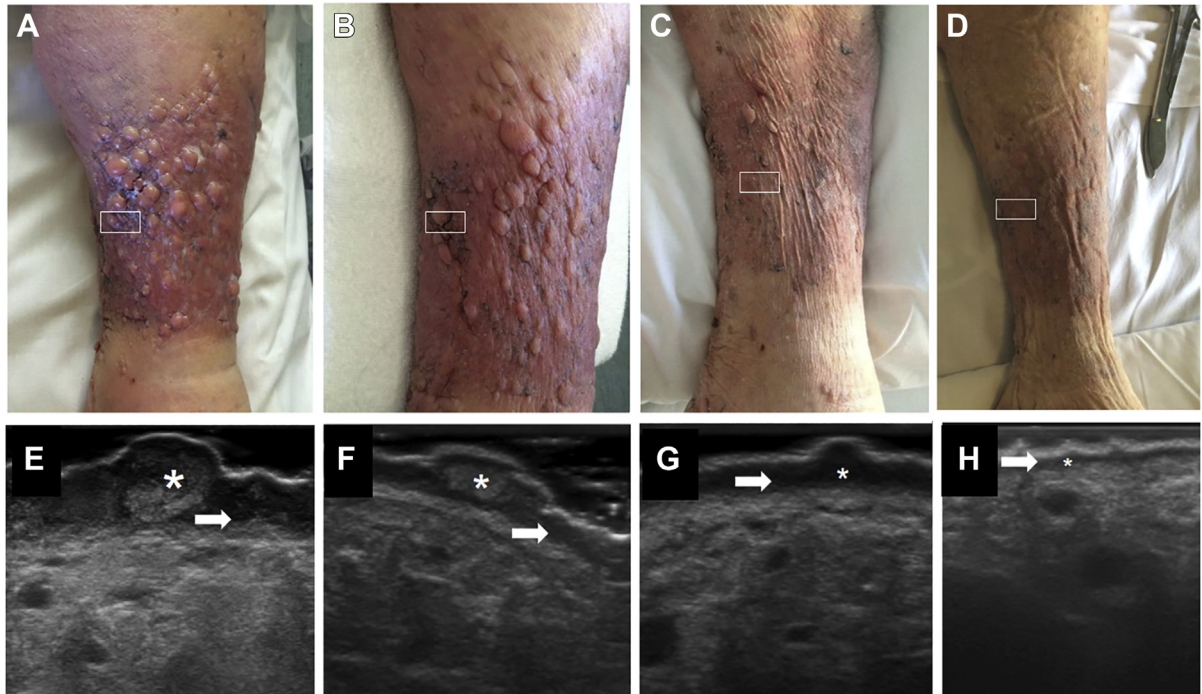


Fig 2. Patient G.L., 84 years old. Verrucous hyperplasia of the skin (VHS) clinical (**A-D**) and ultrasound (**E-H**) changes related to compression. The areas displayed by ultrasound are marked. Before treatment (**A** and **E**) and after 2 weeks (**B** and **F**), 4 weeks (**C** and **G**), and 6 weeks (**D** and **H**) of compression treatment. Compression induces a progressive reduction of the papillary dermis edema (*arrows*) and of fibrous proliferation of the reticular layer (*).

VHS is an uncommon cutaneous complication in legs with chronic inflammation of the skin due to severe impairment of venous return. It usually affects both legs when venous stasis is due to CHF, obesity, prolonged leg immobility, or dependency and, frequently, a combination of them.³ Unilateral VHS may occur in limbs with PTS.⁷ Significantly, venous stasis alone cannot produce the fibrotic nodular lesions of VHS.⁶ Multiple episodes of erysipelas seem to be responsible for the chronic

inflammatory edema and dermal fibrous hyperplasia typical of VHS.⁸

Ultrasound findings correspond to the histologic description of the skin changes typical of VHS⁷: pseudoe-pitheliomatous hyperplasia, marked dermal edema and fibrosis, and chronic inflammatory infiltrate of the subcutaneous layer. Moreover, ultrasound allows evaluation of the evolution of the disease and the potential effects of treatments.

Table. Thickness (mm) of the dermoepidermal complex (DE) and subcutaneous layer (SCL) before (Pre) and after (Post) compression treatment

Patient	DE		SCL	
	Pre	Post	Pre	Post
G.L.	13	4	28	13.2
N.T.	9	3.5	27.5	12
R.C.	15	8	41.7	23

In legs affected with lymphedema, papillomatous skin protrusions are considered irreversible changes⁷ and surgery their only possible treatment.⁸ On the contrary, in legs with verrucous skin changes related to venous stasis, compression seems to easily reduce skin inflammation and edema as well as the related dermal hyperplasia responsible for the verrucous appearance of the skin.

REFERENCES

1. Executive Committee. The Diagnosis and Treatment of Peripheral Lymphedema: 2016 Consensus Document of the

International Society of Lymphology. *Lymphology* 2016;49:170-84.

2. Sisto K, Khachemoune A. Elephantiasis nostras verrucosa: a review. *Am J Clin Dermatol* 2006;9:141-5.
3. Baird D, Bode D, Akers T, DeYoung Z. Elephantiasis nostras verrucosa (ENV): a complication of congestive heart failure and obesity. *J Am Board Fam Med* 2010;23:413-41.
4. Freitas A, Rodrigues JF. Elephantiasis nostras verrucosa secondary to recurrent erysipelas. *BMJ Case Rep* 2017;2017:bcr-2017-221014.
5. Caggiati A. Ultrasonography of skin changes in legs with chronic venous diseases. *Eur J Vasc Endovasc Surg* 2016;52:534-42.
6. Suehiro K, Morikage N, Murakami M, Yamashita O, Samura M, Hamano K. Significance of ultrasound examination of skin and subcutaneous tissue in secondary lower extremity lymphedema. *Ann Vasc Dis* 2013;6:180-8.
7. Yang YS, Ahn JJ, Haw S, Shin MK, Haw CR. A case of elephantiasis nostras verrucosa. *Ann Dermatol* 2009;21:326-9.
8. Pitcher AA, Pagan CA, Small K, Otterburn DM. Excision of elephantiasis nostras verrucosa lesions in a patient with hereditary lymphedema: case report and review of the literature. *J Foot Ankle Surg* 2015;54:747-50.

Submitted Sep 19, 2018; accepted Jan 8, 2019.