

Ultrasonography for oxygen-ozone therapy in musculoskeletal diseases

Eleonora Latini*, Enrico Roberto Curci, Andrea Massimiani, Sveva Maria Nusca, Flavia Santoboni, Donatella Trischitta, Mario Vetrano, Maria Chiara Vulpiani

Unit of Physical Medicine and Rehabilitation, Sant'Andrea Hospital, "Sapienza" University of Rome, Rome, Italy

*Correspondence to: Eleonora Latini, MD, eleonora_gib@yahoo.it.
orcid: 0000-0003-0032-215X (Eleonora Latini)

Abstract

Over the years, infiltrative oxygen-ozone therapy has shown clinical benefits in several musculoskeletal disorders, due to its potential analgesic, anti-inflammatory, antioxidant and immunomodulatory effect. Ultrasonography is a safe, non-invasive imaging, easily available, and has the additional advantage of being real time for imaging and image-guided procedures of the musculoskeletal system. This review explains the numerous promising ways in which ultrasonography can be useful in oxygen-ozone therapeutic practices for musculoskeletal disorders, in order to improve safety and accuracy of treatment.

Key words: ozone; ultrasound; oxygen-ozone therapy; musculoskeletal diseases; ultrasonography; paravertebral injection; peritendinous zone; intraarticular ozone

doi: 10.4103/2045-9912.254638

How to cite this article: Latini E, Curci ER, Massimiani A, Nusca SM, Santoboni F, Trischitta D, Vetrano M, Vulpiani MC. Ultrasonography for oxygen-ozone therapy in musculoskeletal diseases. *Med Gas Res.* 2019;9(1):18-23.

INTRODUCTION

Oxygen-ozone therapy

The oxygen-ozone (O_2-O_3) therapy is based on the application of a mixture of 5% O_3 and 95% of medical O_2 . O_3 is a colorless natural gas with a characteristic odor; it is composed of three oxygen atoms. Its high reactivity gives it a short half-life (in gaseous form at 20°C, its half-life is 3 days, while in liquid form, its half-life is 20 minutes). This means that it cannot be stored but must be produced just before use. It can be produced artificially by subjecting diatomic oxygen to a high-voltage electrical discharge, through the endothermic reaction $3O_2 \rightarrow 2O_3$. In literature,¹⁻⁵ the followings are widely described, what O_3 is, how it acts, how its toxicity can be controlled, the route of administration, the behaviour and fate of the O_3 messengers (reactive oxygen species, and lipid oxidative products) after coming into contact with body fluids, and the therapeutic effects of O_3 . Probable mechanism of action of the O_2-O_3 mixture may be found in the biochemical properties of O_3 , including an analgesic, anti-inflammatory, antioxidant effects and an immunomodulatory action.⁶ These are performed by: (i) activating the cellular metabolism, (ii) reducing proinflammatory prostaglandins synthesis or the release of algogenic compounds, (iii) increasing release of immunosuppressor cytokines, (iv) reducing oxidative stress through induction of the synthesis of antioxidant enzymes (superoxide dismutase, glutathione peroxidase, and catalase) and, in addition, (v) amelioration of the tissue O_2 supply through hemoreologic action, vasodilatation, and angiogenesis stimulation.^{6,7} This effects are the basis of O_3 clinical effectiveness.

In particular, the therapeutic efficacy of O_2-O_3 therapy is due to the controlled and moderate oxidative stress produced by the reactions of O_3 with several biological components. Calculated and transitory O_3 -induced oxidative stress generates a number of second messengers in various intracellular sig-

nalling pathways. These are capable to induce an antioxidant response through activation of nuclear transcriptional factors and upregulation of the antioxidant enzymes. O_3 acts as a hormetic prodrug,⁵ on the basis of phenomenon that says "the exposure of an organism to a low level of an agent, harmful at high levels, induces an adaptive and beneficial response".⁸ Effectiveness and toxicity of O_3 depend on the intensity of the oxidative stress. At the appropriate dose, O_3 paradoxically upregulates the antioxidant defences and is capable of reversing a chronic oxidative stress.⁵

O_2-O_3 therapy is widely used in the field of musculoskeletal disorders, mainly to the treatment of vertebral column diseases (intervertebral disc protrusion or herniation, failed back surgery syndrome), osteoarthritis (degenerative or inflammatory), and several other joint-tendinitis affections.⁹⁻¹⁰ O_2-O_3 mixture has different routes of administration. In spinal disorder an indirect technique can be used by injecting the gas into the points localizable in the paravertebral muscle corresponding to the metamer of the herniated disc. This approach can be defined as the indirect approach. Alternatively a intradiscal injection of ozone at the level of the pathologic intersomatic space under radioscopic control can be performed. This approach can be defined as the direct approach. In osteoarthritis O_2-O_3 mixture is administered *via* intra-articular and periarticular injections. In tendinopathies O_2-O_3 mixture is administered *via* peritendinous injections.¹¹ The contraindications to the use of O_2-O_3 therapy are some patient conditions such as pregnancy, glucose-6-phosphate dehydrogenase deficiency (favism), uncontrolled hyperthyroidism, severe cardiovascular diseases and heart failure.¹¹ The adverse effects of O_2-O_3 therapy can be distinguished from those of the O_2-O_3 mixture and the administration technique. The feeling of heaviness or burning at the injection site is first documented until a vagal crisis. The side effects based on the technique of administration are: hematoma due to injury to blood vessels, pain, and

local infection due to a non-sterile procedure. However, these events are rare and can be avoided with good procedures.¹²

Ultrasonography

Musculoskeletal ultrasound is a non-invasive, rapid, safe, relatively inexpensive imaging modality, emits no ionizing radiation, and can be performed in the outpatient clinical setting.¹³ It is capable of providing real-time dynamic tissue assessment,¹⁴ allowing exploration of the musculoskeletal system, and it is ideally suited for image-guided interventions. The basis of image-guided intervention is the ability to identify the region to be injected (target), confirm placement of the needle at the appropriate location thereby minimizing risks of injury to adjacent structures,¹⁵ and ensure correct localization of therapeutic agent. Recently, an increasing number of physicians have integrated musculoskeletal ultrasound into their clinical practices to ensure patient care.¹⁶ This review provides a brief overview of the potential use of ultrasonography in the treatment of musculoskeletal diseases with O_2-O_3 , in order to facilitate the performance of safe and precise interventions.

ULTRASONOGRAPHY AS A PRE-PROCEDURE ASSESSMENT BEFORE THE PARAVERTEBRAL INFILTRATION

Intramuscular paravertebral injection of O_2-O_3 mixture is a technique used frequently in clinical practice to treat spinal diseases. It has been also defined as “chemical acupuncture” because both the needle and gas injection have a role in eliciting a complex series of chemical and neurological reactions leading to the disappearance of pain in the majority (positive responses in 70–80% of cases) of patients with low spinal pain.¹⁷ The intramuscular injection is administered in the paravertebral muscles corresponding to the metamer of each vertebral segment affected. For each treatment session, one or several (up to four) symmetrical injections of 5–10 mL of O_2-O_3 gaseous mixture (15–20 $\mu\text{g/mL}$ concentration) for site were performed, *via* an extraspinal lateral approach.¹⁷ Currently, needles are available in a wide range of lengths and gauges: for paravertebral injections gauge (from G22 to G25 in lumbar region, and G25 to G30 in cervical region) and length changes according to the patient body size. Under sterile conditions, medical O_2-O_3 mixture is injected at a distance of 2 cm laterally from spinous processes in the paravertebral muscles, making sure not to be inside a blood vessel. The gaseous mixture should be introduced very slowly in order to avoid pain and promote homogeneous distribution of the gas through the muscle fibers.¹¹ Usually, the O_2-O_3 infiltrations are performed using an aseptic free-hand approach after the individuation of surface anatomical landmarks. In lumbar region, the L3–4 intervertebral level can be estimated from the intercrystal line as the imaginary horizontal line across the top of the iliac crests.¹⁸ The spinous process of L4 is identified by palpating as a large and sagittally ridged eminence,¹⁹ while the spinous process of L5 is described as a deep, small bony point, identified caudally from L4.²⁰ In the cervical region, the spinous process of C7 (vertebra prominens) can be easily recognized at palpation. Other anatomical landmarks are the inferior tip of the mastoid process, situated just superiorly and

laterally to the transverses processes of C1 and the superior border of the thyroid cartilage corresponds to C4.²¹

Ultrasonography can be used to integrate the landmark-guided approach to improve accuracy and safety of the treatment. Ultrasonography allows a detailed pre-procedural examination of the area of interest, identifying and characterizing the various anatomical structures of the cervical and lumbar spine. An ultrasound examination of the spine can be performed combining a sagittal and a transverse scan with the patient in the sitting or prone position. A sagittal scan can be performed through the midline (median sagittal scan) or through a paramedian (paramedian sagittal scan) plane.²² For lumbar spine examination a paramedian oblique sagittal scan is performed to identify and mark the intervertebral level, while a transverse scan to evaluate the medial paravertebral muscles, injection site with O_2-O_3 mixture. In the paramedian oblique sagittal scan, the probe is placed approximately 2 cm lateral to the midline in the sagittal axis and it is tilted softly medially toward the midline. In this view, the sacrum is identified as a flat hyperechoic structure with a large acoustic shadow anteriorly. Sliding the transducer in a cranial direction, the gap between the line of the sacrum and the lamina of the L5 vertebra (with its typical sonographic “sawtooth” appearance) represents the L5–S1 interlaminar space (**Figure 1**).

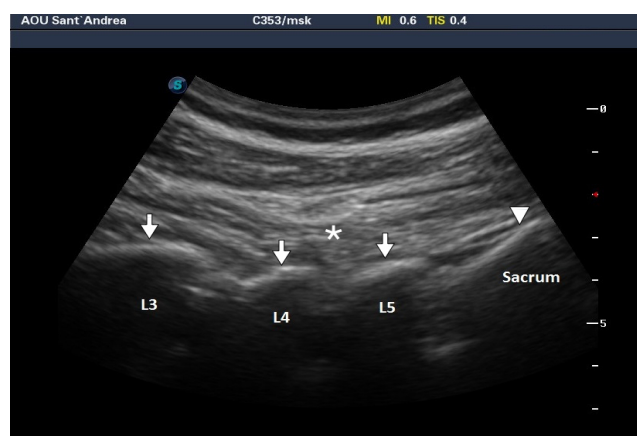


Figure 1: Paramedian sagittal oblique view.

Note: The sacrum (arrowhead) is recognizable as a horizontal hyperechoic curvilinear structure, the L3–5 laminae (arrows) have the typical “sawtooth” appearance, and the erector spinae muscles (asterisk) are hypoechoic and lie superficial to the laminae. The images were obtained by means of a Sonoscape P50 Ultrasound (Sonoscape Europe s.r.l., Rome, Italy). The O_2-O_3 mixture was produced by means of a Multiossigen Medical 991R generator (Multiossigen S.p.A., Gorle, Bergamo, Italy).

The successive lumbar interlaminar spaces, corresponding to the intervertebral spaces (from L5/S1 to L1/L2), can be determined by counting upward from the lumbosacral junction. To improve the accuracy of ultrasound to identify intervertebral space can combine a counting-up approach from the L5–S1 junction with a “counting-down” approach from T12, identified by its articulation with the twelfth rib.²² This combined approach is helpful in patients with anomalies of the lumbosacral junction as sacralization of the L5 vertebra, or less commonly, lumbarization of the S1 vertebra, which occurs approximately in 12% of the general population.²³ By placing

each interlaminar space in the centre of the ultrasound screen, its position can be marked on the skin at the midpoint of the long axis of the probe. This prevents misidentification of the level during later scanning in the transverse plane.

Once the examination in the parasagittal oblique scan is completed, the transducer is rotated 90° into a transverse orientation and is positioned with the centre of the probe over the spinous process (transverse spinous process view). In this view, the tip of the spinous process is visible as a superficial hyperechoic line with vertical linear acoustic shadowing beneath, while at either side of the base of the spinous process the laminae appear as bright white horizontal landmarks. Lateral to the spinous process and upon the laminae the erector spinae muscle can be visualized (**Figure 2**).

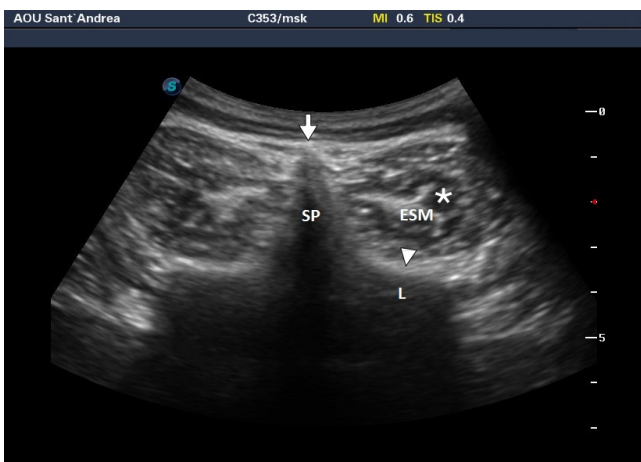


Figure 2: Transverse spinous process view, when the transducer is positioned directly over the spinous process.

Note: The acoustic shadow of the spinous process (arrow) and of the lamina (arrowhead). Erector spinae muscle (asterisk) is easily visualized. SP: Spinous process; L: lamina; ESM: erector spinae muscle. The images were obtained by means of a Sonoscape P50 Ultrasound (Sonoscape Europe s.r.l., Rome, Italy). The O₂-O₃ mixture was produced by means of a Multiossigen Medical 99IR generator (Multiossigen S.p.A., Gorle, Bergamo, Italy).

For cervical spine examination a median sagittal scan and a transverse scan are performed. In the median sagittal scan, the transducer is applied over the midline to obtain a long axis view of the spine. In this view, the C1 vertebra is visualized immediately caudal to the occiput and has a rudimentary spinous process or not, while C2 vertebra shows the first real spinous process (**Figure 3**). Moving the transducer caudally, the other spinous processes are identified up to C7, known as vertebra prominens.

Once the median sagittal scan and the identification of the correct cervical level has been performed, the transducer is rotated 90° into a transverse orientation and is positioned with the centre of the probe over the spinous process (transverse spinous process view). In this view, the bifid spinous processes of C2-6 vertebra (**Figure 4**) and the large and unique process at C7 level (vertebra prominens) can be visualized by moving the probe caudally.

Once the cervical or lumbar vertebral level to treat in trasversal axis is identified, the transducer is then moved laterally to each side to visualize the left and right paravertebral muscles. These are bordered medially by the spinous process

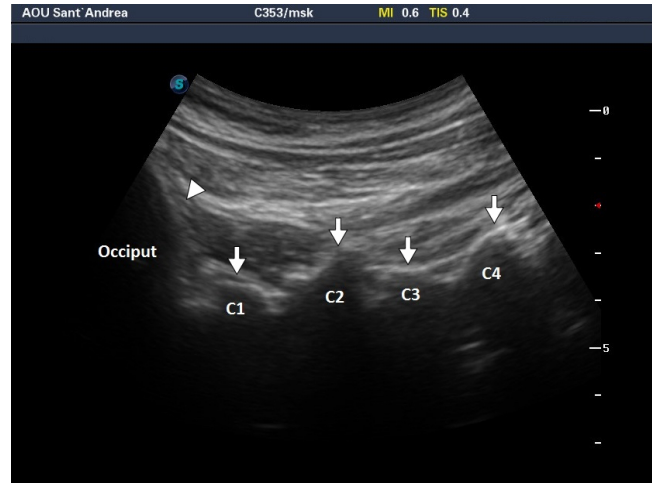


Figure 3: Midline sagittal spinous process view, when the transducer is positioned directly over the midline.

Note: The occiput (arrowhead), spinous process of C1 (rudimentary)-C2-C3-C4 (arrows) can be easily identified. The images were obtained by means of a Sonoscape P50 Ultrasound (Sonoscape Europe s.r.l., Rome, Italy). The O₂-O₃ mixture was produced by means of a Multiossigen Medical 99IR generator (Multiossigen S.p.A., Gorle, Bergamo, Italy).

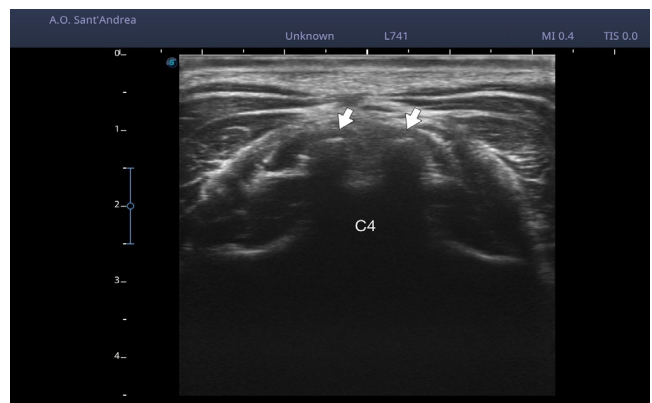


Figure 4: Transverse spinous process view, when the transducer is positioned directly over the spinous process at the C4 level.

Note: Spinous process is small and bifid (arrows). The images were obtained by means of a Sonoscape P50 Ultrasound (Sonoscape Europe s.r.l., Rome, Italy). The O₂-O₃ mixture was produced by means of a Multiossigen Medical 99IR generator (Multiossigen S.p.A., Gorle, Bergamo, Italy).

and inferiorly by the vertebral laminae. In this view, in order to evaluate the O₂-O₃ injections site, we suggest performing two linear measurements, at 1.5 cm lateral from the spinous process in cervical region (**Figure 5A**), and at 2 cm lateral from the spinous process in lumbar region (**Figure 5B**). The measurements are: (I) the distance between the skin and hyperechoic fascia surrounding the superior border of the muscle, named by authors with the acronym Skin-Muscle Distance; (II) the distance between the skin and hyperechogenic vertebral lamina (used as a landmark to identify the deep border of the muscle), named Skin-Lamina Distance (**Figure 5**). These two measurements provide useful information about paravertebral muscle depth. The Skin-Muscle Distance allows estimating the minimum depth necessary to achieve the musculature, and it is influenced by the thickness of the subcutaneous tissue. The Skin-Lamina Distance allows an assessment of the maximum paravertebral muscles depth. Based on these measurements

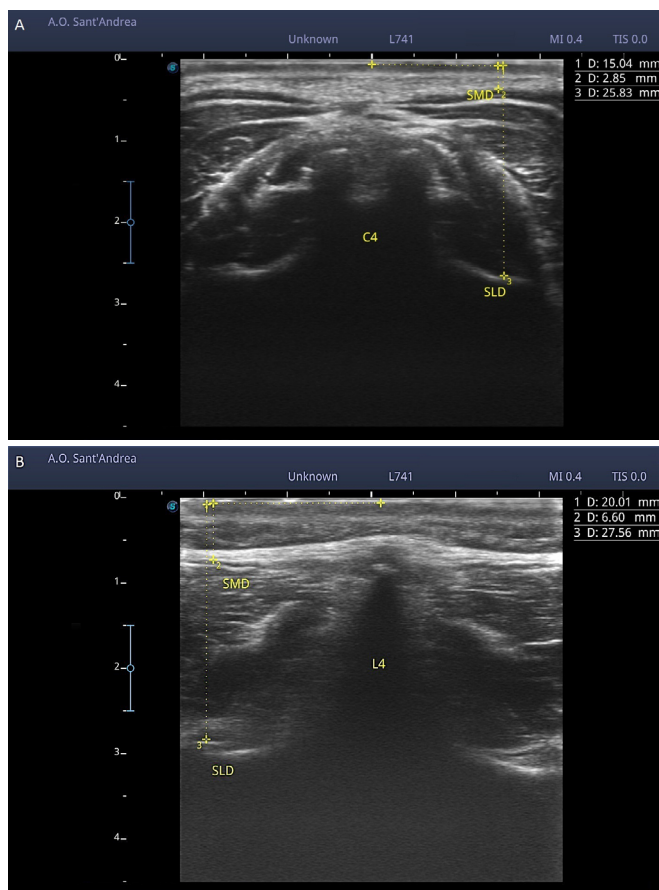


Figure 5: Example of measurements performed in transverse spinous process view.

Note: (A) At the C4 level, Skin-Muscle Distance (SMD) and Skin-Lamina Distance (SLD) are respectively 2.85 mm and 25.83 mm. (B) At the L4 level, SMD and SLD are 6.60 mm and 27.56 mm. The images were obtained by means of a Sonoscape P50 Ultrasound (Sonoscape Europe s.r.l., Rome, Italy). The O_2-O_3 mixture was produced by means of a Multiossigen Medical 99IR generator (Multiossigen S.p.A., Gorle, Bergamo, Italy).

it is possible to identify the needle length range that is most suitable to perform infiltration. Thinner and shorter needles can be used if the aim is to decrease patient discomfort during injections; while longer needles can be used if the goal is release therapeutic agent nearby vertebral lamina. In both cases, the injection can be performed being sure to be inside the musculature. Furthermore, the ultrasound examination is helpful in patients with a peculiar distribution of adipose tissue in which the most commonly needles used for O_2-O_3 injections are not long enough to achieve the paravertebral muscles. In these cases, the Skin-Muscle Distance is decisive for the correct needle choice.

ULTRASONOGRAPHY AS A REAL-TIME IMAGING MODALITY DURING INJECTIONS

Peritendinous and intra-articular injections require a thorough knowledge of the anatomy and an accurate physical examination to determine the optimal injection site and placement of O_2-O_3 mixture. Given the complexity of the anatomical sites of injection and the proximity to adjacent structures as vessels or nerves, to ensure safe and appropriate placement may be extremely difficult. The use of ultrasound as a real-time imag-

ing modality allows to evaluate the area of interest, reaching the target structure with precision and avoiding damaging important adjacent anatomical structures, confirm placement of the needle at the appropriate location, and ensure correct localization of therapeutic agent. The choice of the ultrasound probe depends on the characteristics of the structure to be sampled. The linear probe (10–15 MHz) provides adequate visualization of most superficial sites: joints, superficial muscles, and superficial bones. To visualize sites located deeper as deep joint articular surfaces, a linear probe with lower frequency or a convex probe (5–10 MHz) may be required. Before any definitive procedural intervention a preliminary scan through the site of interest should be performed, to inspect regional anatomy and visualize nearby neuro-vascular structures. Color or Power Doppler imaging can be used to evaluate region vascularity and help guide the procedure to minimize the potential for bleeding. In the case of peritendinous injections, the muscle and tendon should be scanned throughout their course. Placing the probe in longitudinal section, the needle is best visualized when its long axis is parallel to and in line with the long axis of the probe. In this plane, it is seen as a linear echogenic structure with reverberation artifact distally. In this view has been observed a higher success rate for injections.²⁶ In intra-articular injections, the joint space should be scanned in all dimensions to determine the safest and most optimal injection site. The selection of the needle is based on the depth of the structure being injected. The needle is inserted in target structure under direct sonographic visualization and it should be visible at all times during the procedure (Figure 6A). The O_2-O_3 injection, performed under ultrasound-guide, allows visualizing the real-time diffusion of the gas in the appropriate location (joint space or peritendinous soft tissues) and prevents inadvertent application into the tendons or peri-articular structures. The O_2-O_3 mixture appears as hyperechoic area in the peritendinous soft tissue with a well-defined shadow, or most rarely, with a faint shadow (Figure 6B).

The ultrasound-guided procedure, as demonstrated in literature for other therapeutic agent injection, reduces pain both during and after the injection, decreases overall patient discomfort, and improves joint or muscle mobility more than traditional blind injections.²⁵⁻²⁸ Obviously, it requires good experience and deep knowledge of the anatomy.

ULTRASONOGRAPHY AS POST-PROCEDURE VALUATION OF THE OXYGEN-OZONE DISTRIBUTION IN THE TISSUE

Once injected in the site to treat, ultrasonography may be useful tool to evaluate the O_2-O_3 mixture distribution in the tissue. O_2-O_3 mixture spreads in the tissue following the path of least resistance, and is visible for a variable time. In intramuscular paravertebral injection, ultrasonography shows a homogeneous gas distribution through the paravertebral muscle fibers (Figure 7); in peritendinous injection, O_2-O_3 mixture spreads along the peritendinous soft tissue (Figure 8).

CONCLUSION

Ultrasonography, used as a pre-procedure assessment before the paravertebral infiltration, is useful to identify the needle length range most suitable to perform infiltration. Ultraso-

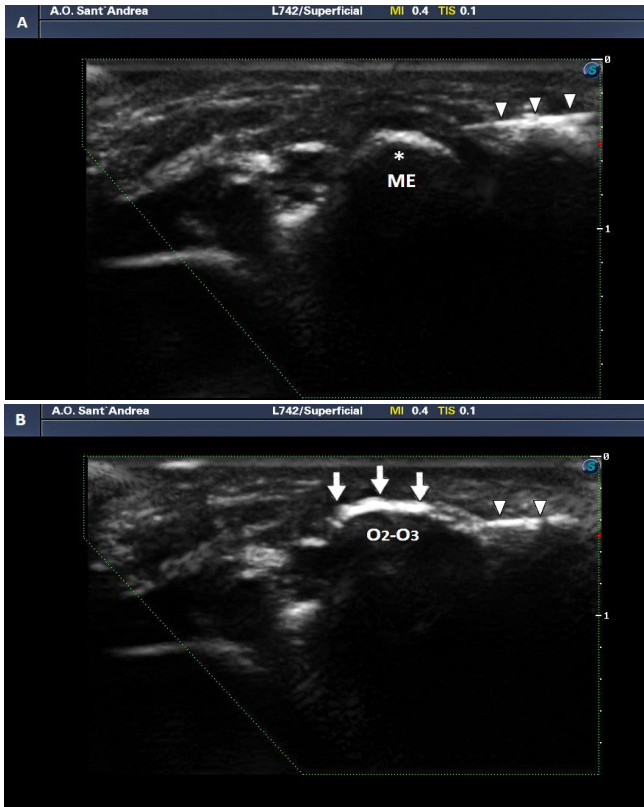


Figure 6: Medial epicondylitis ultrasound-guided infiltration.

Note: (A) The bony prominence of medial epicondyle (ME) is easily recognizable (asterisk). The needle (arrowheads) is positioned in the peritendinous soft tissue, near the tendon insertion. (B) The O_2-O_3 mixture (arrows) appears as hyperechoic area in the peritendinous soft tissue with a well-defined shadow that obscures the medial epicondyle below. The images were obtained by means of a Sonoscape P50 Ultrasound (Sonoscape Europe s.r.l., Rome, Italy). The O_2-O_3 mixture was produced by means of a Multiossigen Medical 99IR generator (Multiossigen S.p.A., Gorle, Bergamo, Italy).

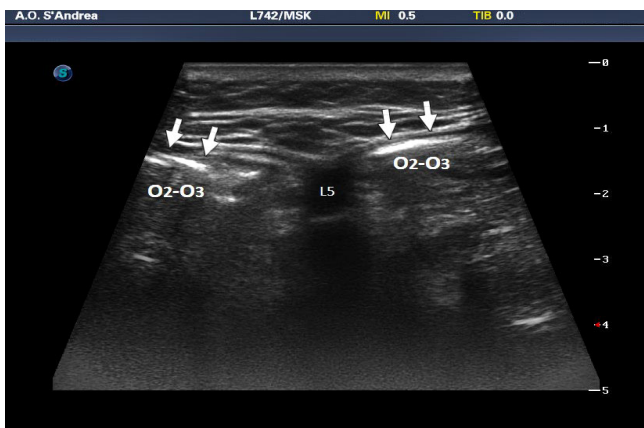


Figure 7: Intramuscular paravertebral injection at L5 level.

Note: The O_2-O_3 mixture (arrows) appears as hyperechoic area with a faint shadow. The images were obtained by means of a Sonoscape P50 Ultrasound (Sonoscape Europe S.p.A., Rome, Italy). The O_2-O_3 mixture was produced by means of a Multiossigen Medical 99IR generator (Multiossigen S.p.A., Gorle, Bergamo, Italy).

nography, used as a real-time imaging modality (or guide) during peritendinous and intra-articular injections, is useful to provide patients with safe and accurate treatments, following in real time every step of the procedure. Moreover, used as

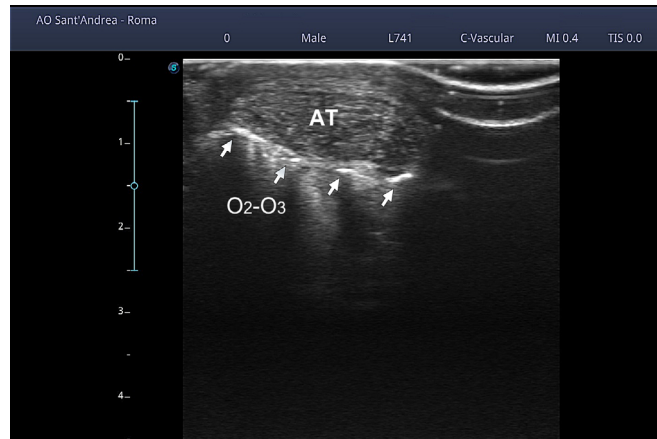


Figure 8: Achilles tendon ultrasound-guided infiltration.

Note: The O_2-O_3 mixture (arrows) appears as hyperechoic area along inferior border of Achilles Tendon (AT). The images were obtained by means of a Sonoscape P50 Ultrasound (Sonoscape Europe S.p.A., Rome, Italy). The O_2-O_3 mixture was produced by means of a Multiossigen Medical 99IR generator (Multiossigen S.p.A., Gorle, Bergamo, Italy).

post-procedure valuation, ultrasonography allows confirming the optimal distribution of the O_2-O_3 mixture injected in the tissue. In according to this review ultrasonography may be an added value to improve procedural accuracy, maximize patient's safety, and optimize clinical outcomes.

Author contributions

Study design, concept and definition: EL, ERC, AM, SMN, FS, DT, MV, MCV. All authors read and approved the final version of the paper for publication.

Conflicts of interest

None.

Financial support

None.

Declaration of patient consent

Written consent was obtained by patients for publication of pictures before we can publish it. Moreover, the images are anonymised by the removal of any identifying marks and are not accompanied by text that could reveal the patient's identity through clinical or personal detail.

Copyright license agreement

The Copyright License Agreement has been signed by all authors before publication.

Plagiarism check

Checked twice by iThenticate.

Peer review

Externally peer reviewed.

Open access statement

This is an open access journal, and articles are distributed under the terms of the Creative Commons Attribution-NonCommercial-ShareAlike 4.0 License, which allows others to remix, tweak, and build upon the work non-commercially, as long as appropriate credit is given and the new creations are licensed under the identical terms.

REFERENCES

1. Bocci V. How a calculated oxidative stress can yield multiple therapeutic effects. *Free Radic Res.* 2012;46:1068-1075.
2. Bocci V, Valacchi G. Free radicals and antioxidants: how to reestablish redox homeostasis in chronic diseases? *Curr Med Chem.* 2013;20:3397-3415.
3. Bocci V. *Oxygen-Ozone Therapy: A Critical Evaluation.* Dordrecht: Kluwer Academic Publishers. 2002.



4. Bocci VA. Scientific and medical aspects of ozone therapy. State of the art. *Arch Med Res.* 2006;37:425-435.
5. Bocci V, Borrelli E, Travagli V, Zanardi I. The ozone paradox: ozone is a strong oxidant as well as a medical drug. *Med Res Rev.* 2009;29:646-682.
6. Bocci V, Luzzi E, Corradeschi F, Paulesu L, Di Stefano A. Studies on the biological effects of ozone: III, an attempt to define conditions for optimal induction of cytokines. *Lymphokine Cytokine Res.* 1993;12:121-126.
7. Bocci VA. Scientific and medical aspects of ozone therapy. State of the art. *Arch Med Res.* 2006;37:425-435.
8. Calabrese EJ. Paradigm lost, paradigm found: The re-emergence of hormesis as a fundamental dose response model in the toxicological sciences. *Environ Pollut.* 2005;138:379-411.
9. Al-Jaziri AA, Mahmoodi SM. Painkilling effect of ozone-oxygen injection on spine and joint osteoarthritis. *Saudi Med J.* 2008;29:553-557.
10. Borrelli E, Alexandre A, Iliakis E, Alexandre A, Bocci V. Disc herniation and knee arthritis as chronic oxidative stress diseases: the therapeutic role of oxygen ozone therapy. *J Arthritis.* 2015;4:161.
11. Schwartz-Tapia A, Martínez-Sánchez G, Sabah F. *Madrid Declaration on Ozone Therapy, Madrid.* Vol. 50. Madrid: ISCO3 (International Scientific Committee of Ozone Therapy); 2015. Madrid Declaration on Ozone Therapy 2015-2020 Eng.
12. Perri M, Grattacaso G, Di Tunno V, et al. T2 shine-through phenomena in diffusion-weighted MR imaging of lumbar discs after oxygen-ozone discolysis: a randomized, double-blind trial with steroid and O₂-O₃ discolysis versus steroid only. *Radiol Med.* 2015;120:941-950.
13. Louis LJ. Musculoskeletal ultrasound intervention: principles and advances. *Radiol Clin North Am.* 2008;46:515-533.
14. Patel Y, Scillia A, Festa A, Mclnerney V, Hirsch S. The role of ultrasound-guided injections in orthopaedic sports medicine: upper extremity. *AAOS Now.* 2015;9:14.
15. Sibbitt WL, Peisajovich A, Michael AA, et al. Does sonographic needle guidance affect the clinical outcome of intraarticular-injections? *J Rheumatol.* 2009;36:1892-1902.
16. Smith J, Finnoff JT. Diagnostic and interventional musculoskeletal ultrasound: part 2. Clinical applications. *PM R.* 2009;1:162-177.
17. Bocci V, Borrelli E, Zanardi I, Travagli V. The usefulness of ozone treatment in spinal pain. *Drug Des Devel Ther.* 2015;9:2677-2685.
18. Pysyk CL1, Persaud D, Bryson GL, Lui A. Ultrasound assessment of the vertebral level of the palpated intercrystal (Tuffier's) line. *Can J Anaesth.* 2010;57:46-49.
19. Grieve GP. *Common Vertebral Joint Problems.* Edinburgh: Churchill Livingstone; 1983.
20. Stokes M, Rankin G, Newham DJ. Ultrasound imaging of lumbar multifidus muscle: normal reference ranges for measurements and practical guidance on the technique. *Man Ther.* 2005;10:116-126.
21. Oh CH, Ji GY, Yoon SH, et al. Surface landmarks do not correspond to exact levels of the cervical spine: references according to the sex, age and height. *Korean J Spine.* 2014;11:178-182.
22. Chin KJ, Karmakar MK, Peng P. Ultrasonography of the adult thoracic and lumbar spine for central neuraxial blockade. *Anesthesiology.* 2011;114:1459-1485.
23. Bron JL, van Royen BJ, Wuisman PI. The clinical significance of lumbosacral transitional anomalies. *Acta Orthop Belg.* 2007;73:687-695.
24. Royall NA, Farrin E, Bahner DP, Stawicki SPA. Ultrasound-assisted musculoskeletal procedures: A practical overview of current literature. *World J Orthop.* 2011;2:57-66.
25. Naredo E, Cabero F, Beneyto P, et al., A randomized comparative study of short term response to blind injection versus sonographic-guided injection of local corticosteroids in patients with painful shoulder. *J Rheumatol.* 2004;31:308-314.
26. Sibbitt WL, Peisajovich A, Michael AA, et al. Does sonographic needle guidance affect the clinical outcome of intraarticular-injections? *J Rheumatol.* 2009;36:1892-1902.
27. Luz KR, Furtado RN, Nunes CC, Rosenfeld A, Fernandes AR, Natour J. Ultrasound-guided intra-articular injections in the wrist in patients with rheumatoid arthritis: a double-blind, randomised controlled study. *Ann Rheum Dis.* 2008;67:1198-1200.
28. Smith J, Finnoff JT, Santaella-Sante B, Henning T, Levy BA, Lai JK. Sonographically guided popliteus tendon sheath injection: techniques and accuracy. *J Ultrasound Med.* 2010;29:775-782.

Received: January 17, 2019

Accepted: February 12, 2019