

National trends of preoperative imaging modalities before partial nephrectomy for renal masses in the U.S. from 2007–2015

Jae Heon Kim, MD^{1,2*}; Shufeng Li, MSc^{3*}; Yash Khandwala MD^{1,4}; Francesco Del Giudice, MD⁵; Kyung Jin Chung, MD¹; Hyung Keun Park, MD¹; Benjamin I. Chung, MD¹

¹Department of Urology, Stanford University Medical Center, Stanford, CA, United States; ²Department of Urology, Soonchunhyang University Hospital, Soonchunhyang University Medical College, Seoul, Korea; ³Department of Urology and Dermatology, Stanford University Medical Center, CA, United States; ⁴University of California, San Diego School of Medicine, San Diego, CA, United States; ⁵Department of Urology, Sapienza University of Rome, Rome, Italy

*Equal contributors

Cite as: *Can Urol Assoc J* 2019;13(3):E89-94. <http://dx.doi.org/10.5489/cuaj.5414>

Published online August 30, 2018

Abstract

Introduction: Although the performance of partial nephrectomies (PN) for renal masses has increased rapidly over the years, only a few studies have investigated the frequency and patterns of preoperative imaging modalities. The aim of this study was to investigate the frequency and patterns in preoperative imaging modalities before PN.

Methods: A total of 21 445 patients who underwent PN between 2007 and 2015 were selected from a national representative population in the MarketScan database and included in this study. The annual incidence and proportion of PN, as well as the use of each preoperative imaging modality were analyzed.

Results: Both annual crude number and frequency rate of PN decreased or became static since 2012. Computed tomography (CT) shows the greatest proportion of the crude number and percentage; despite a slight decrease in percentage, it is still >80%. Among the combinations, CT alone and CT combined with ultrasonography showed the highest performance rate during the complete observational period. The proportion of all other combinations, which include other complex combinations except CT alone, CT plus ultrasonography, CT plus magnetic resonance imaging (MRI), and CT plus MRI plus ultrasonography, was 13.95% in 2007, but increased to 19.04% in 2014.

Conclusions: CT still plays a major role in preoperative imaging for renal masses, whereby CT alone and CT combined with ultrasonography account for a major proportion of the preoperative imaging patterns. The use of other imaging combinations, as well as renal biopsies, shows an increasing trend. Additional studies are needed to investigate whether this trend in preoperative imaging is related to the frequency rate of PN.

Introduction

The prevalence of small, localized renal masses among renal cell carcinomas (RCC) has increased over the years in the U.S., representing almost half of all newly diagnosed RCC cases.¹ The increased use of preoperative imaging modalities explains the increase in the number of incidental small renal masses.¹ Both American and European urology guidelines recommend nephron-sparing surgery as the standard treatment strategy for small renal masses, especially T1 renal masses.²

The use of partial nephrectomy (PN) is currently increasing compared with the decrease in the use of radical nephrectomy.³⁻⁵ This trend is observed because a preservation of renal function is sought whenever feasible, which might compromise overall survival after radical nephrectomy. To date, urologists have focused on the extended role of PN in T2 (larger tumours) and even in T3 stage cases with sinus fat invasion state.^{6,7} They have been concerned with reduction of postoperative complications or sequelae, oncological outcomes, and procedure types in subjects undergoing PN.⁸

However, the increasing use of PN has resulted in a markedly high incidence of benign pathologies after PN.^{9,10} Although a few studies investigated potential risk factors for the detection of histologically benign pathologies after PN,^{11,12} no study so far has focused on general trends in preoperative imaging modalities, which might represent a crucial factor regarding the high prevalence of benign pathologies following PN. Considering the high accuracy in predicting pathologies before PN,¹³ the trends and patterns of preoperative imaging modalities and its combinations should be investigated precisely.

Furthermore, contrary to the general opinion of urologists regarding the gradually increasing incidence of renal malignancies and the use of PN, a recent Surveillance, Epidemiology, and End Results (SEER) annual report confirmed that the incidence of renal malignancy no longer shows an increasing trend, but rather a slightly decreasing or

static trend. Moreover, based on the data from the California Cancer Registry, Morris et al¹⁴ reported that the incidence of not only all RCCs but also all localized RCCs indicated for PN no longer shows an increasing trend. This study was the first report to show that the incidence of localized RCC is not increasing.¹⁴

The aim of our study was to investigate the trends in preoperative radiological imaging techniques for renal masses, as well as to investigate the frequency trend of PN using national representative data derived from the MarketScan database. To the best of our knowledge, our recent study represents the first to investigate the real performance status of preoperative imaging modalities for renal masses before PN.

Methods

Data source

Data were derived from the IBM® MarketScan® Research Database. The data reflected the confidentiality requirements of the Health Insurance Portability and Accountability Act of 1996. Use of data from this database without informed consent was approved by the institutional review board of Stanford University.

Study population

All adults aged above 18 with a primary procedure code (International Classification of Diseases, Ninth Revision, Clinical Modification [ICD-9-CM], and the Current Procedural Terminology [CPT] surgical codes) for elective PN (55.4) with a related diagnosis between January 1, 2007, and December 31, 2015, were selected. We selected all PN procedures performed in the inpatient service from 2007 and considered the surgery date as the index date. To determine preoperative imaging, the following CPT codes were used: computed tomography (CT; 74150, 74160, and 74170); magnetic resonance imaging (MRI; 74181, 74182, and 74183); ultrasonography (USG; 76700, 76705, 76770, and 76775); and renal mass biopsy (50200 and 50205).

Main outcome measures

Our study included two main outcomes: annual PN trend and annual trend in preoperative imaging pattern before PN. The annual PN trend included two measures: the actual frequency and the frequency rate per 100 000. The annual trend associated with the preoperative imaging pattern before PN included the actual number and proportion (of annual number of PN patients) with each preoperative imaging modality and the annual trend associated with the combination of preoperative imaging modalities. Surgery date

was regarded as the index date, and preoperative imaging within one year was considered as preoperative imaging for PN. The performance of each imaging modality was defined as any type of CT (those patients with performance of CT regardless of any other imaging modalities), MRI, USG, or biopsy. Patterns of imaging combinations were categorized as CT alone, CT plus USG, CT plus MRI, CT plus MRI plus USG, and other combinations (MRI only, MRI+USG, any other combination with biopsy).

Statistical analysis

Frequency rate per year was calculated using the frequency density rate as the number of new PN cases in the relevant year multiplied by 100 000 and divided by the number of persons at risk (enrolled total cohort in the relevant year). Regarding the temporal changes in preoperative imaging patterns annually, we used the actual frequency numbers and proportions together. To determine the significance of trend with time, a linear regression for the line of fit was conducted. Post-hoc subgroup analysis was performed by dividing the patients into age groups of <65 and ≥65 years. All analyses were conducted with SAS 9.4 (SAS Institute, Cary, NC, U.S.).

Results

Study population

A total of 21 445 patients with an ICD-9-CM code of 55.4 were identified from 2007–2015 using the Truven database system. Owing to the insufficient records of patients in 2015, 1216 patients were excluded. In addition, the patients without any records of preoperative imaging within one year from the index date were also excluded (n=1602). A total of 18 627 patients were selected for final inclusion into analyses (Fig. 1).

Annual frequency and frequency rate of PN

Both the annual crude number and frequency rate of PN are described in Fig. 2. Until 2012, similarly, both the crude number and frequency rate showed an increasing trend with a coefficient of 2.19 (95% confidence interval [CI] 1.41, 2.97). However, the crude number showed a sharp decrease in 2013 (n=2549) and then a slight increase in 2014 (n=2579). The frequency rate tended to decline to 6.8 in 2013 and further down to 6.5 in 2014.

Annual frequency of preoperative imaging modalities

Fig. 2 shows the crude number and percentage of each imaging modality by year. The annual trend associated with the

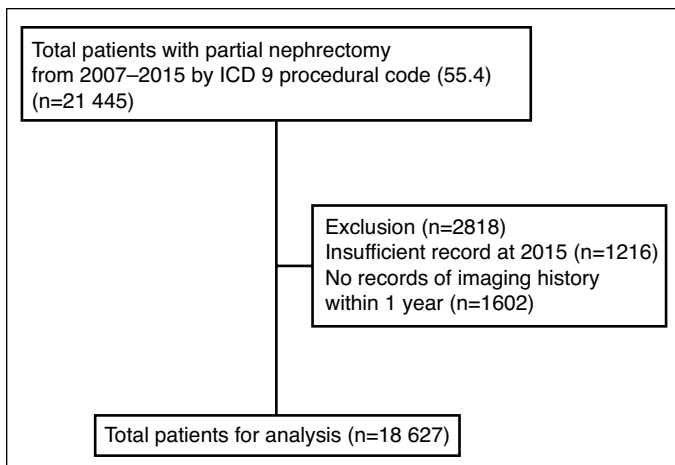


Fig. 1. Deposition of the study population.

crude number of imaging procedures (Fig. 3A) is similar to that of the crude number of PN. CT yielded the maximum crude number and percentage; despite a slight decrease in the percentage of CT, with a coefficient of -1.29 (95% CI $-3.35, 0.77$), it is still used $>80\%$ of the time (Fig. 3B). USG is the second most frequently used preoperative imaging modality, with a significant increase in percentage (coefficient of 0.60 [95% CI $0.23, 0.74$]) (43.56% in 2007 and 55.45% in 2014). MRI accounts for approximately 30–33% of the cases from 2007–2014, with a coefficient of 1.12 (95% CI $-0.45, 2.69$). Biopsy showed a significant increase, with a coefficient of 1.53 (95% CI $0.89, 2.16$), from 5.28% in 2007 to 9.58% in 2014.

Annual trend associated with a combination of preoperative imaging modalities

The crude numbers associated with combination patterns are shown in Fig. 4A. Among the combinations, CT alone

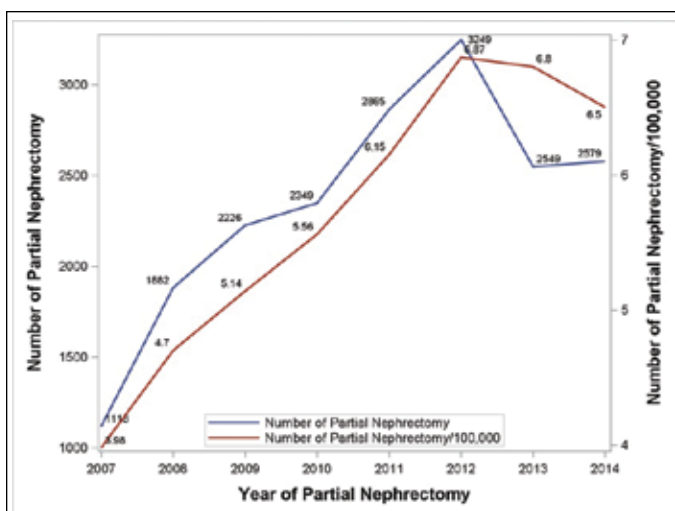


Fig. 2. Annual frequency and frequency rate of partial nephrectomy.

and CT combined with USG showed the highest numbers during the whole year, with a similar trend as PN. However, the proportion of CT alone and CT combined with USG no longer showed an increasing trend (Fig. 4B). The proportion of CT alone decreased significantly, with a coefficient of -0.68 (95% CI $-1.12, -0.24$) from 38.37% in 2007 to 28.46% in 2014. The crude number and proportion of all other combinations that include other complex combinations except CT alone, CT plus USG (coefficient 1.03 [95% CI $-0.06, 2.13$]), CT plus MRI (coefficient -1.85 [95% CI $-4.00, 0.30$]), and CT plus MRI plus USG (coefficient 0.45 [95% CI $-1.57, 2.48$]) represent a steady state. The proportion of other combinations showed a significant increasing trend (coefficient 1.12 [95% CI $0.54, 1.70$]).

Post-hoc subgroup analysis

Fig. 5 shows the crude number and frequency rate (/100 000) of PN in two age groups, ≥ 65 and <65 years. The total crude number of PN in the <65 year age group showed a sharp decrease in 2013. The frequency rate of PN in the ≥ 65 year age group showed a steady increase from 2007 to 2014. Fig. 5 shows the crude number and percentage of each preoperative imaging modality. The percentage of CT showed a decreasing trend in both groups (Fig. 6A). The trend for MRI showed a similar pattern; however, USG and biopsy showed a prominently increasing pattern in the ≥ 65 year age group (Fig. 6B).

Discussion

To the best of our knowledge, we are the first to report the most recent frequency analysis of PN and the annual trends in preoperative imaging techniques with combined modalities. Contrary to the general concept suggesting that the use of PN is steadily increasing and rapidly replacing the significant role of radical nephrectomy,³⁻⁵ our data showed no definitive increase since 2012.

The absence of an increasing trend in the absolute frequency number of PN might be attributed to the incidence of renal malignancy itself showing no increasing trend. The most recent SEER data showed that the average annual percentage change (AAPC) from 13 SEER areas from 2005 to 2014 was -0.9 (SEER Cancer Statistics Review 1975–2014). Moris et al¹⁴ also reported using California Cancer Registration data that the incidence of RCC showed a steadily increasing pattern until 2008 and 2009. However, the increasing trend was reversed from 2008 and 2009, and the incidence was stabilized. Furthermore, the incidence of RCCs <4 cm in size warranting PN showed a declining trend since 2009, with an AAPC of -0.3 .

Although our study is the first to report the decreasing or static patterns of the crude numbers and frequencies of

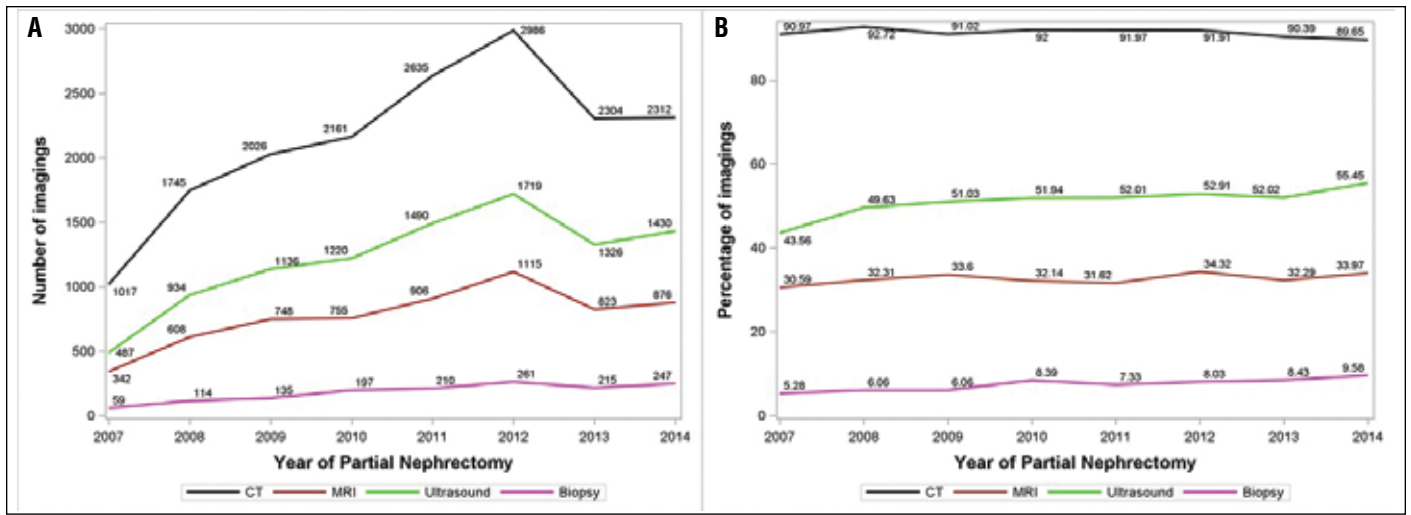


Fig. 3. Annual frequency and proportions of preoperative imaging modalities.

PN, the proportion of PN compared with that of radical nephrectomy still showed an increasing trend.¹⁴ Urologists have focused on the expansion of the indications for PN even to T3 stages with sinus fat invasion^{6,7} and have been concerned with perioperative complications, including ischemia time and blood loss, and postoperative complications, such as postoperative exacerbation in renal function.⁸ Several reports have focused on the benign pathology after PN.⁹⁻¹² Considering the socioeconomic burden of PN and related complications among patients with benign pathology, several studies focused more on the critical role of preoperative imaging modalities, which are now increasingly accurate in predicting RCC.^{13,15-17} However, no studies have been conducted regarding preoperative imaging trends or patterns before PN for renal masses so far. Our additional goal was to investigate the trends and patterns in preoperative imaging modalities.

Our study provides the most recent evidence supporting the role of CT, which still plays a major role in preopera-

tive imaging. Based on the pattern of the combined use of imaging modalities, CT alone and CT combined with USG accounted for the highest proportion of preoperative imaging. Although CT is still the standard modality to predict renal masses and associated with high accuracy,¹³ over the last decade, radiologists have shown the excellent predictive outcome of MRI and renal mass biopsy.¹⁵⁻¹⁸

The question about urologists focusing less on additional imaging modalities, including MRI, persists. A substantial gap exists between urologists and radiologists in terms of radiological interpretation. Most reports investigating the accuracy of MRI in predicting RCCs among small renal masses were based on retrospective studies¹⁵⁻¹⁸ and the retrospective interpretation of MRI varies from real-time interpretation in real clinical practice. Eventually, the ultimate ability of technologies such as CT or MRI to predict RCCs in small renal masses, as shown in previous studies, requires time, which is not feasible in real clinical practice. Concerned this issue, Kim et al¹⁸ reported that the diagnostic accuracies of

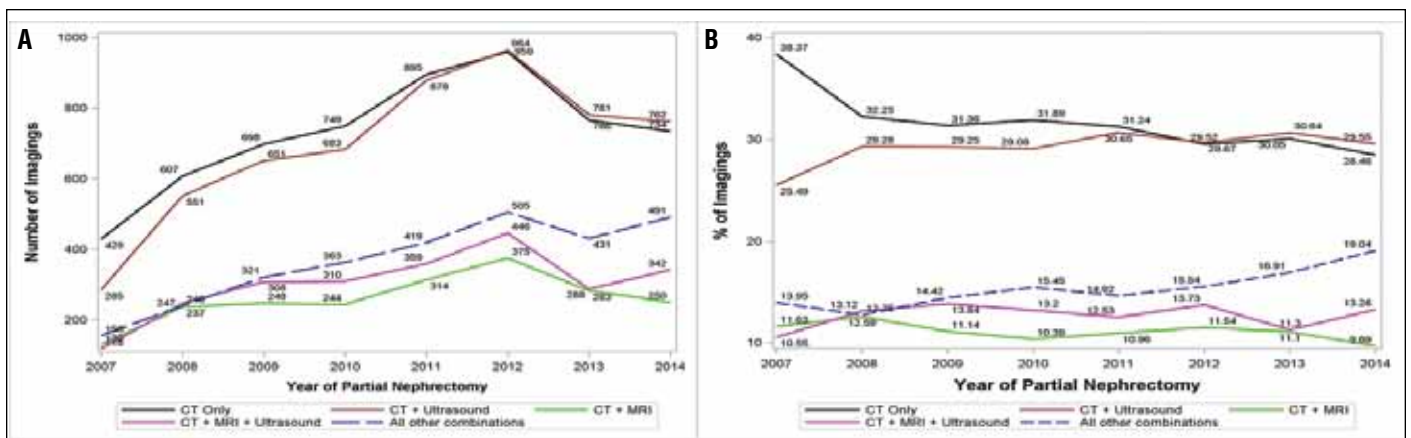


Fig. 4. Annual frequency and proportions of combination patterns in preoperative imaging modalities.

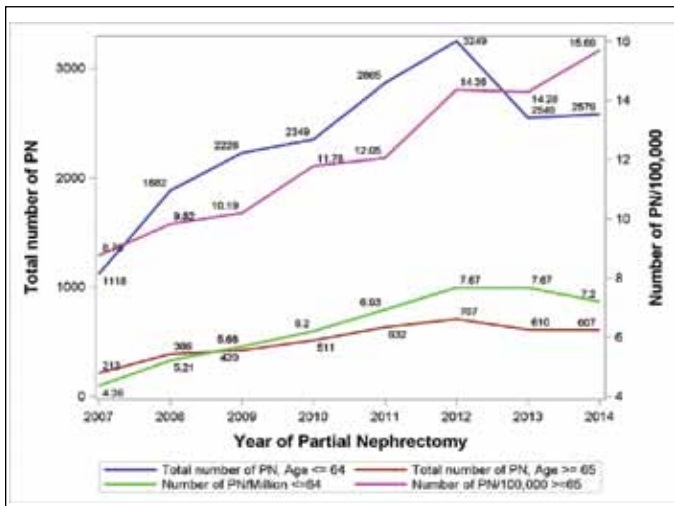


Fig. 5. Crude number and frequency rate (/100 000) of partial nephrectomy in the two age groups: ≥65 and <65 years.

CT and MRI are not high in predicting RCCs in small renal masses. CT and MRI showed 79.7% and 88.1% sensitivity, and 44.4% and 33.3% specificity, respectively, based on a subjective radiological interpretation in real clinical practice.

Although our study clearly indicates an increasing trend associated with the use of other imaging modalities, including MRI and renal biopsy, several limitations remain. One important limitation of our study is the fact that we were not able to show the substantial role of MRI or renal biopsy in the context of patients with histologically benign pathologies. Furthermore, we could not determine the role of radical nephrectomy compared with PN in this study. Other limitations include the lack of additional information pertaining to the procedural type of PN (robotic, laparoscopic, or open). In addition, although we calculated the frequency of PN using the MarketScan population database, it was not meant

to be the standardized rate. Lastly, due to limited followup information, the role of active surveillance was not observed.

Conclusion

Clinicians are undecided as to the most practical option for treatment of small renal masses, including CT alone or CT plus USG, or additional imaging modalities, such as MRI and biopsy for small renal masses to reduce the incidence of benign pathologies after PN and prevent unnecessary surgery and related complications. Avoiding unnecessary surgery is more important than the issue of cost-effectiveness. Hence, the current trend reflecting the use of other combination modalities and renal mass biopsy represents a positive phenomenon.

Competing interests: The authors report no competing personal or financial interest related to this work.

Acknowledgement: Data for this project were accessed using the Stanford Center for Population Health Sciences Data Core. The PHS Data Core is supported by a National Institutes of Health National Center for Advancing Translational Science Clinical and Translational Science Award (UL1 TR001085) and from Internal Stanford funding. This work was also supported by Soonchunhyang University Research Fund.

This paper has been peer-reviewed.

References

1. Chow WH, Devesa SS, Warren JL, et al. Rising incidence of renal cell cancer in the United States. *JAMA* 1999;281:1628-31.
2. Kim SP, Thompson RH, Boorjian SA, et al. Comparative effectiveness for survival and renal function of partial and radical nephrectomy for localized renal tumours: A systematic review and meta-analysis. *J Urol* 2012;188:51-7. <https://doi.org/10.1016/j.juro.2012.03.006>

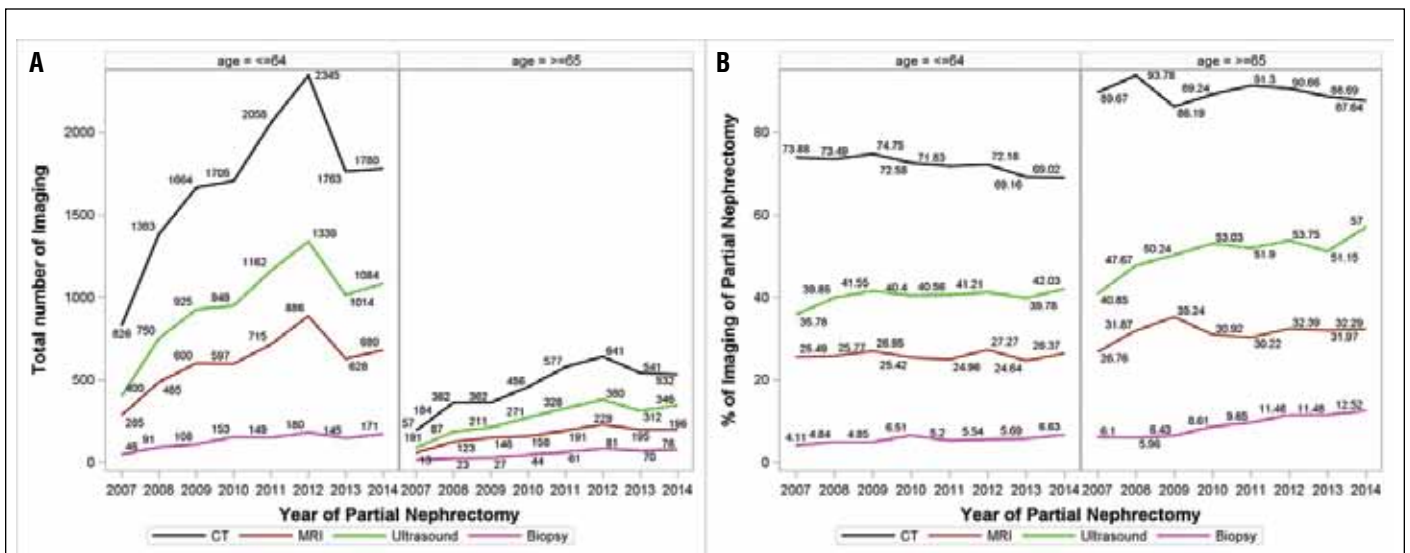


Fig. 6. Crude number and percentage of each preoperative imaging modality: ≥65 and <65 years.

3. Bjurlin MA, Walter D, Takslar GB, et al. National trends in the utilization of partial nephrectomy before and after the establishment of AUA guidelines for the management of renal masses. *Urology* 2013;82:1283-9. <https://doi.org/10.1016/j.urology.2013.07.068>
4. Leppert JT, Mittakanti HR, Thomas IC, et al. Contemporary use of partial nephrectomy: Are older patients with impaired kidney function being left behind? *Urology* 2017;100:65-71. <https://doi.org/10.1016/j.urology.2016.08.044>
5. Tan HJ, Daskivich TJ, Shirk JD, et al. Health status and use of partial nephrectomy in older adults with early-stage kidney cancer. *Urol Oncol* 2017;35:153e157-153e114.
6. Mouracade P, Dagenais J, Chavali JS, et al. Perinephric and sinus fat invasion in stage pT3a tumours managed by partial nephrectomy. *Clin Genitourin Cancer* 2018;16:e1077-e1082. <https://doi.org/10.1016/j.clgc.2017.07.019>
7. Zhang Z, Yu C, Velet L, et al. The difference in prognosis between renal sinus fat and perinephric fat invasion for pT3a renal cell carcinoma: A meta-analysis. *PLoS One* 2016;11:e0149420. <https://doi.org/10.1371/journal.pone.0149420>
8. Spaliviero M, Power NE, Murray KS, et al. Intravenous mannitol vs. placebo during partial nephrectomy in patients with normal kidney function: A double-blind, clinically integrated, randomized trial. *Eur Urol* 2018;73:53-9. <https://doi.org/10.1016/j.eururo.2017.07.038>
9. Fujii Y, Komai Y, Saito K, et al. Incidence of benign pathologic lesions at partial nephrectomy for presumed RCC renal masses: Japanese dual-centre experience with 176 consecutive patients. *Urology* 2008;72:598-602. <https://doi.org/10.1016/j.urology.2008.04.054>
10. Kutikov A, Fosssett LK, Ramchandani P, et al. Incidence of benign pathologic findings at partial nephrectomy for solitary renal mass presumed to be renal cell carcinoma on pre-operative imaging. *Urology* 2006;68:737-40. <https://doi.org/10.1016/j.urology.2006.04.011>
11. Bauman TM, Potretzke AM, Wright AJ, et al. Partial nephrectomy for presumed renal cell carcinoma: Incidence, predictors, and perioperative outcomes of benign lesions *J Endourol* 2017;31:412-7.
12. Jeon HG, Lee SR, Kim KH, et al. Benign lesions after partial nephrectomy for presumed renal cell carcinoma in masses 4 cm or less: Prevalence and predictors in Korean patients. *Urology* 2010;76:574-9. <https://doi.org/10.1016/j.urology.2009.11.082>
13. Mazzei FG, Mazzei MA, Cioffi Squitieri N, et al. CT perfusion in the characterization of renal lesions: An added value to multiphasic. *CT Biomed Res Int* 2014;2014:135013.
14. Morris CR, Lara PN Jr, Parikh-Patel A, et al. Kidney cancer incidence in California: End of the trend? *Kidney Cancer* 2017;1:71-81. <https://doi.org/10.3233/KCA-170005>
15. Kim JH, Bae JH, Lee KW, et al. Predicting the histology of small renal masses using pre-operative dynamic contrast-enhanced magnetic resonance imaging. *Urology* 2012;80:872-6. <https://doi.org/10.1016/j.urology.2012.06.001>
16. Oliva MR, Glickman JN, Zou KH, et al. Renal cell carcinoma: t1 and t2 signal intensity characteristics of papillary and clear-cell types correlated with pathology. *AJR Am J Roentgenol* 2009;192:1524-30. <https://doi.org/10.2214/AJR.08.1727>
17. Sun MR, Ngo L, Genega EM, et al. Renal cell carcinoma: Dynamic contrast-enhanced MR imaging for differentiation of tumor subtypes — correlation with pathologic findings. *Radiology* 2009;250:793-802. <https://doi.org/10.1148/radiol.2503080995>
18. Kim JH, Sun HY, Hwang J, et al. Diagnostic accuracy of contrast-enhanced computed tomography and contrast-enhanced magnetic resonance imaging of small renal masses in real practice: sensitivity and specificity according to subjective radiologic interpretation. *World J Surg Oncol* 2016;14:260. <https://doi.org/10.1186/s12957-016-1017-z>

Correspondence: Dr. Jae Heon Kim, Department of Urology, Stanford University Medical Center, Stanford, CA, United States; piacekjh@stanford.edu