



SAPIENZA  
UNIVERSITÀ DI ROMA

**Dottorato in Scienze Endocrinologiche**

**XXXI Ciclo**

Coordinatore Prof. Andrea Lenzi

Tesi di Dottorato

*“Effects of percutaneous varicocele repair on testicular volume and  
function: results from a 12-month follow-up”*

Relatore

Prof. Francesco Romanelli

Co-Relatore

Dott. Daniele Gianfrilli

Dottorando

Dott. Andrea Sansone

<b>INTRODUCTION</b>	<b>4</b>
---------------------	----------

---

**PROTOCOL #1: TESTICULAR CATCH-UP GROWTH FOLLOWING PERCUTANEOUS LEFT VARICOCELE REPAIR:**

<b><u>RESULTS FROM A 12-MONTHS FOLLOW-UP.</u></b>	<b>5</b>
---	----------

<b>INTRODUCTION</b>	<b>5</b>
<b>MATERIALS AND METHODS</b>	<b>5</b>
PATIENTS	5
PROTOCOL	6
PERCUTANEOUS TREATMENT OF VARICOCELE	6
STATISTICAL ANALYSIS	7
<b>RESULTS</b>	<b>7</b>
COMPLICATIONS, FAILURE RATE AND RADIATION EXPOSURE	8
<b>DISCUSSION</b>	<b>9</b>
<b>CONCLUSIONS</b>	<b>11</b>

**PROTOCOL #2: ENDOCRINE AND SPERMATOGENETIC FUNCTION OF THE HYPOTROPHIC TESTIS IN**

<b><u>VARICOCELE PATIENTS</u></b>	<b>12</b>
-----------------------------------	-----------

---

<b>INTRODUCTION</b>	<b>12</b>
<b>MATERIALS AND METHODS</b>	<b>12</b>
PATIENTS	12
ENDOCRINE ASSESSMENT	12
SEMEN ANALYSIS	13
STATISTICAL ANALYSIS	13
<b>RESULTS</b>	<b>13</b>
<b>DISCUSSION</b>	<b>15</b>
<b>CONCLUSIONS</b>	<b>17</b>

<b><u>PROTOCOL #3: EFFECTS OF PERCUTANEOUS TREATMENT OF LEFT VARICOCELE ON SPERMATOGENETIC AND ENDOCRINE FUNCTION OF THE TESTIS: RESULTS FROM A 12-MONTH FOLLOW-UP.</u></b>	<b>18</b>
<b>INTRODUCTION</b>	<b>18</b>
<b>MATERIALS AND METHODS</b>	<b>18</b>
PATIENTS	18
PERCUTANEOUS TREATMENT OF VARICOCELE.	18
ENDOCRINE ASSESSMENT	18
SEMEN ANALYSIS	19
STATISTICAL ANALYSIS	19
<b>RESULTS</b>	<b>19</b>
<b>DISCUSSION</b>	<b>20</b>
<b>CONCLUSIONS</b>	<b>22</b>
<b><u>PROTOCOL #4: AMH AND INSL3 AS MARKERS OF TESTICULAR MATURATION STATUS AND THEIR ROLE IN TESTICULAR AND SYSTEMIC CONDITIONS.</u></b>	<b>23</b>
<b>INTRODUCTION</b>	<b>23</b>
<b>AMH</b>	<b>24</b>
REGULATION OF AMH EXPRESSION	24
AMH IN TESTICULAR PATHOPHYSIOLOGY	25
<b>INSL3</b>	<b>27</b>
REGULATION OF INSL3 EXPRESSION	27
INSL3 IN TESTICULAR PATHOPHYSIOLOGY	28
<b>BEYOND REPRODUCTION: EXTRA-GONADAL PATHOPHYSIOLOGY OF AMH AND INSL3</b>	<b>28</b>
<b>CONCLUSIONS</b>	<b>29</b>
<b><u>TABLES AND FIGURES</u></b>	<b>31</b>
<b><u>REFERENCES</u></b>	<b>52</b>

## Introduction

Varicocele – the excessive dilatation of the pampiniform venous plexus of the spermatic cord [1] – is a common finding in males of reproductive age since adolescence. Its prevalence is debated, as estimates from different populations yield different results [2]: however, it is usually reported that varicocele may occur in up to 15% of all males between 15 and 19 years, with a much lower prevalence before puberty [3]. Testicular damage resulting from varicocele has been variably associated with reduced testicular volume, impaired spermatogenesis, and increased sperm DNA damage [4, 5], although the mechanisms involved are still not completely understood [6]. It is therefore unsurprising that it is listed as one of the most frequent causes of male infertility and that its prevalence is much higher in infertile men, at 30-40% in primary and 80-85% in secondary infertility [7, 8].

Existing guidelines propose different approaches on when and how to treat varicocele [9]. Reduced ipsilateral testicular size is one of the indications for treatment, above all in adolescents. As 80-90% of testicular volume is made up of germ cells within seminiferous tubules, an asymmetrical reduction in testicular volume is universally accepted as a sign of testicular damage. Improvements in testicular volume [10], sperm parameters [11] and DNA fragmentation [12] have been variably reported following surgical treatment of varicocele; however, to our knowledge, no study has yet described the long-term effects of percutaneous varicocele embolization on testicular volume or function. As this treatment is regularly used in clinical practice [8], we retrospectively assessed testicular volume catch-up growth and changes in testicular function during a 12-month follow-up in a single center protocol-driven study.

# Protocol #1: Testicular catch-up growth following percutaneous left varicocele repair: results from a 12-months follow-up.

## Introduction

In the first part of this project, we aimed to assess the effects of percutaneous treatment of varicocele on testicular volume. In order to reduce bias, we aimed to exclude from analysis all patients with an history of testicular pathology as well as all those subjects with right or bilateral varicocele. It is generally accepted that testicular volume is largely influenced by pubertal status [13]: before the onset of puberty, immature Sertoli cells are the most represented cell population in the testis, whereas germ cells account for more than 70% of adult testicular volume. However, changes in testicular volume occur during adult life as well: compensatory hypertrophy of the remaining testis occurs following orchiectomy, and administration of exogenous FSH is likewise associated with an increase of testicular volume [14]. However, despite anecdotal reports, there is no evidence of the possible effects of varicocele treatment on testicular volume. This change has definite psychological consequences, but might also be an important predictor of improved testicular function in regards to both spermatogenesis and hormone production.

## Materials and methods

### *Patients*

We retrospectively assessed data in an electronic database of all patients followed for varicocele in our clinic between 2006 and 2016 (**Figure 1**). Analysis was limited to young adults (age <35 years, **Figure 2**) as we considered that a change in testicular volume following treatment is less likely in patients with longstanding varicocele. An increase in testicular size is more commonly observed in young subjects, although it has also been reported in adults undergoing surgical varicocele repair [15]. Patients with right or bilateral varicocele, or with any diseases known to influence testicular volume (orchitis, testicular neoplasms, cryptorchidism, hypogonadism, genetic disorders, testicular

torsion) were excluded from the analysis. Patients who were ineligible for or who refused percutaneous treatment were excluded, as were those whose internal spermatic veins could not be accessed during the procedure and those with recurrent varicocele following treatment. Overall, 114 patients met the inclusion and follow-up criteria (**Figure 1**). The patients were followed for up to 12 months: 36 patients completed all visits (3, 6, and 12 months), while 40 and 38 patients respectively skipped one or two intermediate follow-up visits (**Table 1**). The recruitment strategy took advantage of the “*Amico Andrologo*” permanent nationwide surveillance program of male students in their final grade of high-school conducted by the Italian Society of Andrology and Sexual Medicine (SIAMS) and supported by the Italian Ministry of Health.

### *Protocol*

Since year 2004, all patients admitted to our unit for varicocele treatment have followed a fixed internal protocol. At the time of admission and at all follow-up visits (3, 6, and 12 months), patients undergo collection of medical history, physical examination, color Doppler ultrasound (US) to assess testicular volume and grade of varicocele, and blood sampling for hormone evaluation. During the first visit, after sample collection the patients undergo percutaneous treatment of their varicocele, as described below. All US examinations are performed using a Philips IU22 unit (Philips, Bothell, WA, USA) with a 7–15 MHz wideband linear transducer. Standardized protocols with axial and transverse examinations of the testes are routinely performed [16]. Testicular volume is calculated using an ellipsoid formula: length (L) x width (W) x height (H) x 0.52. Rather than using a clinical classification for varicocele, a US-based staging system [17] is used in order to provide the most information for clinicians while at the same time reducing the risk of skewness towards a higher or lower grade (see **Supplementary Table 1**).

### *Percutaneous treatment of varicocele*

All procedures were performed in an outpatient setting using a 4 Fr introducer sheath (Terumo, Tokyo, Japan) positioned in a right brachial vein. Catheterization of the left spermatic vein was performed with a standard 180 cm 0.035” standard glide-wire (Terumo, Tokyo, Japan) with a

different 4 Fr angiographic catheter (Sim1, C2, Vertebral) selected as indicated by the patient's individual anatomy. The aim of the catheterization procedure was to position the distal tip of the catheter within the internal inguinal ring. Angiography was then performed to exclude the presence of collaterals or shunting (e.g. with the ipsilateral iliac vein). Manual compression was applied to the distal inguinal channel prior to embolization to prevent distal non-target embolization. Once the target vein was completely filled with pure contrast agent, the embolization was performed by gently withdrawing the catheter while injecting a mousse of two vials of Lauromacrogol 400 1%. Manual compression was then performed to seal the brachial access.

### *Statistical analysis*

The statistical analysis was performed by R software (version 3.4.2). Numerical variables were summarized as the median [interquartile range, IQR] and mean (standard deviation, SD) as appropriate. Normal distribution of data was assessed via the Shapiro-Wilk test of normality. The left varicocele grade was expressed as absolute and percent frequency of distribution. Random intercept models were assessed with the *nlme* package to assess changes in left testicular volume during follow-up. Significance was set at  $p < 0.05$ .

## **Results**

The baseline characteristics of the caseload are presented in **Table 1**. As reported above, 26 subjects (22.81%) had LTH; there was no difference in the mean age between the LTH and no-LTH groups (total  $22.8 \pm 5.4$  years; LTH:  $22.9 \pm 4.8$  years, no LTH:  $22.8 \pm 5.6$  years,  $P=0.953$ ). Grade 3 varicocele was the most prevalent in our study population (55 subjects, 48.2%), while similar numbers of patients had grade 2 (27 subjects, 23.7%) and grade 4 (32 subjects, 28.1%) varicocele. Left testicular volumes at the baseline and during follow-up are shown in **Table 2**.

Linear mixed effect (random intercept) models were used to assess the effects of percutaneous treatment of left varicocele on left testicular volume. The response variable (i.e. left testicular volume) was normally distributed, as assessed by Shapiro-Wilk's test of normality. The first model

included left testicular hypotrophy (LTH), defined on the basis of current literature [17-19] as a baseline difference of  $\geq 20\%$  between left and right testicular volume, and its course during follow-up, in order to evaluate different growth rates between the two groups; the grade of varicocele, age at treatment and duration of follow-up were assessed as covariates. The results are shown in **Table 3**.

There was a statistically significant difference in baseline left testicular volume, which was smaller in the LTH group ( $14.5 \pm 2.7$  ml vs  $15.7 \pm 3.8$  ml,  $P=0.032$ ). No significant increase was observed in left testicular volume after treatment ( $P=0.448$ ). The grade of varicocele and age at intervention also had non-significant effects on testicular volume ( $P=0.180$  and  $P=0.506$  respectively). However, the interaction analysis showed that testicular volume increased significantly more in LTH than in non-LTH subjects ( $+0.107$  ml/month,  $P=0.035$ ).

To exclude potential bias, the model was adjusted for the baseline left testicular volume. The results of the second model are reported in **Table 4**. This model confirmed that during follow-up, testicular volume increased at a significantly higher rate in subjects with LTH than in those without LTH ( $+0.114$  ml/month,  $P=0.020$ ), independently of baseline left testicular volume. Furthermore, a significant negative effect of age was observed in the expanded model ( $-0.072$  ml/year,  $P=0.024$ ). No significant effects were observed for grade of varicocele: when stratifying, non-significant effects were confirmed for more severe degrees of varicocele (grade 3,  $P=0.604$ ; grade 4,  $P=0.955$ ). At the end of follow-up, as described in **Table 2**, the left testicular volume in the LTH group was similar to that observed in the no-LTH group (LTH:  $16.9 \pm 3.0$  ml, no LTH:  $16.5 \pm 3.1$  ml,  $P=0.565$ ) (**Figure 3**), and in fact had significantly increased since the baseline (baseline volume:  $14.5 \pm 2.7$  ml, volume at 12 months:  $16.9 \pm 3.0$  ml,  $P=0.023$ ) (**Figure 4**).

#### *Complications, failure rate and radiation exposure*

No significant complications were reported in our population following the varicocele repair. While occasional testicular pain and transitory edema were reported, these data are not mentioned in the US report and probably have no bearing on the study outcome.



When technical problems occurred during the procedure, members of the Vascular and Interventional Radiology Unit usually re-scheduled the intervention for a later date. In these cases, we considered the date of the first complete embolization as the baseline for our study. If the Radiology Unit had reasons for doubting the efficacy of re-scheduling intervention, the patient was either transferred to Urology for surgical treatment or, for more severe cases, closely monitored for clinical outcomes. These patients are listed in the flowchart as “Treatment not suggested”. Recurrence of varicocele was found in 151 of the 838 men who underwent treatment. These patients are listed in the flowchart as “Treatment failed”.

Radiation exposure was not measured directly. However, the mean duration of exposure to radiation was minimized to the extent possible (mean 6.2 minutes, range 3-9 minutes) in order to reduce the risks for the patients undergoing the procedure.

## **Discussion**

The present study is the first to provide a quantitative analysis of catch-up growth in testicular volume after percutaneous varicocele embolization in a large homogeneous cohort of young adults followed up constantly for one year after treatment.

If and when to treat varicocele is a recurring dilemma for physicians due to inconsistencies in the scientific literature, with guidelines from different scientific societies suggesting different approaches to and indications for treatment [9]. The risk of overtreatment should not be underestimated [20]. Furthermore, improvements in sperm parameters following treatment often reach statistical significance, but have little clinical relevance; sperm quality fluctuates with time and, except for those seeking immediate conception, an objective clinical result of the treatment is lacking. A surrogate marker of improved testicular function is therefore needed. As reduced testicular volume is universally accepted as an indication for treatment, we considered left testicular volume as one of the most reliable and objective parameters to be affected by left varicocele, consistently with the most recent literature [20].

Our study suggests that subjects with a difference of at least 20% between left and right testicular volume are more likely to benefit from treatment of left varicocele, with a monthly increase of 0.114 ml (95% CI: 0.018 – 0.210) during follow-up. This increase would therefore result in an almost 1.37 ml improvement over one year (95% CI 0.221 – 2.516), corresponding to an approximately 9.5% increase over the mean baseline volume. Graphical representations of the effects on left testicular volume are shown in **Figures 3 and 4**.

Our results also show that age is significantly associated with reduced left testicular volume in these patients (-0.072 ml/year,  $P=0.020$ ), possibly suggesting that early intervention should be attempted in order to prevent testicular damage. However, despite its statistical significance, whether this finding actually has any clinical bearing is a matter of debate.

Testicular hypotrophy is associated with worse outcomes in terms of sperm quality [21], and endocrine impairments have been described in subjects with varicocele [18]. The significant increase in testicular volume observed in our study warrants further investigation, as catch-up growth might offer a better view of subsequent long-term improvement in the spermatogenic function of the testes [18]. It could also have a positive psychological effect.

Most reports describe catch-up growth in children only. Ours is the first study to report an increase in testicular volume following percutaneous treatment of varicocele. Testicular hypoxia and hyperthermia, which have been described in this condition, could increase the production of reactive oxygen species; several studies suggest that oxidative stress is associated with germ cell apoptosis and is a marker of testicular dysfunction [22-26].

This study has some limitations, including its retrospective nature and absence of a control group. However, it also offers some unique advantages: just two, highly qualified clinicians performed the US in all patients, and a single centre performed all the percutaneous embolization procedures, leading to the highly consistent assessment and treatment of the caseload. In addition, the enrolled population had a relatively narrow age range (**Figure 2**) and other conditions affecting testicular volumes were excluded. As previously stated, many young adults were diagnosed with varicocele

during the “*Amico Andrologo*” permanent nationwide surveillance program for students in the last year of Italian high school.

Prospective studies assessing the effects of percutaneous varicocele repair should also consider several other features, such as number and diameter of varicose veins, changes in testicular echotexture, and circulating inflammatory markers, as any improvements in sperm parameters and endocrine function might actually be secondary, rather than a direct consequence of treatment.

## **Conclusions**

Percutaneous treatment of left varicocele leads to a significant increase in ipsilateral testicular volume, but only in subjects with a difference of at least 20% between right and left testicular volume. Whether this improved testicular size is associated with better outcomes in terms of endocrine and reproductive function remains to be established. In any case, early intervention should be suggested in order to maximize the improvement. A 12-month follow-up is recommended for all young subjects undergoing varicocele repair, as the most clinically evident effects on testicular catch-up growth take place in this period.

## Protocol #2: Endocrine and spermatogenetic function of the hypotrophic testis in varicocele patients

### Introduction

In the second part of this project, we aimed to assess whether varicocele with testicular hypotrophy had different patterns of spermatogenetic and/or endocrine function compared to varicocele controls without clinically relevant left testicular hypotrophy (LTH). We therefore queried the database from both the endocrinology and the seminology lab in order to get the necessary information for all selected patients from protocol #1.

### Materials and methods

#### *Patients*

Data from 105 patients from study population were included in analysis (92.1% of protocol #1). Once again, patients entered in the study had no other conditions affecting testicular volume.

#### *Endocrine assessment*

All endocrine parameters were assessed in a dedicated lab. Baseline blood samples were obtained from all subjects by antecubital venous puncture in the early morning (7.30-9.00 a.m.) after an overnight fast. Samples were centrifuged after 30' and the serum immediately frozen at -20°C.

FSH, LH, estradiol (E2) and testosterone (T) were measured in duplicate with chemiluminescent microparticle immunoassay (CMIA, Architect System; Abbott Laboratories, IL, USA) with limits of detection (LOD) of 0.05 mIU/mL, 0.07 mIU/mL,  $\leq 10$  pg/mL and 0.28 nmol/L respectively. Intra- and inter-assay coefficients of variation for our laboratory were: 3.6% and 5.4% at 3.2 mIU/mL (FSH); 3.8 and 5.5% at 4.1 mIU/mL (LH); 5% and 7% at 190 and 600 pg/mL (E2); 2.1% and 3.6% at 10.08 nmol/L (T). Serum concentrations of inhibin B were measured by enzyme-linked

immunosorbent assay (ELISA) (GEN II, Beckman Coulter laboratories, USA) with LOD of 7.0 pg/mL, while intra- and inter-assay coefficients of variation were 3.3 % and 7.2 % at 122 pg/mL.

### *Semen analysis*

Semen samples were examined by light microscope according to the most recent World Health Organization criteria in a high-specialization seminology lab. The fifth edition of the WHO guidelines, published in 2010, has been used since its introduction; previously, semen analysis was performed following the indications from the fourth edition, published in 1999. Semen samples were collected by masturbation directly into a sterile plastic container after 2–7 days of sexual abstinence. The following variables were taken into consideration: volume (mL), sperm concentration (n/mL), total sperm number ( $n \times 10^6$ /ejaculate), progressive motility (%) and morphology (% abnormal forms).

### *Statistical analysis*

Statistical analysis was performed by R software (version 3.4.2). Numerical variables were summarized as the median [interquartile range, IQR] and mean (standard deviation, SD) as appropriate. Normal distribution of data was assessed via the Shapiro-Wilk test of normality. Welch two sample t-test was used for assessment of the difference between means of the two groups. Robust linear regression models were used for assessment of the estimates of all relevant covariates, as by results of protocol #1.

## **Results**

105 subjects were entered in the analysis, among which left testicular hypotrophy was found in 24 men (22.86%). Baseline characteristics of all subjects are listed in **Table 5**. No significant difference was observed in regards to the age of the two groups ( $t = -0.46989$ ,  $df = 37.754$ ,  $p\text{-value} = 0.6411$ ) and in regards to the distribution of different grades of varicocele ( $X\text{-squared} = 0.075617$ ,  $df = 2$ ,  $p\text{-value} = 0.9629$ ). Considering our previous findings in regards to the effects of isolated left testicular hypotrophy  $\geq 20\%$  (LTH) on volume recovery, we hypothesized a role of this parameter in

endocrine and spermatogenetic function of the testis as well. In a two-step approach, we first measured whether LTH had a direct effect on several endocrine parameters related to testicular function – namely, FSH, LH, E2, T and inhibin B – and on standard parameters of semen analysis via Welch two sample t-test; we then performed robust linear regression models in order to reliably perform multivariable analysis on possible confounders.

Results of the direct comparisons between groups are detailed in **Table 6**. In short, no significant effect of LTH was observed on any parameters, except for serum inhibin B ( $P=0.0493$ ) which was significantly higher in subjects without LTH (mean  $149.51 \pm 71.7$  pg/mL) than in subjects with LTH (mean  $122.76 \pm 43.2$  pg/mL).

Robust linear regression models were used for multivariate analysis in order to circumvent possible bias resulting from skewness of the data. While in protocol #1 this bias was prevented by the repeated measures design, in the present study robust methods were required for non-normally distributed response variables. Results from all models are reported in **Tables 7 to 16**.

No significant effects were observed for age at intervention, baseline left testicular volume and presence of LTH in regards to semen volume (**Table 7**), total sperm concentration (**Table 9**), atypical morphology (**Table 11**), FSH (**Table 12**), LH (**Table 13**), total T (**Table 15**) and E2 (**Table 16**).

Presence of LTH and its interaction terms with baseline left testicular volume had significant effects in the model for sperm concentration per milliliter (**Table 8**): presence of LTH had a statistically significant markedly negative coefficient ( $\beta = -132.676 \pm 54.878$ ,  $P=0.0233$ ), which was “balanced” by its interaction terms with baseline left testicular volume ( $\beta = 10.832 \pm 3.802$ ,  $P=0.0082$ ).

Age at intervention had statistically significant effects on progressive motility ( $\beta = -0.628 \pm 0.23$ ,  $P=0.0075$ ), although this finding doubtfully has any clinical relevance. Furthermore, neither direct, nor indirect effects of LTH reached statistical significance in this model (**Table 10**).

Serum inhibin B levels were positively associated with baseline left testicular volume ( $\beta = 6.342$ ,  $P=0.0003$ ), although no direct or indirect significant effects of LTH were observed in these regards (**Table 14**).

Despite not reaching statistical significance, it is worth noting that negative coefficients were found in statistical modeling for all semen parameters – except, as predictable, the prevalence of atypical morphologies, which showed a positive coefficient.

An expanded robust linear regression model (**Table 17**) with FSH as an outcome variable including age at intervention, inhibin B, baseline left testicular volume and presence of LTH found significant negative effects for inhibin B ( $\beta = -0.005 \pm 0.002$ ,  $P=0.0273$ ), with LTH showing positive, yet non-significant coefficients ( $\beta = 0.537 \pm 1.651$ ,  $P=0.0273$ ).

## Discussion

Our results suggest that in subjects with isolated left varicocele the presence of a severe testicular hypotrophy ( $\geq 20\%$ ) is likely to have marginal effects on *a priori* testicular function.

Among semen parameters, LTH had significant negative effects on sperm concentration per milliliter only, and these effects are actually balanced by baseline left testicular volume, suggesting that higher testicular volume is enough to compensate for the concentration loss. In all other models, LTH failed to reach statistical significance; however, regression coefficients hint at a worsening effect of hypotrophy on all semen parameters. Studies with bigger sample size are much needed in these regards.

These findings might be important in the clinical setting. Presence of severe hypotrophy is easily assessable, even without performing ultrasound imaging. Measurements performed by using the Prader orchidometry usually overestimate testicular volume in comparison to ultrasound [27-29]; however, the difference between left and right testis is easily identifiable with clinical examination, and could then be confirmed by ultrasound examination. It has been hypothesized that improvements in sperm parameters might occur in patients with testicular asymmetry only [30].

Concerning endocrine correlates of subjects with isolated left varicocele, we only found a significant effect for baseline volume in determining serum inhibin levels. Given the delicate balance of the hypothalamic-pituitary-gonadal (HPG) axis, these findings require careful interpretation. First and foremost, it should be considered that T, the main endocrine product of the testes, is secreted by interstitial Leydig cells, which are much more resistant to external stressors than germ cells [31]. In males, E2 originates from peripheral aromatization of T, particularly in adipose tissue [32]. Several substances might influence the aromatization rates in peripheral tissues, such as isoflavones and aromatase inhibitors [33]. Inhibin B is secreted by mature Sertoli cells independently of the HPG axis: it is therefore a reliable marker of testicular damage in regards to fertility outcomes [34]. FSH and LH are produced by the pituitary gland under direct stimulus from the hypothalamus: pulsatile release of gonadotropin-releasing hormone (GnRH) from GnRH neurons controls the rate of secretion of both gonadotropins, allowing for fine tuning in their secretion. As it is commonplace in endocrine axes, a finely-regulated feedback system allows negative control on the secretion of gonadotropins at both the hypothalamic and pituitary levels [35]. In these regards, inhibin B seems to be the most important feedback regulator of FSH secretion [36], although T and E2 also regulate secretion by the hypothalamus [35]. Furthermore, single nucleotide polymorphisms (SNPs) of the FSH-R and FSH-B gene, respectively encoding the FSH receptor and for the FSH subunit beta, might lead to different phenotypes of gene expression, ultimately affecting testicular size and function [37]. Increased levels of FSH might therefore mirror reduced susceptibility to endogenous control or be a consequence of impaired secretion of other hormones, such as inhibin B, as an additional stimulus for induction and maintenance of spermatogenesis. In our study, subjects with LTH had lower mean levels of inhibin B, although FSH levels were not significantly different; furthermore, in the regression model detailed in **Table 12**, the effects for baseline left testicular volume, LTH, and their interaction failed to reach statistical significance when considering serum FSH as the outcome variable. The expanded model including inhibin B as an additional variable (**Table 17**) showed its significant negative effects on



serum FSH, suggesting that the feedback mechanism is preserved in our study population. It is therefore possible that administration of exogenous FSH might further stimulate maturation of Sertoli cells, improving outcomes independently of varicocele repair. Other markers of testicular maturation, such as INSL3 and AMH, might be helpful to understand the exact mechanisms involved in this complex interaction, as de-differentiation or impaired maturation of Sertoli cells might actually provide additional clues to how varicocele impairs testicular functioning.

## **Conclusions**

There are minor differences in regards to the endocrine and spermatogenetic testicular function of subjects with and without LTH at baseline. The most important finding is undoubtedly the difference between serum inhibin B between the two groups: inhibin B is a marker of Sertoli cell maturation status, and a significant reduction in its serum concentration is a surrogate marker of de-differentiation or impaired maturation of Sertoli cells. Evidence from literature also suggest that inhibin B levels increase following varicocele repair, once again hinting at functional recovery of Sertoli cells. Based on these findings, we can hypothesize that administration of exogenous FSH might stimulate maturation of Sertoli cells, therefore improving spermatogenesis.

Protocol #3: Effects of percutaneous treatment of left varicocele on spermatogenetic and endocrine function of the testis: results from a 12-month follow-up.

## **Introduction**

In the third part of this project, we aimed to assess whether treatment of isolated left varicocele was associated with significant improvements in regards to both spermatogenetic and/or endocrine function of the testis, additionally distinguishing between subjects with and without (LTH). We therefore queried the database from both the endocrinology and the seminology lab in order to get the necessary information for all selected patients from protocol #1. No data were collected in regards to actual fertility of patients – i.e. no data were entered in the database in regards to actual live births in the couple. This is unsurprising, given the young age of most subjects undergoing treatment for varicocele. Therefore, sperm parameters were considered as the most viable surrogate marker for male fertility.

## **Materials and methods**

### *Patients*

Only subjects with a complete assessment at baseline and at the end of follow-up (12-14 months after treatment) were selected for more reliable comparisons. Therefore, 77 subjects from protocol #1 were entered into data analysis (67.6%). Once again, patients entered in the study had no other conditions affecting testicular volume.

### *Percutaneous treatment of varicocele.*

See Protocol #1.

### *Endocrine assessment*

See Protocol #2.

### *Semen analysis*

See protocol #2.

### *Statistical analysis*

Statistical analysis was performed by R software (version 3.4.2). Numerical variables were summarized as the median [interquartile range, IQR] and mean (standard deviation, SD) as appropriate. Normal distribution of data was assessed via the Shapiro-Wilk test of normality. Welch two sample t-test was used for assessment of the difference between means of the two groups. Robust linear mixed effect (random intercept) regression models were used for assessment of the estimates of all relevant covariates, as by results of protocol #1, with each subjects acting as his own control as to reduce bias.

## **Results**

In the two-step analysis previously described in Protocol #2, we performed direct comparisons between all relevant variables at baseline and at the end of follow-up before switching to more complex statistical analysis.

Among the 77 subjects in the study population, 19 had LTH (24.7%). No significant difference was observed concerning age (LTH: 23.9±5.1 years, no LTH: 23.1±5.3 years, p-value = 0.55) and distribution of varicocele grades ( $X^2= 0.242$ ,  $df = 2$ , p-value = 0.886) before intervention. In a direct comparison between endocrine and sperm parameters, only inhibin B showed significant changes between baseline and end of follow-up (**Table 18**). The same findings were confirmed when repeating the same analysis in both study groups (LTH and no-LTH; data not shown).

Statistical modeling was then performed for all relevant parameters. All models included correction for the baseline values of the outcome variable, as well as the presence of LTH and the change in volume (as per results of Protocol #1); furthermore, despite the lack of significant effects on testicular volume, we also included grade of left varicocele based on current literature.

Baseline values of all the outcome variables showed, as expected, significant effects on the models (**Tables 19-29**).

The presence of LTH was significantly associated with greater increase in regards to progressive sperm motility ( $\beta = 7.458 \pm 2.672$ ,  $P=0.007$ ), suggesting that varicocele repair is more likely to produce better outcomes in regards to sperm motility in subjects with LTH (**Table 22**).

A significant effect of varicocele grade was observed in the model for atypical morphology (**Table 23**). Both grade 3 ( $\beta = -3.721 \pm 1.604$ ,  $P=0.024$ ) and grade 4 ( $\beta = -3.644 \pm 1.82$ ,  $P=0.035$ ) varicocele had negative effects on the percentage of spermatozoa with atypical morphology – in other words, varicocele repair yielded better outcomes in subjects with higher degrees of varicocele. Statistical modeling (**Table 24**) showed a statistically significant effect of age on serum FSH ( $\beta = 0.163 \pm 0.044$ ,  $P=0.001$ ), and a trend for the effects of increasingly severe grades of varicocele which reached statistical significance for grade 4 only ( $\beta = 1.181 \pm 0.508$ ,  $P=0.025$ ).

No significant effects of any variable, except for baseline value of the outcome variable, were observed for serum LH, T and E2.

No significant effects were found in the base model for serum inhibin (**Table 26**); however, following to our results in Protocol #2, we designed a different model, including changes in serum FSH as an additional variable (**Table 27**). In this expanded model, we observed a significant effect of the increase in serum FSH ( $\beta = 34.2 \pm 11.749$ ,  $P=0.008$ ), although no other effect reached statistical significance.

## Discussion

Our results point out that treatment of isolated left varicocele leads to better outcomes in regards to the endocrine and spermatogenetic function of the testis. The effects of varicocele repair on sperm morphology and in sperm motility are highly significant, although whether they have any clinical bearing is a question largely left unanswered. Varicocele treatment is perhaps the most controversial topic in the history of male infertility [38], as the most important outcomes – pregnancy rates and

live births – are rarely investigated, due to the young age of the population affected. Furthermore, the high variability of semen analysis and the chance of spontaneous pregnancies are so high that skepticism persists in regards to many treatments [38]. In these regards, we strongly believe that while direct effects on male fertility are difficult to assess, several surrogate parameters allow for more precise estimate of the effects of varicocele repair on testicular pathophysiology. In Protocol #2 we reported the interaction between FSH and E2, both in the general physiology of the HPG axis and in our our statistical models; results from Protocol #3 provide further proof of the fine interplay mediated by Sertoli cells via production of inhibin B. In fact, during follow-up, a significant increase in inhibin B occurs, with a significant positive effect of FSH on the model: this hints at a possible effect of FSH on Sertoli cell maturation, ultimately resulting in increased inhibin B levels. This finding is consistent with other reports in literature [39-41] describing the effects of varicocele and varicocele repair on production of inhibin B.

It is likely, although our results do not allow for conclusive remarks in this direction, that serum inhibin B might be a reliable marker of the residual activity of the testes. It is possible to assume that subjects with “healthy” concentrations of inhibin B have adequately achieved Sertoli cell maturation, whereas those with low or low-normal concentration might have further benefit from varicocele repair. FSH is at the same time the stimulus for Sertoli cell maturation, and a marker for germ cell failure: a rapid increase in serum FSH following treatment, when associated with an increase in testicular volume, hints at an enhanced response from the HPG axis. Once again, studies aimed at assessing the maturation status of Sertoli cells in different grades of varicocele might allow more solid conclusions in these regards.

The small sample size of the study population is an important limitation to this study. However, both the endocrinology and the seminology labs are highly specialized, therefore providing reliable results; likewise, as stated in Protocol #1, there is little risk of interobserver variation, as all ultrasound exams were performed by just two, highly qualified clinicians.

## Conclusions

In subjects with isolated left varicocele, percutaneous treatment does not dramatically change fertility outcomes, despite some minor, yet statistically significant improvements in some surrogate markers. However, our study highlighted how inhibin B levels are affected by varicocele; this is most likely the result of a persisting insult to the Sertoli cell population, as demonstrated by the sudden increase in inhibin B during follow-up. Furthermore, during follow-up, positive effects of serum FSH are observed on serum inhibin B, suggesting that the rapid increase in FSH levels observed in more severe forms of varicocele might actually be a stimulus, rather than a marker of testicular failure.

## Protocol #4: AMH and INSL3 as markers of testicular maturation status and their role in testicular and systemic conditions.

### Introduction

Testicular functions include spermatogenesis and hormone production – both largely dependent on the integrity of the hypothalamic-pituitary-gonadal (HPG) function and of the testis itself. It is textbook knowledge that GnRH is secreted by hypothalamic GnRH-secreting neurons into the hypophyseal portal circulation; from here, GnRH reaches the anterior pituitary, where it induces release of the two gonadotropins LH and FSH by binding to its receptor on the surface of gonadotrope cells [42]. Secretion of GnRH is pulsatile: frequency and amplitude of each pulse affect the pituitary response, and change dramatically during life [42]. In males, FSH and LH act on specific receptors predominantly expressed in the testis: receptors for FSH are mostly expressed by Sertoli cells, whereas Leydig cells express LH receptors. The binding of LH to its receptor on Leydig cells induces T synthesis by increased activity of the desmolase enzyme [43]; similarly, FSH binds to its receptor on Sertoli cells, activating several pathways ultimately needed for supporting spermatogenesis [44-46]. An intra-testicular paracrine role has been clearly identified for T, suggesting that its binding to the androgen receptor is the key stimulus for successful spermatogenesis[47]. On the contrary, the role of FSH has been somewhat questioned in the last few years: studies in men with polymorphisms in the genes for either the  $\beta$  chain of the FSH molecule (*FSHB*) or the FSH receptor (*FSHR*) have shown that clinical phenotypes may differ, ranging from azoospermia [48] to normal sperm counts [37]. A different approach to the hormonal regulation of spermatogenesis seems to suggest that in mammals, as a result of evolutionary changes, FSH is acting as an anti-apoptotic factor, rather than a proliferative signal for Sertoli cells[47].

Germ cells do not express receptors for either FSH or androgens, therefore suggesting that the effect on spermatogenesis is mediated through Sertoli cells via production of other hormones acting in a paracrine, autocrine or endocrine fashion. Sertoli cells express the androgen receptor (AR) and it is well-established that adequate levels of intratesticular T are required for successful spermatogenesis. Sertoli cells also express the receptor for AMH (AMHR-II): however, these receptors have also been found in Leydig cells of the human testis [49], suggesting a more complex interplay between the two cellular populations.

## AMH

### *Regulation of AMH expression*

Anti-Müllerian hormone (AMH), previously described as Müllerian inhibiting substance, is a 140 kD homodimeric disulfide-linked glycoprotein belonging to the TGF- $\beta$  superfamily [50] and secreted in males by Sertoli cells. Expression of AMH is largely dependent on the maturation status of Sertoli cells, as shown by the changes in AMH concentration during fetal life, before puberty and in adults. Sertoli cells produce high quantities of AMH during fetal life, but undergo dramatic changes in both their structure and function approaching puberty, when they ultimately shift their pattern of protein expression and establish tight junctions. In the fetal male gonad, SOX9 acts as a trigger for expression, which is then regulated by different factors including SF1, WT1 and FSH [51], independently of FSH and LH. At a later stage of gestation, FSH induces production of AMH by immature Sertoli cells. Following birth, AMH concentrations mirror the delicate balance between the stimulating effects of FSH and the inhibiting effects of T. During puberty, the increasing levels of intra-testicular T inhibit AMH secretion, possibly by inducing maturation of Sertoli cells rather than by direct action. The maturation process throughout pubertal development is accompanied by morphological changes of Sertoli cells and reflected by distinct changes in histoskeleton architecture identified by immunohistochemical markers [52-54]. Once Sertoli cells reach their maturation serum concentrations of AMH undergo a rapid decline; however, AMH is



preferentially released in the seminiferous tubules, where it reaches far greater concentrations than in the serum [55]. The AMH exerts its function on the target tissues by binding to its receptor (AMHR-II), which is expressed on Sertoli and Leydig cells, as well as on the paramesonephric ducts[55].

In females, AMH is produced by granulosa cells of the preantral and small antral follicles and is therefore detectable in serum only before menopause. Inconsistent findings have emerged from studies investigating the effects of conditions such as vitamin D deficiency, obesity and smoking on AMH secretion[56]. Several studies have shown a direct effect of AMH in the pathogenesis of polycystic ovary syndrome (PCOS) [57] and effects on the progeny of AMH-treated mice have been recently elucidated, suggesting a possible mechanism of trans-generational transmission [58].

#### *AMH in testicular pathophysiology*

In the early stages of fetal life, the interaction between AMH and its receptor induces a change in the morphology of the Müllerian duct mesenchyme, ultimately resulting in apoptosis in the cells of paramesonephric ducts and regression of internal female genitalia (Müllerian ducts, uterus, fallopian tubes and upper vagina) [59, 60]. At the same time, T stimulates differentiation of the Wolffian ducts into vas deferens, epididymis and seminal vesicles. It should be therefore expected that AMH is among the key hormones involved in sex differentiation: mutations in either AMH or AMHR-II result in a rare condition defined Persistent Müllerian Duct Syndrome (PMDS), in which derivatives of Müllerian ducts are seen in phenotypically normal 46,XY male subjects. This condition is the result of masculinizing effects from endogenous T, which affects Wolffian ducts, and absent pro-apoptotic effects on the Müllerian ducts.

Measurement of AMH might be helpful in discerning bilateral cryptorchidism from anorchia. In fact, as Sertoli and granulosa cells are the only source of AMH, pre-pubertal females should have undetectable AMH levels; therefore, measurable concentrations of AMH are strongly suggestive of the presence of testicular tissue. Likewise, serum AMH is a valid and reliable tool for differential diagnosis between congenital hypogonadotropic hypogonadism and constitutional delay in growth

and puberty [61]. In the pre-pubertal testis Sertoli cells are the most prevalent and the most active cell population [13], and as such markers of their development are more reliable than those associated with Leydig cell function [62]. Subjects with delayed puberty show normal AMH levels for their age, while patients with congenital hypogonadotropic hypogonadism have markedly reduced AMH as a result of impaired development of Sertoli cells [63].

In Klinefelter patients, normal levels of serum AMH, inhibin B and FSH are observed until late puberty [13, 64], with a subsequent decline possibly from hyalinization of seminiferous tubules. In these subjects, chances of sperm retrieval via mTESE (microdissection testicular sperm extraction) are largely dependent on spermatogenetic maturity – therefore suggesting that markers of Leydig cell development, as well as age, should be considered more reliable predictors than AMH and Inhibin B [65].

Exogenous FSH administration, as currently used in the treatment of infertile males, is associated with an increase in serum AMH [66], possibly as a result of enhanced gonadal function. However, hCG administration inhibits AMH secretion from Sertoli cells, whether alone or in combination with FSH [67, 68]. This effect is possibly the result of the increased intra-testicular concentration of T due to hCG, and fits nicely with evidence suggesting that priming with FSH improves testicular function [69-71].

Serum AMH is positively correlated with testicular volume and negatively correlated with serum FSH, but only in men with history of testicular maldescent [72], possibly proving the presence of persisting damage and functional de-differentiation of Sertoli cells [73]. Several reports suggest lower levels of AMH in children with bilateral or unilateral cryptorchidism [61, 74], providing further confirmation of this theory; similarly, testicular dysgenesis syndrome has been associated with disruption in Sertoli cell maturation, a phenomenon which might contribute to the functional impairment of the Sertoli cell and therefore to reduced AMH secretion [75].

Modifications of Sertoli cell structure and patterns of protein expression in most forms of cancer also provide an explanation in regards to the changes in serum AMH detectable in patients with

testicular tumors [13, 76]. So far, however, AMH is most commonly recognized as a marker for granulosa cell tumors of the ovary [77, 78], and most recent reports concerning its validity in the diagnosis of Sertoli cell tumors mostly come from animal models [79, 80]. New findings also suggest a possible role for serum AMH and the AMH-to-T ratio as independent predictor biomarkers for successful sperm retrieval at microTESE [81].

Few studies have assessed the relationship between varicocele and AMH. A single study [82] found increased serum AMH levels in adolescent males with varicocele compared to healthy controls, whereas another study on adult men found no significant difference compared to controls in regards to serum AMH, but found lower concentration of AMH in the spermatic veins of varicocele patients [83]. While more solid evidence concerning decreased inhibin B in patients with varicocele suggests a negative effect on Sertoli cell development, the paucity of studies on the association between AMH and varicocele does not allow drawing conclusions in these regards.

## **INSL3**

### *Regulation of INSL3 expression*

INSL3 is a “neohormone” – i.e., an adaptation of the endocrine system, stemming from the increasingly complex regulations of reproduction resulting from evolution [84]. Production of INSL3 occurs exclusively in mammalian Leydig cells: in fact, INSL3 is undetectable in anorchid men [85, 86]. INSL3 is constitutively secreted by Leydig cells without direct acute regulation by the HPG axis, therefore being a marker of Leydig cell function and differentiation status [87]. It is therefore unsurprising that INSL3 expression closely mirrors the patterns of Leydig cell activity and population size, with a transient increase during fetal life, a second peak occurring roughly 3 months after birth (“mini-puberty”) and a third increase during puberty [88], which ultimately leads to persisting high concentrations during adult life [85] with a slight reduction in older age [89]. Although acute regulation of the HPG axis is not involved in INSL3 expression, it should be noted that LH stimulation is needed for Leydig cells differentiation and measurable levels of INSL3 after

pubertal development: further proof of this comes from treatment of congenital hypogonadotropic hypogonadism, as men undergoing testosterone replacement treatment (TRT) show undetectable INSL3 levels whereas a significant increase in INSL3 is observed in patients treated with hCG [90]. As the differentiating effect of LH on the Leydig cell is conserved during adult life as well, reduced INSL3 levels are observed following suppression of the HPG axis [91]. Autocrine and paracrine factors have also been considered in the regulation of INSL3 expression: T and E2 possibly regulate transcription of the *INSL3* gene by binding to their receptors, respectively stimulating and inhibiting the transcription factors SF1 and NUR77 [85, 92].

### *INSL3 in testicular pathophysiology*

INSL3 binds to its receptor RXFP2, mainly expressed on germ cells and Leydig cells. There is solid evidence supporting a role for INSL3 in the transabdominal phase of testicular descent [85], as cells of the gubernacular bulb express RXFP2; when INSL3 binds to RXFP2, the following cascade of events in the cell causes thickening of the bulb, effectively “anchoring” the testis in the inguinal region, next to the abdominal wall [85]. The following phases of testicular descent likely require both INSL3/RXFP2 and T/AR interaction [93]. Mutations in the *INSL3* or *RXFP2* genes are associated with cryptorchidism, but they only account for a small percentage of cases[94].

### **Beyond reproduction: extra-gonadal pathophysiology of AMH and INSL3**

AMH has been largely considered in recent times as a valid marker for ovarian reserve [95], whereas no function has been attributed to it in adult males despite detectable serum levels. Some reports have suggested a possible role for AMH in cardiovascular prevention in elderly men [96, 97], as well as in Klinefelter pre-pubertal boys [98] and in premenopausal women [99]: these results require further confirmation, but are plausible given that AMH has been identified as a potent regulator of TGF- $\beta$ /BMP signaling [100], which is in turn involved in vascular development [101, 102].

The most known function of INSL3, as previously stated, involves testicular descent. However, the expression of INSL3 occurs throughout all adult life – therefore suggesting that INSL3 might actually be involved in other conditions. Further proof of an endocrine role for INSL comes from identification of RXFP2 in several other organs, including thyroid, seminal vesicles, kidney, brain and bone marrow.

It has been hypothesized that some of the defining features of male hypogonadism might actually be the result of reduced INSL3 levels, or at least that low INSL3 might contribute to signs and symptoms of male hypogonadism, such as muscle wasting [103, 104]. Impaired bone mineral density was the first clinical finding described in association with inactivating mutations in the humans [105]. This hypothesis seemed valid, considering the common origin of both T and INSL3 – the Leydig cell – and the identification of RXFP2 on osteoblasts: following studies confirmed a role for INSL3 in bone remodeling, as receptor activation stimulates osteoblast proliferation and bone anabolic activity while at the same time influencing osteoclastogenesis [103]. Furthermore, lower levels of INSL3 have been described in Klinefelter patients compared to healthy controls [106, 107] and negatively correlated with sclerostin, an osteocyte-specific protein with anti-anabolic effects on bone formation.

INSL3 has proven useful as a surrogate marker of endocrine disruption. Studies in rodent models have proven downregulation of *Insl3* gene expression in the fetal testis following administration of diethylstilbestrol (DES) to pregnant mice [108]. This finding corroborates the clinical finding that associated cryptorchidism with administration of DES to pregnant mothers (“blacklisted” by the FDA in the early 1970s, but widely used before that).

## Conclusions

It is currently clear that Leydig and Sertoli cells are able to influence the endocrine milieu of the testes by several pathways (**Figure 5**) and affecting also exocrine testicular function. In these regards, functions of AMH and INSL3 are only beginning to emerge. It is accepted that both

hormones are involved in sexual differentiation: mutations of AMH or its receptor lead to persistence of the Müllerian duct, whereas reduction in INSL3 levels account for a small, but relevant, percentage of cases of cryptorchidism. So far, INSL3 and AMH have prevalently been considered for differential diagnosis as reliable markers of maturation of Leydig and Sertoli cells (**Table 30**). The role of both INSL3 and AMH in several conditions, such as varicocele, has only marginally been hinted at. Furthermore, effects of AMH and INSL3 extend beyond gonadal range: symptoms of male hypogonadism have been often associated with decline in serum INSL3 levels, and reduced AMH concentrations have been correlated with worse cardiovascular conditions.

## Tables and figures

**Table 1.** Demographics of the study population for protocol #1.

	<b>Total</b>	<b>LTH: No</b>	<b>LTH: Yes</b>
<b>N</b>	114	88	26
<b>Age (years)</b>			
Median [IQR]	20.5 [19-27.5]	20.5 [19-28]	20.5 [20-25.2]
Mean (SD)	22.8 (5.4)	22.8 (5.6)	22.9 (4.8)
<b>Grade of left varicocele</b>			
Grade 2	27 (23.7%)	20 (22.7%)	7 (26.9%)
Grade 3	55 (48.2%)	42 (47.7%)	13 (50%)
Grade 4	32 (28.1%)	26 (29.6%)	6 (23.1%)

§Left testicular hypotrophy (>20% difference between left and right testicular volume)

**Table 2.** Left testicular volume in mL as assessed by testicular ultrasound at baseline and during follow-up.

	<b>Total</b>	<b>§LTH: No</b>	<b>§LTH: Yes</b>
<b>Baseline (n=114)</b>			
Mean (SD)	15.4 (3.6)	15.7 (3.8)	14.5 (2.7)
<b>3 months (n=91)</b>			
Mean (SD)	15.9 (3.2)	16.2 (3.4)	14.9 (2.3)
<b>6 months (n=82)</b>			
Mean (SD)	16.9 (3.8)	17.2 (3.8)	15.0 (2.6)
<b>12 months (n=69)</b>			
Mean (SD)	16.6 (3.0)	16.5 (3.1)	16.9 (3.0)

§Left testicular hypotrophy (>20% difference between left and right testicular volume)

**Table 3.** Random intercept model for testicular volume increase.

	$\beta$	<i>P</i>
<i>(Intercept)</i>	11.657	<0.001
Age (years)	0.039	0.506
Grade of left varicocele	1.210	0.180
LTH <sup>§</sup> (yes)	-1.388	0.088
Time (months)	-0.018	0.448
LTH <sup>§</sup> (yes): Time (months)	0.107	0.035

<sup>§</sup>Left testicular hypotrophy (>20% difference between left and right testicular volume)

**Table 4.** Expanded random intercept model for testicular volume increase.

	$\beta$	<i>P</i>
<i>(Intercept)</i>	5.908	<0.001
Baseline left testicular volume (ml)	0.784	<0.001
Age (years)	-0.072	<b>0.024</b>
Grade of left varicocele		
Grade 2	Ref.	
Grade 3	-0.216	0.604
Grade 4	0.027	0.955
LTH <sup>§</sup> (yes)	-0.426	0.409
Time (months)	-0.020	0.395
LTH <sup>§</sup> (yes): Time (months)	0.114	<b>0.020</b>

<sup>§</sup>Left testicular hypotrophy (>20% difference between left and right testicular volume)



**Table 5.** Baseline characteristics of subjects included in protocol #2. Data entered as median [IQR] or mean (SD) as appropriate.

	<b>Study population</b>
<b>N</b>	105
<b>Age (years)</b>	
Median [IQR]	20 [19 – 28]
Mean (SD)	22.8 (5.427)
<b>Grade of left varicocele</b>	
Grade 2	27 (25.7%)
Grade 3	50 (47.6%)
Grade 4	28 (26.7%)
<b>Semen analysis</b>	
Volume (ml)	3.20 [2.5 – 4]
pH	7.40 [7.30 – 7.50]
Sperm concentration per ml (x10 <sup>6</sup> )	56.5 [30 – 81.2]
Total sperm concentration (x10 <sup>6</sup> )	180.8 [98.1 – 272.2]
Progressive motility (%)	50 [40 – 55]
Atypical morphology (%)	79.5 [76 – 85]
<b>Endocrine parameters</b>	
FSH (mIU/mL)	2.76 [2.07 – 3.91]
LH (mIU/mL)	3.08 [2.48 – 4.03]
E2 (pg/mL)	27.1 [21.2 – 33.0]
Inhibin B (pg/mL)	144 [106 – 176]
Total testosterone (nmol/L)	22.4 [18.6 – 26.4]

**Table 6.** Subjects included in protocol #2: comparison between baseline parameters of testicular endocrine and spermatogenetic function. Welch two sample t-test used for numeric variables; Pearson’s chi-squared test used for categorical variables.

	<b>LTH<sup>§</sup>: No</b>	<b>LTH<sup>§</sup>: Yes</b>	<b>P</b>
<b>N</b>	81	24	
<b>Age (years)</b>			
Median [IQR]	20 [19 – 28]	20 [19 – 26.8]	
Mean (SD)	22.8 (5.58)	23.0 (4.98)	0.6411
<b>Grade of left varicocele</b>			
Grade 2	21 (25.9%)	6 (25%)	
Grade 3	38 (46.9%)	12 (50%)	0.9629
Grade 4	22 (27.2%)	6 (25%)	
<b>Semen analysis</b>			
Volume (ml)	3.35 [2.5 – 4.0]	3.05 [2.65 – 3.4]	0.0804
pH	7.40 [7.40 – 7.50]	7.35 [7.3 – 7.47]	0.0504
Sperm concentration per ml (x10 <sup>6</sup> )	53.5 [30.5 – 77.8]	68.5 [31 – 110]	0.1895
Total sperm concentration (x10 <sup>6</sup> )	173 [92.4 – 270.7]	204 [113.2 – 321.1]	0.3529
Progressive motility (%)	50 [40 – 55]	50 [40 – 55]	0.8562
Atypical morphology (%)	80 [76.5 – 85]	78.5 [74 – 85.8]	0.7417
<b>Endocrine parameters</b>			
FSH (mIU/mL)	2.87 [2.05 – 3.93]	2.58 [2.13 – 3.48]	0.7838
LH (mIU/mL)	3.00 [2.39 – 3.60]	3.23 [2.73 – 4.84]	0.1795
E2 (pg/mL)	27.0 [21.5 – 31.0]	31 [19.5 – 38.5]	0.2934
Inhibin B (pg/mL)	148 [110.5 – 187.2]	127 [105 – 147.5]	<b>0.0493</b>
Total testosterone (nmol/L)	21.5 [18.3 – 26.2]	23.8 [21.9 – 26.9]	0.4318

<sup>§</sup>Left testicular hypotrophy (>20% difference between left and right testicular volume)

**Table 7.** Robust linear regression model for semen volume at baseline.

	$\beta$	SE	<i>P</i>
<i>(Intercept)</i>	2.923	0.818	0.0005
Baseline left testicular volume (ml)	0.032	0.041	0.4475
LTH <sup>§</sup> (yes)	-0.119	1.69	0.9429
Age at intervention (years)	-0.004	0.024	0.8536
LTH <sup>§</sup> (yes): baseline left testicular volume (ml)	-0.005	0.117	0.9655

<sup>§</sup>Left testicular hypotrophy (>20% difference between left and right testicular volume)

**Table 8.** Robust linear regression model for sperm concentration (per ml) at baseline.

	$\beta$	SE	<i>P</i>
<i>(Intercept)</i>	62.724	26.548	0.0208
Baseline left testicular volume (ml)	0.681	1.335	0.6111
LTH <sup>§</sup> (yes)	-132.676	54.878	<b>0.0233</b>
Age at intervention (years)	-0.804	0.775	0.2979
LTH <sup>§</sup> (yes): baseline left testicular volume (ml)	10.832	3.802	<b>0.0082</b>

<sup>§</sup>Left testicular hypotrophy (>20% difference between left and right testicular volume)

**Table 9.** Robust linear regression model for total sperm concentration at baseline.

	$\beta$	SE	<i>P</i>
<i>(Intercept)</i>	177.751	83.641	0.0402
Baseline left testicular volume (ml)	4.216	4.206	0.3276
LTH <sup>§</sup> (yes)	-287.389	172.893	0.1022
Age at intervention (years)	-2.683	2.443	0.2726
LTH <sup>§</sup> (yes): baseline left testicular volume (ml)	23.802	11.979	0.0512

<sup>§</sup>Left testicular hypotrophy (>20% difference between left and right testicular volume)

**Table 10.** Robust linear regression model for progressive motility at baseline.

	$\beta$	SE	<i>P</i>
<i>(Intercept)</i>	56.969	7.828	0.0001
Baseline left testicular volume (ml)	0.237	0.393	0.5473
LTH <sup>§</sup> (yes)	-14.136	16.152	0.387
Age at intervention (years)	-0.628	0.23	<b>0.0075</b>
LTH <sup>§</sup> (yes): baseline left testicular volume (ml)	1.048	1.122	0.3545

<sup>§</sup>Left testicular hypotrophy (>20% difference between left and right testicular volume)

**Table 11.** Robust linear regression model for atypical morphology at baseline.

	$\beta$	SE	<i>P</i>
<i>(Intercept)</i>	84.08	4.51	0.0001
Baseline left testicular volume (ml)	-0.152	0.227	0.5017
LTH <sup>§</sup> (yes)	11.396	9.322	0.2169
Age at intervention (years)	-0.054	0.132	0.683
LTH <sup>§</sup> (yes): baseline left testicular volume (ml)	-0.912	0.646	0.1537

<sup>§</sup>Left testicular hypotrophy (>20% difference between left and right testicular volume)

**Table 12.** Robust linear regression model for serum FSH at baseline.

	$\beta$	SE	<i>P</i>
<i>(Intercept)</i>	2.97	0.932	0.0022
Baseline left testicular volume (ml)	-0.071	0.049	0.1449
LTH <sup>§</sup> (yes)	0.193	1.915	0.922
Age at intervention (years)	0.049	0.029	0.1022
LTH <sup>§</sup> (yes): baseline left testicular volume (ml)	-0.039	0.132	0.7769

<sup>§</sup>Left testicular hypotrophy (>20% difference between left and right testicular volume)

**Table 13.** Robust linear regression model for serum LH at baseline.

	$\beta$	SE	<i>P</i>
<i>(Intercept)</i>	3.59	0.768	0.0001
Baseline left testicular volume (ml)	-0.034	0.041	0.4027
LTH <sup>§</sup> (yes)	1.776	1.601	0.264
Age at intervention (years)	0.003	0.024	0.9093
LTH <sup>§</sup> (yes): baseline left testicular volume (ml)	-0.09	0.11	0.4061

<sup>§</sup>Left testicular hypotrophy (>20% difference between left and right testicular volume)

**Table 14.** Robust linear regression model for serum inhibin B at baseline.

	$\beta$	SE	<i>P</i>
<i>(Intercept)</i>	81.966	35.052	0.0211
Baseline left testicular volume (ml)	6.342	1.711	<b>0.0003</b>
LTH <sup>§</sup> (yes)	79.309	67.695	0.2478
Age at intervention (years)	-1.568	1.097	0.1534
LTH <sup>§</sup> (yes): baseline left testicular volume (ml)	-6.333	4.649	0.1793

<sup>§</sup>Left testicular hypotrophy (>20% difference between left and right testicular volume)

**Table 15.** Robust linear regression model for serum total testosterone at baseline.

	$\beta$	SE	<i>P</i>
<i>(Intercept)</i>	20.087	3.794	0.0001
Baseline left testicular volume (ml)	0.088	0.202	0.666
LTH <sup>§</sup> (yes)	5.878	7.972	0.4699
Age at intervention (years)	0.033	0.12	0.7824
LTH <sup>§</sup> (yes): baseline left testicular volume (ml)	-0.271	0.546	0.6235

<sup>§</sup>Left testicular hypotrophy (>20% difference between left and right testicular volume)

**Table 16.** Robust linear regression model for serum total estradiol at baseline.

	$\beta$	SE	<i>P</i>
<i>(Intercept)</i>	25.81	7.14	0.0006
Baseline left testicular volume (ml)	-0.123	0.384	0.7491
LTH <sup>§</sup> (yes)	-5.926	14.518	0.6846
Age at intervention (years)	0.119	0.231	0.6081
LTH <sup>§</sup> (yes): baseline left testicular volume (ml)	0.595	0.985	0.5466

<sup>§</sup>Left testicular hypotrophy (>20% difference between left and right testicular volume)

**Table 17.** Robust linear regression model for serum FSH at baseline, adjusted for serum baseline inhibin B.

	$\beta$	SE	<i>P</i>
<i>(Intercept)</i>	3.436	0.895	0.0003
Baseline left testicular volume (ml)	-0.047	0.045	0.2953
LTH <sup>§</sup> (yes)	0.537	1.651	0.7526
Age at intervention (years)	0.047	0.028	0.0966
Serum baseline inhibin B (pg/mL)	-0.005	0.002	<b>0.0273</b>
LTH <sup>§</sup> (yes): baseline left testicular volume (ml)	-0.084	0.114	0.480

<sup>§</sup>Left testicular hypotrophy (>20% difference between left and right testicular volume)

**Table 18.** Subjects included in protocol #3: comparison between baseline and end-of-follow-up parameters of testicular endocrine and spermatogenetic function. Data expressed as median [IQR]. Welch two sample t-test used for numeric variables.

	Baseline	End of follow-up	<i>P</i>
<b>Semen analysis</b>			
Volume (ml)	3.2 [2.5 – 4]	3 [2.5 – 3.95]	0.574
Sperm concentration per ml (x10 <sup>6</sup> )	58 [30 – 87.5]	65.5 [37.8 – 95]	0.314
Total sperm concentration (x10 <sup>6</sup> )	176 [92.4 – 273]	200 [140 – 280]	0.327
Progressive motility (%)	50 [35 – 55]	50 [40 – 55]	0.322
Atypical morphology (%)	80 [75 – 85]	79.5 [77 – 87]	0.41
<b>Endocrine parameters</b>			
FSH (mIU/mL)	2.73 [2.02 – 3.92]	2.64 [1.92 – 3.68]	0.857
LH (mIU/mL)	3.03[2.46 – 3.58]	3.07 [2.18 – 4.08]	0.737
E2 (pg/mL)	28 [20 – 34]	27 [22 – 33]	0.338
Inhibin B (pg/mL)	144 [109 – 170]	165 [142 – 199]	<b>0.005</b>
Total testosterone (nmol/L)	22.4 [18.3 – 26.0]	23.9 [19 – 26.8]	0.469

§Left testicular hypotrophy (>20% difference between left and right testicular volume)

**Table 19.** Robust linear regression model for semen volume during follow-up.

	$\beta$	SE	<i>P</i>
<i>(Intercept)</i>	1.952	0.861	0.027
Baseline left testicular volume (ml)	0.444	0.083	<b>0.001</b>
LTH <sup>§</sup> (yes)	-0.384	0.329	0.248
Left testicular volume change (+1 ml)	-0.017	0.065	0.791
Age at intervention (years)	0.003	0.029	0.920
Grade of left varicocele			
Grade 2	Ref.		
Grade 3	-0.249	0.343	0.470
Grade 4	-0.141	0.382	0.712

§Left testicular hypotrophy (>20% difference between left and right testicular volume)

**Table 20.** Robust linear regression model for sperm concentration (per ml) during follow-up.

	$\beta$	SE	<i>P</i>
<i>(Intercept)</i>	17.015	33.801	0.617
Baseline sperm concentration ( $10^6$ /ml)	0.726	0.115	<b>0.001</b>
LTH <sup>§</sup> (yes)	0.756	13.638	0.956
Left testicular volume change (+1 ml)	0.245	2.671	0.927
Age at intervention (years)	0.43	1.179	0.717
Grade of left varicocele			
Grade 2	Ref.		
Grade 3	-1.224	14.46	0.933
Grade 4	3.512	16.104	0.828

<sup>§</sup>Left testicular hypertrophy (>20% difference between left and right testicular volume)

**Table 21.** Robust linear regression model for total sperm concentration during follow-up.

	$\beta$	SE	<i>P</i>
<i>(Intercept)</i>	38.365	123.278	0.757
Baseline total sperm concentration ( $10^6$ )	0.633	0.144	<b>0.001</b>
LTH <sup>§</sup> (yes)	7.207	49.706	0.885
Left testicular volume change (+1 ml)	2.398	9.694	0.806
Age at intervention (years)	1.849	4.295	0.669
Grade of left varicocele			
Grade 2	Ref.		
Grade 3	25.6	52.294	0.626
Grade 4	34.755	59.208	0.56

<sup>§</sup>Left testicular hypotrophy (>20% difference between left and right testicular volume)



**Table 22.** Robust linear regression model for sperm progressive motility during follow-up.

	$\beta$	SE	<i>P</i>
<i>(Intercept)</i>	18.08	7.588	0.021
Baseline sperm progressive motility (%)	0.646	0.075	<b>0.001</b>
LTH <sup>§</sup> (yes)	7.458	2.672	<b>0.007</b>
Left testicular volume change (+1 ml)	-0.271	0.528	0.61
Age at intervention (years)	-0.062	0.238	0.795
Grade of left varicocele			
Grade 2	Ref.		
Grade 3	2.554	2.892	0.381
Grade 4	-1.388	3.194	0.665

<sup>§</sup>Left testicular hypotrophy (>20% difference between left and right testicular volume)

**Table 23.** Robust linear regression model for atypical morphology during follow-up.

	$\beta$	SE	<i>P</i>
<i>(Intercept)</i>	44.173	8.275	0.001
Baseline atypical morphology (%)	0.514	0.084	<b>0.001</b>
LTH <sup>§</sup> (yes)	-1.095	1.526	0.476
Left testicular volume change (+1 ml)	-0.009	0.295	0.976
Age at intervention (years)	-0.056	0.13	0.667
Grade of left varicocele			
Grade 2	Ref.		
Grade 3	-3.721	1.604	<b>0.024</b>
Grade 4	-3.644	1.82	<b>0.035</b>

<sup>§</sup>Left testicular hypotrophy (>20% difference between left and right testicular volume)

**Table 24.** Robust linear regression model for serum FSH during follow-up.

	$\beta$	SE	<i>P</i>
<i>(Intercept)</i>	-3.66	1.245	0.005
Baseline serum FSH (mUI/mL)	0.804	0.11	<b>0.001</b>
LTH <sup>§</sup> (yes)	-0.687	0.453	0.136
Left testicular volume change (+1 ml)	0.2	0.102	0.055
Age at intervention (years)	0.163	0.044	<b>0.001</b>
Grade of left varicocele			
Grade 2	Ref.		
Grade 3	0.632	0.467	0.183
Grade 4	1.181	0.508	<b>0.025</b>

<sup>§</sup>Left testicular hypotrophy (>20% difference between left and right testicular volume)

**Table 25.** Robust linear regression model for serum LH during follow-up.

	$\beta$	SE	<i>P</i>
<i>(Intercept)</i>	0.384	1.331	0.774
Baseline serum LH (mUI/mL)	0.514	0.136	<b>0.001</b>
LTH <sup>§</sup> (yes)	-0.355	0.419	0.401
Left testicular volume change (+1 ml)	0.1	0.097	0.309
Age at intervention (years)	0.034	0.041	0.411
Grade of left varicocele			
Grade 2	Ref.		
Grade 3	0.274	0.428	0.524
Grade 4	0.892	0.472	0.065

<sup>§</sup>Left testicular hypotrophy (>20% difference between left and right testicular volume)

**Table 26.** Robust linear regression model for serum inhibin B during follow-up.

	$\beta$	SE	<i>P</i>
<i>(Intercept)</i>	129.23	48.631	0.011
Baseline serum inhibin B (pg/ml)	0.567	0.104	<b>0.001</b>
LTH <sup>§</sup> (yes)	-9.89	16.053	0.541
Left testicular volume change (+1 ml)	6.275	3.893	0.115
Age at intervention (years)	-1.938	1.819	0.293
Grade of left varicocele			
Grade 2	Ref.		
Grade 3	-6.636	17.158	0.701
Grade 4	-8.582	20.944	0.684

<sup>§</sup>Left testicular hypotrophy (>20% difference between left and right testicular volume)

**Table 27.** Robust linear regression model for serum inhibin B during follow-up, adjusted for increase in serum FSH.

	$\beta$	SE	<i>P</i>
<i>(Intercept)</i>	117.908	45.19	0.013
Baseline serum inhibin B (pg/ml)	0.607	0.094	<b>0.001</b>
LTH <sup>§</sup> (yes)	-15.942	13.717	0.257
Left testicular volume change (+1 ml)	3.402	3.366	0.321
FSH change (+1 mUI/mL)	34.2	11.749	<b>0.008</b>
Age at intervention (years)	-1.568	1.629	0.335
Grade of left varicocele			
Grade 2	Ref.		
Grade 3	-2.959	14.74	0.842
Grade 4	-3.94	17.98	0.828

<sup>§</sup>Left testicular hypotrophy (>20% difference between left and right testicular volume)

**Table 28.** Robust linear regression model for serum total testosterone during follow-up.

	$\beta$	SE	<i>P</i>
<i>(Intercept)</i>	6.872	5.487	0.217
Baseline serum testosterone (nmol/L)	0.591	0.115	<b>0.001</b>
LTH <sup>§</sup> (yes)	3.346	1.779	0.066
Left testicular volume change (+1 ml)	0.299	0.391	0.448
Age at intervention (years)	0.031	0.167	0.853
Grade of left varicocele			
Grade 2	Ref.		
Grade 3	2.384	1.802	0.192
Grade 4	1.694	2.066	0.416

<sup>§</sup>Left testicular hypotrophy (>20% difference between left and right testicular volume)

**Table 29.** Robust linear regression model for serum total estradiol during follow-up.

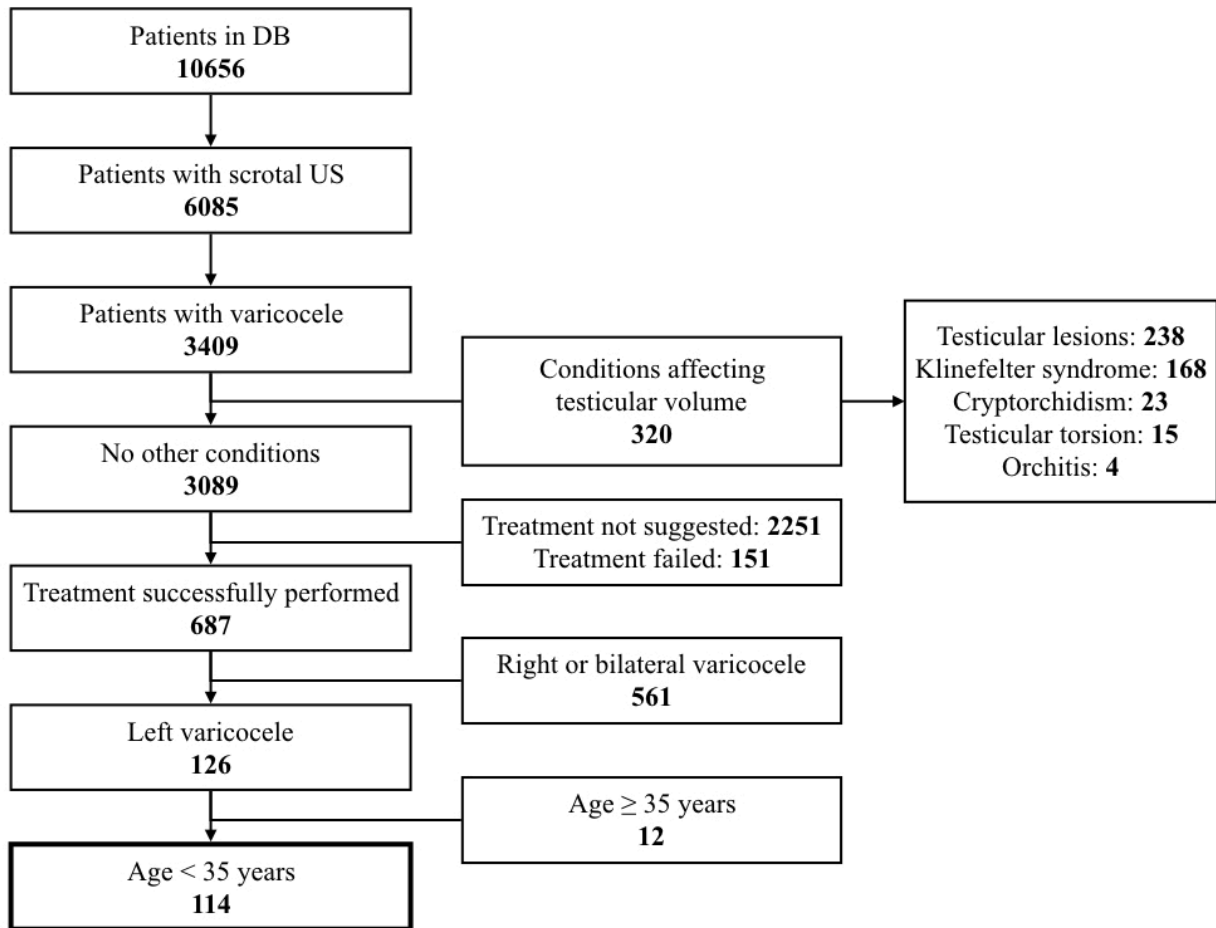
	$\beta$	SE	<i>P</i>
<i>(Intercept)</i>	28.183	11.053	0.015
Baseline serum estradiol (pg/mL)	0.151	0.146	0.309
LTH <sup>§</sup> (yes)	3.64	3.623	0.321
Left testicular volume change (+1 ml)	0.004	0.848	0.996
Age at intervention (years)	-0.063	0.364	0.863
Grade of left varicocele			
Grade 2	Ref.		
Grade 3	-2.579	3.769	0.498
Grade 4	-6.062	3.857	0.124

<sup>§</sup>Left testicular hypotrophy (>20% difference between left and right testicular volume)

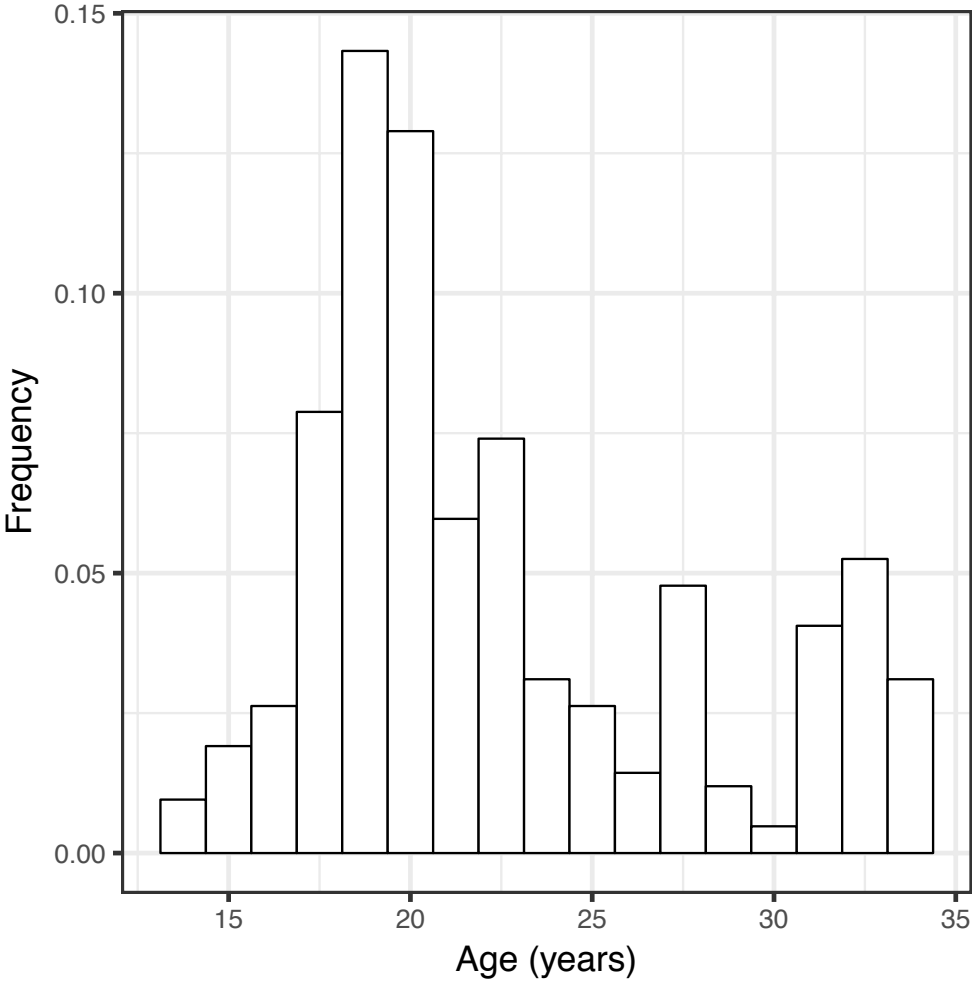
**Table 30.** Reference values for AMH and INSL3 by age. Adapted from Edelsztein et al [13] and Ferlin et al [88].

<b>Age</b>	<b>Serum AMH</b>		<b>Serum INSL3</b>
	pmol/l	ng/ml	pg/ml
<14 days	250–1000	35–140	-
15 days – 6 months	400–1500	55–210	-
6 months – 2 years	600–2300	85–320	-
2–9 years	400–1800	55–250	-
9–18 years:			
Tanner 1	250–1400	35–200	10.3–19.8
Tanner 2	70–1000	10–140	30.6–43.7
Tanner 3	30–400	4–55	74.3–92.8
Tanner 4	30–160	4–22	85.5–150.0
Tanner 5	30–150	4–21	100.1–145.8
Adults	25–130	3–18	493.1–643.5

**Figure 1.** Flowchart detailing the process of patient retrieval from our electronic database. Several patients had more than one condition affecting testicular volume.

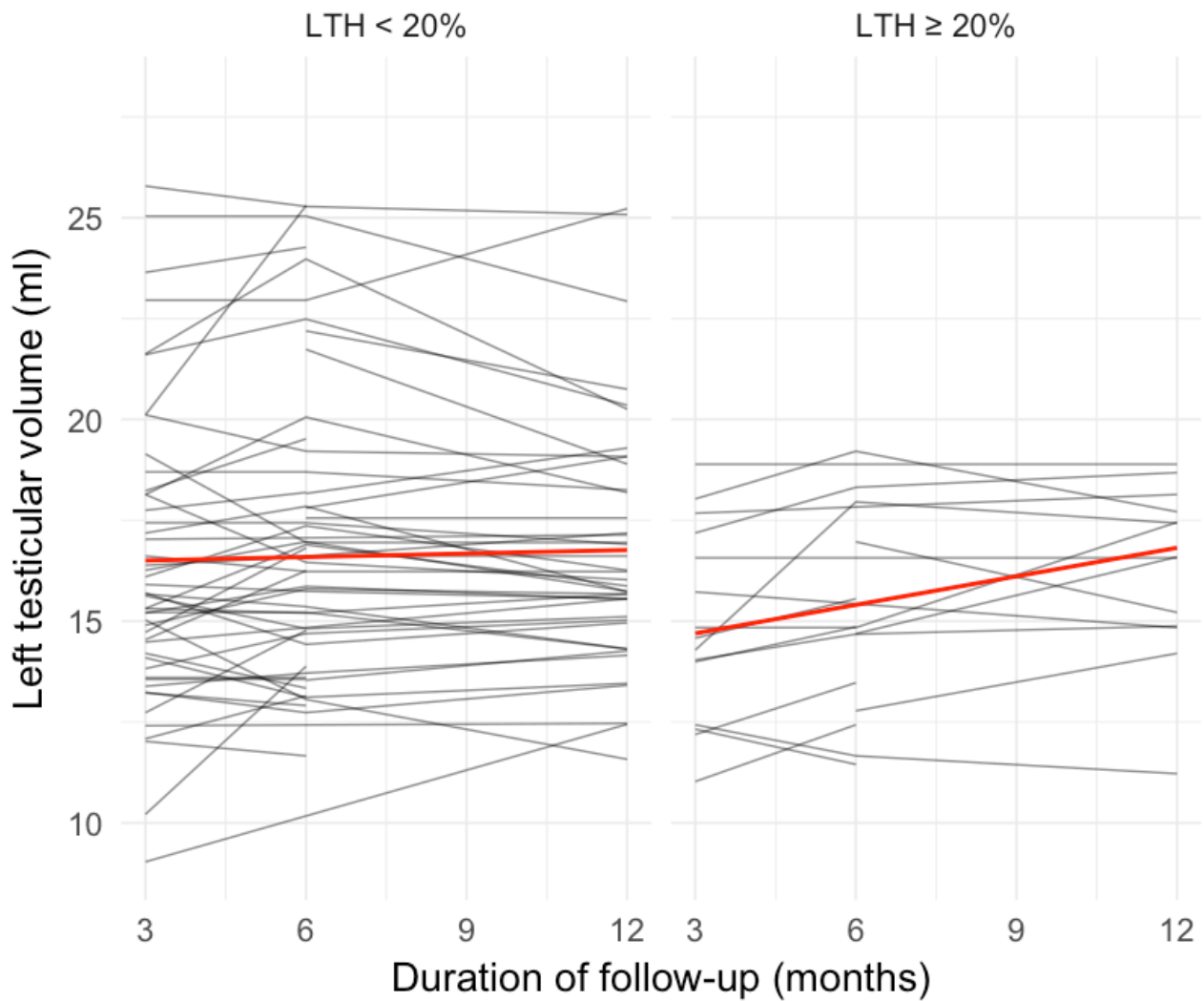


**Figure 2.** Histogram detailing age distribution in the study population (n = 114).



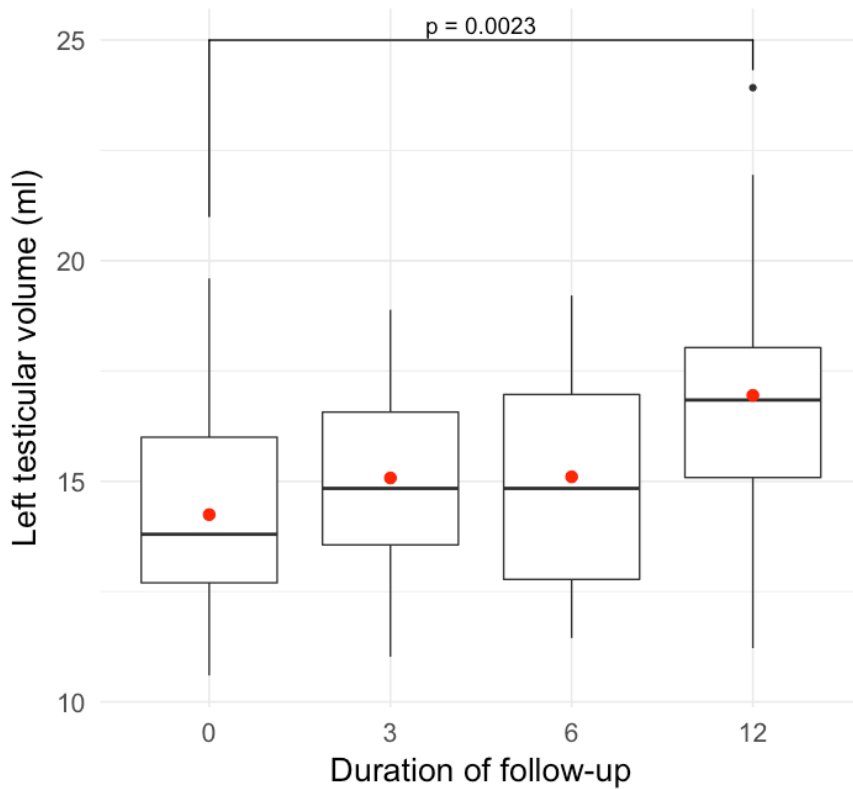
**Figure 3.** Changes in left testicular volume following percutaneous treatment of left varicocele.

Each line represents a single patient; the red line describes the mean.

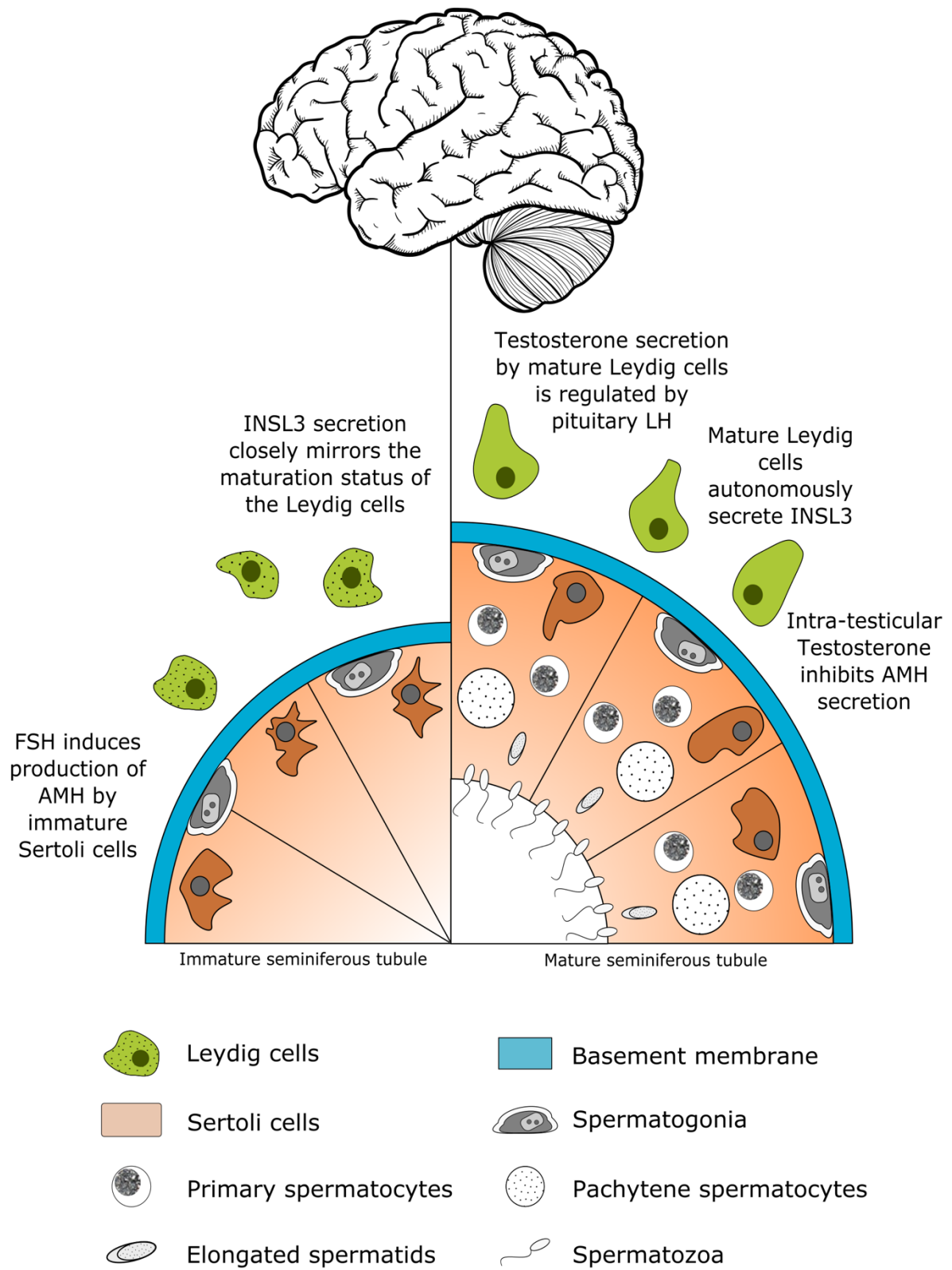




**Figure 4.** Graphical representation of changes in left testicular volume following percutaneous treatment of left varicocele in patients with left testicular hypotrophy. Boxplots describe the median and interquartile range; the red dot is the mean. Wilcoxon rank-sum test was used to assess the statistical difference between the means.



**Figure 5.** Testicular endocrine function before and after testicular maturity.



**Supplementary Table 1.** Ultrasound classification of varicocele according to the Ultrasound of the Testis for the Andrologist – Morphological and Functional Atlas [17]. Modified with permission of the Authors.

		<b>Revisited classification (Dubin-Solbiati)</b>	<b>Corresponding to Dubin</b>
	<b>B-Mode</b>	<b>Reflux</b>	
<b>Grade 1</b>	Dilated vessel (>2.5 mm) in inguinal region only	Inguinal reflux only during Valsalva manoeuvre (lasting 2–3 s)	Grade 1
<b>Grade 2</b>	Supra-testicular vessel dilation (>3 mm)	Supra-testicular reflux only during Valsalva manoeuvre, lasting more than 3 s	
<b>Grade 3</b>	Supra- and peritesticular vessel dilation (>3 mm)	Supra- and peritesticular reflux at rest which increases during Valsalva manoeuvre, lasting more than 3 s	Grade 2
<b>Grade 4</b>	Peritesticular vessel dilation with further dilation during functional manoeuvre, testicular hypotrophy	Peritesticular reflux at rest which may or may not increase during Valsalva manoeuvre	Grade 3
<b>Grade 5</b>	Peritesticular vessel dilation that does not increase with functional manoeuvre or intratesticular vessels and testicular hypotrophy	Peritesticular reflux at rest which increases minimally during Valsalva manoeuvre or dilated intratesticular vessels which refill with Valsalva manoeuvre	

## References

- [1] Serefoglu EC, Saitz TR, La Nasa JA, Jr., Hellstrom WJ. Adolescent varicocele management controversies. *Andrology*. 2013;1:109-15.
- [2] Jacobson DL, Johnson EK. Varicoceles in the pediatric and adolescent population: threat to future fertility? *Fertil Steril*. 2017;108:370-7.
- [3] Kolon TF. Evaluation and Management of the Adolescent Varicocele. *J Urol*. 2015;194:1194-201.
- [4] Cortes-Gutierrez EI, Davila-Rodriguez MI, Fernandez JL, Lopez-Fernandez C, Aragon-Tovar AR, Urbina-Bernal LC, et al. DNA damage in spermatozoa from infertile men with varicocele evaluated by sperm chromatin dispersion and DBD-FISH. *Arch Gynecol Obstet*. 2016;293:189-96.
- [5] Pallotti F, Paoli D, Carlini T, Vestri AR, Martino G, Lenzi A, et al. Varicocele and semen quality: a retrospective case-control study of 4230 patients from a single centre. *J Endocrinol Invest*. 2018;41:185-92.
- [6] Sheehan MM, Ramasamy R, Lamb DJ. Molecular mechanisms involved in varicocele-associated infertility. *J Assist Reprod Genet*. 2014;31:521-6.
- [7] Clavijo RI, Carrasquillo R, Ramasamy R. Varicoceles: prevalence and pathogenesis in adult men. *Fertil Steril*. 2017;108:364-9.
- [8] Johnson D, Sandlow J. Treatment of varicoceles: techniques and outcomes. *Fertil Steril*. 2017;108:378-84.
- [9] Roque M, Esteves SC. A systematic review of clinical practice guidelines and best practice statements for the diagnosis and management of varicocele in children and adolescents. *Asian J Androl*. 2016;18:262-8.
- [10] Li F, Chiba K, Yamaguchi K, Okada K, Matsushita K, Ando M, et al. Effect of varicocelectomy on testicular volume in children and adolescents: a meta-analysis. *Urology*. 2012;79:1340-5.

- [11] Nork JJ, Berger JH, Crain DS, Christman MS. Youth varicocele and varicocele treatment: a meta-analysis of semen outcomes. *Fertil Steril*. 2014;102:381-7 e6.
- [12] Smit M, Romijn JC, Wildhagen MF, Veldhoven JL, Weber RF, Dohle GR. Decreased sperm DNA fragmentation after surgical varicocelectomy is associated with increased pregnancy rate. *J Urol*. 2013;189:S146-50.
- [13] Edelsztejn NY, Grinspon RP, Schteingart HF, Rey RA. Anti-Mullerian hormone as a marker of steroid and gonadotropin action in the testis of children and adolescents with disorders of the gonadal axis. *International Journal of Pediatric Endocrinology*. 2016;2016:20.
- [14] Selice R, Ferlin A, Garolla A, Caretta N, Foresta C. Effects of endogenous FSH on normal human spermatogenesis in adults. *Int J Androl*. 2011;34:e511-7.
- [15] Sakamoto H, Saito K, Ogawa Y, Yoshida H. Effects of varicocele repair in adults on ultrasonographically determined testicular volume and on semen profile. *Urology*. 2008;71:485-9.
- [16] Oyen RH. Scrotal ultrasound. *Eur Radiol*. 2002;12:19-34.
- [17] Isidori AM, Lenzi A. *Ultrasound of the Testis for the Andrologist - Morphological and Functional Atlas*: Springer International Publishing; 2017.
- [18] Garcia-Roig ML, Kirsch AJ. The dilemma of adolescent varicocele. *Pediatr Surg Int*. 2015;31:617-25.
- [19] Glassberg KI. My indications for treatment of the adolescent varicocele (and why?). *Transl Androl Urol*. 2014;3:402-12.
- [20] Sack BS, Schafer M, Kurtz MP. The Dilemma of Adolescent Varicoceles: Do They Really Have to Be Repaired? *Curr Urol Rep*. 2017;18:38.
- [21] Guzel O, Aslan Y, Balci M, Tuncel A, Unal B, Atan A. Significant worsening sperm parameters are associated to testicular hypotrophy in patients with a high grade varicocele. *Actas Urol Esp*. 2015;39:392-5.
- [22] Lombardo F, Sansone A, Romanelli F, Paoli D, Gandini L, Lenzi A. The role of antioxidant therapy in the treatment of male infertility: an overview. *Asian J Androl*. 2011;13:690-7.

- [23] Kasahara E, Sato EF, Miyoshi M, Konaka R, Hiramoto K, Sasaki J, et al. Role of oxidative stress in germ cell apoptosis induced by di(2-ethylhexyl)phthalate. *Biochem J.* 2002;365:849-56.
- [24] Barbonetti A, Castellini C, Di Giammarco N, Santilli G, Francavilla S, Francavilla F. In vitro exposure of human spermatozoa to bisphenol A induces pro-oxidative/apoptotic mitochondrial dysfunction. *Reprod Toxicol.* 2016;66:61-7.
- [25] Micillo A, Vassallo MR, Cordeschi G, D'Andrea S, Necozone S, Francavilla F, et al. Semen leukocytes and oxidative-dependent DNA damage of spermatozoa in male partners of subfertile couples with no symptoms of genital tract infection. *Andrology.* 2016;4:808-15.
- [26] Cho CL, Esteves SC, Agarwal A. Novel insights into the pathophysiology of varicocele and its association with reactive oxygen species and sperm DNA fragmentation. *Asian J Androl.* 2016;18:186-93.
- [27] Lotti F, Maggi M. Ultrasound of the male genital tract in relation to male reproductive health. *Hum Reprod Update.* 2015;21:56-83.
- [28] Oehme NHB, Roelants M, Bruserud IS, Eide GE, Bjerknes R, Rosendahl K, et al. Ultrasound-based measurements of testicular volume in 6- to 16-year-old boys - intra- and interobserver agreement and comparison with Prader orchidometry. *Pediatr Radiol.* 2018;48:1771-8.
- [29] Sakamoto H, Ogawa Y, Yoshida H. Relationship between testicular volume and testicular function: comparison of the Prader orchidometric and ultrasonographic measurements in patients with infertility. *Asian J Androl.* 2008;10:319-24.
- [30] Chu DI, Zderic SA, Shukla AR, Srinivasan AK, Tasian GE, Weiss DA, et al. Does varicolectomy improve semen analysis outcomes in adolescents without testicular asymmetry? *J Pediatr Urol.* 2017;13:76 e1- e5.
- [31] Cupertino MC, Novaes RD, Santos EC, Neves AC, Silva E, Oliveira JA, et al. Differential Susceptibility of Germ and Leydig Cells to Cadmium-Mediated Toxicity: Impact on Testis Structure, Adiponectin Levels, and Steroidogenesis. *Oxid Med Cell Longev.* 2017;2017:3405089.

- [32] Wu A, Shi Z, Martin S, Vincent A, Heilbronn L, Wittert G. Age-related changes in estradiol and longitudinal associations with fat mass in men. *PLoS One*. 2018;13:e0201912.
- [33] Iannone M, Botre F, Cardillo N, de la Torre X. Synthetic isoflavones and doping: A novel class of aromatase inhibitors? *Drug Test Anal*. 2018.
- [34] Grinspon RP, Urrutia M, Rey RA. Male Central Hypogonadism in Paediatrics - the Relevance of Follicle-stimulating Hormone and Sertoli Cell Markers. *Eur Endocrinol*. 2018;14:67-71.
- [35] Jin JM, Yang WX. Molecular regulation of hypothalamus-pituitary-gonads axis in males. *Gene*. 2014;551:15-25.
- [36] Boepple PA, Hayes FJ, Dwyer AA, Raivio T, Lee H, Crowley WF, Jr., et al. Relative roles of inhibin B and sex steroids in the negative feedback regulation of follicle-stimulating hormone in men across the full spectrum of seminiferous epithelium function. *J Clin Endocrinol Metab*. 2008;93:1809-14.
- [37] Tuttelmann F, Laan M, Grigороva M, Punab M, Sober S, Gromoll J. Combined effects of the variants FSHB -211G>T and FSHR 2039A>G on male reproductive parameters. *J Clin Endocrinol Metab*. 2012;97:3639-47.
- [38] Silber S. The varicocele argument resurfaces. *J Assist Reprod Genet*. 2018;35:1079-82.
- [39] Blevrakis E, Chatzidarellis E, Anyfantakis D, Sakellaris G, Raissaki M, Zoras O, et al. Impact of varicocele on biological markers of gonadal function. *Hernia*. 2016;20:435-9.
- [40] Molinaro F, Cerchia E, Garzi A, Severi FM, Angotti R, Petraglia F, et al. Serum levels of inhibin B in adolescents after varicocelelectomy: A long term follow up. *Open Med (Wars)*. 2016;11:204-6.
- [41] Di Bisceglie C, Bertagna A, Baldi M, Lanfranco F, Tagliabue M, Gazzera C, et al. Varicocele sclerotherapy improves serum inhibin B levels and seminal parameters. *Int J Androl*. 2007;30:531-6.
- [42] Stamatiades GA, Kaiser UB. Gonadotropin regulation by pulsatile GnRH: Signaling and gene expression. *Mol Cell Endocrinol*. 2018;463:131-41.

- [43] Dufau ML, Winters CA, Hattori M, Aquilano D, Baranao JL, Nozu K, et al. Hormonal regulation of androgen production by the Leydig cell. *J Steroid Biochem.* 1984;20:161-73.
- [44] Lucas TF, Nascimento AR, Pisolato R, Pimenta MT, Lazari MF, Porto CS. Receptors and signaling pathways involved in proliferation and differentiation of Sertoli cells. *Spermatogenesis.* 2014;4:e28138.
- [45] Simoni M, Gromoll J, Nieschlag E. The follicle-stimulating hormone receptor: biochemistry, molecular biology, physiology, and pathophysiology. *Endocr Rev.* 1997;18:739-73.
- [46] Walker WH, Cheng J. FSH and testosterone signaling in Sertoli cells. *Reproduction.* 2005;130:15-28.
- [47] Huhtaniemi I. A short evolutionary history of FSH-stimulated spermatogenesis. *Hormones (Athens).* 2015;14:468-78.
- [48] Huhtaniemi I. Mutations affecting gonadotropin secretion and action. *Horm Res.* 2003;60 Suppl 3:21-30.
- [49] Salhi I, Cambon-Roques S, Lamarre I, Laune D, Molina F, Pugniere M, et al. The anti-Mullerian hormone type II receptor: insights into the binding domains recognized by a monoclonal antibody and the natural ligand. *Biochem J.* 2004;379:785-93.
- [50] Iliadou PK, Tsametis C, Kaprara A, Papadimas I, Goulis DG. The Sertoli cell: Novel clinical potentiality. *Hormones (Athens).* 2015;14:504-14.
- [51] Rey R, Lukas-Croisier C, Lasala C, Bedecarras P. AMH/MIS: what we know already about the gene, the protein and its regulation. *Molecular and Cellular Endocrinology.* 2003;211:21-31.
- [52] Franke FE, Pauls K, Rey R, Marks A, Bergmann M, Steger K. Differentiation markers of Sertoli cells and germ cells in fetal and early postnatal human testis. *Anat Embryol (Berl).* 2004;209:169-77.
- [53] Pleuger C, Fietz D, Hartmann K, Weidner W, Kliesch S, O'Bryan MK, et al. Expression of katanin p80 in human spermatogenesis. *Fertil Steril.* 2016;106:1683-90 e1.



- [54] Schubert K, Polte T, Bonisch U, Schader S, Holtappels R, Hildebrandt G, et al. Thy-1 (CD90) regulates the extravasation of leukocytes during inflammation. *Eur J Immunol*. 2011;41:645-56.
- [55] Matuszczak E, Hermanowicz A, Komarowska M, Debek W. Serum AMH in Physiology and Pathology of Male Gonads. *Int J Endocrinol*. 2013;2013:128907.
- [56] Shahrokhi SZ, Kazerouni F, Ghaffari F. Anti-Mullerian Hormone: genetic and environmental effects. *Clin Chim Acta*. 2018;476:123-9.
- [57] Pellatt L, Rice S, Mason HD. Anti-Mullerian hormone and polycystic ovary syndrome: a mountain too high? *Reproduction*. 2010;139:825-33.
- [58] Tata B, Mimouni NEH, Barbotin AL, Malone SA, Loyens A, Pigny P, et al. Elevated prenatal anti-Mullerian hormone reprograms the fetus and induces polycystic ovary syndrome in adulthood. *Nat Med*. 2018;24:834-46.
- [59] Roberts LM, Visser JA, Ingraham HA. Involvement of a matrix metalloproteinase in MIS-induced cell death during urogenital development. *Development*. 2002;129:1487-96.
- [60] Roly ZY, Backhouse B, Cutting A, Tan TY, Sinclair AH, Ayers KL, et al. The cell biology and molecular genetics of Mullerian duct development. *Wiley Interdiscip Rev Dev Biol*. 2018;7:e310.
- [61] Condorelli RA, Cannarella R, Calogero AE, La Vignera S. Evaluation of testicular function in prepubertal children. *Endocrine*. 2018;62:274-80.
- [62] Rohayem J, Nieschlag E, Kliesch S, Zitzmann M. Inhibin B, AMH, but not INSL3, IGF1 or DHEAS support differentiation between constitutional delay of growth and puberty and hypogonadotropic hypogonadism. *Andrology*. 2015;3:882-7.
- [63] Adan L, Lechevalier P, Couto-Silva AC, Boissan M, Trivin C, Brailly-Tabard S, et al. Plasma inhibin B and antimullerian hormone concentrations in boys: discriminating between congenital hypogonadotropic hypogonadism and constitutional pubertal delay. *Med Sci Monit*. 2010;16:CR511-7.

- [64] Aksglaede L, Christiansen P, Sorensen K, Boas M, Linneberg A, Main KM, et al. Serum concentrations of Anti-Mullerian Hormone (AMH) in 95 patients with Klinefelter syndrome with or without cryptorchidism. *Acta Paediatr.* 2011;100:839-45.
- [65] Rohayem J, Fricke R, Czeloth K, Mallidis C, Wistuba J, Krallmann C, et al. Age and markers of Leydig cell function, but not of Sertoli cell function predict the success of sperm retrieval in adolescents and adults with Klinefelter's syndrome. *Andrology.* 2015;3:868-75.
- [66] Colacurci N, De Leo V, Ruvolo G, Piomboni P, Caprio F, Pivonello R, et al. Recombinant FSH Improves Sperm DNA Damage in Male Infertility: A Phase II Clinical Trial. *Front Endocrinol (Lausanne).* 2018;9:383.
- [67] Sinisi AA, Esposito D, Maione L, Quinto MC, Visconti D, De Bellis A, et al. Seminal anti-Mullerian hormone level is a marker of spermatogenic response during long-term gonadotropin therapy in male hypogonadotropic hypogonadism. *Hum Reprod.* 2008;23:1029-34.
- [68] Young J, Chanson P, Salenave S, Noel M, Brailly S, O'Flaherty M, et al. Testicular anti-mullerian hormone secretion is stimulated by recombinant human FSH in patients with congenital hypogonadotropic hypogonadism. *J Clin Endocrinol Metab.* 2005;90:724-8.
- [69] Isidori AM, Sansone A, Gianfrilli D. Hormonal Treatment of Male Infertility: Gonadotropins and Beyond. In: Simoni M, Huhtaniemi I, editors. *Endocrinology of the Testis and Male Reproduction.* Cham: Springer International Publishing; 2017. p. 1-20.
- [70] Raivio T, Wikstrom AM, Dunkel L. Treatment of gonadotropin-deficient boys with recombinant human FSH: long-term observation and outcome. *Eur J Endocrinol.* 2007;156:105-11.
- [71] Rohayem J, Nieschlag E. Stimulation of Spermatogenesis in Hypogonadotropic Men. In: Winters SJ, Huhtaniemi IT, editors. *Male Hypogonadism.* Cham: Springer International Publishing; 2017. p. 423-36.
- [72] Tuttelmann F, Dykstra N, Themmen AP, Visser JA, Nieschlag E, Simoni M. Anti-Mullerian hormone in men with normal and reduced sperm concentration and men with maldescended testes. *Fertil Steril.* 2009;91:1812-9.

- [73] Sharpe RM, McKinnell C, Kivlin C, Fisher JS. Proliferation and functional maturation of Sertoli cells, and their relevance to disorders of testis function in adulthood. *Reproduction*. 2003;125:769-84.
- [74] Grinspon RP, Gottlieb S, Bedecarras P, Rey RA. Anti-Mullerian Hormone and Testicular Function in Prepubertal Boys With Cryptorchidism. *Front Endocrinol (Lausanne)*. 2018;9:182.
- [75] Nistal M, Gonzalez-Peramato P, De Miguel MP. Sertoli cell dedifferentiation in human cryptorchidism and gender reassignment shows similarities between fetal environmental and adult medical treatment estrogen and antiandrogen exposure. *Reprod Toxicol*. 2013;42:172-9.
- [76] Rey R, Sabourin JC, Venara M, Long WQ, Jaubert F, Zeller WP, et al. Anti-Mullerian hormone is a specific marker of sertoli- and granulosa-cell origin in gonadal tumors. *Hum Pathol*. 2000;31:1202-8.
- [77] Farkkila A, Koskela S, Bryk S, Alfthan H, Butzow R, Leminen A, et al. The clinical utility of serum anti-Mullerian hormone in the follow-up of ovarian adult-type granulosa cell tumors--A comparative study with inhibin B. *Int J Cancer*. 2015;137:1661-71.
- [78] Rey RA, Lhomme C, Marcillac I, Lahlou N, Duvillard P, Josso N, et al. Antimullerian hormone as a serum marker of granulosa cell tumors of the ovary: comparative study with serum alpha-inhibin and estradiol. *Am J Obstet Gynecol*. 1996;174:958-65.
- [79] Claes AN, Ball BA. Biological Functions and Clinical Applications of Anti-Mullerian Hormone in Stallions and Mares. *Vet Clin North Am Equine Pract*. 2016;32:451-64.
- [80] Holst BS, Dreimanis U. Anti-Mullerian hormone: a potentially useful biomarker for the diagnosis of canine Sertoli cell tumours. *BMC Vet Res*. 2015;11:166.
- [81] Alfano M, Ventimiglia E, Locatelli I, Capogrosso P, Cazzaniga W, Pederzoli F, et al. Anti-Mullerian Hormone-to-Testosterone Ratio is Predictive of Positive Sperm Retrieval in Men with Idiopathic Non-Obstructive Azoospermia. *Sci Rep*. 2017;7:17638.

- [82] Trigo RV, Bergada I, Rey R, Ballerini MG, Bedecarras P, Bergada C, et al. Altered serum profile of inhibin B, Pro-alphaC and anti-Mullerian hormone in prepubertal and pubertal boys with varicocele. *Clin Endocrinol (Oxf)*. 2004;60:758-64.
- [83] Goulis D, Mintziori G, Koliakos N, Hatzichristou D, Papadimas I, Hatzimouratidis K, et al. Inhibin B and anti-Mullerian hormone in spermatic vein of subfertile men with varicocele. *Reprod Sci*. 2011;18:551-5.
- [84] Anand-Ivell R, Dai Y, Ivell R. Neohormones as biomarkers of reproductive health. *Fertil Steril*. 2013;99:1153-60.
- [85] Bay K, Andersson AM. Human testicular insulin-like factor 3: in relation to development, reproductive hormones and andrological disorders. *Int J Androl*. 2011;34:97-109.
- [86] Foresta C, Bettella A, Vinanzi C, Dabrilli P, Meriggiola MC, Garolla A, et al. A novel circulating hormone of testis origin in humans. *J Clin Endocrinol Metab*. 2004;89:5952-8.
- [87] Ivell R, Heng K, Anand-Ivell R. Insulin-Like Factor 3 and the HPG Axis in the Male. *Front Endocrinol (Lausanne)*. 2014;5:6.
- [88] Ferlin A, Garolla A, Rigon F, Rasi Caldogno L, Lenzi A, Foresta C. Changes in serum insulin-like factor 3 during normal male puberty. *J Clin Endocrinol Metab*. 2006;91:3426-31.
- [89] Anand-Ivell R, Wohlgemuth J, Haren MT, Hope PJ, Hatzinikolas G, Wittert G, et al. Peripheral INSL3 concentrations decline with age in a large population of Australian men. *Int J Androl*. 2006;29:618-26.
- [90] Bay K, Hartung S, Ivell R, Schumacher M, Jurgensen D, Jorgensen N, et al. Insulin-like factor 3 serum levels in 135 normal men and 85 men with testicular disorders: relationship to the luteinizing hormone-testosterone axis. *J Clin Endocrinol Metab*. 2005;90:3410-8.
- [91] Bay K, Matthiesson KL, McLachlan RI, Andersson AM. The effects of gonadotropin suppression and selective replacement on insulin-like factor 3 secretion in normal adult men. *J Clin Endocrinol Metab*. 2006;91:1108-11.

- [92] Lee SY, Park E, Kim SC, Ahn RS, Ko C, Lee K. ERalpha/E2 signaling suppresses the expression of steroidogenic enzyme genes via cross-talk with orphan nuclear receptor Nur77 in the testes. *Mol Cell Endocrinol.* 2012;362:91-103.
- [93] Yuan FP, Li X, Lin J, Schwabe C, Bullesbach EE, Rao CV, et al. The role of RXFP2 in mediating androgen-induced inguinoscrotal testis descent in LH receptor knockout mice. *Reproduction.* 2010;139:759-69.
- [94] Foresta C, Zuccarello D, Garolla A, Ferlin A. Role of hormones, genes, and environment in human cryptorchidism. *Endocr Rev.* 2008;29:560-80.
- [95] van Rooij IA, Broekmans FJ, te Velde ER, Fauser BC, Bancsi LF, de Jong FH, et al. Serum anti-Mullerian hormone levels: a novel measure of ovarian reserve. *Hum Reprod.* 2002;17:3065-71.
- [96] Chong YH, Dennis NA, Connolly MJ, Teh R, Jones GT, van Rij AM, et al. Elderly men have low levels of anti-Mullerian hormone and inhibin B, but with high interpersonal variation: a cross-sectional study of the sertoli cell hormones in 615 community-dwelling men. *PLoS One.* 2013;8:e70967.
- [97] Dennis NA, Jones GT, Chong YH, van Rij AM, McLennan IS. Serum anti-Mullerian hormone (AMH) levels correlate with infrarenal aortic diameter in healthy older men: is AMH a cardiovascular hormone? *J Endocrinol.* 2013;219:13-20.
- [98] Davis S, Lahlou N, Bardsley M, Temple MC, Kowal K, Pyle L, et al. Gonadal function is associated with cardiometabolic health in pre-pubertal boys with Klinefelter syndrome. *Andrology.* 2016;4:1169-77.
- [99] Appt SE, Chen H, Clarkson TB, Kaplan JR. Premenopausal antimullerian hormone concentration is associated with subsequent atherosclerosis. *Menopause.* 2012;19:1353-9.
- [100] Beck TN, Korobeynikov VA, Kudinov AE, Georgopoulos R, Solanki NR, Andrews-Hoke M, et al. Anti-Mullerian Hormone Signaling Regulates Epithelial Plasticity and Chemoresistance in Lung Cancer. *Cell Rep.* 2016;16:657-71.

- [101] Cai J, Pardali E, Sanchez-Duffhues G, ten Dijke P. BMP signaling in vascular diseases. *FEBS Lett.* 2012;586:1993-2002.
- [102] Lowery JW, de Caestecker MP. BMP signaling in vascular development and disease. *Cytokine Growth Factor Rev.* 2010;21:287-98.
- [103] Ferlin A, De Toni L, Sandri M, Foresta C. Relaxin and insulin-like peptide 3 in the musculoskeletal system: from bench to bedside. *Br J Pharmacol.* 2017;174:1015-24.
- [104] Ferlin A, De Toni L, AgoulNIK AI, Lunardon G, Armani A, Bortolanza S, et al. Protective Role of Testicular Hormone INSL3 From Atrophy and Weakness in Skeletal Muscle. *Front Endocrinol (Lausanne).* 2018;9:562.
- [105] Ferlin A, Pepe A, Giancesello L, Garolla A, Feng S, Giannini S, et al. Mutations in the insulin-like factor 3 receptor are associated with osteoporosis. *J Bone Miner Res.* 2008;23:683-93.
- [106] Di Nisio A, De Toni L, Rocca MS, Ghezzi M, Selice R, Tagliavoro G, et al. Negative Association Between Sclerostin and INSL3 in Isolated Human Osteocytes and in Klinefelter Syndrome: New Hints for Testis-Bone Crosstalk. *J Clin Endocrinol Metab.* 2018;103:2033-41.
- [107] Overvad S, Bay K, Bojesen A, Gravholt CH. Low INSL3 in Klinefelter syndrome is related to osteocalcin, testosterone treatment and body composition, as well as measures of the hypothalamic-pituitary-gonadal axis. *Andrology.* 2014;2:421-7.
- [108] Emmen JM, McLuskey A, Adham IM, Engel W, Verhoef-Post M, Themmen AP, et al. Involvement of insulin-like factor 3 (Insl3) in diethylstilbestrol-induced cryptorchidism. *Endocrinology.* 2000;141:846-9.