

Six months follow up of a single intravitreal injection of ocriplasmin for symptomatic vitreomacular adhesion

Fernanda Pacella¹, Kostantinos Nikolakopoulos¹, Athanasios Nikolakopoulos², Roberto Secondi¹, Anna Santa Guzzo³, Antonella Mollicone¹, Elena Pacella¹

¹Department of Sense Organs, Faculty of Medicine and Dentistry Sapienza University of Rome, Italy.

²Department Papanikolaou Hospital, Thessaloniki, Greece.

³Risk Manager Academic Hospital Policlinico Umberto I Sapienza University of Rome, Italy.

***Corresponding author:** Elena Pacella, e-mail: elena.pacella@uniroma1.it; Department of Sense Organs, Faculty of Medicine and Dentistry “Sapienza” University of Rome, Viale del Policlinico Clinica Oculistica 00161 Rome (ITALY); Tel: +39 0649975303 - +39 336783409

Article history

Received: March 26, 2016

Accepted: March 30, 2016

Published: March 31, 2016

Abstract

Purpose: To evaluate the efficacy and the safety of the enzymatic vitreolysis with a single intravitreal injection of ocriplasmin 125 µg across a group of patients with symptomatic vitreomacular adhesion (sVMA) during 6 months follow up.

Design: A randomized, placebo-controlled, double-masked, 6-month follow up study.

Participants: A total of 28 patients (12 M / 16F) (19 receiving ocriplasmin; 9 receiving placebo), mean aged 71 years old, diagnosed with sVMA, VMT, FTMH e ERM by optical coherence tomography.

Methods: A single intravitreal injection of ocriplasmin 125 µg or placebo. Primary endpoint was sVMA resolution or FTMH closure. Secondary endpoint included the integrity of the external membrane and the inner and outer segments of the photoreceptor interface using OCT. The evaluation was carried out at baseline and during 6 months after intravitreal injection of ocriplasmin or placebo.

Results: After a 6 months follow-up period, the rate of VMA resolution was 42.1% in the Ocriplasmin group vs the 22% in the placebo group. FTMH closure rate was 50% in the Ocriplasmin group vs 0% in the placebo group. The best results were obtained within 28 days from the treatment. No case of uveitis, endophthalmitis, retinal tears, retinal detachment or bleeding during follow-up were reported. One patient reported floaters and transitional photopsias.

Conclusions: The study confirmed the efficacy and safety of Ocriplasmin injection for patients with VMT, including when associated with full-thickness macular holes during six months follow up. Long term studies are certainly needed to confirm these results.

Keywords: vitreomacular adhesion; ocriplasmin; intravitreal injection; enzymatic vitreolysis.

Introduction

Vitreous body is a gel that ensures the volume and the stability of the eye.

It is made by a mixture of water and an heterogeneous texture formed by collagen fibrils of types II, V, XI and

IX and hyaluronic acid fibers, that maintain the gel structure [1].

A few cells called ialocytes located in the cortex, especially at the level of the base of the vitreous and in the zonular region. They are more numerous in the young adult and decrease with age [2]. Posterior vitreous

cortex contracted close relations with the macula, the nobel part of the retina, forming a complex anatomical unit known as vitreoretinal interface (VRI) [3].

The progressive vitreal syneresis with aging and vitreoretinal adhesions weakening lead to separation of the posterior cortex from the internal limiting membrane of the retina (ILM), phenomenon known as posterior vitreous detachment (PVD).

In the majority of cases, PVD remains asymptomatic or it causes symptoms such as floaters, cobwebs, without other complications [4].

However, in a few cases, the persistence of VMA exerting tractional forces (vitreomacular traction, VMT) may be associated with distortion of the macular architecture. Patients report symptoms such as blurred vision, photopsia, metamorphopsia or, in the final stages, a decrease in visual acuity led by the development of cystoid macula edema or macular hole. (Symptomatic vitreomacular adhesion, sVMA).

Only in this stage, VMA can determine a pathological process for macular anatomy [5].

Optical coherence tomography (OCT) explained the patogenesis of the VMT, improved the diagnostic accuracy and therefore the appropriateness of therapies [6].

Until few years ago pars plana vitrectomy with or without removal of the ILM (ILM peeling) was the gold standard for the treatment of VMT. However, as surgical procedure, it is associated with possible complications such as infection, bleeding, retinal detachment, cataract in phakic patients [7].

Pharmacologic Vitreolysis with enzymes, which can result in the liberation of VMT, facilitating the induction of a PVD, opened new fronteers for the treatment of VMT [8].

Many drugs like collagenase, dispase, natokinase, hyaluronidase, plasmin and plasminogen activator have been purposed as vitreolytic agents [9-14].

Ocriplasmin is a truncated subunit of human plasmin with aspecific proteolytic activity, capable of inducing liquefaction of the vitreous and separation of the vitreous cortex from retina [15].

Ocriplasmin (Jetrea, ThromboGenics) was approved for intravitreal use for the treatment of symptomatic VMT and MH by the Food and Drug Administration (FDA) in the United States, in November 2012 and by

the European Medicines Agency (EMA) in May 2013 [16].

In this study we presented the results about effectiveness and safety of a single intravitreal injection of ocriplasmin 125 µg across a group of patients with symptomatic vitreomacular adhesion (sVMA) during 6 months follow up.

Materials and methods

The study was designed as randomized, double-blind, placebo-controlled and was carried out in the Ophthalmology Department of " Sapienza" University' of Rome. We selected 28 patients, 12 males and 16 females, aged between 62 and 81 years (mean age 71 years old). All eyes were diagnosed of sVMA, highlighted by OCT. 22 eyes were phakic and 6 eyes were pseudophakic. 8 phakic patients of the total had full-thickness macular hole (FTMH). Five of these also suffered of ERM. 11 patients (9 phakic and pseudophakic 2) were diagnosed of epiretinal membrane (ERM) by OCT.

Inclusion criteria were: age of 18 years or older; focal sVMA diagnosed with OCT, BSCVA equal to or less than 20/25 (0.1 logMAR) based on the tables of Treatment of Early diabetic Retinopathy Study (ETDRS).

Patients with proliferative diabetic retinopathy, macular degeneration, retinal vascular occlusion, aphakia, high myopia (more than -8 diopters), uncontrolled glaucoma by therapy, macular hole above 400 µm in diameter, vitreous opacities, zonular instability, history of retinal detachment, recent vitrectomy, recent macular laser photocoagulation were excluded from the study.

The purpose of the study was to evaluate the efficacy and safety of a single injection of Ocriplasmin 125 micrograms in proteolytic resolution of symptomatic sVMA or FTMH closure.

Also the integrity of the external membrane and the inner and outer segments of the photoreceptor interface were evaluated using OCT.

The evaluation was carried out at baseline and during 6 months after intravitreal injection of ocriplasmin (**Table A**) or placebo (**Table B**).

Table A
Ocriplasmin subgroup: data at time of enrollment (t0) and during 6 months of follow up

Pt	Age	Sex	Lens	BCVA T0	BCVA 28 days after injection	FTMH	ERM	ØVMA (µm)	PVD	PVD (days after injection)	Vitrectomy
1	68	F	Phakic	20/25	20/20	-	-	435	+	1	-
2	70	F	Phakic	20/50	20/40	-	+	282	+	68	-
3	71	M	Phakic	20/100	20/30	+	+	250	+	28	-
4	57	F	Phakic	20/40	20/30	-	-	450	+	21	-
5	74	M	Phakic	20/60	20/40	+	-	391	+	42	-
6	76	M	Phakic	20/25	20/25	-	+	600	+	14	-
7	68	M	Phakic	20/60	20/25	+	-	115	+	2	-
8	68	F	Phakic	20/60	20/60	+	-	300	+	28	+
9	65	M	Phakic	20/30	20/25	-	-	377	-	-	+
10	62	F	Phakic	20/50	20/40	+	+	120	-	-	+
11	75	F	Pseudo- Phakic	20/80	20/60	-	-	250	-	-	+
12	77	F	Phakic	20/50	20/50	-	-	497	-	-	+
13	76	M	Phakic	20/200	20/200	-	+	>1500	-	-	+
14	68	F	Phakic	20/60	20/60	+	+	100	-	-	+
15	79	M	Pseudo- Phakic	20/80	20/80	-	+	>1500	-	-	+
16	81	F	Phakic	20/60	20/60	-	+	>1500	-	-	+
17	70	F	Phakic	20/70	20/200	-	-	400	-	-	+
18	81	M	Pseudo- Phakic	20/50	20/40	-	-	878	-	-	+
19	67	F	Pseudo- Phakic	20/40	20/40	-	+	398	-	-	+

Table B
Placebo subgroup: data at time of enrollment (t0) and during 6 months of follow up

Pt	Age	Sex	Lens	BCVA T0	BCVA 28 days after injection	FTMH	ERM	ØVMA (µm)	PVD	PVD (day after injection)	Vitrectomy
1	64	F	Phakic	20/40	20/25	-	-	200	+	28	-
2	69	F	Phakic	20/60	20/60	-	-	281	+	90	-
3	80	M	Pseudo- Phakic	20/40	20/50	-	-	164	-	-	+
4	73	F	Phakic	20/80	20/100	+	-	650	-	-	+
5	67	M	Phakic	20/100	20/100	-	-	840	-	-	+
6	77	F	Phakic	20/60	20/50	+	+	>1500	-	-	+
7	71	M	Phakic	20/80	20/80	-	-	400	-	-	+
8	67	M	Pseudo- Phakic	20/40	20/50	-	+	384	-	-	+
9	72	M	Phakic	20/25	20/30	-	+	120	-	-	+

Treatment was randomized with a single intravitreal injection of ocriplasmin or placebo. Before signing informed consent, all patients were informed extensively on the benefits and possible complications of the injection. Institutional Review Board (IRB)/Ethics Committee approval was obtained. The ratio of administration of ocriplasmin and placebo was 2:1. 19 patients received the ocriplasmin and 9 placebo. All implants were performed under sterile operating room conditions, using 5% povidone-iodine solution, topical anesthetic with ropivacaine [17].

The single intravitreal injection contained 125 micrograms of ocriplasmin in 0.10 ml of solution. The injection of placebo contained 0.10 ml withdrawn in the same way and containing the same saline solution without the ocriplasmin. Postoperative therapy consisted in ofloxacin drops 4 times a day for 7 days after the treatment. All patients were monitored for local or systemic adverse effects relative to the implant for the duration of the whole study.

The evaluations were performed at the moment of enrollment and during a follow up period which included the first day after the injection (T0), 7 days after injection (T1), 14 days after injection (T2), 28 days after injection (T3), 90 days after injection (T4) and 180 days after injection (T5). Each evaluation included best corrected visual acuity (BCVA) by the boards of ETDRS placed at distance of 4 meters, biomicroscopy with a slit lamp, measuring intraocular pressure (IOP) with Goldman applanation tonometry, binocular indirect ophthalmoscopy after pupillary dilation, B-scan ultrasonography, Spectralis HRA-OCT Heidelberg Engineering, fundus photography.

Patients compiled the National Eye Institute Visual Functioning Questionnaire-25 (VFQ-25), Version 2000.

We considered the efficacy of the injection as a mean improvement of BCVA \geq 10 letters (2 lines).

Pars plana vitrectomy was considered when patient presented one of the following parameters: worsening of the underlying disease; visual acuity decrease of more than two lines on boards of ETDRS; no improvement 28 days after injection.

Results

Data about results are summarized in Tables A (Ocriplasmin group) and B (Placebo group).

The primary endpoint of the study was the resolution of sVMA after a single injection of 125 micrograms of Ocriplasmin. After a 6 months follow-up period, 42.1% of patients of the Ocriplasmin group had a complete resolution of VMA compared to the 22% in the placebo group.

Considering the subgroup of phakic patients, the resolution of VMA were found in 34.2% of patients of

Ocriplasmin group compared to the 25% of the placebo group. Among the pseudophakic patients any resolution of VMA was observed.

In the Ocriplasmin group, two of eight patients with ERM (25%) and five of eleven without ERM (45%) had a non-surgical resolution of VMA compared to the 0% and 33 % respectively in the placebo group. Four of six patients (66.2%) affected by FTMH treated with Ocriplasmin had resolution of VMA and three of these (50%) achieved complete closure of the hole. Four (31%) of the remaining patients without MH, had the resolution of VMA.

Two patients in the placebo group, affected by FTMH, had not clinical improvement.

The mean BSCVA of all patients was 63 letters on the EDTRS boards (0.38 to 0.48 logMAR; Snellen from 20/50 to 20/60).

In the Ocriplasmin group, BSCVA remained unchanged in 42.1% of patients.

Eight patients had a modest improvement (less than 2 EDTRS lines) and two patients had a significant improvement (more than three EDTRS lines). Only one patient of all groups had visual impairment from 20/70 to 20/200, leading by the progression of the VMT in FTMH. Patients who had been given placebo had no significant improvement or loss of visual acuity.

Regarding safety, any case of uveitis, endophthalmitis, retinal tears, retinal detachment or bleeding during follow-up were reported. One patient reported floaters and transitional photopsias.

Discussion

Ocriplasmin intravitreal injection represents a new therapeutical option that can contribute to a better management of vitreoretinal interface diseases. Our results about incidence of VMA resolution are consistent with data reported in Literature [18]. In our study the rate of VMA resolution was 42%. Pharmacologic action of ocriplasmin appeared to be greater in the first month after the injection. In fact, the most improvement has occurred during the first 28 days of treatment and remained stable in the subsequent six months (Fig.1).

Clinical features as VMA diameter of less than 1.500 micron, presence of a full-thickness macular hole (FTMH), age <65 years old and being phakic patient are critical for a better response to therapy.

The main symptom of VMT is the decrease in BCVA. BCVA improvement in the Ocriplasmin group was superior to placebo group. It could appear a modest improvement. However, in these patients, mean preoperative BCVA was relatively good (64 ETDRS letters corresponding to 20/50 on the Snellen scale). At the same time, patients with a poor preoperative BCVA had a significant visual recovery (three or more lines of letters on EDTRS chart).

This could seem a limitation of the study, but early treatment of VMT could prevent the progression of the disease indeed.

No adverse effects related to Ocriplasmin injection were observed during the follow-up period, even though retinal tears, retinal detachment, vitreitis and bleeding were reported in the Literature [19]. One patient complained of floaters and photopsias, but they were transient symptoms and resolved during the follow-up

period. At 6 months follow-up, Ocriplasmin resulted efficient, with substantial improvements in BCVA values due to a significant resolution of VMT (**Fig.2**) and FTMH (**Fig.3**).

About the safety profile, the drug resulted well tolerated and no complications related to the injection nor the drug itself emerged, in accordance with Literature [20-21].

Figure 1

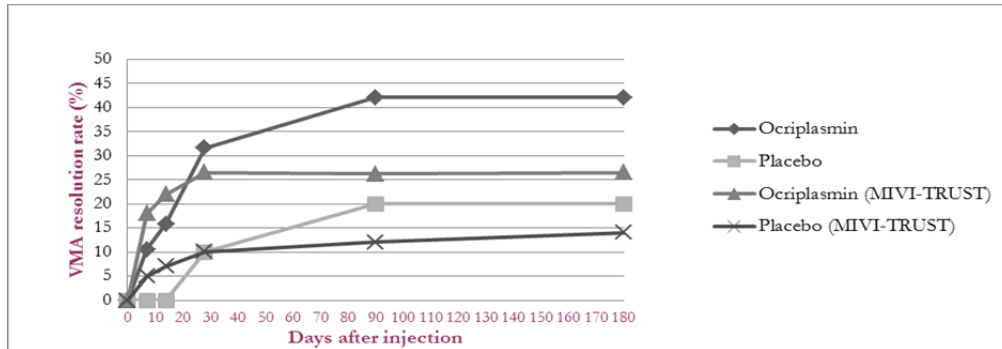


Figure 2: VMA resolution rate

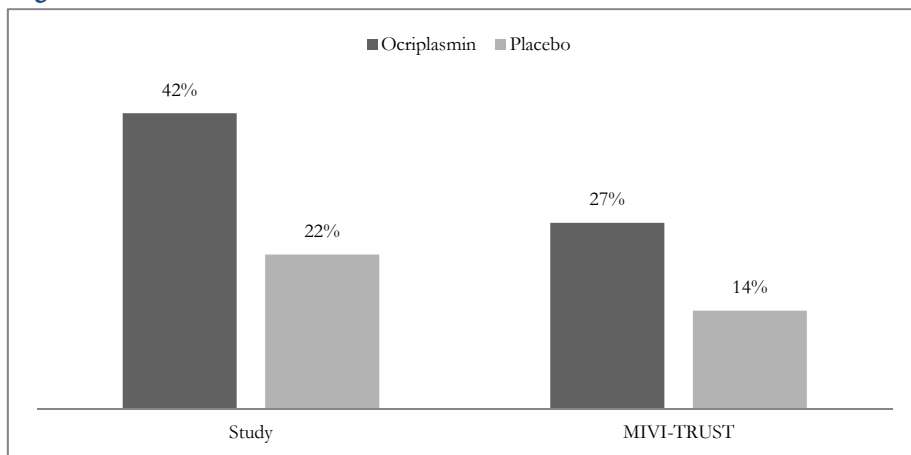
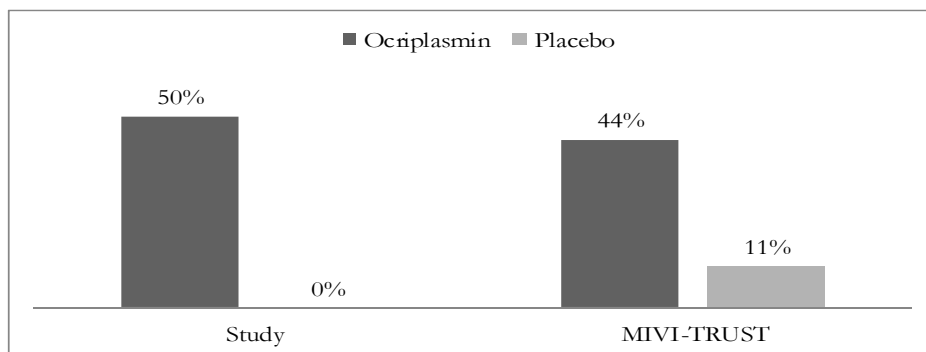


Figure 3: FTMH closure rate



In conclusion, our study confirms that ocriplasmin injection represents an efficient and safe treatment option for patients with VMT, including when associated with full-thickness macular holes $\leq 400 \mu\text{m}$ in diameter. These results are stable during six months. Long term studies are certainly needed to confirm these results

References

1. Bishop PN “ Structural macromolecules and supramolecular organisation of the vitreous gel ”. *Prog Retin Eye Res* 2000, No. 19, 323-344.
2. Sebag J, “Ageing of the vitreous” *Eye*, vol. 22, pp. 1214–1222, 2008.
3. Bishop, PN; Holmes DF; Kadler E et al. “ Age-related changes on the surface of vitreous collagen fibrils “ 2004, No. 45, 1041–1046.
4. Larsson L, Osterlin S.” Posterior vitreous detachment: a combined clinical and physiochemical study” *Graefes Arch Clin Exp Ophthalmol*. 1985;223(2):92-95.
5. Johnson MW, “ Posterior vitreous detachment: evolution and complications of its early stages ” *The American Journal of Ophthalmology*, vol. 149, no. 3, pp. 371–382, 2010.
6. Gallemore RP; Jumper JM.; McCuen “ Diagnosis of vitreoretinal adhesions in macular disease with optical coherence tomography “ *Retina* 2000, No. 20, 115–120.
7. Melberg, N; Williams D; Balles MW et al “ Vitrectomy for vitreomacular traction syndrome with macular detachment “ *Retina* 1995, No. 28, 192-197.
8. Khoshnevis M, Sebag J.” Pharmacologic vitreolysis with ocriplasmin: rationale for use and therapeutic potential in vitreo-retinal disorders” *BioDrugs*. 2015 Apr;29(2):103-12.
9. O’Neill, R.; Shea, M. “The effects of bacterial collagenase in rabbit vitreous” *Can. J. Ophthalmol*. 1973, No. 8, 366-370.
10. Stenn, K. S.; Link, R.; Moellmann, G.; Madri, J.; Kuklinska, E. “ Dispase, a neutral protease from *Bacillus polymyxa*, is a powerful fibronectinase and type IV collagenase” *J. Invest. Dermatol* 1981, No. 93, 287–290
11. Jorge, R.; Oyamaguchi, E. K.; Cardillo et al. “Intravitreal injection of dispase causes retinal hemorrhages in rabbit and human eyes ” *Curr. Eye Res*. 2003, No. 26, 107-112.
12. Wang, F.; Wang, Z.; Sun, X.; Wang, F.; Xu, X.; Zhang, X. “ Safety and efficacy of dispase and plasmin in pharmacologic vitreolysis “ *Invest. Ophthalmol. Vis. Sci* 2004, No. 45, 3286–3290.
13. Narayanan, R.; Kuppermann, B. D. “ Hyaluronidase for pharmacologic vitreolysis “ *Dev. Ophthalmol*. 2009, No. 44, 20-25.
14. Kuppermann, B. D.; Thomas, E. L.; de Smet, M. D.; Grillone, L. R. “ Vitrase for Vitreous Hemorrhage Study Groups. Pooled efficacy results from two multinational randomized controlled clinical trials of a single intravitreal injection of highly purified ovine hyaluronidase (Vitrax) for the management of vitreous hemorrhage “ *Am. J. Ophthalmol*. 2005, No. 140, 573-584.
15. Girach, A.; Kozma-Wiebe, P.; Pakola, S. Knowledge for Growth. “ Ocriplasmin as treatment for symptomatic vitreomacular adhesion: Phase III trial results “ *Gent*, 2012
16. Ocriplasmin (Jetrea) (125 mcg Intravitreal Injection): For the Treatment of Symptomatic Vitreomacular Adhesion. Canadian Agency for Drugs and Technologies in Health; 2014 Jan.
17. Pacella F, Collini S, Turchetti P, Smaldone G, Troisi F, Salducci M, Pacella E “ Ropivacaine vs tetracaine in topical anesthesia for intravitreal injection “ *Senses Sci* 2015; 2 (4):106-110
18. Pravin U. Dugel “ A Single Injection Of Ocriplasmin For The Treatment Of Symptomatic Vitreomacular Adhesion (sVMA): Results Of The Phase III MIVI-TRUST Program” *MIVI-TRUST Study Group Investigative Ophthalmology & Visual Science* April 2011, Vol.52, 6628.
19. Jager, R. D.; Aiello, L. P.; Patel et al “ Risks of intravitreal injection: a comprehensive review”. *Retina* 2004, No. 24, 676-698.
20. Kaiser PK, Kampik A, Kuppermann BD et al. “ Safety profile of ocriplasmin for the pharmacologic treatment of symptomatic vitreomacular adhesion/traction ” *Retina*. 2015 Jun;35(6):1111-27.
21. García-Layana A, García-Arumí J, Ruiz-Moreno JM et al “ A review of current management of vitreomacular traction and macular hole “ *J Ophthalmol*. 2015;2015:809640.