



**SAPIENZA**  
UNIVERSITÀ DI ROMA

# Personal identification of living people and corpses: usefulness and reliability of intraoral scanners and 3D technologies in modern forensic dentistry

**Facoltà di Medicina e Odontoiatria**  
**Dipartimento di Scienze Odontostomatologiche e Maxillofacciali**  
**Dottorato di Ricerca in Tecnologie Innovative nelle Malattie dello**  
**Scheletro, della Cute e del Distretto Oro-Cranio-Facciale**

**Dott.ssa Alessandra Putrino**  
**Matricola 944554**

Relatore  
Prof.ssa Gabriella Galluccio

Correlatori  
Prof. Enrico Marinelli  
Prof. Andrea Pilloni

A.A. 2017-2018

## Index

1. Introduction .....	4
2. Personal identification methods in dentistry .....	11
2.1. Dental Analysis .....	14
2.2. Bite marks .....	19
2.3. Age estimation on dental records .....	23
2.4. Sex determination on dental records .....	26
2.5. Race determination on dental records .....	28
2.6. Cheiloscopy .....	30
2.7. Rugoscopy .....	32
2.8. Oral autopsy .....	39
3. Intraoral scanner technology .....	44
4. Objectives .....	50
5. Materials and Methods .....	51
6. Results .....	66

7. Discussion .....	100
8. Conclusions.....	110
9. Bibliography .....	112

## 1. Introduction

Forensic dentistry (or forensic odontology) is that branch of forensic science that exploits the skills of the dentist to determine the recognition of the person, whether living or deceased, for investigative purposes or justice processes. According to the definition of Keiser-Neilsen, forensic dentistry is the discipline that “in the interest of justice deals with the proper handling and examination of dental evidence and the proper evaluation and presentation of dental findings”<sup>1</sup>. In cases of mass disasters or incidents such as air plane crashes, train/ road accidents, terrorist attacks, bomb blasts or natural events like earthquakes, tsunamis, land slide and in all those cases where a more or less wide number of human remains (especially those mutilated and dismembered) are beyond recognition, in cases of sexual assaults and/or abuse on children and adults, in cases of finding unknown persons for whom the attribution of an identification is necessary or in finding human remains that include the head and oral cavity or part thereof (for example, only the mandible or skull with the nasomaxillary complex but devoid of the mandible), in cases

of malpractice and negligence in which the principles of forensic dentistry are applicable, the expert odontologists may provide the help key to the authorities by providing their expertise through dental data and through all information related to them with mainly comparative methodologies (Fig.1).



*Figure 1 Forensic Odontology, inspection on human remain*

The history is full of famous examples that lead to think like the "seed" of forensic dentistry, as we know it today, was already present when the processes of personal identification related to the dental characteristics

were certainly not comparable to the rigour of modern science methodology. An example of all is the one involved Agrippina, the mother of Roman emperor Nero. In 66 AC, she demanded to see Lollia Paulina's head as proof of her death and she recognized her rival by the distinctive presence of her discolored front teeth<sup>2</sup>. Another famous process of recognition on which has been much debated over time (this affair has affected experts since the death of Hitler until the years '80), less fictionalized and more significant than the case of Agrippina, for the historical and methodological weight is that made on the remains of bodies, whose identity was as a result of the analysis attributed to Adolf Hitler and Eva Braun, through the use of ante-mortem dental data<sup>3,4</sup> (Fig.2).

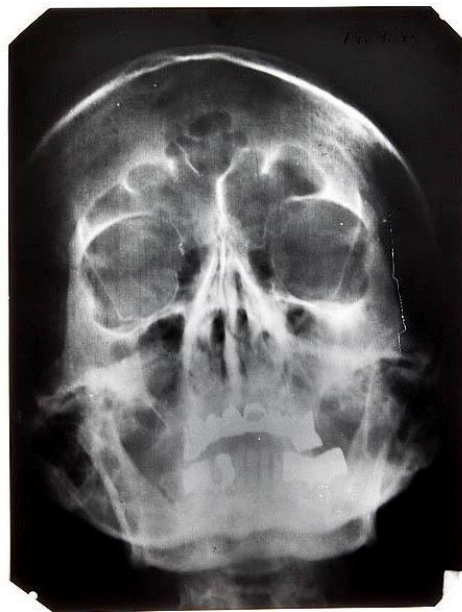
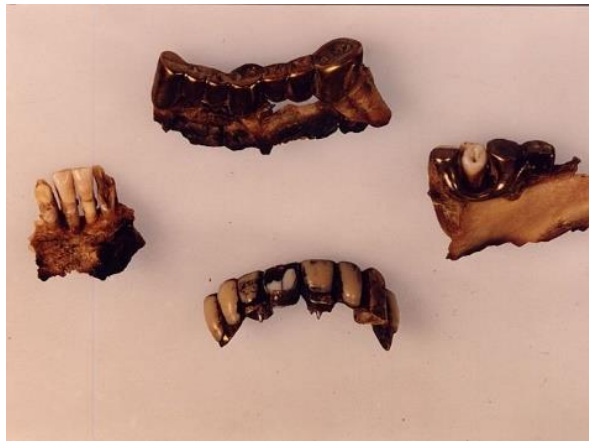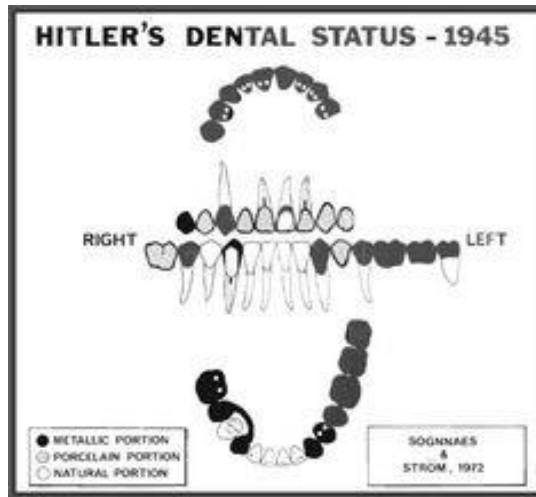
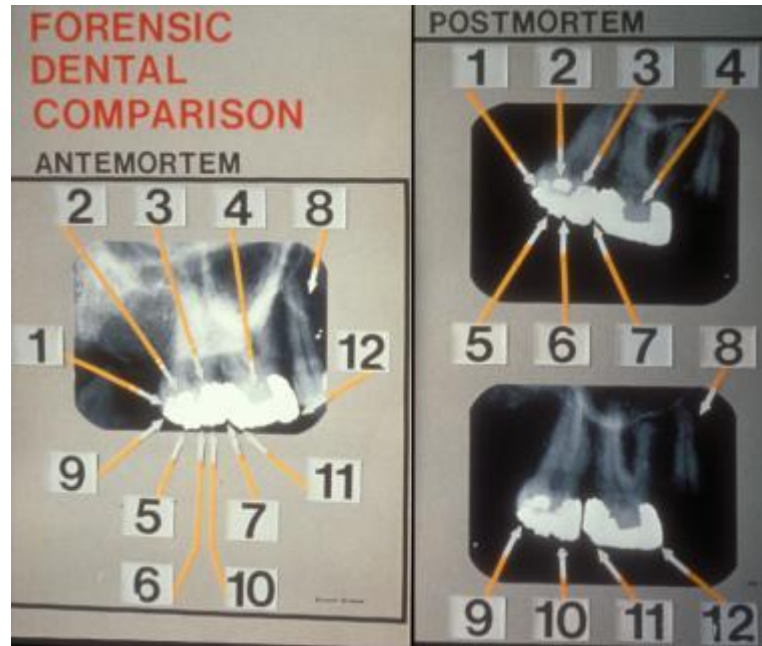


Figure 2 Hitler's dental records used for his personal identification

From the past to today the identification methods of odontologist competence have been enriched of new tools. To those of an exclusively dental nature, which mainly lead to comparative methods between ante-mortem data or between ante-mortem and post-mortem data (in example, comparison between data collected during intraoral inspection and X-rays or plaster models of subject of which identity is suspected) (Fig.3), high-reliability methods such as rugoscopy and cheiloscopy and and bite marks and oral autopsy on cadaver have been associated. The latter, unlike the previous ones, for the remarkable invasiveness, being a real complex surgical procedure, plays a role as important as it is critical because, with the methods currently documented, it entails a profound alteration of the face of the subject with important ethical and legal implications.





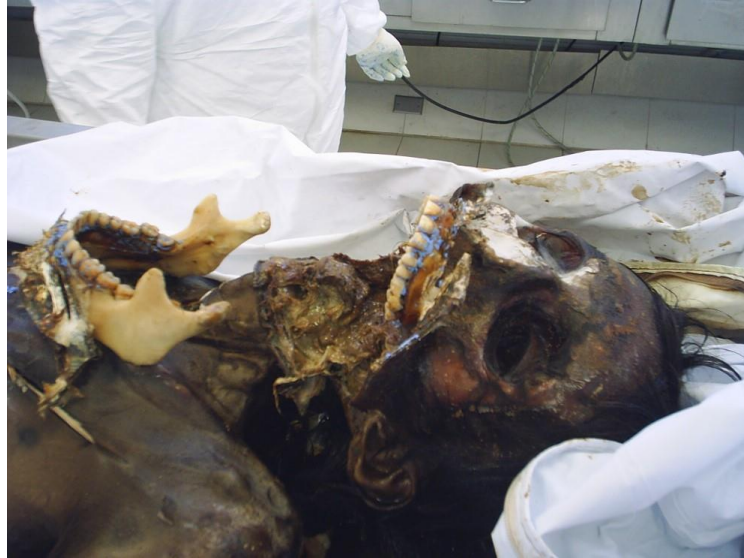*Figure 3 Radiographic Comparison between ante-mortem periapical radiographs and post-mortem periapical radiographs*

The main objective of this thesis work that is the fruit of this research project is to demonstrate how the modern and latest technologies available to the daily dental clinic practice, combined in particular to the specialist skill in orthodontics, can help redefine the methods of personal identification according to the levels of accuracy, trueness and feasibility greater than those applied in traditional forensic dentistry. To do so will first follow a descriptive section on methods to date in use as reported in the literature and subsequently the presentation of the experimental work

that was conducted using an intraoral scanner device both on a sample of orthodontic patients and on a control group but also, for the first time in the world, on corpses.

## 2. Personal identification methods in dentistry

The teeth and the oral structures have individual characteristics that make each individual unique and unrepeatably<sup>5</sup>. For this reason, as is the case for fingerprints and DNA, the mouth is a very important source for the processes of personal identification. Where the other means of identification are destroyed, deeply altered (Fig.4) or voluntarily removed (fingerprints can be deleted) or when the use of other techniques would be wasteful because it is necessary to apply them on a large number of subjects (DNA analysis is more expensive), the oral cavities are the strongest part of the human body withstanding the most serious chemical and physical injuries (Fig.5).



*Figure 4 Corpse deeply altered. Traditional dental impressions taken for ante-mortem data comparison.*

Primary and adult human dentition vary in morphology, size, volume and sometimes structure among different individuals constituting the basic set of unique characteristics called “tooth class characteristics” for identification. Other features like restorations, prosthesis, dental pathologies and anomalies contribute to defining the “dental identity”<sup>6</sup>. From teeth, we can estimate the biological profile and determine the age, the gender, and the ethnicity<sup>7-12</sup>. The evidence in forensic dentistry is obtained also with no dental records as rugoscopy, cheiloscopy and oral autopsy. These methods should not be considered to be less precise than the dental analysis, but should also be considered as complementary to the

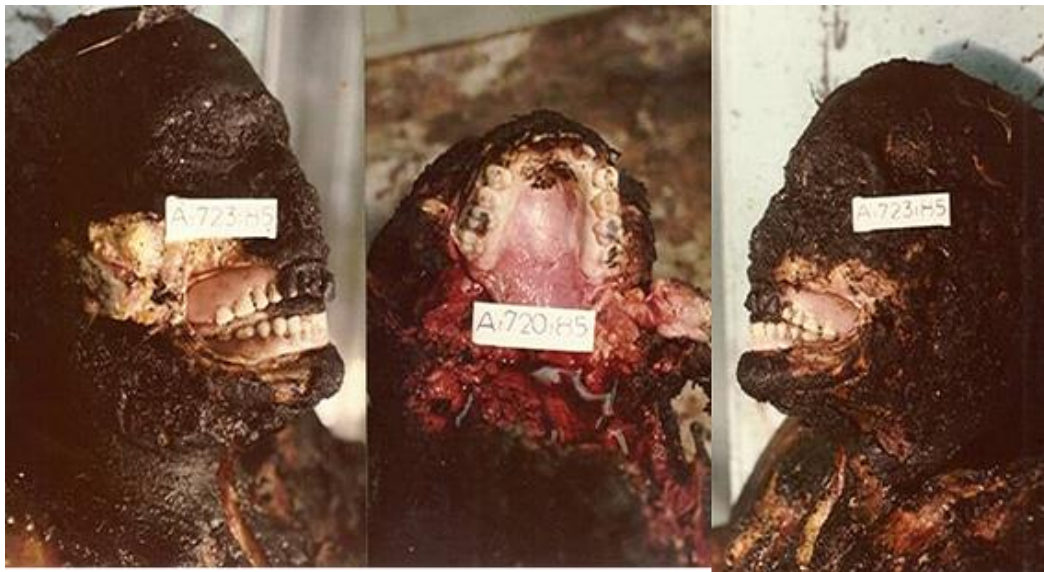
identification or altogether essential (especially for the rugoscopy) when dental analysis it is not a conclusive or workable test.

All these characteristics however, may not be useful to the forensic processes in absence of ante-mortem dental records and where comparison of the post-mortem records with ante-mortem records is not possible. For this reason it would be necessary and of great importance to hope for the preservation of data and the creation of a "dental" database as well as the communities of the different countries already have it for fingerprints.

## 2.1. Dental Analysis

Even though the status of a person's teeth change throughout the entire life, the presence of distinctive features as the presence of restorations, prosthetics, alterations of tooth structure including caries and the absence itself of some teeth plays a key role when identification concerns mutilated subjects on which it is not possible to perform the fingerprint test or the visual recognition. It is possible to use identification through dental analysis especially when the corpse is skeletonized or decomposed by burns, carbonization, drowning, and action of acids or other substances causing irreversible chemical damage to the body structure. Indeed dental hard tissues are well preserved after death and can even resist a temperature of 1600°C when heated without appreciable or significant loss of microstructure<sup>1</sup> (Fig.5). Odontological identification of deceased persons obtained by dental evidence can be complicated by traumas affected the jaws or by inadequate ante-mortem dental records like dental plaster models and dental radiographs<sup>7, 13</sup>. The main dental identification method is based on the comparison of pre and post-mortem dental

features of the person under recognition process using dentist's patient documentation<sup>14,15</sup> or with photographs, available with the family, showing the subject smiling when he was still alive, although to be useful it is necessary that at least the frontal anterior teeth are clearly visible<sup>16</sup>.



*Figure 5 Carbonized corpse with a perfect preserved dentition and palatal vault.*

Following the American Board of Forensic Odontology dental identification can be divided into four types<sup>2,17</sup>:

1. Positive identification: ante-mortem and post-mortem data match to establish that it is from same individual;

2. Possible identification: ante-mortem and post-mortem data have few consistent features, but because of quality of the records it is difficult to establish the identity;

3. Insufficient evidence: data is not enough to form the conclusion;

4. Exclusion: The ante-mortem and post-mortem data are clearly inconsistent.

In cases of insufficient evidence or exclusion, further methods are necessary.

When handling dentition data, the international nomenclature system is used. All salient dental features are collected and recorded to be compared with ante-mortem dental data. The presence of dental restorations or decayed teeth, the crowding and abnormal position of one or more teeth, the presence of spacing for extractions, missing teeth or natural diastema, the presence of supernumerary teeth or cusps, the root or crown configuration are all characteristic features can help in dental profiling.

Among all the dental anomalies those related to morphology and volume,



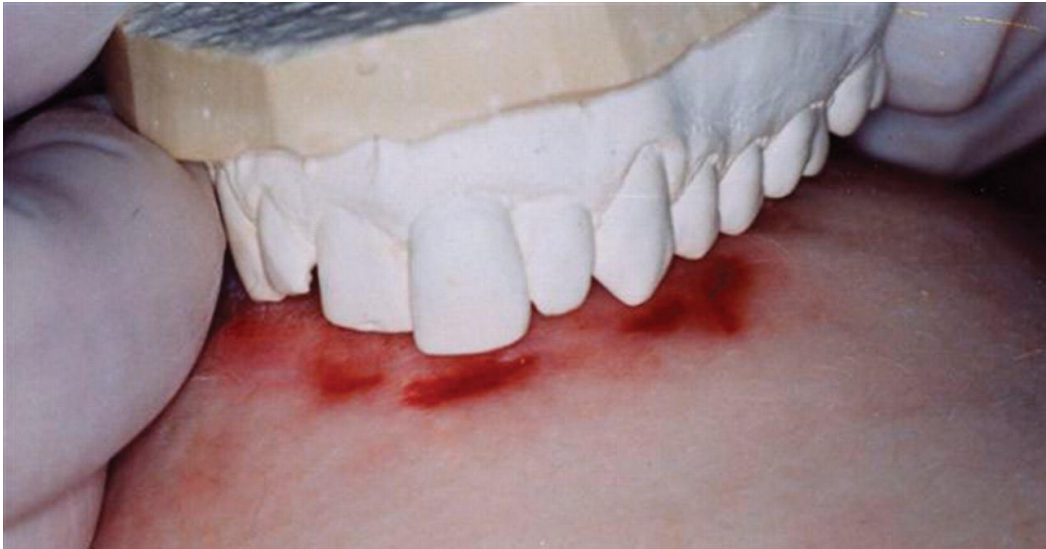those have most relevance in the forensic field: disturbances in shape such as dilaceration, flexion, taurodontism, peg shaped lateral incisors, simplification of shapes, talon cusp, supernumerary cusps such as Carabelli's cusp, shovel shaped incisors, variations in roots' number. Dental identification can be affected also by size anomalies such as microdontia and macrodontia and disturbances in the number of teeth such as anodontia, hypodontia, oligodontia and polydontia or hyperdontia. Also structure abnormalities such as cases of enamel hypoplasia or forms of amelogenesis and imperfect dentinogenesis may constitute distinctive elements of dentition<sup>18</sup>. When teeth fail in their eruption and remain impacted or when their eruption pathway bring them to an anomalous position (dental ectopy) this phenomenon can lead to the establishment of an oral status characteristic of that subject influencing personal identification process<sup>19</sup>. As we know from the basic concepts of orthodontics, the relationship between the upper jaw and the mandible defines the characteristics of an occlusion. The occlusion can be normal or altered both on the vertical plane and on the transverse and

sagittal ones. It is clear that the presence of a normocclusion may not be in itself a distinctive feature in a subject. Conversely, the presence of a second or third class malocclusion, as well as an alteration of the overjet and overbite parameters and the presence of any anterior or posterior scissor bite or cross bite may represent distinctive signs of a subject. They are almost always easily replicable even from the observation of the dentition of a corpse of which it is necessary to ascertain the identity, exceeded the stiffening phase of the body and with appropriate manipulation of the mandible even in case of fractures. The use of dental plaster models of suspected identity is a great help for the study of malocclusion also for forensic purposes<sup>20</sup>. All the dental anomalies and variations mentioned above help in the comparison and matching of ante-mortem and post-mortem data leading to a positive identification. The value of this method is comparable to the quality and precision of DNA profiling and fingerprints analysis.

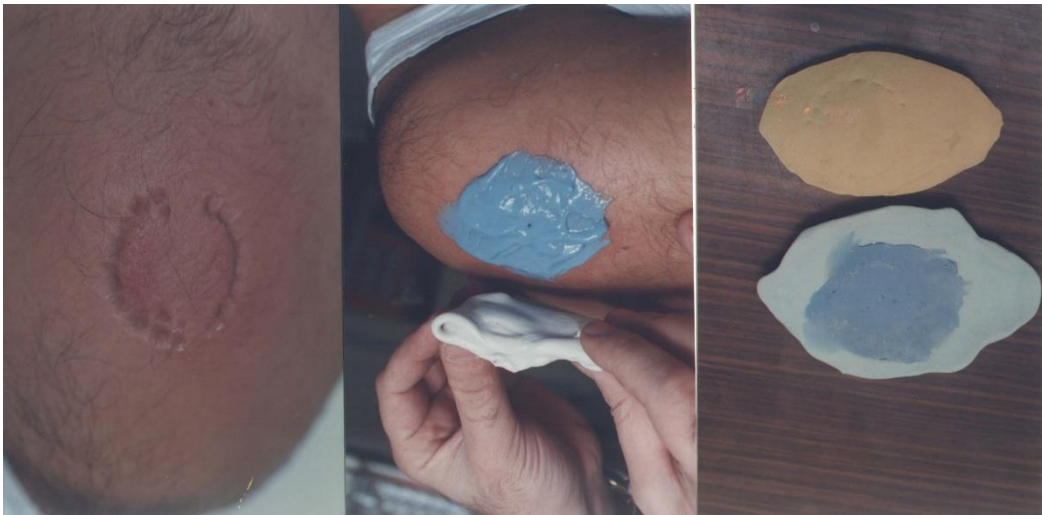## 2.2. Bite marks

A bitemark has been defined as “a pattern produced by human or animal dentitions and associated structures in any substance capable of being marked by these means”<sup>21</sup>. They can be classified also as examples of ‘crush’ injuries, due to the dental compression of the skin and soft tissues, leaving indentations or provoking a real injury in the skin<sup>22, 23</sup>. This action leaves indentations and/ or breaks in the skin. Bitemarks can provide evidence in those cases of sexual assaults or abuse and become a source to extract the assailant DNA<sup>24</sup>. The bitemark left by human teeth is classically a circular or oval mark (bruise) with central sparing. There are differences of dimensions related to the kind of dentition (primary or adult) and the extension of the bitemark too can be reduced if it is limited to a part of dental arch. They are usually produced in dynamic scenes, this feature reduces the clarity of the sign. Dentists and forensic odontologists are called to investigate on these marks and the classical procedure entails that the bitemark is compared with the impression and dental plaster of the suspect's teeth (Fig.6).

The aim is to identify adequate correspondence between the main shape and size of the teeth of an accused with the features of the bitemark (Fig.7).



*Figure 6 high correspondence between bite-mark and dental plaster model.*

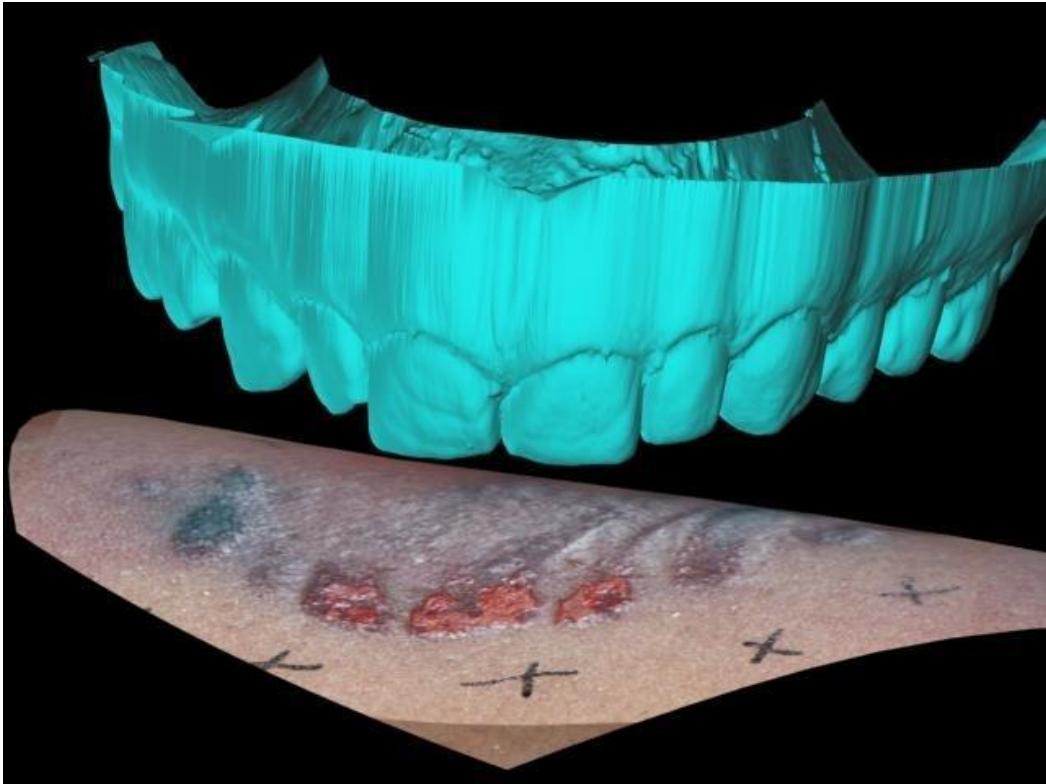


*Figure 7 Classic bite-mark impression and model. It will be compared with ante-mortem data.*

All those distinctive features of dentition such as dental malposition, crowding, missing or damaged teeth can affect the bitemarks and they can be reasonably considered reference points in the comparative analysis<sup>25</sup>.

Traditionally, the comparison between the bitemark and the suspect's teeth was based on a process of superimposition involved the occlusal surfaces of a dental model of the suspect's teeth, specially stained on ink, and marking the teeth 'bite' pattern onto a transparent sheet (in acetate)<sup>26</sup>.

With the advent of new technologies, the limits of this procedure, which have always been discussed and looked at with a certain distrust in the forensic field, have been partly overcome thanks to software that allows the digital overlap of the bitemark photos to digital models<sup>27, 28</sup>(Fig.8).



*Figure 8 Digital superimposition between digital model and photograph.*

### 2.3. Age estimation on dental records

In the last decades, the problem of age estimation does not concern only unidentified corpses but above all living persons have no valid proof of date of birth<sup>29</sup>. We can distinguish two main methodological categories in dental age estimation<sup>30</sup>.

1) Developmental changes: occur while the teeth are growing and emerging into the oral cavity. They include hard tissues changes, dental eruption and the specific third molar eruption and dental measurements.

2) Degenerative changes: occur once teeth have erupted and begin to wear down.

Developmental changes related hard tissue modifications start since teeth start their formation, around six month. The exact sequence of formation and eruption of teeth allows to accurately estimating age. The basic principle is the comparison between teeth scores and a corresponding chart<sup>31</sup>, such as in the famous Demirijan's method<sup>32</sup>. The comparison between post-mortem radiographs of a person under personal

identification process and eruption standards lead to the estimation of age, since humans have two stages of dentition, and a mixed stage<sup>31</sup>. Third molars are the last teeth to erupt and also those with the highest variables: they can be partially or at all impacted and their missed eruption after 20 years old can indicate they are absent at all. Only radiographs can reasonably show their presence, position and relations with the adjacent structures<sup>30</sup>. Dental length can be directly assessed, using the crown or the exposed root and then compared with radiographic measurements. Dental mineralization is less affected than bone by nutritional and endocrine factors<sup>8</sup>.

Once the teeth are erupted in the dental arches and begin to perform their masticatory and functional functions, they obviously begin to undergo alterations that accompany the progress of age with signs that can be very characteristic and aid in determining the age of a subject. One of the most characteristic examples in the context of the degenerative changes useful in the determination of age is the observation of the pulp volume that reduced progressively with the passage of time for a process of secondary



dentin deposition<sup>33</sup>. Another method of age estimation in adults by measuring the size of the pulp is taking the measurement from periapical radiographs of the teeth dependent upon the sex of the individual<sup>34</sup>. The most complete method of age estimation based on regressive changes has been developed primarily by Gustafson, and later by Johnson. These methods consider changes affect teeth for the occlusal attrition, the loss of periodontal attachment, the dentine and cementum apposition, the amount of periapical resorption, the root transparency<sup>35, 36</sup>.

## 2.4. Sex determination on dental records

Sex determination is the first question in identification of unknown individuals, especially when other evidence for sex determination is present. As for the other distinctive features defining and detailing the individual, this parameter often need to be confirmed with the help of many methods, because sex determination from teeth may be not conclusive. Sex determination in forensic odontology starts from odontometrics' technique<sup>9, 37</sup>. This is based on the differences between the mesio-distal and bucco-lingual dental dimensions, recorded like linear multiple measurements that are subsequently compared<sup>38, 39</sup>. Sexual dimorphism in the teeth can be showed using different dental indices: crown index, incisor index, mandibular-canine index<sup>40-42</sup>. This last one index is considered one of the more reliable in sex determination since these teeth exhibit a greater sexual dimorphism compared to upper canines with an overall accuracy established around ~72%<sup>43</sup>. The canine distal accessory ridge located on the lingual surface (between the medial lingual ridge and distal marginal ridge) has been found to be more

pronounced and more frequent found in males than females<sup>44</sup>. In the last years a laboratory method has been developed: the sex chromatin or Barr bodies extracted from the pulp help in sex identification<sup>45-47</sup>. The Amelogenin, called also "AMEL", is the major protein found in human enamel. Two different genes express for AMEL: one is located on chromosome X and one on the Y chromosome. The patterns of nucleotide sequence show differences in males and females<sup>45, 47</sup>. Amelogenin has different patterns of nucleotide sequence in the enamels of males and females<sup>48-50</sup>.

## 2.5. Race determination on dental records

The possibility of identifying race or ethnicity from certain dental characteristics is still subject to debate today. Indeed there are dental traits that may be characteristic of some populations but their influence on racial individual identity is critical and needs to be supported by other elements. Sometimes some dental characteristics are mostly referable to habits, activities or related to the environment in which an individual lives, so they can be referred to the ethnicity only secondarily and by deduction, finding a relationship between that trait Characteristic dental and that particular ethnic group. This consideration is more evident for the shovelling or scooping of the upper incisor (most common in Asiatic Mongoloids and Amerindians), chisel shaped incisors. Other features such as taurodontism, peg shaping of the teeth, Carabelli's cusp of the first upper molars, hypocone, and protostylid, are used to determine the racial profile but their power in this meaning is much more weak than other parameters<sup>51-53</sup>. The provenience of an individual, more than a specific

ethnicity, may be in some cases indicated by dental restoration features, because some methods or materials may be typical of a place<sup>54</sup>.

## 2.6. Cheiloscopy

Labial wrinkles have the same value as fingerprints, this is the reason why the method of cheiloscopy is a valid forensic investigation add evidence to a crime scene, in example on glasses, windows, cigarette butt, or tapes (if a person has been gagged or bound), especially when other evidence are weak or totally absent<sup>55</sup>. The lip prints indeed can be easily left on many surfaces where they pressed up against. There are four types of lip grooves: straight line, curved line, angled line, sine shaped line<sup>2</sup>. Lip print patterns often appear as a mixture of varying types even though we can distinguish five main pattern: vertical, partial vertical, branched, intersected, reticular (Fig.9) . There is a probable genetic inheritance since twins and family members showed similar grooves<sup>56</sup>. The lip print pattern is anyhow unique to each individual and remain unaltered during a person's lifetime. They can be altered by pathologies or environmental factors but only those events or pathologies affect the labial subtrack can irreversibly damage lip prints, in light traumas or not severe pathologies they use to repair without any change and to maintain their pattern. Lip

prints similarly to finger prints may be visible or not visible. Many reagents can be used to make latent lip prints visible<sup>56,58</sup>. Lip print analysis is very simple and not expensive, but the absence of a standard protocol to collect, record and analyse lip prints data reduce their judicial value as test document<sup>59,60</sup>.

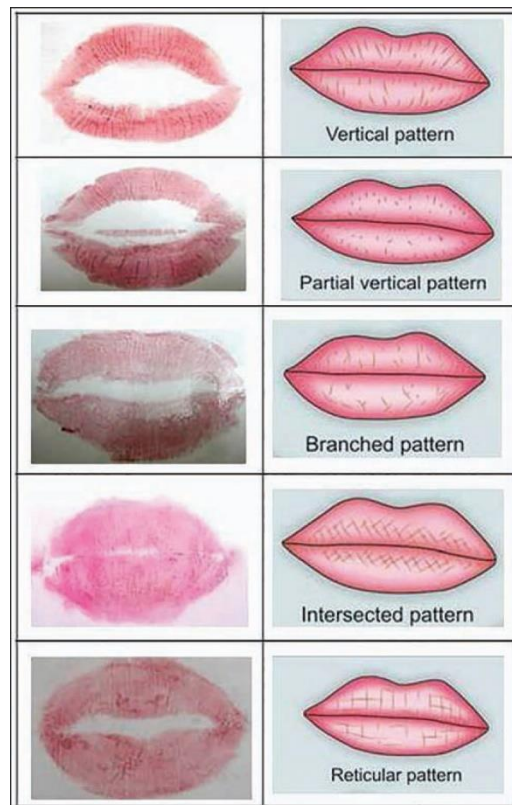


Figure 9 Cheiloscropy patterns (Gugulothu RN, Alaparathi RK, Maloth KN, Kesidi S, Kundoor V, Palutla MM. Personal identification and sex determination using cheiloscropy. *J Indian Acad Oral Med Radiol* 2015;27:399-404.).

## 2.7. Rugoscopy

The analysis of palatal rugae named also rugoscopy or palatoscopy is one of the most important and challenging applications of forensic methods for personal identification. The use of palatal rugae for forensic purposes started in 1889 with Harrison Allen, but the name of “palatal rugoscopy” has been properly introduced later, in 1932, by Trobo Hermosa<sup>61</sup>. Then many classifications followed in the years (Tab. 1), according to different features like shape, direction, position, length, unification.

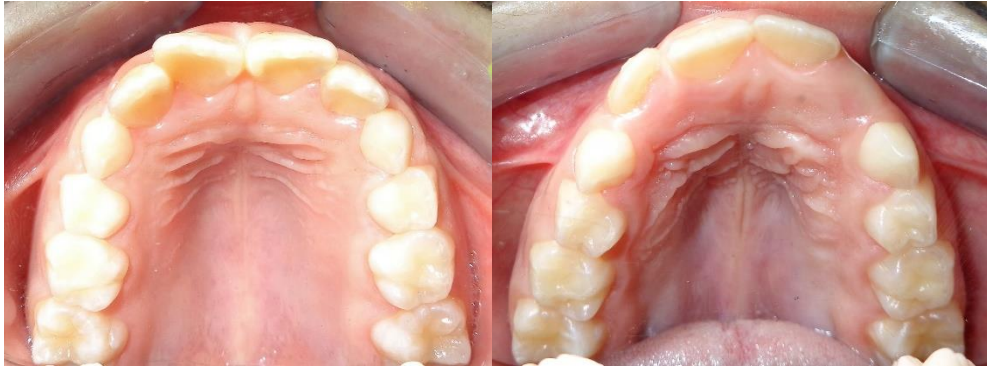*Table 1 Authors classified palatal rugae listed by year.*

Goria	1911
López De León	1924
Trobo	1932
Carrea	1937
Martins Dos Santos	1946
Lysell	1955
Basauri	1961
Lima	1968
Tzatcheva and Jordanov	1970
Thomas and Kotze	1983

Palatal rugae is relevant for human identification due to the internal position, stability and maintainance after death<sup>62</sup>. Palatal rugae also called as rugae or plicae palatinae refers to the transverse ridges on the anterior part of the palatal mucosa on each side of the median palatal raphe and



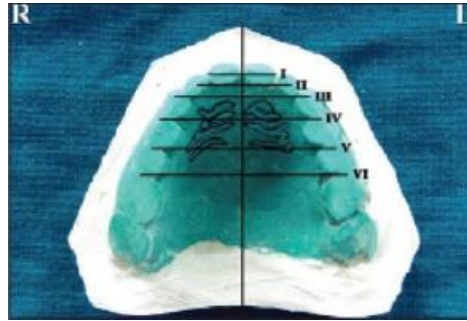
behind the incisive papillae. They are three to seven in number and the variability is the main feature of their uniqueness (Fig.10).



*Figure 10 Different palatal rugae patterns in two young patients.*

It's a well accepted fact that rugal pattern is as unique to a human as are his DNA or fingerprints and since palatal rugae formation during the 12-14<sup>th</sup> week of prenatal life pattern's structure remain unchanged throughout life not altered by diseases, traumas, heat and chemicals uptaken during life (food, nicotine, dugs, ethanol, etc.). Due to their stability palatal rugae is considered as a reliable landmark during orthodontic treatments, cleft palate surgeries, palatal prosthesis and medicolegal evaluations<sup>63</sup>. The palatal rugae position is designated as left/right to determine which

quadrant they belong. Rugoscopic area can be divided into quadrants, with the aim of obtaining the coordinates position of palatal rugae. For this, six horizontal lines divide the cast into 5 zones<sup>64</sup>.



*Figure 11 Palatal area divided in the six areas [Chowdhry A. A simple working type Integrated Rugoscopy Chart proposed for analysis and recording rugae pattern. Journal of Forensic Dental Sciences 2016; Vol.8(3):171-172].*

One of the most used classifications to perform a rugoscopic study is the one elaborated by Lysell and Thomas and Kotze<sup>65,66</sup>. Rugae length is the first level of information need to be assessed. They distinguished three categories:

- Primary rugae: 5 mm or more (5-10 mm)
- Secondary rugae: 3-5 mm
- Fragmentary rugae: 2-3 mm

Rugae measuring < 2 mm were not considered.

After length is determined usually the shape is assessed. Transversely, for each palatal rugae starting from the mid-palatine raphe, we can individuate the medial point, and arriving to the external palatal area adjacent teeth, we can individuate the lateral point. Ever transversely we can classify four major types of shapes: circular, curvy, straight, wavy (Fig.12). Adding other shapes we can classify ten major types<sup>67</sup>:

- Angle
- Anomaly
- Bifurcated
- Circle
- Curve
- Interrupted
- Line
- Point
- Sinuous
- Trifurcated



Figure 12 The four major palatal rugae's shape

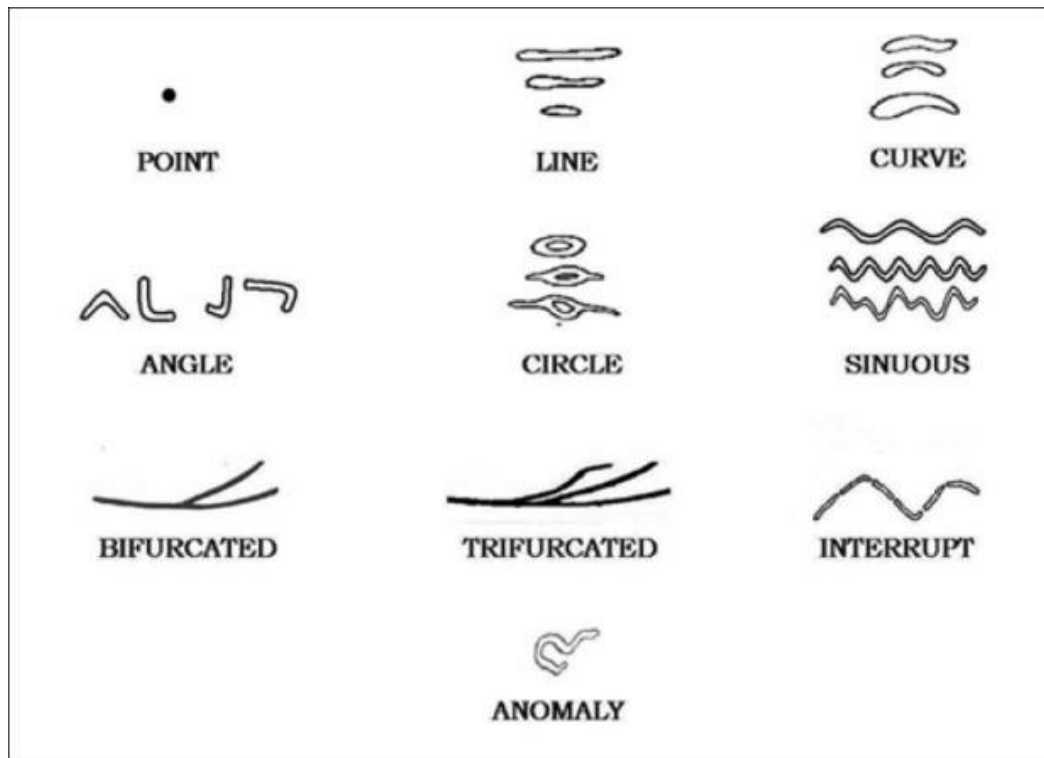


Figure 13 Different palatal rugae shapes [Indira AP, Manish Gupta M, David MP. Usefulness of palatal rugae patterns in establishing identity: Preliminary results from Bengaluru city, India. *Journal of Forensic Dental Science* 2012 Jan-Jun; 4(1): 2-5].

The palatal rugae direction is determined by measuring the angle formed by the line joining its origin and termination and the line perpendicular to the median raphe. Based on direction rugae can be classified in:

- Forward directed

- Backward directed
- Perpendicular

Another feature can be assessed in palatoscopy is the presence of unification, occurred when two rugae joined at their origin or termination.

Traditional and still valid palatal rugae analysis is made on maxillary dental plaster models using cheap tools: pencil, caliper (if possible a digital one), magnifying glass. The general method is strictly comparative. The use of direct inspection and comparison with photographs proved to be unsuccessful and this method was abandoned. In the more recent years the development of experimental softwares for photographic superimposition (i.e. RUGFP- Id, Palatal Rugae Comparison Software) introduced oral photographs again as alternative source to plaster models. Nowadays the stereoscopy and the stereophotogrammetry allows the 3D analysis and comparison of dental models.

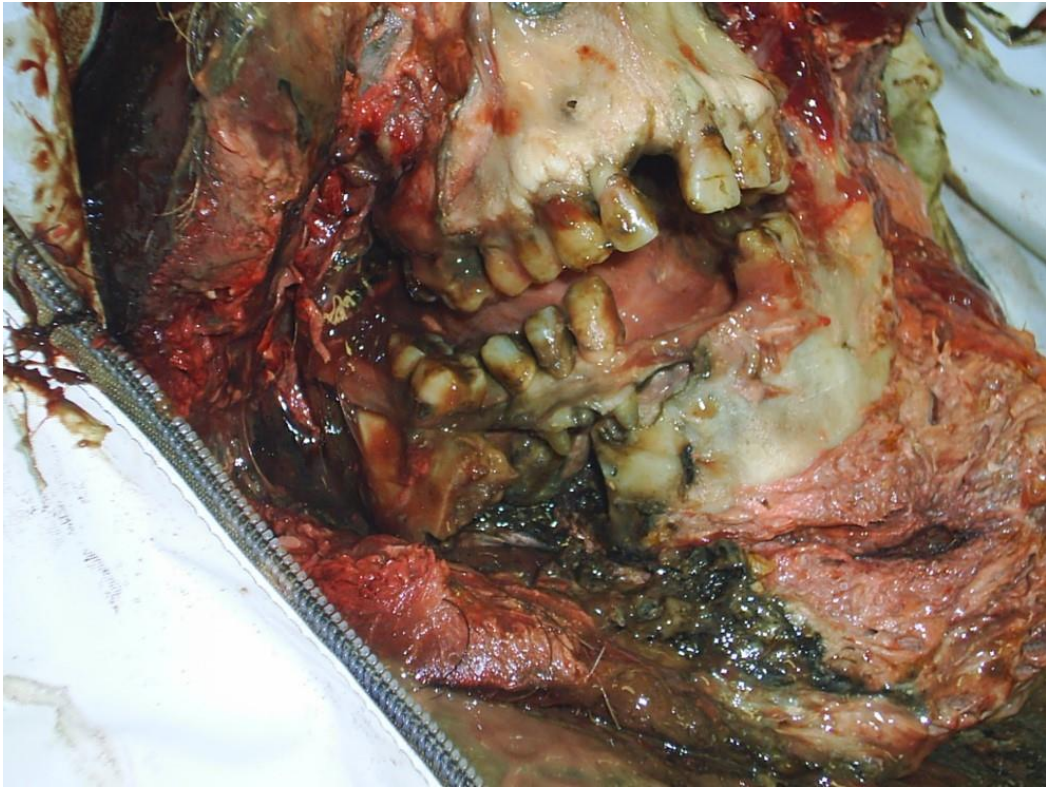
Palatal rugae patterns have been studied in many researches to evaluate if they are a reliable forensic marker for sex determination<sup>61,63</sup>,

epidemiological traits<sup>63, 65, 67</sup>, and their stability after orthodontic treatments<sup>68-70</sup>. The patients selected in these studies underwent different orthodontic therapies: extractive and not extractive<sup>71- 73</sup>, functional<sup>74</sup>, orthopaedic with palatal expanders<sup>75</sup>. The most of the rugoscopic studies found in literature have been performed on dental casts and living persons. Nowadays there's only one study in literature analyse palatal rugae stability in cadavers and burn victims using a visual inspection and photographs without a real personal identification purpose<sup>76</sup>.

## 2.8. Oral autopsy

Usually, the forensic dentist participates in personal identification processes helping in establishing the age, sex, and race of corpses or skeletal remains. The sources are teeth, bite marks, lip prints, palatal rugae. The forensic dentist can use radiological examinations and post-mortem dental records, all as already described in the preceding paragraphs. Oral autopsy may help in all those cases where dental evidence is almost mandatory and intra-oral examination cannot be accurate or possible at all due to a poor accessibility<sup>77</sup>. This problem is not rare during identification especially when the conservation of body is critical or when remains are uncompleted and the identification process risks to be retarded, in other situations the intra-oral examination is easier due to traumas and injuries affecting the face and oral region (Fig.14). Oral autopsy helps to register the teeth present in the oral cavity, the type of occlusion, and the presence of ante-mortem dental restorations. The age of the person influence oral autopsy operations: in adults often is necessary to operate with jaw removal and skin and muscle dissection, especially when rigor mortis

closes the access to a clear observation of the mouth; the muscular weakness in children makes this procedure less complicated.



*Figure 14 Example of severely altered face allows an intra-oral examination without the surgical procedure of oral autopsy.*

Teeth or their germs can be extracted and age estimated by light microscope studies or scanning electron microscope<sup>78, 79</sup>. In presence of deciduous teeth the age estimation is simpler. In cases of criminal abortions, mass disasters, abandons and miscarriages the oral autopsy of fetuses and infants is such important as more complicated than children



or adults<sup>80</sup>. The procedure of oral autopsy ever starts with frontal and lateral photographs of the face's corpse and then follow these steps<sup>81</sup>:

- an incision from the angle of the mouth to the tragus of the ear on either side (Fig.15);
- a folding of lip and cheek tissue (Fig.16);
- the sectioning of the muscles and the capsular ligament of the temporomandibular joint;
- the opening of the mouth by traction that allows visualization of the lower and upper dental arches (Fig.17);
- photographic records of the oral cavity;
- removal of prosthetic and orthodontic appliances if present;
- charting of the mouth in the postmortem dental record;
- description of the anomalies of shape, position, and size of the teeth;
- taking of adequate photographs to compare with ante mortem records;
- suturing (Fig.18).

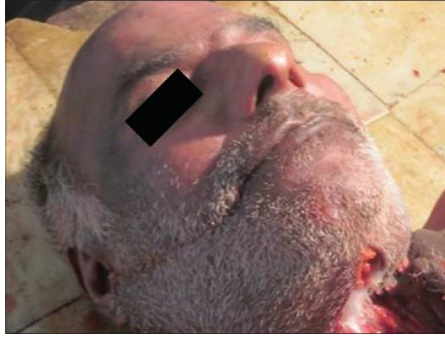

Figure 15 Incision for oral autopsy

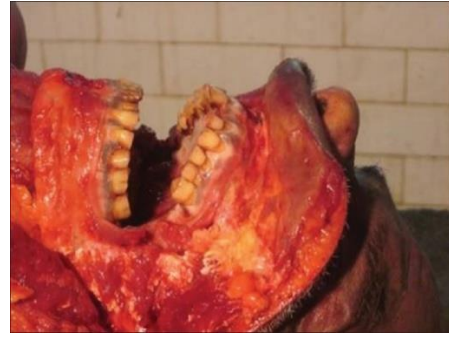

Figure 16 Accurate folding of soft tissues

(Charan Gowda BK, Mohan CV, Hemavathi. Oral autopsy: A simple, faster procedure for total visualization of oral cavity. J Forens Dent Sci 2016 May-Aug; 8(2): 103–107)

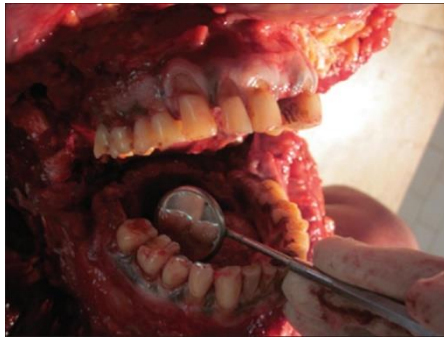

Figure 17 Suturing procedure

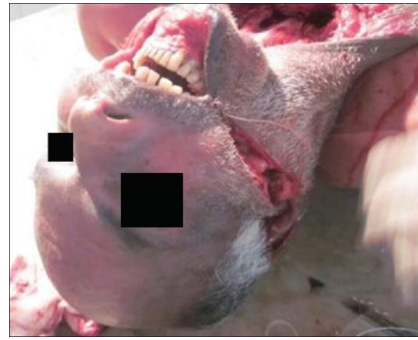
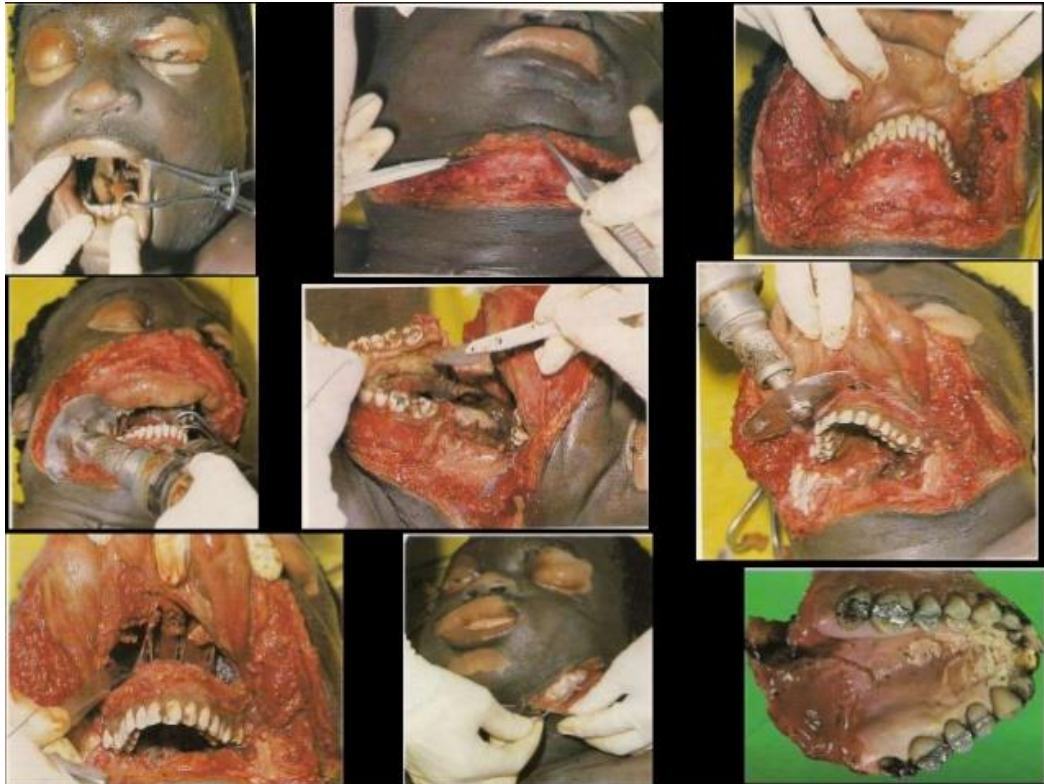
Figure 18 Intra-oral examination

(Charan Gowda BK, Mohan CV, Hemavathi. Oral autopsy: A simple, faster procedure for total visualization of oral cavity. J Forens Dent Sci 2016 May-Aug; 8(2): 103–107)

Some autopsy procedures deviate from this method described above all with regard to the surgical incision that can take place below the mandibular plane, keeping intact the appearance of the skin tissues and muscular planes.



*Figure 19 Alternative surgical incision for intra-oral examination*

Oral autopsy procedures regardless of the surgical method used to expose the oral cavity and make it explorable are always very invasive. Despite the accuracy of the operators, remains the problem of alteration of the body of the corpse, that despite the indisputable need to carry out this examination for identification purposes, where necessary, however, has important practical implications. It is a vilification of the corpse, both on the ethical level because the family of the deceased is put in front of a further pain that is added to that of the loss of the loved one.

### 3. Intraoral scanner technology

Conventional impression techniques, highly conditioned by volumetric changes in materials, have been overwhelmed by the three-dimensional geometry of dental tissues obtained from the intraoral scanners for dental use<sup>82, 83</sup>. Intra-oral scanners devices offer easier and faster dental treatment planning, rapid case acquisition, fast communication with laboratories, reduced material storage and a short intervention time<sup>84, 85</sup>. The intraoral scanner available nowadays is a medical device consisting of a portable camera (hardware), a computer and a software. The goal in taking digital impression is to accurately record the three-dimensional geometry of teeth and adjacent oral structures. The most popular digital format is the “.STL” or stereolithographic format. This format describes a succession of triangulated surfaces where each triangle is defined by three points and a surface (Fig.20). However, other file formats have been developed, in example the “.ply” or polygon file format able to record the color, transparency or structure of dental tissues. All cameras inside the scanners record individual or sequential images or capture videos after the

recognition of a “point of interest”<sup>86</sup>. The attribution of the three coordinates for each point of the triangle is so subdivided: x and y on the image, z on the basis of its distance from the camera.

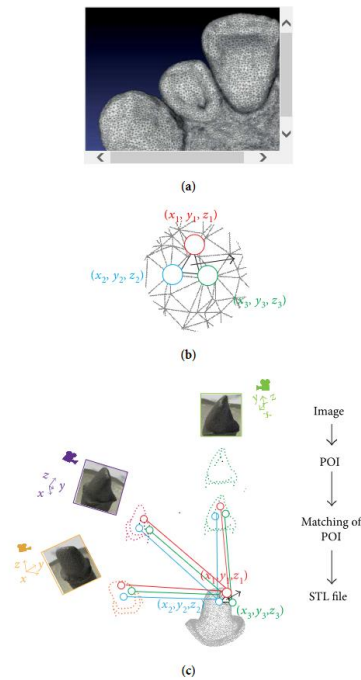


Figure 20 Process generating STL file (Raphaël R, Goujat A, Venet L, Viguie G, Viennot S, Robinson P, Farges JC, Fages M, Ducret M. *Intraoral Scanner Technologies: A Review to Make a Successful Impression. Journal of Healthcare Engineering* 2017; 1-9).

Dental enamel and many restored or natural dental surfaces may reflect the light altering the corresponding digital record during the scanning teeth due to overexposure. To avoid this phenomenon, clinicians may change the camera orientation and increase diffuse light. For other scanners, a 20 – 40  $\mu\text{m}$  powder coating is required during the digitalization

process, which reduces reflectivity (Fig.21). The quality and the quantity of the powder could reduce the accuracy of the 3D file, even if the software is able to take an average thickness in consideration<sup>87</sup>.

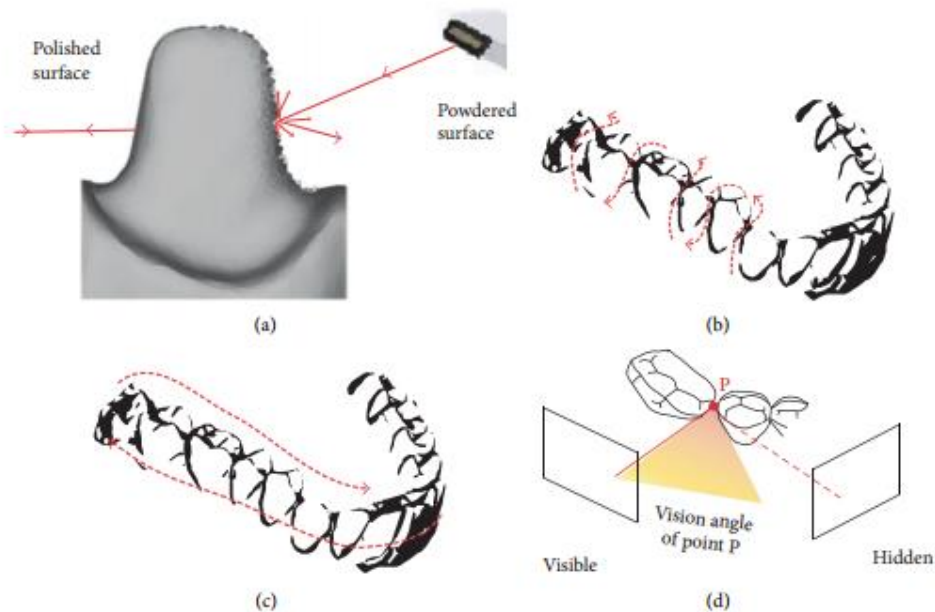


Figure 21 Scanning strategies and powdering effects (Raphaël R, Goujat A, Venet L, Viguie G, Viennot S, Robinson P, Farges JC, Fages M, Ducret M. Intraoral Scanner Technologies: A Review to Make a Successful Impression. Journal of Healthcare Engineering 2017; 1-9).

However, the powder could cause discomfort to patient during scanning even if used on a limited area as for prosthetic reasons. The use of powders could increase the patient's discomfort for full mouth digital impressions, especially because it is not easy to keep the powder coating on all the dental surfaces for the entire duration of the scan<sup>88</sup> and when it is time to

remove it the procedure can not be easy and comfortable, this is one of the reasons the pulverizations could be repeated during the same scanning session<sup>89</sup>. A scanning strategy should be followed, for example, by simplifying the order of precedence scanning to "simple zones" such as the occlusal faces of the posterior teeth, so that the software has sufficient information even when the detection is lost. Manufacturers are currently developing different strategies and algorithms in software to recover the scan when monitoring is lost, thanks to the geometric recognition of the saved object, this tool is called "auto-locate function". For this reason, when the operator needs to review a significant area it must retrieve enough information from the camera to the software. The presence of high curvatures or of "hidden faces" reduce the number of point of interest and complicate the rendering completion process for the software<sup>90</sup>.

During intraoral scanning the patient's sudden movements can generate errors and peripheral soft tissues such as the tongue or jaws can be included in the scan<sup>91</sup>. In the same way, the presence of blood, saliva, or gingival fluid may falsify the scanned image<sup>92</sup> (Fig.). The latest generations

of intraoral scanners provide color and texture data that increase the perception of clinical situations and dental volume.



*Figure 22 Complex points and critical surfaces during intraoral scanning effects (Raphaël R, Goujat A, Venet L, Viguie G, Viennot S, Robinson P, Farges JC, Fages M, Ducret M. Intraoral Scanner Technologies: A Review to Make a Successful Impression. Journal of Healthcare Engineering 2017; 1-9).*

The complete rendering of the file consulted in the graphical user interface corresponds to the reality in a rate depends on the accuracy of the scans and the scanner itself.

The reliability of intraoral scanner is described by three parameters: accuracy, trueness and precision<sup>93</sup>. The recorded data are authentic and precise, the more there is correspondence between the arithmetic mean of



the large number of results and the true reference value. The exact and precise variability conditions reported for intraoral scanner depend on various factors such as the operator, the equipment used and its calibration or susceptibility, the time elapsed between measurements and the environment (temperature, humidity, etc.) of investigation. The methods for calculating the accuracy and trueness of the data from intraoral scanner are always limited, due to the quality of the references used and the measuring technique used, but the average error for the discrepancy between the real dimension and the digital one has been calculated in many studies and the eventual presence of digital distortions too. These considerations result especially thanks to the comparison between digital scans of real dental arches and of their plaster models. The inaccuracies may have a physical-chemical nature<sup>95</sup>. Intra-oral scanners are very useful clinical devices allow to obtain digital models comparable in accuracy and trueness to the models (digital or plaster) obtained by traditional impressions.

#### 4. Objectives

The aim of this research is to show the usefulness of intraoral scanner technology and reliability of the digital scans and their successful superimposability with 2D radiographs for forensic purposes in personal identification on living and corpses.

## 5. Materials and Methods

For this study on living and corpses, the recruitment of the sample on living subjects was started in January 2016 and the observations were performed until July 2018. 50 patients under orthodontic treatment and 50 patients under periodontal control have been selected respectively in the Orthodontic and Periodontology Units of the Policlinico Umberto I of Rome at Sapienza University and in a private dental office in Rome. From January 2016 to February 2017 were also observed 23 corpses present in the morgue at the Institute of Forensic Medicine of the Sapienza University of Rome. The written consent was obtained for all patients and Ethical Committee Approval has been requested and obtained.

The orthodontic patients (called A group) had the following features:

- aged between 10-54 years;
- 25 females and 25 males;
- late mixed and permanent dentition;

- selected for fixed-multi brackets therapies, functional therapies, orthopaedic therapies, therapies with clear aligners;
- extractive and surgical-orthodontic cases have been excluded.

They had the following documents:

- orthopantomographs (those taken before to start the therapy and if available those repeated when necessary for orthodontic reasons);
- plaster and digital dental models obtained by intra-oral scanner (Carestream 3500®) taken before to start the therapy and repeated at the end of the treatment of at the end of the first year of therapy;
- intra-oral and extra-oral photos.

The 50 patients under periodontal control (called B group) had the following features:

- aged between 35-67 years;
- 25 females and 25 males;
- permanent dentition;

- partially edentulous or prosthetically rehabilitated patients have been included;
- patients surgically treated or planned to be treated in one year have been excluded.

They had the following documents:

- orthopantomographs and full mouth periapical films (taken before to start the professional oral hygiene therapy);
- plaster and digital dental models obtained by intra-oral scanner (Carestream 3500®) taken before to start the professional oral hygiene therapy and repeated after one year;
- periodontal chart properly updated;
- intra-oral and extra-oral photos.

The cadavers (called C group) available in the morgue had the following features:

- aged between 45-69 years old;
- 12 females and 11 males;

- permanent dentition, full arches, partial or totally edentulous arches; fixed/removable prosthetics;
- different causes of death;
- no jaws fractures.

They had the following documents:

- orthopantomographs and/or full mouth periapical films (taken when the subjects were still alive and released by relatives/dentists)
- plaster and digital dental models obtained by intra-oral scanner (Carestream 3500®) taken at the moment the corpses arrived at the morgue and when possible repeated after one week.

A characteristic common to all the subjects, living and corpses, is the belonging to the Caucasian race, except one subject belonging to the African race in the C group.

### The Intraoral Scanner Carestream 3500®

The intraoral Scanner Carestream 3500® used for this research is a dedicated portable laptop device (Fig.23). The Intraoral scanner used is of the stitching-type category: it reprocesses the 3D image from a series of photographic shots generated by a single green-light pulse. There is no need to use powders. For each scan shot the device takes about 250 photos at the same time. It provides a high level of accuracy (30 µm) and resolution (1024x768 pixels for still images and 640x480 pixels for videos). During the scanning, that take 30-40 minutes for full arches mode, the instrument is positioned in the oral cavity with the tip facing the surface of the dental elements. The correct capture of each individual image must be slow. A “beep” is emitted every time the photograph is performed without any inappropriate movement of the operator or micro-movements by the patient. Just for the type of scanner to which it belongs, it needs to be moved a few mm to ensure continuity in the re-elaboration of the

images. Every single scan of a specific tooth surface must be carried out maintaining an overlap of information of about 30% with the previous image otherwise it is not acquired and also in detail on the laptop appears a Scan that "does not proceed". The tip, oriented on the occlusal, vestibular and lingual or palatal surfaces of the dental elements, must maintain continuity to allow a complete and precise pixel mapping.

The scanner communicates with the laptop in real time. On the video screen a live preview is displayed. Automatically scanned images generate the 3D model display, it can be saved or the procedure can be improved adding further scans for incomplete or unclear areas. The incorrect recording of elements such as the tongue or the mucosa can be corrected before the result is finalised manually, or automatically.





Figure 23 Technical specifications of Intraoral Scanner Carestream 3500®.

The Carestream 3500® Intraoral scanner is equipped with two tips (Fig.24), equal in shape, but of different sizes. The larger one completes digitization with a smaller number of total scans, its field of view is 16x12 mm. The smaller one achieves better the posterior sectors, especially the upper ones, where it can be difficult to position the device with the opening of the mouth but will need a greater number of scans, indeed its field of view is 12x9 mm. The number of scans required to make the digital impression of a single arch is on average 150-160, the scan of the complete upper jaw of

the vault requires obviously a greater number of scans than the lower arch.

Once the file (usually .stl) has been created, it is possible to see the true colour or plaster style arches and their reciprocal relationship by occlusion on the CS Viewer Software (Fig.25).



Figure 24 Tips of the Carestream 3500® intraoral scanner.

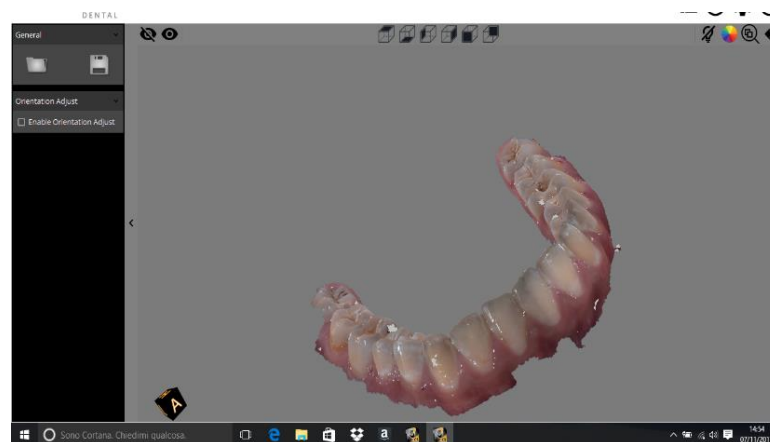


Figure 25 Screenshot of a lower arch digital model obtained with the Carestream 3500® intraoral scanner.

### Description of the experimental protocol

For all the three groups the intra-oral scans on living and corpses have been taken by the same operator (A.P.). All the general data (names encoded through initials, age, gender) of the subjects sampled have been collected in digital sheets (Microsoft Office Excel, 2016®).

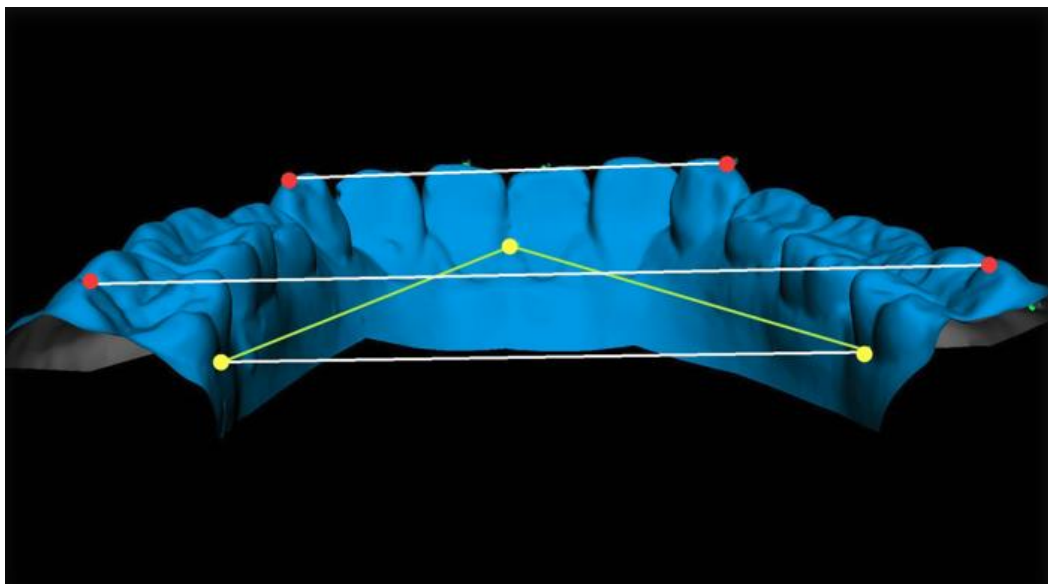
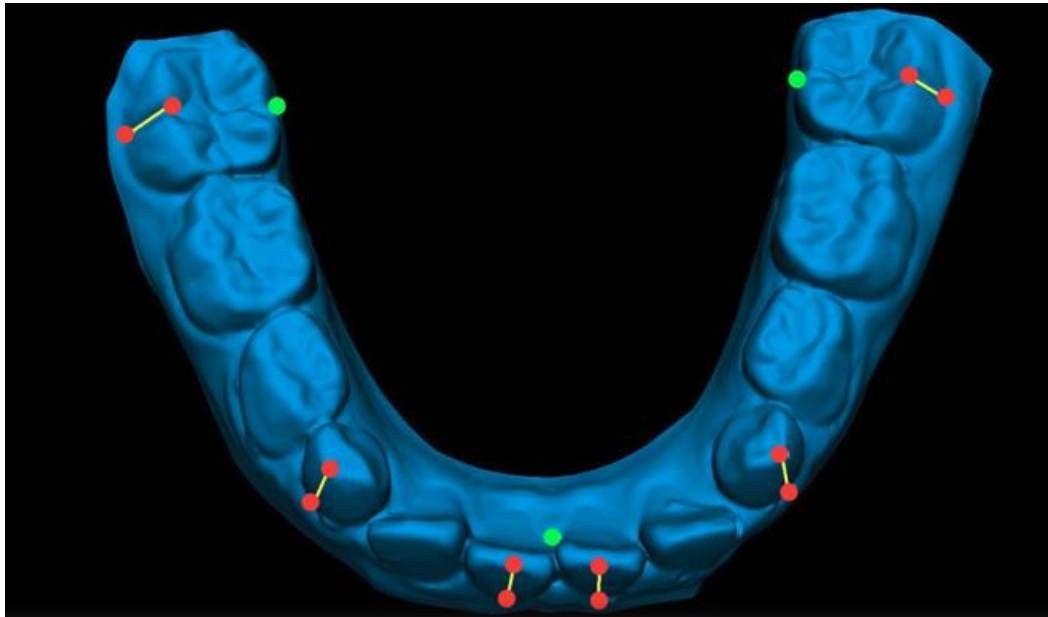
In the A group, subjects have been further classified for type of dentition (at the first and last intra-oral scan) and type of therapy (functional and orthopaedic specifying the appliance; fixed multi-brackets specifying the systematic; with clear aligners). In the B group, subjects have been further classified for type of prosthetic/conservative rehabilitations. In the C group, corpses have been further classified for type of prosthetic/conservative rehabilitations; cause of death if known. For all the groups the sampled population had a radiographic documentation on CD-ROM, if the CD-ROM was not available, in presence of a traditional radiograph it has been scanned with HP Officejet J4580 All-in-One and converted in digital image as .jpeg file.

After the acquisition of all the scans the digital archive obtained has been used to start the digital measurements on a dedicated software called MeshLab® (version 1.3.3). To calibrate the digital dimensions with the in vivo dimensions, and to have the certainty there is a proper correspondence of both of them with each other, before to start the use of intra-oral scanner, a digital caliper (Borletti CDJB20, accuracy 0.03 mm) has been used (Fig.26). The inter-molar and inter-canine distance of every arch, the mesial-distal diameter of canines and the vertical height of first molars (from the median sulcus to the gingival contour) and of canines have been recorded.

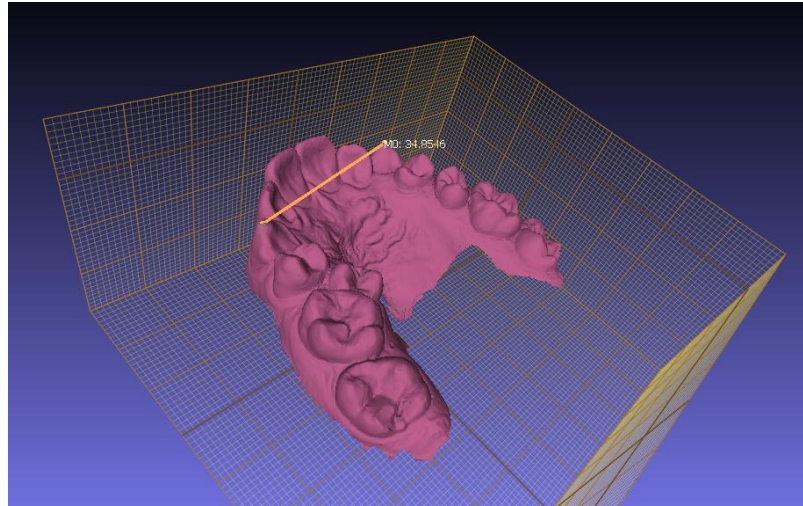


*Figure 26 Digital Caliper used in the in vivo measurements for the comparisons with the digital measurements.*

On the MeshLab Software the same measurements have been taken and recorded on a dedicated digital sheet for a direct comparison between the in vivo and digital values (Fig.27,28).



*Figure 27 Digital reference points for calibration with in vivo measurements.*



*Figure 28 Digital inter-canine measurement based on reference points.*

The part of the study dedicated to the digital superimpositions has been conducted by two independent operators: a dentist specialized in orthodontics (A.P.) and a doctor specializing in forensic science (V.B.).

Three comparative methods have been followed:

1. The superimposition of initial and late digital models, to verify the stability of some structures as palatal rugae after a period of observation. This application on A and B groups wants to evaluate palatal rugae's changes or stability under orthodontic forces or less (Fig.29). The same analysis on cadavers wants to evaluate the stability of palatal rugae after death. For each individual in the three study group two digital scans have been obtained, initial (t0) and

after 1 year (t1) in A group; initial (t0) and after 1 year (t1) in B group; initial (t0) and when the corpse still available in the morgue, after 1 week (t1), in the C group.

To compare the rugae length the Lysell and Thomas and Kotze classification was followed (primary, secondary, fragmentary) for the first, second and third rugae. The rugae shapes have been compared too following the four major types (straight, curvy, circular and wavy). In the superimposition procedure the initial and last digital scan have been differentiated attributing two different colours (i.e. light grey and red; fuchsia and red; fuchsia and blue, etc.). Length and shape data have been recorded on both right and left sides of initial and final digital scan. Obtained results were subjected to statistical analysis.

2. The superimposition of digital models obtained by intraoral scanning and ortopantomographs as possible comparative method between ante-mortem and post-mortem records by the randomly

distribution among the two observers for matching between initial or final random scan and radiograph.

3. The superimposition of digital models obtained by intraoral scanning and full mouth periapical films as possible comparative method between ante-mortem and post-mortem records ever by the randomly distribution among the two observers for matching matching between initial or final random scan and radiograph.

The last two superimpositions have been possible slicing digital models with a software called Slicer 3D® (Version 4.8) and the digital-radiographic superimposition has been obtained with the Geomagic® Control X Software (Version 2017.0.2).

The data obtained will be analysed statistically using the R Software (Version 3.5.1) and Excel Software (Microsoft Office 2016).

The palatal rugae stability has been assessed by mean and deviation standard comparison in all the three groups and subcategories with the t-Student test. The correctness of the match for each examiner was



calculated as percentage, the X-Square Test and the X-Square Test with Yates correction have been furtherly used to assess if the differences in the matching results was statistically significative or less. Both statistical methods have been chosen on the basis of previous researches in literature<sup>96,97</sup>. To evaluate the accuracy of all the examiners' observations, Kappa test was performed and the score was ever 100, which indicates an agreement between observers. It has been considered a measurement error around 0.35-0.41 mm in the digital-radiographic comparison.

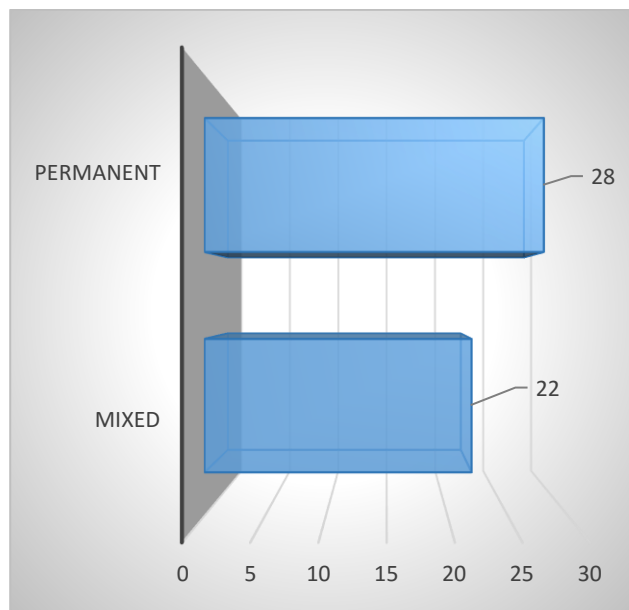
## 6. Results

During the phase of selection of subjects their data have been collected and organized to follow the amount of informations required for proper further analysis. The distribution of the characteristics evaluated is presented in tables and graphics.

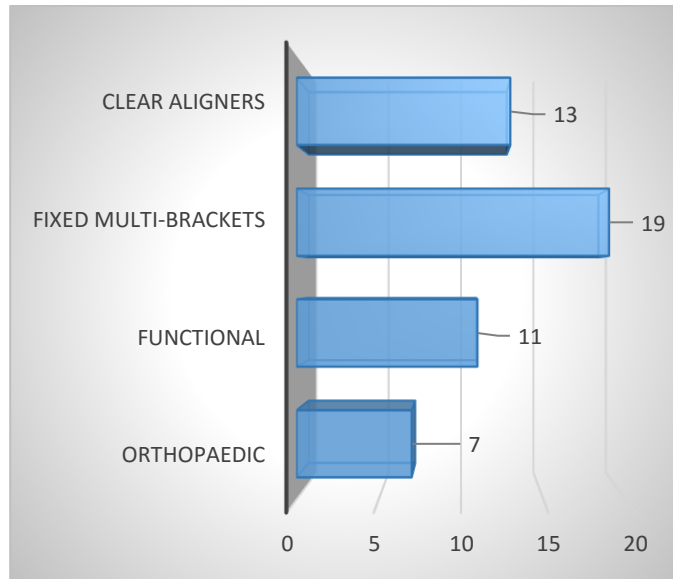
The distribution for gender in the A group is homogenous and the mean age too is enough similar (Tab.2). More than the 50% of them is in permanent dentition, the others are in mixed dentition (Graph.1). The type of therapies are strictly influenced by the age and type of dentition. A wide number of orthodontic patients underwent to a fixed multi-brackets treatment, followed for their amount by patients treated with clear aligners, with functional (Twin Block, Fraenkel type II and III, Bionator II) and with orthopaedic appliances (Rapid Palatal Expander) (Graph.2).

Table 2 Age and Gender distribution in A group (orthodontic patients)

Number	Gender	Mean Age
25	Female	18,88
25	Male	19,28



Graphic 1 Type of Dentition in A group (Orthodontic Patients)



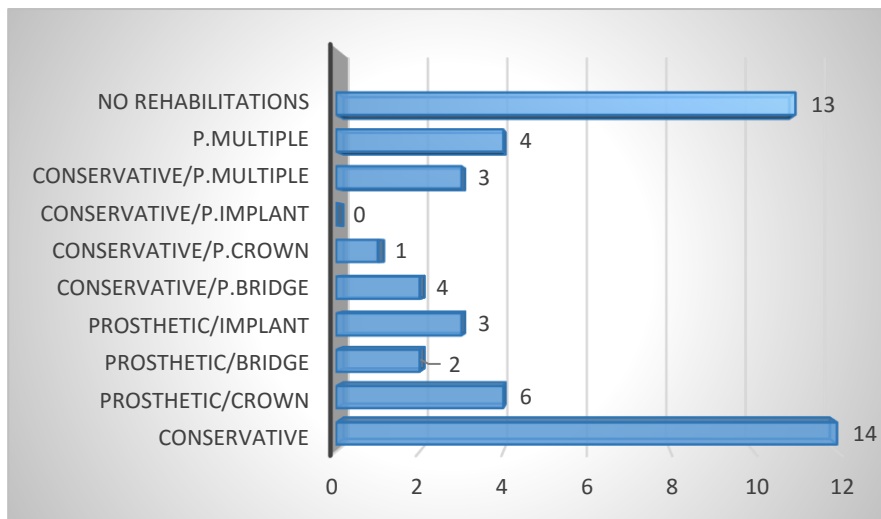
*Graphic 2 Type of treatment distribution in A group (orthodontic patients)*

The B group collects together the patients under periodontal health control with periodic checks and professional plaque and tartar removal. The patients selected have not been programmed for periodontal surgical or regenerative treatments during the time of observation. They had a homogenous age (Tab. 3) and few of them had a natural dentition, more of them at the time of observation had already lost one or more teeth, and a big number of them had at least one conservative or prosthetic rehabilitation (Graph.3). The conservative and prosthetic rehabilitations of interest for this study, for both the B and C groups, in the upper arch are those in anterior, lateral and posterior teeth from second premolar to

second premolar. This is due to the possible correlation with the presence of restorations and stability of palatal rugae analysed.

Number	Gender	Mean Age
25	Female	47
25	Male	47,44

*Table 3 Age and gender distribution in B group (periodontal patients)*



*Graphic 3 Type of Rehabilitations in B group (periodontal patients)*

A part of them had at least one or more conservative restorations and one or more prosthetic rehabilitations at the same time. The presence of multiple prosthetic rehabilitations or the contemporary presence of prosthetic rehabilitations and conservative restorations is more large in the

subjects over 45 years, the conservative rehabilitations and the mouths without restorations are larger in adults under 45 years old.

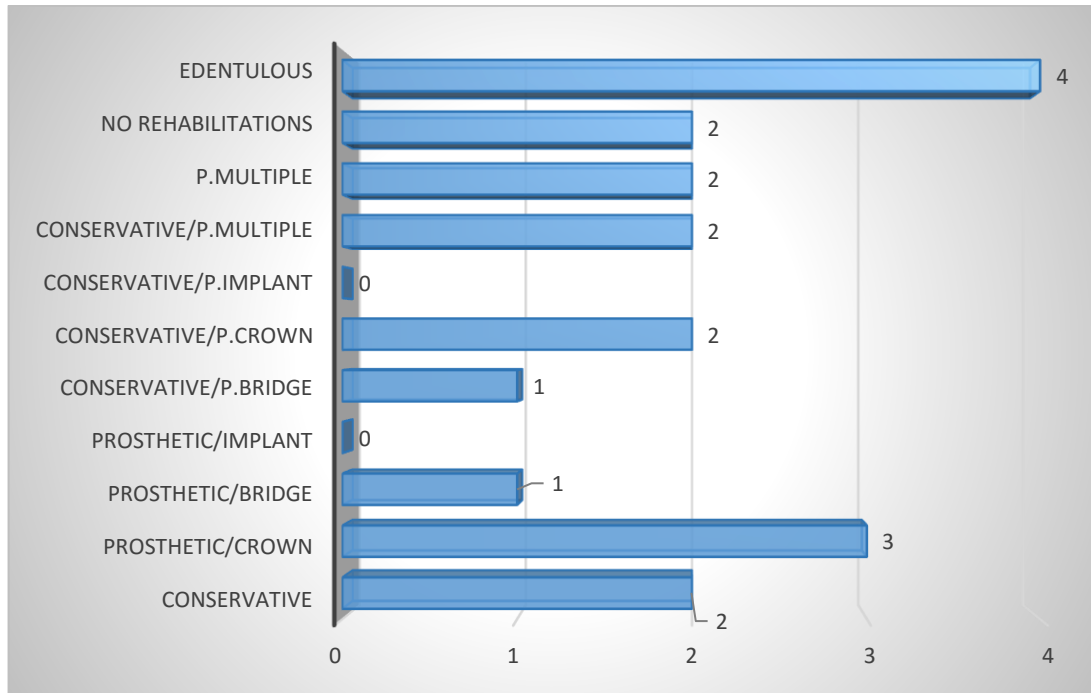
The C group is the one for cadavers. The bodies delivered to the morgue had to carry out the necroscopic investigation. They were mostly elderly people found dead in their homes or homeless. In some cases the bodies had to undergo an autopsy for judicial reasons. In this study no traditional impression materials have been used, since the taking of impression was digital with the intraoral scanner and, at the morgue temperature of 16-18°C, intraoral scanner working is not influenced by that temperature. The manipulation and management of the access to the mouth of each cadaver had the support of the doctors specializing in forensic science present during the procedures (V.B., S.N.). The mean age in this group is enough homogenous in both the genders (Tab.4).

Number	Gender	Mean Age
11	Male	57,09
12	Female	58,46

*Table 4 Age and gender distribution in C group (cadavers).*

It should be indicated for clarification that all the corpses observed did not need to be identified and their age was therefore known.

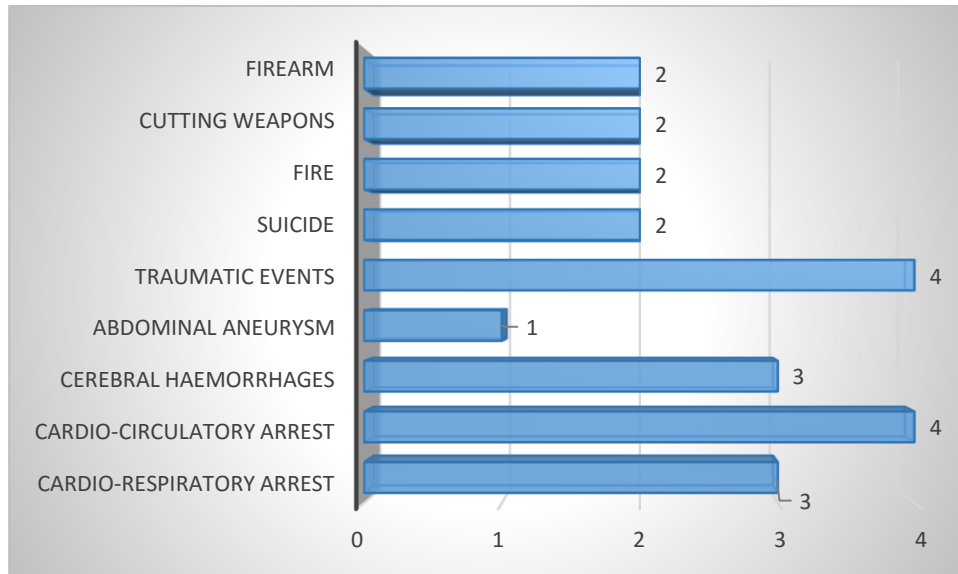
A large number of corpses had one or more prosthetic or conservative rehabilitations in the anterior, lateral and posterior (until second premolars) areas. Just three of them, two females and one male, had no rehabilitations. Four of them were edentulous and the presence of any removable total dentures was established before including the subjects in the study (Graph.4).



*Graphic 4 Type of Rehabilitations in C group (cadavers)*

The causes of death of the subjects were a relevant matter. Most of the subjects died from cardio-circulatory and cardio-respiratory arrest, because of traumatic events (car accidents), cerebral haemorrhages, abdominal aneurysm, suicide, fire, cutting weapons, firearms (Graph.5).





*Graphic 5 Cause of death in the C group*

At the beginning of this study, others corpses were selected and got the first intraoral scan (Fig.29, 30), but the absence of radiographic documentation and in some cases the unavailability of the corpse for the second intraoral scan reduced the amount of cadavers considered from 35 to 23.

The palatal rugae analysis performed by superimposition of digital scans (Fig.31) led to the following results. Starting to analyse the data of the A group the mean values for rugae length of both sides have been calculated as shown below (Tab.5)

Table 5 Mean and SD length in the A group on both sides.

A group	N	Initial Means	Initial SD	Final Mean	Final SD
Clear Aligner	13	8,7467	0,0850	8,7780	0,1413
Orthopaedic	7	8,6375	0,2291	9,0064	0,2735
Functional	11	8,5800	0,2493	8,8238	0,1576
Fixed multi-brackets	19	8,5875	0,1732	8,6873	0,1910
	50				

For clear aligners patients the differences in rugae length in both sides have been calculated and the T-student test resulted not significant ( $P < 0,05$ ).

Table 6 Comparison of initial (1) and last (2) rugae length in patients with clear aligners (T- student test).

Group A CLEAR ALIGNER	1	2
N	13	13
Mean	8,7467	8,7780
SD	0,0850	0,1413
<b>t</b>	<b>0,6849</b>	
<b>df</b>	<b>24</b>	
<b>P (significativity level)</b>	<b>0,5000</b>	

For functional appliances the differences in rugae length in both sides have been calculated and the T-student test resulted significative (P<0,05) (Tab.7).

*Table 7 Comparison of initial (1) and last (2) rugae length in patients with functional appliances (T-student test).*

Group A FUNCTIONAL	1	2
N	11	11
Mean	8,5800	8,8238
SD	0,2493	0,1576
<b>t</b>	<b>2,7413</b>	
<b>df</b>	<b>20</b>	
<b>P (significativity level)</b>	<b>0,0126</b>	

For orthopaedic appliances the differences in rugae length in both sides have been calculated and the T-student test resulted significative (P<0,05) (Tab.8).

*Table 8 Comparison of initial (1) and last (2) rugae length in patients with Orthopaedic Appliances (T-student test).*

Group A Orthopaedic	1	2
N	7	7
Mean	8,6375	9,0064
SD	0,2291	0,2735
<b>t</b>	<b>2,7357</b>	
<b>df</b>	<b>12</b>	
<b>P (significativity level)</b>	<b>0,0181</b>	

For patients underwent to fixed multi-brackets therapy the differences in rugae length in both sides have been calculated and the T-student test resulted not significative ( $P < 0,05$ ).

*Table 9 Comparison of initial (1) and last (2) rugae length in patients with Fixed multi-brackets Appliances (t- Student test).*

Group A fixed multi-brackets	1	2
N	19	19
Mean	8,5875	8,6873
SD	0,1732	0,1910
<b>t</b>	<b>1,6877</b>	
<b>df</b>	<b>36</b>	
<b>P (significativity level)</b>	<b>0,1001</b>	

The comparative statistical analysis of rugae length for B group have been performed ever using the t-Student test. The patients have been classified in four main types: with no rehabilitations, with conservative rehabilitations, with prosthetic rehabilitations and with mixed prosthetic and conservative rehabilitations. Mean and SD for initial and last record in intraoral scans have been calculated for all the four subcategories.

Table 10 Mean and SD length in the B group on both sides.

B group	N	Initial Means	Initial SD	Final Mean	Final SD
No rehabilitations	13	8,5975	0,2284	8,6722	0,1936
Prosthetic R.	17	8,4214	0,2644	8,5318	0,2856
Conserv./Prosth. R.	6	8,4375	0,2136	8,5275	0,2138
Conservative R.	14	8,5875	0,2281	8,6300	0,1734
	50				

The patients with no rehabilitations didn't show any significant change in rugae length after 1 year ( $p < 0,05$ ) (Tab.11).

Table 11 Comparison between initial (1) and last (2) rugae length values in B group patients with no rehabilitations (t-Student test)

Group B No rehabilitations	1	2
N	13	13
Mean	8,5975	8,6722
SD	0,2284	0,1936
<b>t</b>	<b>0,8278</b>	
<b>df</b>	<b>24</b>	
<b>P (significativity level)</b>	<b>0,4176</b>	

Patients with prosthetic rehabilitations singular or multiple, after one year, at the second intraoral scan to obtain a digital model of the upper arch including the palatal rugae had no significant changes too for  $P < 0,05$  (Tab.12).

Table 12 Comparison between initial (1) and last (2) rugae length values in B group patients with prosthetic rehabilitations (t-Student test).

Group B Prosthetic	1	2
N	17	17
Mean	8,4214	8,5318
SD	0,2644	0,2856
<b>t</b>	<b>1,0228</b>	
<b>df</b>	<b>32</b>	
<b>P (significativity level)</b>	<b>0,3166</b>	

The combined presence of more or less extensive conservative and prosthetic restorations did not affect the stability of palatal rugae after one year under periodontal health control ( $p < 0,05$ ) (Tab.13)

Table 13 Comparison between initial (1) and last (2) rugae length values in B group patients with Conservative/prosthetic rehabilitations (t-Student test).

Group B Conservative/Prosthetic	1	2
N	6	6
Mean	8,4375	8,5275
SD	0,2136	0,2138
<b>t</b>	<b>0,7295</b>	
<b>df</b>	<b>10</b>	
<b>P (significativity level)</b>	<b>0,4824</b>	

The last comparison in B group for patients had conservative restorations only confirm the same trend for all the group, there is no significant change after one year ( $p < 0,05$ ) (Tab.14).

Table 14 Comparison between initial (1) and last (2) rugae length values in B group patients with conservative restorations (t-Student test).

Group B Conservative Restorations	1	2
N	14	14
Mean	8,5875	8,6300
SD	0,2284	0,1734
<b>t</b>	<b>0,3926</b>	
<b>df</b>	<b>26</b>	
<b>P (significativity level)</b>	<b>0,6984</b>	

In the C group, from the first intraoral scanner record on the first day of stay in the morgue until its last (for all the corpses, between the seventh and the eighth day) and the last digital scan, the stability of palatal rugae length have been evaluated with the t-Student test (Tab.15).

Table 15 Comparison between initial (1) and last (2) rugae length values in C group patients (t-Student test).

Group C	1	2
N	23	23
Mean	8,4733	8,2557
SD	0,1614	0,2768
<b>t</b>	<b>3,2580</b>	
<b>df</b>	<b>44</b>	
<b>P (significativity level)</b>	<b>0,0022</b>	

Since for  $P < 0,05$  a significative difference resulted between the initial length of palatal rugae and its last record, the same t-Student test has been

used on the different gender and on the different subcategories of dental situation/rehabilitations to see if these two elements affected the stability.

Table 16 Comparison of initial (1) and last (2) rugae length values of both sexes in C group (t-Student test)

Group C females	1	2
N	12	12
Mean	8,4645	8,1975
SD	0,1263	0,2591
<b>t</b>	<b>3,2091</b>	
<b>df</b>	<b>22</b>	
<b>P (significativity level)</b>	<b>0,0040</b>	
Group C males	1	2
N	11	11
Mean	8,4871	8,2427
SD	0,1988	0,2507
<b>t</b>	<b>2,5334</b>	
<b>df</b>	<b>20</b>	
<b>P (significativity level)</b>	<b>0,0198</b>	

The gender doesn't affect the stability of palatal rugae after one week of death, they significantly change (reduction of length) in both sexes (Tab.16).

A further analysis for comparison with t-Student test assessed the stability of palatal rugae after death based on the different dental situations. The absence of teeth influence the stability, such as the presence of prosthetic



rehabilitations and combined conservative and prosthetic rehabilitations.

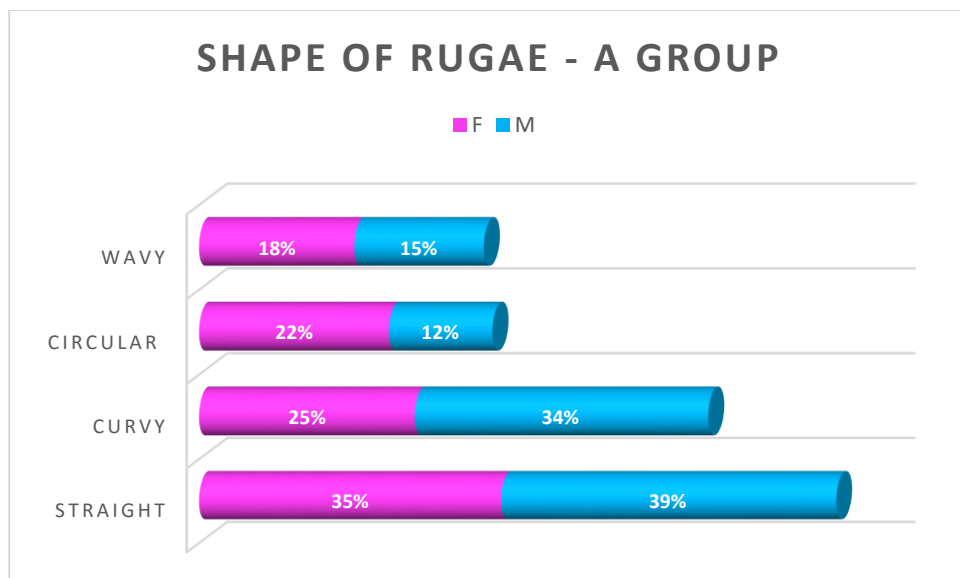
The total absence of any kind of restorations and the presence of conservative restorations help to keep unaltered the palatal rugae after death (Tab.17).

A last confrontation could have been based on the causes of death, but the numerosity of the many sub-categories is not homogeneous and would not allow a statistically representative assessment of the relationship with the stability of the palatal rugae as it was possible for the comparison according to the belonging gender and the type of dentition (natural, absent, re-enabled prothetically or with conservative restorations).

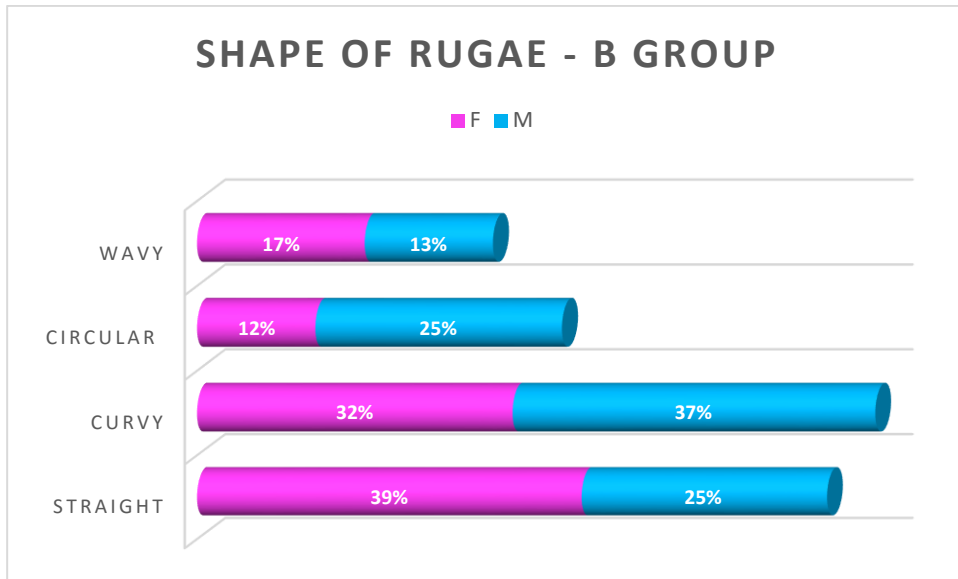
Table 17 Comparison between initial and last length of palatal rugae based on dental situations in C group.

Group C conservative	1	2
N	2	2
Mean	8,4050	8,0950
SD	0,0071	0,4172
<b>t</b>	<b>1,0507</b>	
<b>df</b>	<b>2</b>	
<b>P (significativity level)</b>	<b>0,4036</b>	
Group C Conserastive/Prosthetic	1	2
N	5	5
Mean	8,5000	8,1340
SD	0,1356	0,2867
<b>t</b>	<b>2,5805</b>	
<b>df</b>	<b>8</b>	
<b>P (significativity level)</b>	<b>0,0326</b>	
Group C prosthetic	1	2
N	6	6
Mean	8,4600	8,1683
SD	0,1517	0,2743
<b>t</b>	<b>2,2797</b>	
<b>df</b>	<b>10</b>	
<b>P (significativity level)</b>	<b>0,0458</b>	
Group C no rehabilitations	1	2
N	2	2
Mean	8,3800	8,1550
SD	0,1131	0,2192
<b>t</b>	<b>1,2899</b>	
<b>df</b>	<b>2</b>	
<b>P (significativity level)</b>	<b>0,3261</b>	
Group C edentolous	1	2
N	12	12
Mean	8,4675	8,2825
SD	0,1688	0,1948
<b>t</b>	<b>2,4861</b>	
<b>df</b>	<b>22</b>	
<b>P (significativity level)</b>	<b>0,0210</b>	

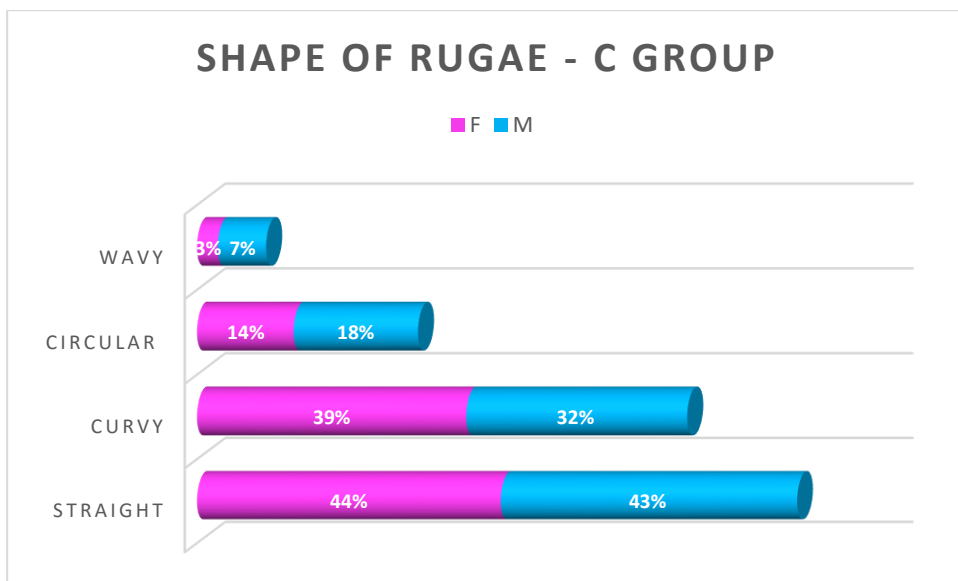
The two observers (A.P. and V.B.) determined the stability of palatal rugae shape in the three groups by the matching of the first scan with the second (Fig.32). The selection of scan was on a random basis, the observers were not informed whether the scan belong to the same individual, so each initial scan of every group were matched with multiple second scans. Correctness of the match for each examiner was calculated as percentage.



Graphic 6 Shape of Rugae in A group



*Graphic 7 Shape of Rugae in B group*



*Graphic 8 Shape of Rugae in C group*

The results of this comparative part of the study on the stability of rugal shapes showed that the straight and curvy shapes are more stable than the circular and wavy type. This is particularly true in the C group where there is a progressive simplification of wavy and circular rugae after one

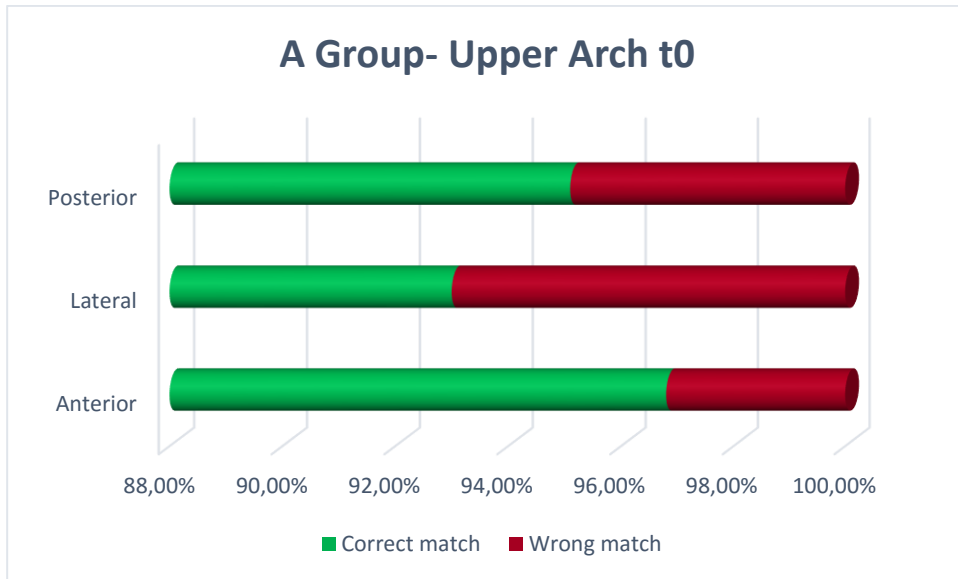
week, while in the other two groups also these shapes remain enough stable after one year. There is no a predominant gender for this trend of change.

The possibility of overlapping in a useful way the scans with the radiographs available of the subject (living or corpse) to contribute to the personal identification was carried out by matching the intra-oral scans cut with the Slicer 3D Software in three or multiple main sections corresponding to the anterior (incisors), lateral (canine and first premolar) and posterior (second premolar and teeth until the second or third molar, if present in the arch) areas of the arch and then overlapped to the radiographs with the automatic calibration tool selected by Geomagic® X control software. For group A, the overlapping of the two scans, initial and final, at time t0 and T1, with the initial orthopantomograph of the subject was made for each subject (Graph.9-12) (Fig.33). For group B, the overlapping of the two scans, initial and final, at time t0 and T1, with the initial periapical full mouth films of the subject was made for each subject (Graph.13-16) (Fig.34).

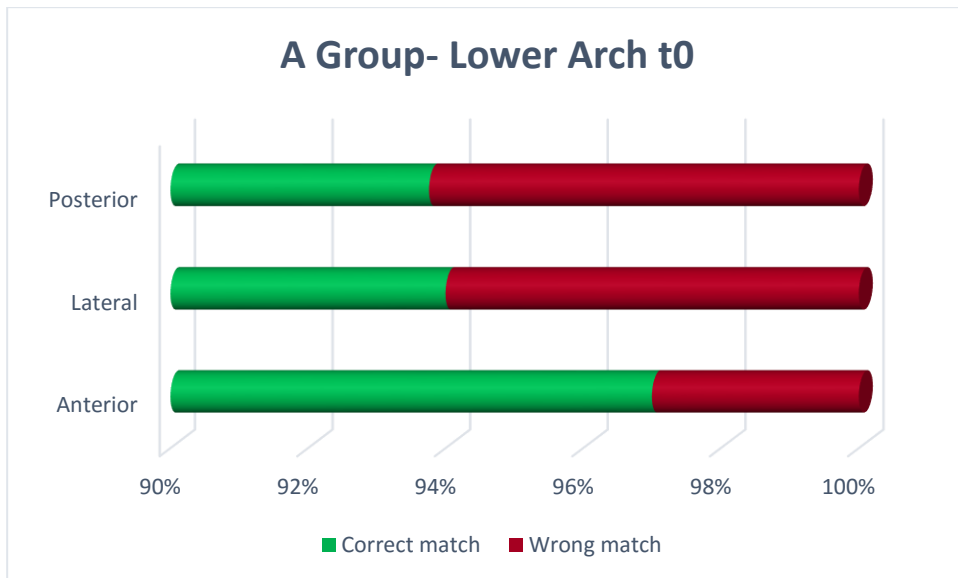
For group C were made for each body, the overlays of the two scans, initial and final, at time t0 and T1, with the orthopantomographs of the subject performed when he was alive (Graph.17-20). For none of the bodies has been found full mouth periapical films.

The results show that the overlap always exceeds 90% in the anterior sectors of both arches for all groups for both the detection time t0 and T1.

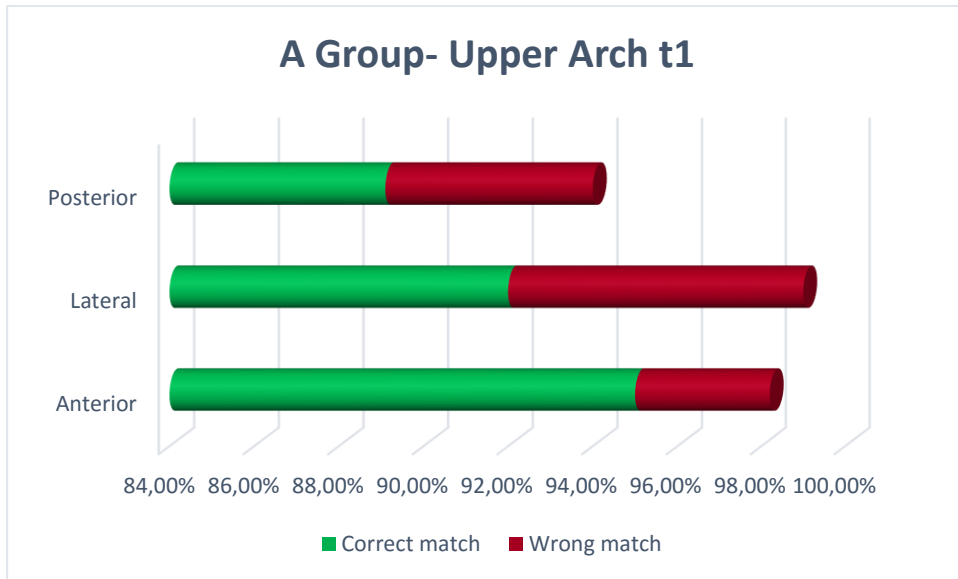
The correctness of the overlays is lowered in particular in the posterior sectors in group A, at the time T1, and slightly in the lateral ones always at the time T1 probably for the effects related to the displacement of the teeth during the orthodontic therapy, which makes more segmented the exact overlap. In group C there is the same trend, but it is in particular the lower posterior sector that where the quality of the matching is lower, probably for the quality of the scan which is sometimes more reduced in those areas where there is a poor access.



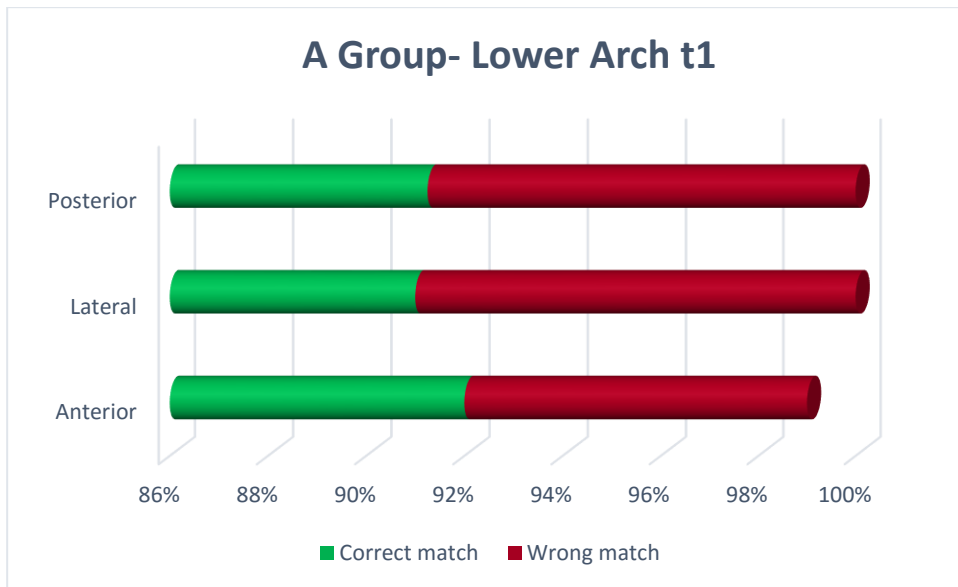
*Graphic 9 First scan-orthopantomograph superimposition in the upper arch of A group*



*Graphic 10 First scan-orthopantomograph superimposition in the lower arch of A group*

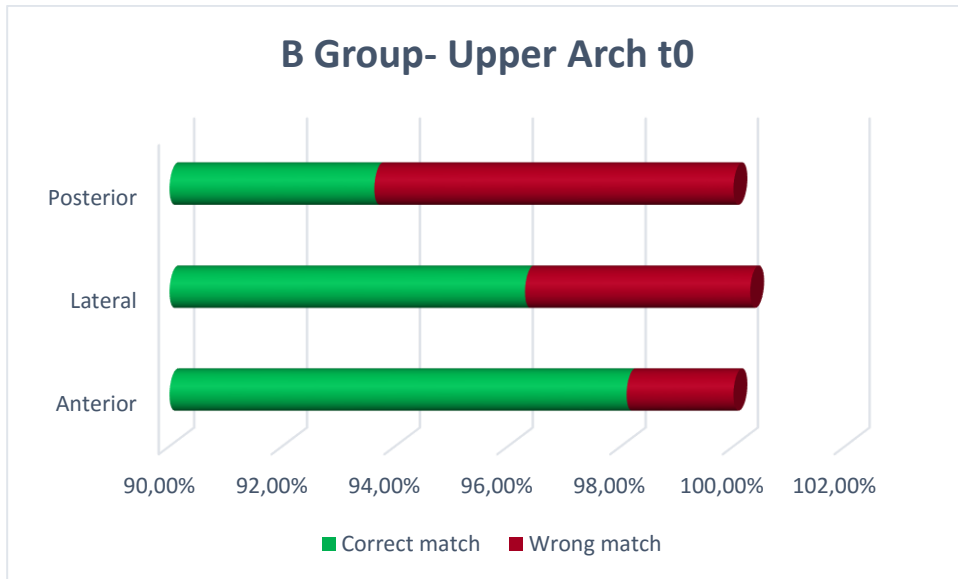


Graphic 11 Second scan-orthopantomograph superimposition in the upper arch of A group

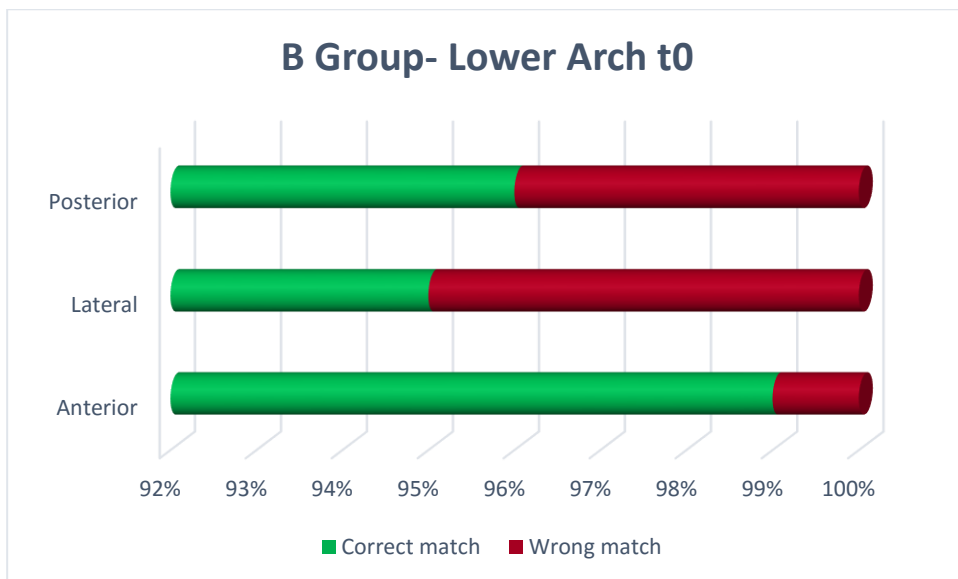


Graphic 12 Second scan-orthopantomograph superimposition in the lower arch of A group

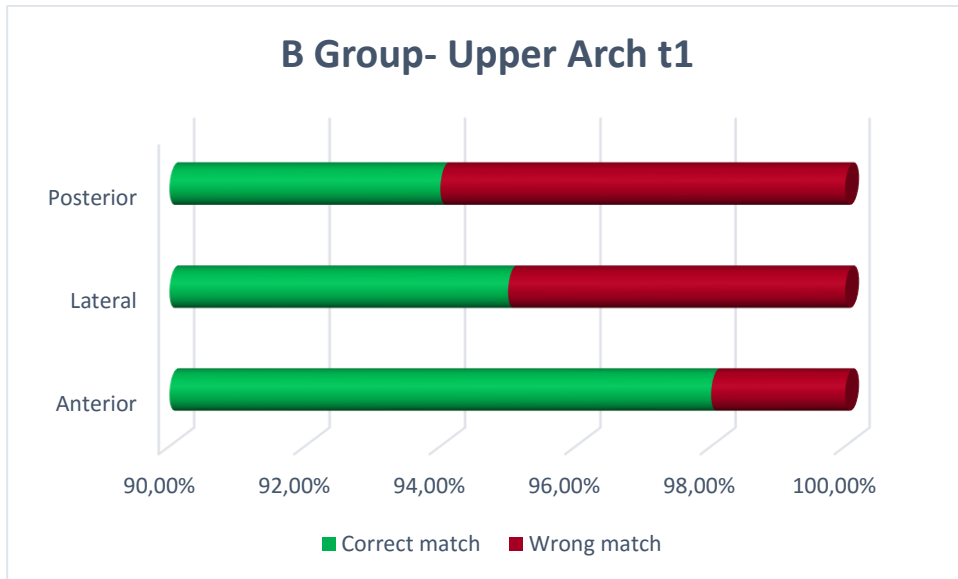




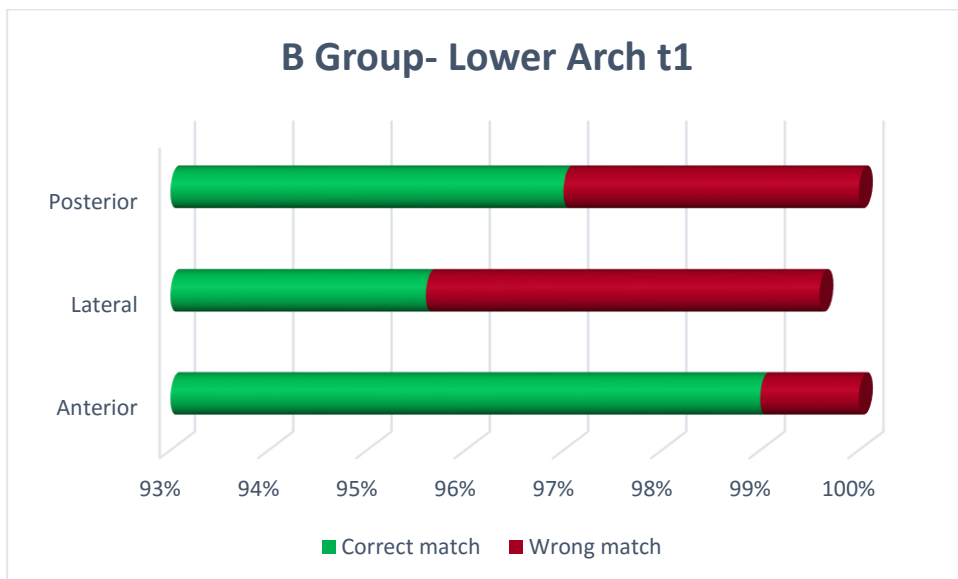
*Graphic 13 First scan-orthopantomograph superimposition in the upper arch of B group*



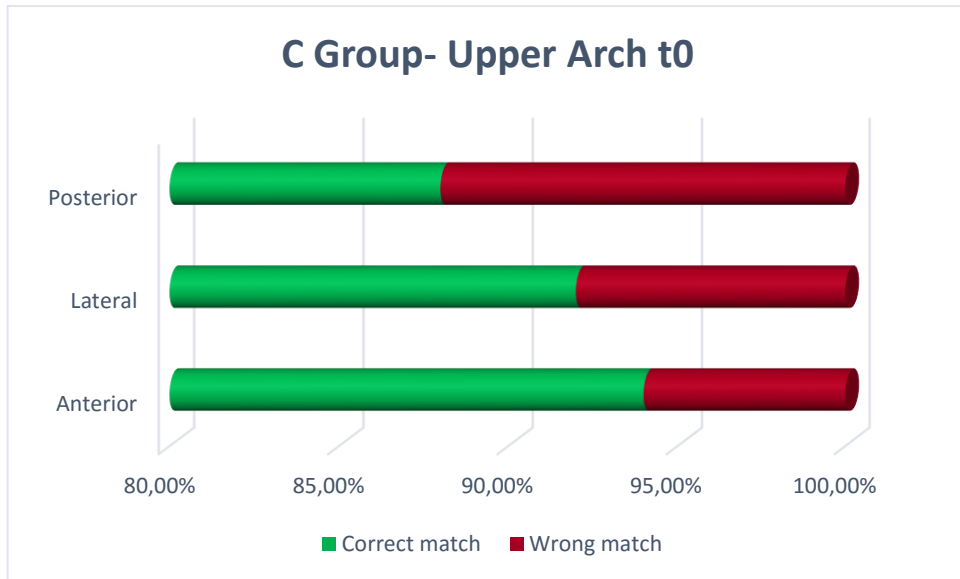
*Graphic 14 First scan-orthopantomograph superimposition in the lower arch of A group.*



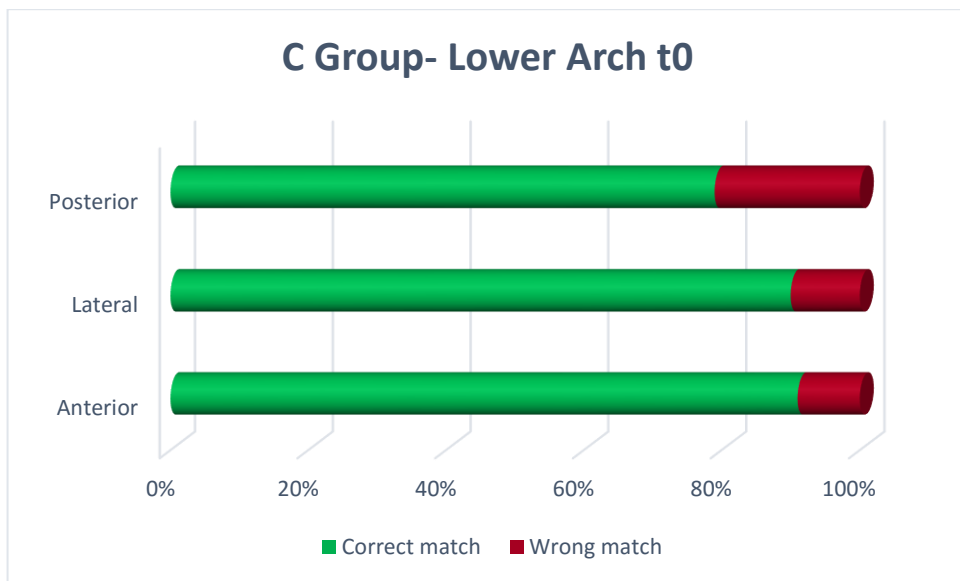
Graphic 15 Second scan-orthopantomograph superimposition in the upper arch of B group.



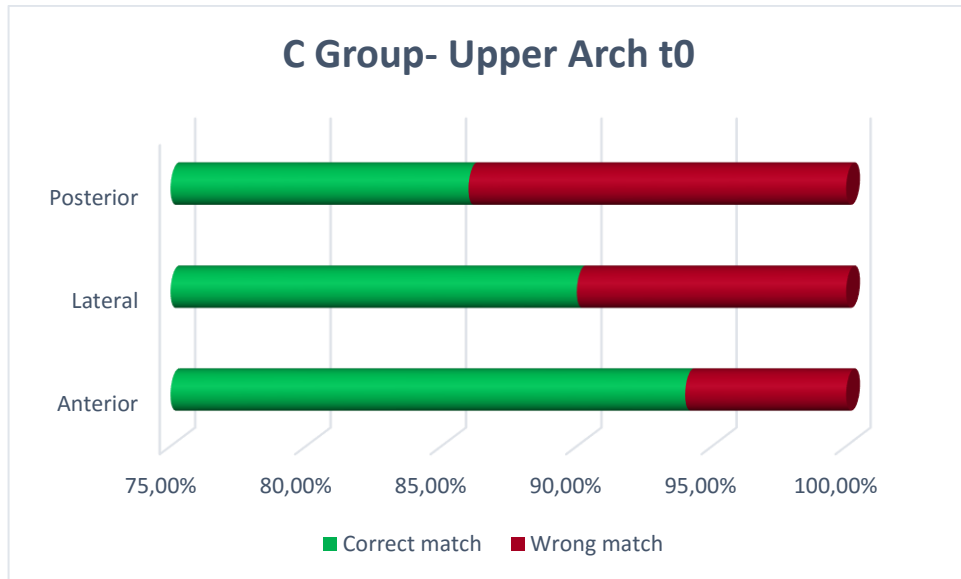
Graphic 16 Second scan-orthopantomograph superimposition in the upper arch of B group.



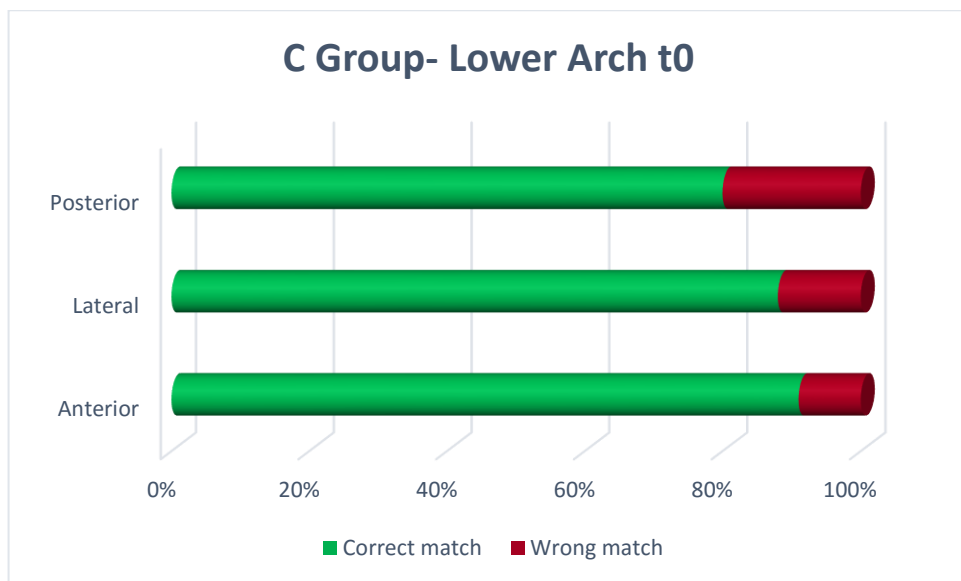
Graphic 17 First scan-orthopantomograph superimposition in the upper arch of C group.



Graphic 18 First scan-orthopantomograph superimposition in the lower arch of C group.



Graphic 19 Second scan-orthopantomograph superimposition in the upper arch of C group.



Graphic 20 Second scan-orthopantomograph superimposition in the lower arch of C group.

To verify that the difference between the mean percentages is not due to the case but that it is a sign of a reliability of the digital-radiographic comparison, the data were analyzed by the X-square test ( $p < 0,05$ ) and the

X-square test with Yates correction. The non-significant differences in all the groups between the t0 and t1 specific values of each sector demonstrate the potential reliability of this type of matching as new comparative method for personal identification.

Table 18 X-square test and X-Square test with Yates correction in the A group (NS: not significant).

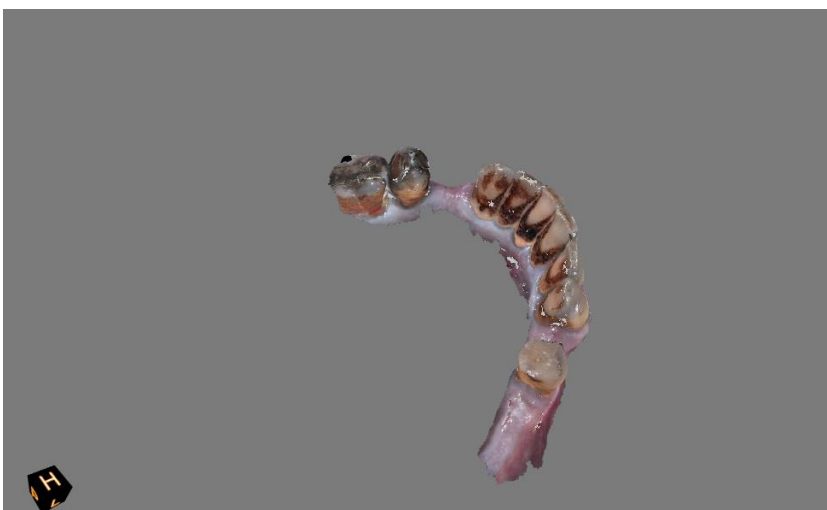
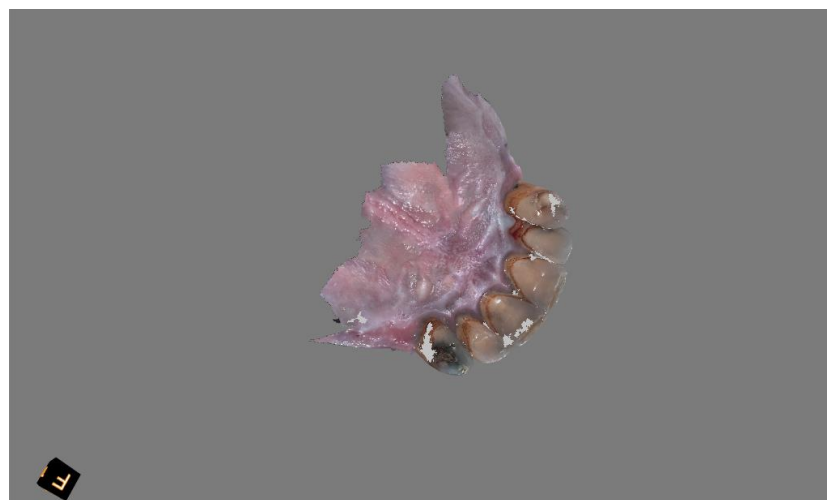
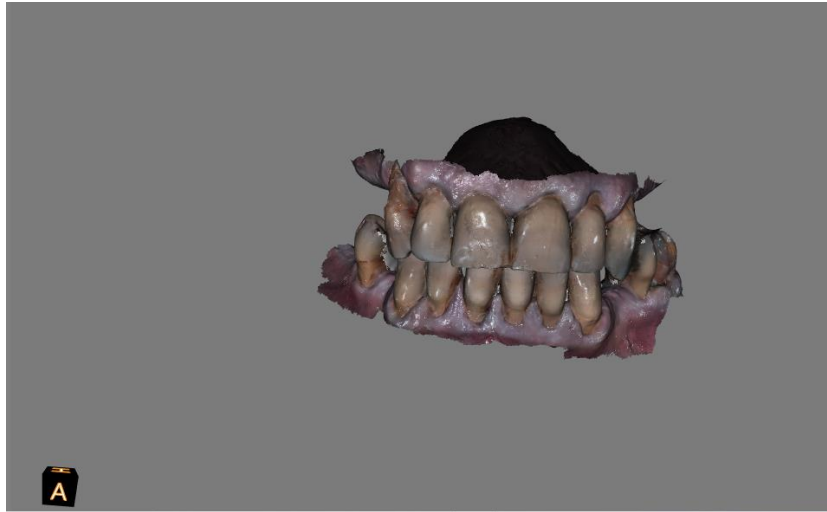
A group t0-t1	X-Square test	p	X-Square test with Yates Correction	p	Odds Ratio	Significativity
Upper Anterior	0,41	0,5236	0,08	0,7754	1,59	NS
Upper Lateral	0,33	0,5673	0,07	0,7849	0,7	NS
Upper Posterior	0,01	0,9208	0,05	0,8192	1,07	NS
Lower Anterior	1,73	0,1888	0,98	0,3223	2,46	NS
Lower Lateral	0,65	0,4206	0,29	0,5913	1,55	NS
Lower Posterior	0,45	0,5003	0,16	0,6851	1,44	NS

Table 19 X-square test and X-Square test with Yates correction in the B group (NS: not significant).

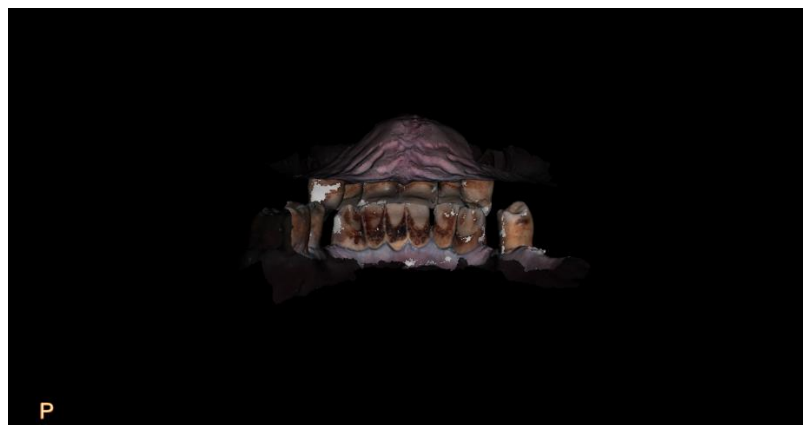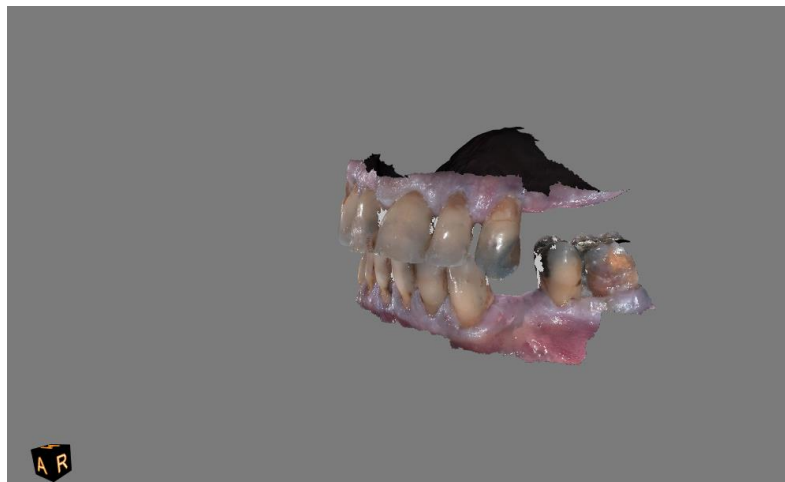
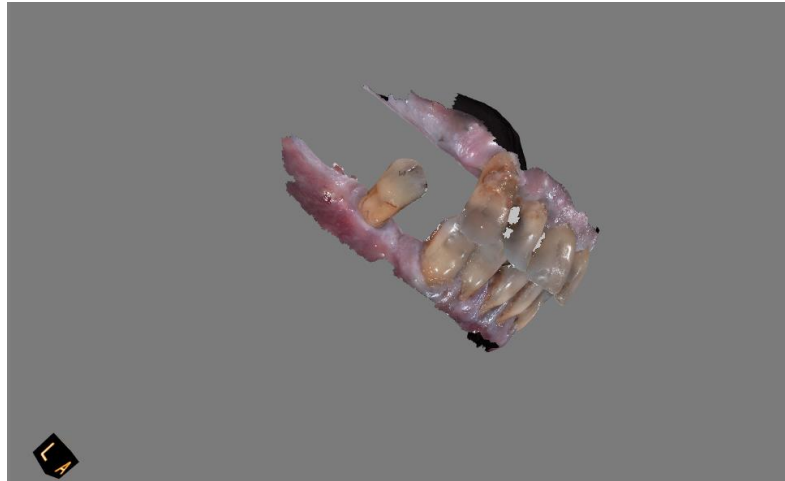B group t0-t1	X-Square test	p	X-Square test with Yates Correction	p	Odds Ratio	Significativity
Upper Anterior	0	0,952	0,21	0,6453	1,05	NS
Upper Lateral	0,12	0,733	0	1	1,26	NS
Upper Posterior	0,01	0,9135	0,03	0,8533	0,94	NS
Lower Anterior	0	1	0,51	0,4773	1	NS
Lower Lateral	0,12	0,733	0	1	0,79	NS
Lower Posterior	0,15	0,7004	0	1	0,74	NS

Table 20 X-square test and X-Square test with Yates correction in the C group (NS: not significant).

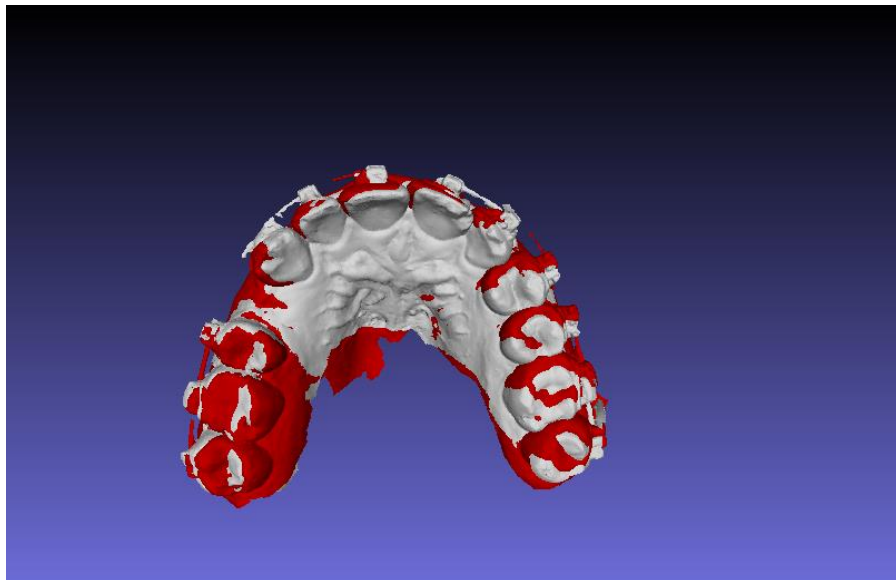
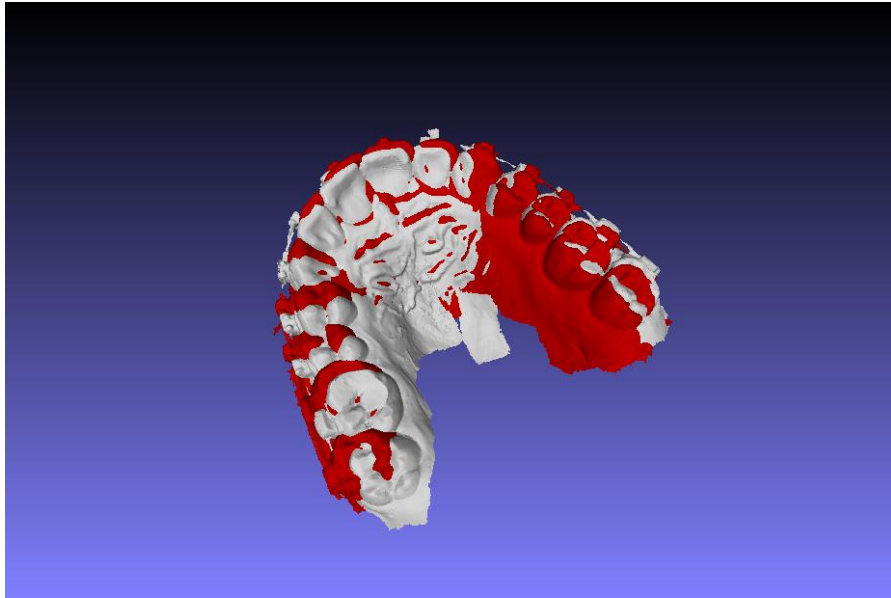
C group t0-t1	X-Square test	p	X-Square test with Yates Correction	p	Odds Ratio	Significativity
Upper Anterior	0	1	0,09	0,7659	1	NS
Upper Lateral	0,24	0,6212	0,06	0,8048	1,28	NS
Upper Posterior	0,18	0,6741	0,04	0,8335	1,19	NS
Lower Anterior	0	1	0,06	0,8048	1	NS
Lower Lateral	0,2	0,6513	0,05	0,8212	1,23	NS
Lower Posterior	0,03	0,861	0	1	0,94	NS



*Figure 29 Frontal and occlusal view of intraoral scan on cadaver*



*Figure 30 Right, left and back view of digital scan occlusion of a cadaver*



*Figure 31 Examples of superimposition of initial and last scan during orthodontic treatments of orthodontic patients for rugoscopic study purpose.*



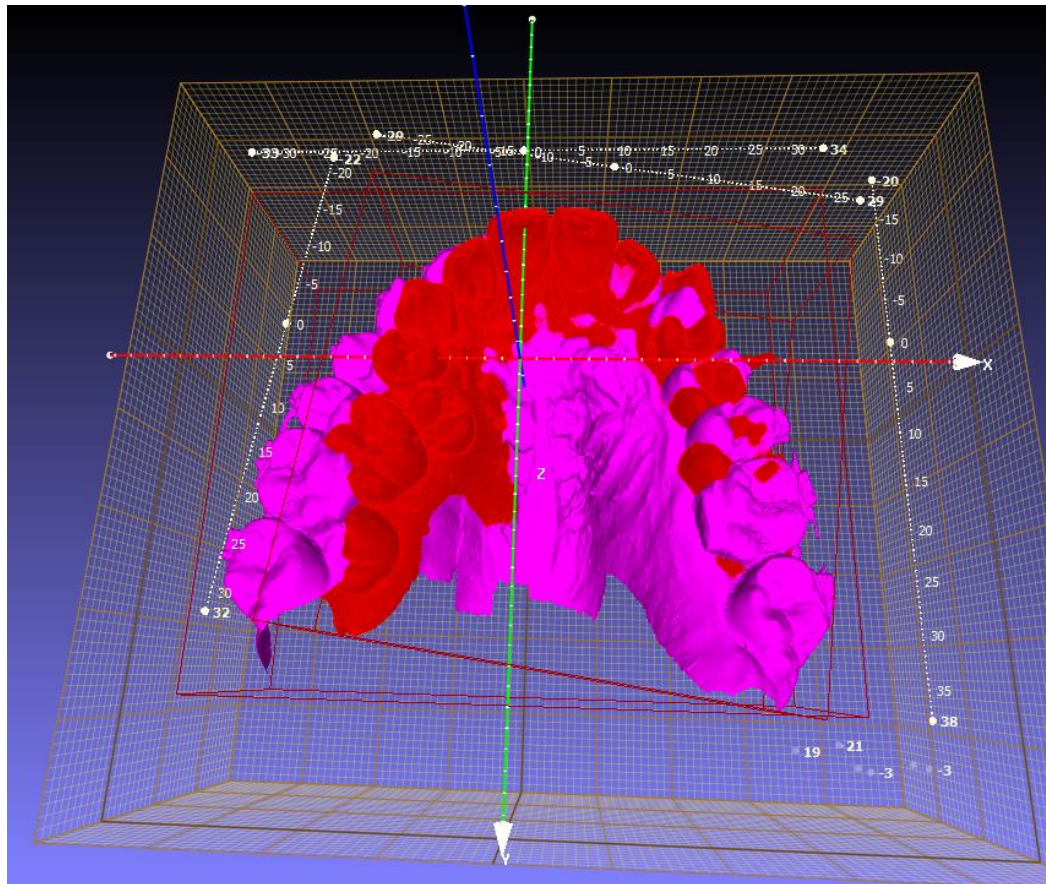
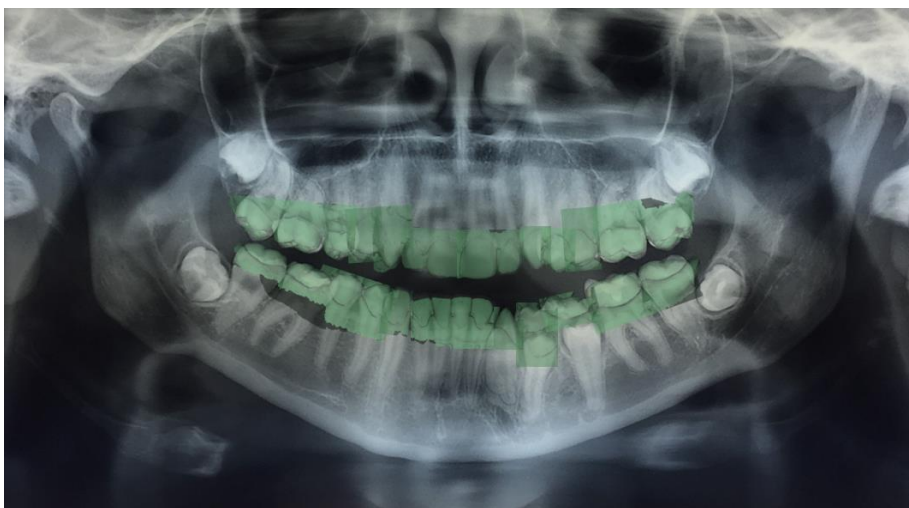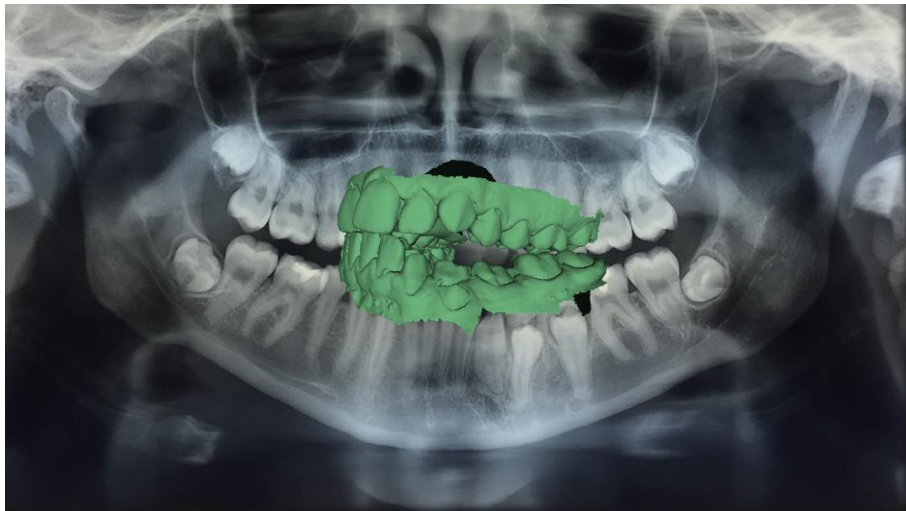
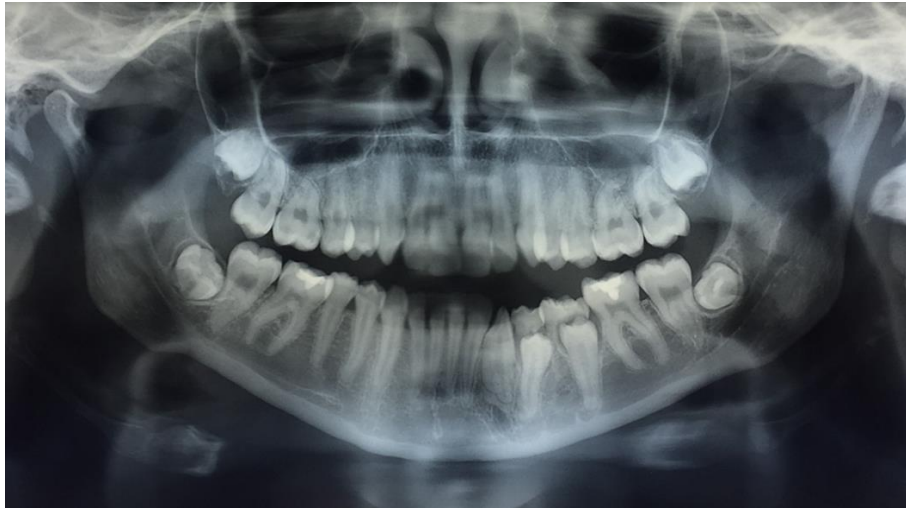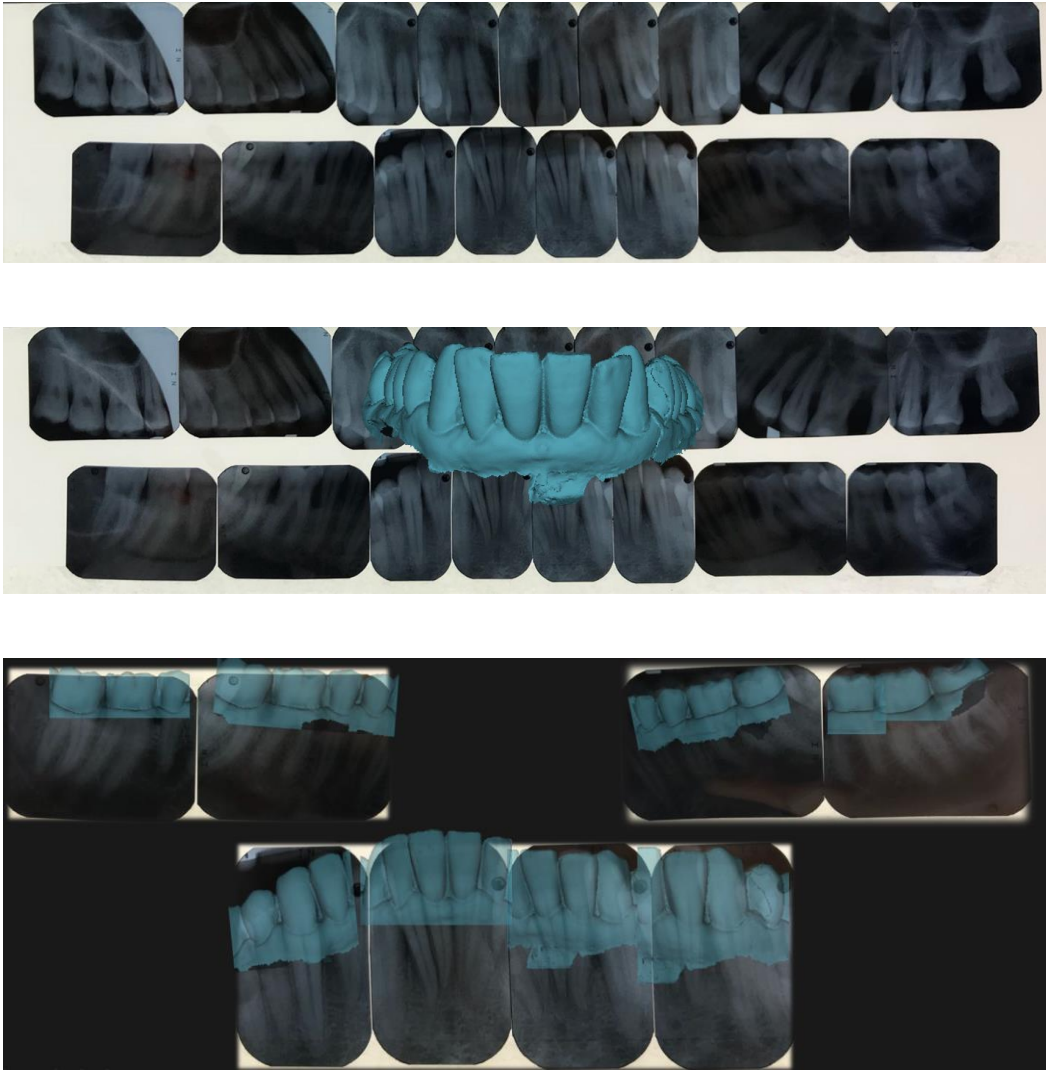


Figure 32 Example of failed matching between an initial digital scan and a wrong second digital scan, not belonging the same person.



*Figure 33 Example of scan-ortopantomograph superimposition.*



*Figure 34 Example of digital scan-full mouth periapical films superimposition.*

## 7. Discussion

Since the first applications of forensic odontology methods for identification purposes has emerged as the competences of the dentist and in particular of the specialist in orthodontics can play a key role in the events and in all those situations where the determination of an individual's identity is made necessary by the lack of other identifying elements, as happens in human remains or mutilated bodies, but also by the complexity of certain events in which many people to whom it must be attributed an identity are involved<sup>5, 21, 55</sup>. Mass disasters, terrorist attacks, air-plane accidents, natural disasters such as earthquakes and tidal waves, are all examples of events that harm a large number of victims in the world. In all these cases, the adoption of methods as effective as possible as easy to use and, why not, less costly than other solutions (such as the large-scale DNA<sup>17</sup> examination has rather prohibitive costs) is extremely important<sup>1,15</sup>. This is certainly one of the first reasons why scientific research in forensic field has consistently sought to document the potential and benefits of comparative methods of dental records for identification purposes<sup>61, 74</sup>.

Examining the currently available scientific literature up to the most recent contributions, however, emerges as compared to the advances in dentistry (and of orthodontics in particular) in the digital field<sup>84, 94</sup>, except for a few research initiatives the forensic science, the forensic dentistry or odontology, has not put itself at the pace of the digital age and still remained branch that exploit methodologies of basic investigation.

Forensic dentistry employs several identifying methods, some of which are of lesser impact and whose reliability is still being debated in the scientific community, such as cheiloscopy<sup>42, 59, 60</sup> and bite marks<sup>25, 26, 28</sup>, which have a smaller scope but also the need to be supported by other elements as an instrument of evidence. Other methods, most of them, are of great interest and have a significant impact in the reality of human identification, sometimes constituting the elective method to perform identifying findings or medical-legal investigations<sup>2, 6, 7, 8, 11, 13, 14, 19</sup>.

The dental comparison between ante-mortem and possible post-mortem records for identification purposes occupies most of the forensic

literature<sup>14</sup>. To look at most of the studies, they support the possibility of recognizing the identity of a subject through the comparison of his plaster models<sup>71,74</sup> or dental radiographs<sup>14, 34</sup> with the data of the direct inspection on an unknown identity body. However, most of these methods do not provide for a real overlap of elements that might return a certain data, but are based on visual evidence sometimes supported by photographic documentation.

Many Authors have then documented the specific potential of the study of palatal rugae, called rugoscopy or palatoscopy<sup>29-33, 61-72, 76</sup>. This exam is described as even more useful because the preservation of the palatine vault even in extreme environmental situations that deteriorate the body allows to perform an accurate investigation. In theory this principle is correct, but apart from a study<sup>76</sup> on carbonized and non-carbonized corpses which is of a descriptive nature and is limited to the inspection of the oral cavity, all the other studies currently documented are mainly researches on plaster models of living subjects on which the observers want to determine the sex<sup>61</sup> or the racial characteristics<sup>63, 65</sup> or thanks to

which is possible to verify the stability of the palatal rugae following orthodontic treatments (with the comparison of pre and post treatment casts) to validate their use as a forensic marker<sup>68, 70, 71-75, 91, 96, 97</sup>.

The intrinsic limit of these studies is that the experimentation is carried out on plaster models and sometimes digital reproduction of the same and does not take into account the characteristics of the material of which they are made, which often presents superficial imperfections or defects or distortions (related to the impression from which they derive) that it is impossible to establish retrospectively with an external evaluation<sup>71-75, 91, 96,</sup>

<sup>97</sup>. Moreover, another element of which is not taken into account is the effect of the compression of the material by impression (alginate or silicone) on the mucous structures including palatal rugae which can therefore be altered already in the acquisition phase and therefore do not reflect the actual conformation of the palate of the subject. Obviously, the same can not be said for the dental elements that are properly reproduced but are still included in a dental cast that often in the storage stages may

report injuries or fractures that disperse important details of the dental anatomy.

To these aspects, one factor no less important should be added for a complete consideration. The traditional rugoscopic exam uses a pencil to highlight the palatal rugae pattern, including length and shape, and a manual caliper<sup>74, 91, 93, 96, 97</sup>. These tools cannot compete with the current skills and technologies and they cannot anyhow allow a detailed and complete study of a complex and three-dimensional structure like the palate.

Intra-oral scanners can no longer be considered a new technology in the dental workflow because they have been introduced in the daily practice many years ago<sup>93</sup>, but their application in the forensic field, for the comparison of the dental data and for the rugoscopic examination, is extremely interesting and innovative. The data in this study show that in subjects under different types of orthodontic therapies the repeated scanning of the dental arches is an advantage both for the monitoring of



the orthodontic movement and for verifying the stability of the palatal rugae and their features. A large number of studies on the effect of orthodontic therapies on palatal rugae are related to fixed multi-brackets therapies, functional therapies or orthopaedic therapies studying the effect of the palatal expansion on the length of palatal rugae<sup>68, 71-73, 75, 96, 97</sup>. This study included patients underwent a therapy with clear aligners too. The therapy with orthopaedic devices such as the rapid palate expander affects the length of the main palatal rugae, but not their shape. The results agreed with other Authors<sup>68, 75</sup>. Significant are the results for patients with functional devices too, where the length of palatal rugae increased with the therapy, and this can not be related only to the eruption of premolars, since a significant change in length have been recorded on the first ruga probably due to the effect of the devices (especially Fraenkel III and Twin Block). Not significant were the results for patients with fixed multi-brackets therapies and clear aligners. The presence of a comparative control group (group B) on which no orthodontic forces would have been applied has allowed other evaluations to be made. It is true that the

orthodontic group (Group A) includes growing subjects but their number is lower than the adult subjects who are part of the sample and who have undergone fixed multi-brackets therapy or with invisible aligners. As a result, group A and group B are mostly adult subjects. In group B, however, in which the subjects had been included in a program to control their periodontal health, the presence of restorations of different types and of different extension gave the possibility to evaluate the stability of palatal rugae even in subjects that have not natural teeth in the front and lateral sector. And the results of this evaluation are that the teeth restored with fixed prostheses or with conservative restorations behave like natural teeth not undergoing any kind of significant variation either for the shape or for the length of the rugae themselves.

The use of the intraoral scanner to record a digital impression of the oral cavity of the corpse as it was done in this study, puts in front of perhaps more articulated considerations. Oral autopsy documented in the literature is described as a complex surgical method but sometimes necessary for a complete inspection of the body's mouth<sup>77,79</sup>. This practice

is rather invasive and exposes elements of debate not only on the ethical level. The alteration of the integrity of the patient's face is evident, despite the accuracy of the procedure. The great limit of oral autopsy is that this alteration produces an irreversible modification of the relationships of the anatomical structures involved in the surgical dissection, as is the case for the general autopsy involving the other districts of the body, and may have consequences in judicial investigations.

This study explored the possibility of performing a virtual autopsy of the corpse, without altering the integrity of its body and collecting as much information as possible that is not limited to a visual inspection but that allows to register the dental and mucous structures in a three-dimensional real-coloured file. Significant chromatic changes of oral mucosa can be monitored scan by scan adding important informations to post-mortem decomposition process. The use of different tips that touch the surfaces without getting in contact with them and without compressing them allow to reach all the areas of the oral cavity even when, as happens in the living, the opening of the mouth can be rather limited. Among other things, the

possibility to record also the occlusion allows to make a comparative examination also of this aspect.

In literature there are not even studies that have investigated the possibility of using intraoral scans of living subjects or corpses for comparative radiographic studies. The possibility to “slice” the scans and to superimpose them with panoramic radiographs of the dental arches and full mouth periapical films has several advantages. First of all, it returns to two-dimensional examinations such as orthopantomographs and full mouth periapical films the importance of being necessary examinations for identifying purposes that do not have, from this point of view, less validity of three-dimensional examinations such as CT Cone beam. The possibility to make a matching, with excellent results, of a three-dimensional file with a two-dimensional examination lead to understand how it is not necessary to have a three-dimensional x-ray exam to reason in three-dimensional terms.

So besides the advantage of knowing that the recovery of radiographs belonging to a subject can be of aid or real proof of identification, there is the advantage of knowing that the full mouth periapical film of a subject can be superimposed to an intraoral scan with the same purpose. Also the full mouth periapical film executed on a corpse (element not of little importance considering that it is an examination that can be played without affecting the position of the body) or on human remains, can be used as a post-mortem record to be compared to ante-mortem records such as radiographs of the subject in life or intraoral scans.

## 8. Conclusions

Personal identification has always had a major role in many legal and administrative actions regarding both living and death beings. Nowadays has been invested by a new social and political interest. Western Countries are bestowing a massive flux of migrants without any type of ID, making a rapid and efficient personal identification system a necessity. In addition to this, the frequent terrorist attacks have shown that personal identification is fundamental for national and international security and for victim recognition. In forensic medicine personal identification is attained through a process that evaluates different informations. There is not a gold standard, and every approach to the issue has its advantages and flaws. The most common and easy approach is to compare recorded

features with the ones noted during the identification process but retrieving this type of information is often difficult and slow. On the one hand, the most reliable approach, DNA analysis is too expensive to be used in large scale, needs high-specialized personal and has an important privacy issue, on the other one oral autopsy is an invasive method altering facial conservation could complicate visual recognition of remains by family members and other interested persons. This study has been set up to study and develop new, reliable and fast methods of personal identification that can surpass many of the issues seen with the other techniques by a modern rugoscopy, a modern radiographic-digital comparison and virtual oral autopsy.

## 9. Bibliography

- 1) Disaster victim identification. Catherine Adams. Forensic Odontology: An Essential Guide, First Edition. John Wiley & Sons, Ltd. 2014.
- 2) Divakar KP, Forensic Odontology: the new dimension in dental analysis. International Journal of Biomedical Sciences, March 2017, 13 (1): 1-5.
- 3) Sognaes RF & Strøm F, The odontological identification of Adolf Hitler. Definitive documentation by X-Rays, interrogation and autopsy findings, in Acta Odontologica Scandinavica, Feb. 1973; 31 (1): 43-69.



- 4) Keiser-Nielsen S & Strøm F, The odontological identification of Eva Braun Hitler, in *Forensic Science International*, Jan.-Feb. 1983; 21 (1): 59-64.
- 5) Williams LN. An introduction to forensic dentistry. *General Dentistry* 2013; 61(5): 16-7.
- 6) Tinoco RL, Martins EC, Daruge E Jr, Daruge E, Prado FB, Caria PH. Dental anomalies and their value in human identification: a case report. *Journal of Forensic Odontostomatology* 2010; 28(1): 39-43.
- 7) Nuzzolese E, Di Vella G. Digital radiological research in forensic dental investigation: case studies. *Minerva Stomatologica* 2012; 61(4): 165-73.
- 8) Willems G. A review of the most commonly used dental age estimation techniques. *Journal of Forensic Odontostomatology* 2001; 19(1): 9-17.
- 9) Zorba E, Spiliopoulou C, Moraitis K. Evaluation of the accuracy of different molar teeth measurements in

- assessing sex. *Forensic Science and Medicine Pathology* 2013; 9(1): 13-23.
- 10) Joseph AP, Harisha RK, Mohammad PKR, Kumar VRB. How reliable is sex differentiation from teeth measurements? *Oral Maxillofacial Pathology Journal* 2013; 4(1): 289-92.
- 11) Edgar HJ. Estimation of ancestry using dental morphological characteristics. *Journal of Forensic Science* 2013; 58 (Suppl 1): S3-8.
- 12) Yaacob H, Nambiar P, Naidu MD. Racial characteristics of human teeth with special emphasis on the Mongoloid dentition. *Malaysian Journal Pathology* 1996; 18(1): 1-7.
- 13) Sydney L. Forensic odontology – identification by dental means. *Australian Dental Journal*. 1977; 22 (6): 481-487.
- 14) Pinchi V, Norelli GA, Caputi F, Fassina G, Pradella F, Vincenti C. Dental identification by comparison of

antemortem and postmortem dental radiographs:  
influence of operator qualifications and cognitive bias.  
Forensic Science International 2012; 222(1-3): 252-5.

15) Pittayapat P, Jacobs R, De Valck E, Vandermeulen  
D, Willems G. Forensic odontology in the disaster victim  
identification process. Journal of Forensic  
Odontostomatology 2012; 30(1): 1-12.

16) John F. Owens. Forensic Odontology with case  
report. International Journal of Medical Sciences Eighth  
Series. 1970; 3: 3.

17) Rai B, Kaur J. DNA technology and Forensic  
Odontology. EvidenceBased Forensic Dentistry. Springer-  
Verlag Berlin Heidelberg. 2013.

18) Kanchan T, Machado M, Rao A, Krishan K, Garg  
AK. Enamel hypoplasia and its role in identification of  
individuals: A review of literature. Indian Journal of  
Dentistry 2015; 6(2): 99-102.

- 19) Hanihara T. Morphological variation of major human populations based on nonmetric dental traits. *American Journal of Physiologic Anthropology* 2008; 136(2): 169-82.
- 20) Nath S. *Introduction to Forensic Anthropology*. New Delhi: Gian Publishing House 1987.
- 21) Clark DH, *Practical Forensic Odontology*, Butterworth Heinemann Ltd., Ed. 1992.
- 22) Gall JAM, Boos SC, Payne-James JJ, Culliford EJ, *Forensic Medicine – Colour Guide*, Churchill Livingstone, 2003.
- 23) Barsley R, Freeman A, Metcalf R, Senn D, Wright F. Bitemark analysis. *Journal of American Dental Association* 2012; 143(5): 444.
- 24) Sweet D, Lorente M, Lorente JA et al. An improved method to recover saliva from human skin: the double swab technique, *Journal of Forensic Science* 1997; 42(2):320-2.

- 25) Sheasby DR, MacDonald DG. A forensic classification of distortion in human bite marks, *Forensic Science International* 2001; 122(1):75-78.
- 26) Kaur S, Krishan K, Chatterjee PM, Kanchan T. Analysis and identification of bite marks in forensic casework. *Oral Health and Dental Management* 2013; 12(3): 127-31.
- 27) Clement JG. Role of and techniques in forensic odontology. Chapt. 45 in Payne-James JJ, Busuttill A, Smock W. 'Forensic Medicine: Clinical and pathological Aspects' 2003; Greenwich Medical Media.
- 28) Thali MJ, Braun M, Markwalder Th.H, Brueschweiler W, Zollinger U, Malik NJ, Dirnhofer R. Bite mark documentation and analysis: the forensic 3D/CAD supported photogrammetry approach. *Forensic Science International* 2003; 135:115-121.
- 29) Kotra Shetti VS, Hollikatti K, Mallapur MD, Hallikeremath SR, et al. Determination of palatal rugae

patterns among two ethnic populations of India by logistic regression analysis. *Journal of Forensic and Legal Medicine* 2011; 18: 360-365.

- 30) Ohtani M, Nishida N, Chiba T, Fukuda M, et al. Indication and limitations of using palatal rugae for personal identification in edentulous cases. *Forensic Science International* 2008; 176 (2-3): 178-182.
- 31) Kapali S, Townsend G, Richards L, Parish T. Palatal rugae patterns in Australian Aborigines and Caucasians. *Australian Dentistry Journal* 1997; 42: 129-133.
- 32) Demirjian A, Goldstein H, Tanner JM. A new system for dental age estimation. *Human Biology* 1973; 45: 211-27.
- 33) Thomas CJ, Kotze TJ. The palatal rugae pattern: A new classification. *Journal Dental Association of South Africa* 1983; 38: 153-157.

- 34) Kvaal SI, Kolltveit KM, Thomsen IO, Solheim T. Age estimation of adults from dental radiographs. *Forensic Science International* 1995; 74(3):175-85.
- 35) Gustafson G. Age determination on teeth. *Journal of American Dental Association* 1950; 41(1): 45-54.
- 36) Johanson G. Age determination from teeth. *Odontologisk Revy* 1971;22: 1-126.
- 37) Khamis MF, Taylor JA, Malik SN, Townsend GC. Odontometric sex variation in Malaysians with application to sex prediction. *Forensic Science International* 2014; 234: 183. e1-7.
- 38) Bakkannavar SM, Monteiro FN, Arun M, Kumar PG. Mesiodistal width of canines: a tool for sex determination. *Medicine, Science and the Law* 2012; 52(1): 22-6.
- 39) Acharya AB, Mainali S. Sex discrimination potential of buccolingual and mesiodistal tooth dimensions. *Journal of Forensic Science* 2008; 53(4):790-2.

- 40) Rao NS, Rao NN, Pai ML, Kotain MS. Mandibular canine index – a clue for establishing sex identity. *Forensic Science International* 1989; 42: 249-54.
- 41) Acharya AB, Mainali S. Are dental indexes useful in sex assessment? *Journal of Forensic Odontostomatology* 2008; 26(2): 53-9.
- 42) Singh J, Gupta KD, Sardana V, Balappanavar AY, Malhotra G. Sex determination using cheiloscopy and mandibular canine index as a tool in forensic dentistry. *Journal of Forensic Dental Science* 2012; 4(2): 70-4.
- 43) Joseph AP, Harisha RK, Mohammad PKR, Kumar VRB. How reliable is sex differentiation from teeth measurements? *Oral Maxillofacial Pathology Journal* 2013; 4(1): 289-92.
- 44) Iscan MY, Kedici SP. Sexual variation in buccolingual dimensions in Turkish dentition. *Forensic Science International* 2003; 137: 160-4.



- 45) Galdames IS, Henríquez IR, Cantin M. Sex chromatin in dental pulp. Performance of diagnosis test and gold standard generation. *International Journal of Morphology* 2010; 28(4): 1093-6.
- 46) Galdames IS, Flores A, Roa I, Cantín M, Zavando D. Sex determination by observation of barr body in teeth subjected to high temperatures. *International Journal of Morphology* 2011; 29(1): 199-203.
- 47) Zapico SC, Ubelaker DH. Sex determination from dentin and pulp in a medicolegal context. *Journal of American Dental Association* 2013; 144(12): 1379-85.
- 48) Porto IM, Laure HJ, Tykot RH, de Sousa FB, Rosa JC, Gerlach RF. Recovery and identification of mature enamel proteins in ancient teeth. *European Journal of Oral Science* 2011; 119(1): 83-7.
- 49) Nakahori Y, Takenaka O, Nakagome Y. A human X-Y homologous region encodes amelogenin. *Genomics* 1991; 9: 264-9.

- 50) Alvarez-Sandoval BA, Manzanilla LR, Montiel R. Sex determination in highly fragmented human DNA by high-resolution melting (HRM) analysis. PLoS One 2014; 9(8): e104629.
- 51) Yaacob H, Nambiar P, Naidu MD. Racial characteristics of human teeth with special emphasis on the Mongoloid dentition. Malaysian Journal of Pathology 1996; 18(1): 1-7.
- 52) Edgar HJ. Estimation of ancestry using dental morphological characteristics. Journal of Forensic Science 2013; 58 (Suppl 1): S3-8.
- 53) Nirmala SV, Gaddam KR, Vimaladevi P, Nuvvula S. Protostylid: A case series. Contemporary Clinical Dentistry 2013; 4(3): 349-52.
- 54) Hemasathya BA, Balagopal S. A study of composite restorations as a tool in forensic identification. Journal of Forensic Dental Science 2013; 5(1): 35-4.

- 55) Tsuchihashi Y. Studies on personal identification by means of lip prints. *Forensic Science* 1974 Jun; 3 (3): 233-248.
- 56) Ball J. The current status of lip prints and their use for identification. *Journal of Forensic Odontostomatology*. 2002;20:43–6.
- 57) Hirth L, Götttsche H, Goedde HW. Lip prints–Variability and genetics. *Humangenetik*. 1975;30:47–62.
- 58) Segui MA, Feucht MM, Ponce AC, Pascual F. Persistent lipsticks and their lip prints: New hidden evidence at the crime scene. *Forensic Science International* 2000;112:41–7.
- 59) Venkatesh R, David MR. Cheiloscopy: an aid for personal identification. *Journal of Forensic Dental Sciences* 2011 Jul-Dec; 3(2): 67–70.
- 60) Gugulothu RN, Alaparathi RK, Maloth KN, Kesidi S, Kundoor V, Palutla MM. Personal identification and sex determination using cheiloscopy. *Journal of Indian*

Academy of Oral Medicine and Radiology 2015;27:399-404.

- 61) Bharath ST, Kumar GR, Dhanapal R, Saraswathi TR.  
Sex determination by discriminant function analysis of palatal rugae from a population of coastal Andhra. Journal of Forensic Dental Science 2011 Jul-Dec; 3(2):58-62.
- 62) Filho EM, Helena SP, Arsernio SP, Suzana MC.  
Palatal rugae pattern as bioindicator of identification in forensic dentistry. RFO. 2009; 14:227-33.
- 63) Babu GS, Bharath TS, Kumar NG. Characteristics of Palatal Rugae Patterns in West Godavari Population in India. Journal of Clinical and Diagnostic Research 2013 Oct; Vol-7(10):2356-2359.
- 64) Chowdhry A. A simple working type Integrated Rugoscopy Chart proposed for analysis and recording rugae pattern. Journal of Forensic Dental Sciences 2016; Vol.8(3):171-172.

- 65) Thomas CJ, Kotze TJ, Van der Merwe CA. An improved statistical method for the racial classification of man by means of palatal rugae. *Archives of Oral Biology* 1987; 32(4):315-7.
- 66) Lysell L. Plicae palatinae transversae and papilla incisiva in man; a morphologic and genetic study. *Acta Odontologica Scandinavica* 1955; Suppl 18:5-137.
- 67) Indira AP, Manish Gupta M, David MP. Usefulness of palatal rugae patterns in establishing identity: Preliminary results from Bengaluru city, India. *Journal of Forensic Dental Science* 2012 Jan-Jun; 4(1): 2-5.
- 68) Mustafa AG, Allouh MZ, Alshehab RM, Morphological changes in palatal rugae patterns following orthodontic treatment. *Journal of Forensic Legal Medicine* 2015 Apr; 31:19-22.
- 69) English WR, Robinson SF, Summit JB, Oesterle LJ, Brannon RB, Morlang WM. Individuality of palatal rugae. *Journal of Forensic Science* 1988 May; 33(3): 718-726.

- 70) Abdel-Aziz HM, Sabet NE. Palatal rugae area: a landmark for analysis of pre-and post-orthodontically treated adult Egyptian patients. *East Mediterranean Health Journal* 2001 Jan-Mar; 7(1-2):60-6.
- 71) Bailey LTJ, Esmalejad A, Almeida MA. Stability of the palatal rugae as landmarks for analysis of dental casts in extraction and non extraction cases. *The Angle Orthodontist* 1996; 66(1):73-78.
- 72) Hoggan Br, Sadowsky C. The use of palatal rugae for the assessment of anteroposterior tooth movements. *American Journal of Orthodontics and Dentofacial Orthopedics* 2001 May; 119(5):482-8.
- 73) Jang I, Tanaka M, Koga Y, Iijima S, Yozgatian JH, Cha BK, Yoshida N. A novel method for the assessment of three-dimensional tooth movement during orthodontic treatment. *The Angle Orthodontist* 2009; 79(3):447-453.

- 74) Almeida MA, Phillips C, Kula K, Tulloch C. Stability of the palatal rugae as landmarks for analysis of dental casts. *The Angle Orthodontist* 1995; 65(1):43-48.
- 75) Kapoor P, Miglani R. Transverse changes in lateral and medial aspects of palatal rugae after mid palatal expansion: a pilot study. *Journal of Forensic Dental Science* 2015 Jan-Apr; 7(1):8-13.
- 76) Muthusubramanian M, Limson KS, Julian R. Analysis of rugae in burn victims and cadavers to simulate rugae identification in cases of incineration and decomposition. *The Journal of Forensic Odontostomatology* 2005 Jun; 23(1): 26-29.
- 77) Inanici MA, Cagdir S, Birgen N, Soysal Z. Identity Determination with Dental Examination and Oral Autopsy. *Academic Journal of Dental Dentistry* 2000; 2, 1-6.
- 78) Kedici PS, Atsu SS, Gokdemir K, Sarikaya Y, Gurbuz F. Micrometric Measurements by Scanning Electron

Microscope (SEM) for Dental Age Estimation in Adults.

The Journal of Forensic Odonto-Stomatology 2000; 18, 22-26.

79) Atsu SS, Aka PS, Nergis, I. Age Estimation from Root Transparency. *Turkiye Klinikleri Journal Dental Science* 2006; 12, 47-52.

80) Aka PS, Canturk N. Aka Canturk Oral Autopsy Method for the Dental Identification of Fetus and Infant Cases. *Forensic Medicine and Anatomy Research*, 2014, 2, 48-50.

81) Charan Gowda BK, Mohan CV, Hemavathi. Oral autopsy: A simple, faster procedure for total visualization of oral cavity. *Journal of Forensic Dental Science* 2016 May-Aug; 8(2): 103–107.

82) Chen LC, Xu ZQ. Innovative 3D dental measurement for tooth model restoration, *Key Engineering Materials* 2005; Vol. 295–296, no. 12, pp. 145–150.



- 83) Hong-Seok P, Chintal S. Development of high speed and high accuracy 3D dental intra oral scanner, *Procedia Engineering* 2015; Vol. 100, pp. 1174–1181.
- 84) Baheti MJ, Soni UN, Gharat NV, Mahagaonkar P, Khokhani R, Dash S. Intra-oral scanners: a new eye in dentistry. *Austin Journal of Orthopedics & Rheumatology* 2015; vol. 2, no. 3.
- 85) Alghazzawi TF. Advancements in CAD/CAM technology: options for practical implementation. *Journal of Prosthodontic Research* 2016; vol. 60, no. 2, pp. 72–84.
- 86) Raphaël R, Goujat A, Venet L, Viguie G, Viennot S, Robinson P, Farges JC, Fages M, Ducret M. Intraoral Scanner Technologies: A Review to Make a Successful Impression. *Journal of Healthcare Engineering* 2017; 1-9.
- 87) Costa JB, Pelogia F, Hagedorn B, Ferracane JL. Evaluation of different methods of optical impression making on the marginal gap of onlays created with

- CEREC 3D. Operative Dentistry 2010; vol. 35, no. 3, pp. 324–329.
- 88) Zimmermann M, Mehl A, Mörmann WH, Reich S. Intraoral scanning systems - a current overview. International Journal of Computerized Dentistry 2015; vol. 18, no. 2, pp. 101–129.
- 89) Joda T, Brägger U. Patient-centered outcomes comparing digital and conventional implant impression procedures: a randomized crossover trial. Clinical Oral Implants Research 2016; vol. 27, no. 12, pp. e185–e189.
- 90) Tzou CHJ, Artner NM, Pona I. Comparison of three-dimensional surface-imaging systems. Journal of Plastic, Reconstructive & Aesthetic Surgery 2014; vol. 67, no. 4, pp. 489–497.
- 91) Taneva E, Kusnoto B, Evans CA. 3D scanning, imaging, and printing in orthodontics. Issues in Contemporary Orthodontics 2015; Chapter 9, pp.147–188.

- 92) Aubreton O, Bajard A, Verney B, Truchetet F. Infrared system for 3D scanning of metallic surfaces. *Machine Vision and Applications* 2013; vol. 24, no. 7, pp. 1513–1524.
- 93) Ender A., T. Attin, and A. Mehl, “In vivo precision of conventional and digital methods of obtaining complete-arch dental impressions,” *The Journal of Prosthetic Dentistry*, vol. 115, no. 3, pp. 313–320, 2016.  
Ender A. and A. Mehl, “Accuracy of complete-arch dental impressions: a new method of measuring trueness and precision,” *The Journal of Prosthetic Dentistry*, vol. 109, no. 2, pp. 121–128, 2013.
- 94) Ender A, Mehl A, “Accuracy in dental medicine, a new way to measure trueness and precision,” *Journal of Visualized Experiments*, no. 86, article e51374, 2014.
- 95) Jeong ID, Lee JJ, Jeon JH, Kim JH, Kim HY, Kim WC. Accuracy of complete-arch model using an intraoral video

scanner: an in vitro study. *The Journal of Prosthetic Dentistry* 2016; vol. 115, no. 6, pp. 755–759.

- 96) Deepak V, Malgaonkar N, Shah NK, Nasser AS, Dagrus K, Bassel T. Palatal rugae patterns in orthodontically treated cases, are they a reliable forensic marker? *Journal of International Oral Health* 2014; 6(5):89-95.
- 97) Shetty D, Juneja A, Jain A, Khanna KS, Pruthi N, Gupta A, Chowdhary M. Assessment of palatal rugae pattern and their reproducibility for application in forensic analysis. *Journal of Forensic Dental Science* 2013; 5:106-9.